



Creating Life in Colors

VIDHI
DIAGNOSTICS

Pathology Department

Patient's name : PATEL DINESHBHAI KANJIBHAI
Age/Sex : 57 Years/Male
Referred by : MEDI WHEEL
Collection Time : 09:57

Reg. ID : P-6846-23
Accession : 24675
Order Dt/time : 23/03/2024 09:57

BIOCHEMISTRY

Sample type :Serum

Test Name	Result	Units	Biological Reference Interval
Urea , (Serum by GLDH method) :	22.8	mg/dl	10 - 50
S.Uric acid , (Serum by Uricase method) :	6.3	mg/dl	3.4 - 7.0
Bun :	10.7	mg/dl	6-20
Creatinine , (Serum by Enzymatic reaction) :	0.90	mg/dl	0.5-1.2
S.G.P.T (ALT) : (Serum by IFCC method)	15.4	U/L	0 - 40
S.G.O.T (AST) : (Serum by IFCC method)	18.5	U/L	0 - 37
ALK.PHOSPHATASE : (Serum by PNP method)	81	U/L	40-129
G.G.T :	28.1	U/L	8 - 78
<u>BILIRUBIN</u>			
Total :	0.75	mg/dl	Up to 1.2
Direct :	0.33	mg/dl	0-0.7
Indirect :	0.42	mg/dl	0 - 0.5
<u>SERUM PROTEINS</u>			
Total Protein (Serum by Biuret method) :	6.44	gms/dl	6.4 - 8.5
Albumin (Serum by BCG method) :	3.98	gms/dl	3.97-4.94
Globulins :	2.46	gms/dl	2.3 - 3.5
A/G Ratio :	1.618		0.9 - 2.9

Dr. Gayatri M. Mehta
M. D. (Patho)

Reg. No. G-32215

DR GAYATRI MEHTA
MD(PATHOLOGY)

DR. ANAND D. PARIKH
MD(PATHOLOGY)

LAB USE ONLY (Entered by :GM Enter Date/Time:23/03/2024 6:45:00 PM) (Verify by :GM Verify Date/Time:23/03/2024 7:10:00 PM)



Vidhi Diagnostics | Pathology Department

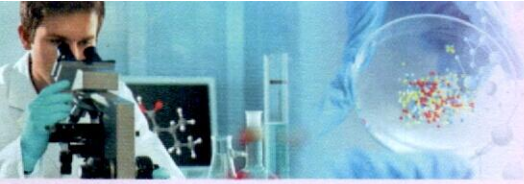L-86, Swatantra Senani Nagar, Opp. Akhbaragar Petrol Pump, Nr. Akhbaragar Circle, Nava-Vadaj, Ahmedabad - 380 013.

M. - Pathology : 8849893954, Ph. : 079-27621406, M. 98799 29406, 98250 09406, E-mail : vidhidiagnostics@gmail.com, Web. : www.vidhidiagnostics.com

Time (Pathology) : Mon. to Sat. 8.30 am to 8.00 pm, Sunday 9 am to 12 Noon

Pathology means science behind medicine

CT SCAN & CBCT FACILITY NOW AVAILABLE



Pathology Department



Patient's name : PATEL DINESHBHAI KANJIBHAI
 Age/Sex : 57 Years/Male
 Referred by : MEDI WHEEL
 Collection Time : 09:57

Reg. ID : P-6846-23
 Accession : 24675
 Order Dt/time : 23/03/2024 09:57

Complete Blood Count

Sample Type: EDTA

Test Name	Result	Units	Biological Reference Interval
<u>Blood Counts</u>			
Haemoglobin :	14.3	Gms%	13.5 - 18.0
Total R.B.C. :	4.31	mill/c.mm	4.7 - 6.0
Total W. B. C. :	5890	/cu mm	4000 - 10500
Platelet Count :	204000	/cu.mm	1,50,000 - 4,50,000
<u>Differential Count</u>			
Neutrophils :	55	%	40 - 70
Lymphocytes :	40	%	20 - 40
Eosinophils :	03	%	1 - 4
Monocytes :	02	%	2 - 6
Basophils::	00	%	0 - 01
<u>Blood Indices</u>			
P. C. V :	43.3	%	42 - 52
M. C. V. :	100.5	fl	78 - 100
M.C.H :	33.1	pg	27 - 31
M. C. H. C :	33.0	%	32 - 36
R.D.W :	13.5	%	11.5 - 14.0

E.S.R.(Westergren Method)

After one hour : 06 mm/hr 1 - 7

TESTS DONE ON FULLY AUTOMATED HEMATOLOGY ANALYZER.

Dr. Gayatri M. Mehta

M. D. (Patho)

Reg. No. G-32215

DR GAYATRI MEHTA
 MD(PATHOLOGY)

DR.ANAND D.PARIKH
 MD(PATHOLOGY)

LAB USE ONLY (Entered by :GM Enter Date/Time:23/03/2024 6:45:00 PM) (Verify by :GM Verify Date/Time:23/03/2024 6:45:00 PM)



Vidhi Diagnostics | Pathology Department

L-86, Swatantra Senani Nagar, Opp. Akhbarnagar Petrol Pump, Nr. Akhbarnagar Circle, Nava-Vadaj, Ahmedabad - 380 013.

M. - Pathology : 8849893954, Ph. : 079-27621406, M. 98799 29406, 98250 09406, E-mail : vidhidiagnostics@gmail.com, Web. : www.vidhidiagnostics.com

Time (Pathology) : Mon. to Sat. 8.30 am to 8.00 pm, Sunday 9 am to 12 Noon

Pathology means science behind medicine

CT SCAN & CBCT FACILITY NOW AVAILABLE



Pathology Department

Patient's name : PATEL DINESHBHAI KANJIBHAI
 Age/Sex : 57 Years/Male
 Referred by : MEDI WHEEL
 Collection Time : 09:57

Reg. ID : P-6846-23
 Accession : 24675
 Order Dt/time : 23/03/2024 09:57

Blood Group

Sample Type: EDTA sample.

Test Name	Result
BG :	" O "
RH :	POSITIVE
Remarks :	Done by forward grouping method.

Blood Glucose

Sample Type: Serum

Test Name	Result	Units	Biological Reference Interval
Fasting Blood Glucose :	<u>111.1</u>	mg/dl	70 - 110
Urine Sugar :	NIL		Absent
<i>GOD-POD Method.</i>			

Blood Glucose

Sample Type: Serum

Test Name	Result	Units	Biological Reference Interval
Post Prandial Blood Glucose After 2hr. :	SAMPLE NOT RECEIVED	mg/dl	80 - 140
Urine Sugar :	SAMPLE NOT RECEIVED		Absent
<i>GOD-POD Method.</i>			

Dr. Gayatri M. Mehta

M. D. (Patho)

Reg. No. G-32215

DR GAYATRI MEHTA
MD(PATHOLOGY)

DR. ANAND D. PARIKH
MD(PATHOLOGY)

LAB USE ONLY (Entered by :GM Enter Date/Time:23/03/2024 6:47:00 PM) (Verify by :GM Verify Date/Time:23/03/2024 6:47:00 PM)



Vidhi Diagnostics | Pathology Department

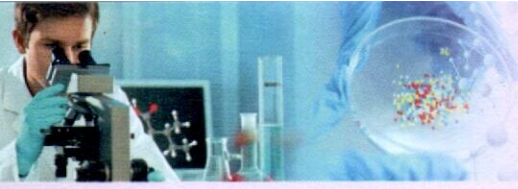L-86, Swatantra Senani Nagar, Opp. Akhbarnagar Petrol Pump, Nr. Akhbarnagar Circle, Nava-Vadaj, Ahmedabad - 380 013.

M. - Pathology : 8849893954, Ph. : 079-27621406, M. 98799 29406, 98250 09406, E-mail : vidhidiagnostics@gmail.com, Web. : www.vidhidiagnostics.com

Time (Pathology) : Mon. to Sat. 8.30 am to 8.00 pm, Sunday 9 am to 12 Noon

Pathology means science behind medicine

CT SCAN & CBCT FACILITY NOW AVAILABLE



Creating life in Gujarat

VIDHI[®] DIAGNOSTICS

Pathology Department

Patient's name : PATEL DINESHBHAI KANJIBHAI
Age/Sex : 57 Years/Male
Referred by : MEDI WHEEL
Collection Time : 09:57

Reg. ID : P-6846-23
Accession : 24675
Order Dt/time : 23/03/2024 09:57

HbA1C

Sample Type: EDTA

Test Name	Result	Units	Biological Reference Interval
HbA1C :	5.5	%	Non-diabetic: 4.2-6.2 Pre-diabetic : 6.3-7.2 Diabetic : 7.3-8.2
Mean Blood Glucose of Last 03 months.	111.15	mg/dl	

Comment

NOTE:

*As per the new 2009 update of American Diabetes Association regarding HbA1C & Mean Blood Glucose relationship.
This test is used to monitor diabetic patients compliance with the therapeutic regimen and logo It's level is proportional to both the average blood glucose concentration and the life span of the red blood cells (RBC) in circulation. HbA1c values are free of day to day glucose fluctuations and are unaffected by exercise or recent food intake.

Dr. Gayatri M. Mehta

M. D. (Patho)

Reg. No. G-32215

DR GAYATRI MEHTA
MD(PATHOLOGY)

DR. ANAND D. PARIKH
MD(PATHOLOGY)

LAB USE ONLY (Entered by : GM Enter Date/Time:23/03/2024 6:46:00 PM) (Verify by : GM Verify Date/Time:23/03/2024 6:46:00 PM)



Vidhi Diagnostics | Pathology Department

L-86, Swatantra Senani Nagar, Opp. Akhbarnagar Petrol Pump, Nr. Akhbarnagar Circle, Nava-Vadaj, Ahmedabad - 380 013.

M. - Pathology : 8849893954, Ph. : 079-27621406, M. 98799 29406, 98250 09406, E-mail : vidhidiagnostics@gmail.com, Web. : www.vidhidiagnostics.com

Time (Pathology) : Mon. to Sat. 8.30 am to 8.00 pm, Sunday 9 am to 12 Noon

Pathology means science behind medicine

CT SCAN & CBCT FACILITY NOW AVAILABLE



Pathology Department

VIDHI[®]
DIAGNOSTICS



Patient's name : PATEL DINESHBHAI KANJIBHAI
Age/Sex : 57 Years/Male
Referred by : MEDI WHEEL
Collection Time : 09:57

Reg. ID : P-6846-23
Accession : 24675
Order Dt/time : 23/03/2024 09:57

Lipid Profile

Sample Type: Serum

Test Name	Result	Units	Biological Reference Interval
S. Cholesterol : Oxidase-esterase method.	137	mg/dl	0 - 200
S. Triglyceride : Enzymatic Colorimetry method	101.9	mg/dL	0 - 200
S. HDL - Cholesterol : Serum by Enzymatic method.	32.2	mg/dL	35 - 65
S. LDL - Cholesterol : Serum by Enzymatic method	84.42	mg/dL	0 - 130
S. VLDL - Cholesterol :	20.38	mg/dL	0 - 30
S. Chole/HDL.Ratio :	4.25		1 - 6
S. LDL / HDL Cholesterol Ratio :	2.62		0 - 3.5

Dr. Gayatri M. Mehta

M. D. (Patho)

Reg. No. G-32215

DR GAYATRI MEHTA
MD(PATHOLOGY)

DR. ANAND D. PARIKH
MD(PATHOLOGY)

LAB USE ONLY (Entered by :GM Enter Date/Time:23/03/2024 6:46:00 PM) (Verify by :GM Verify Date/Time:23/03/2024 6:46:00 PM)



Vidhi Diagnostics | Pathology Department

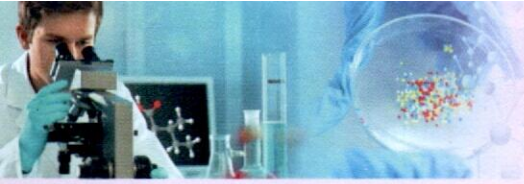L-86, Swatantra Senani Nagar, Opp. Akhbarnagar Petrol Pump, Nr. Akhbarnagar Circle, Nava-Vadaj, Ahmedabad - 380 013.

M. - Pathology : 8849893954, Ph. : 079-27621406, M. 98799 29406, 98250 09406, E-mail : vidhidiagnostics@gmail.com, Web. : www.vidhidiagnostics.com

Time (Pathology) : Mon. to Sat. 8.30 am to 8.00 pm, Sunday 9 am to 12 Noon

Pathology means science behind medicine

CT SCAN & CBCT FACILITY NOW AVAILABLE



Pathology Department



Patient's name : PATEL DINESHBHAI KANJIBHAI
Age/Sex : 57 Years/Male
Referred by : MEDI WHEEL
Collection Time : 09:57

Reg. ID : P-6846-23
Accession : 24675
Order Dt/time : 23/03/2024 09:57

Thyroid Function Test

Sample Type: Serum

Test Name	Result	Units	Biological Reference Interval
TOTAL T3 :	1.58	ng/ml	1.1 - 1.84
TOTAL T4 :	8.58	µg/dL	6.09 - 12.23
TSH(Ultra sensitive) :	2.98	µIU/mL	0.4001 - 4.049

Dr. Gayatri M. Mehta

M. D. (Patho)

Reg. No. G-32215

DR GAYATRI MEHTA
MD(PATHOLOGY)

DR. ANAND D. PARIKH
MD(PATHOLOGY)

LAB USE ONLY (Entered by :AP Enter Date/Time:23/03/2024 5:39:00 PM) (Verify by :GM Verify Date/Time:23/03/2024 6:05:00 PM)



Vidhi Diagnostics | Pathology Department

L-86, Swatantra Senani Nagar, Opp. Akhbarnagar Petrol Pump, Nr. Akhbarnagar Circle, Nava-Vadaj, Ahmedabad - 380 013.

M. - Pathology : 8849893954, Ph. : 079-27621406, M. 98799 29406, 98250 09406, E-mail : vidhidiagnostics@gmail.com, Web. : www.vidhidiagnostics.com

Time (Pathology) : Mon. to Sat. 8.30 am to 8.00 pm, Sunday 9 am to 12 Noon

Pathology means science behind medicine

CT SCAN & CBCT FACILITY NOW AVAILABLE



Pathology Department



Patient's name : PATEL DINESHBHAI KANJIBHAI
Age/Sex : 57 Years/Male
Referred by : MEDI WHEEL
Collection Time : 09:57

Reg. ID : P-6846-23
Accession : 24675
Order Dt/time : 23/03/2024 09:57

Urine Analysis

Sample Type: Urine

Test Name	Result	Units	Biological Reference Interval
<u>Physical Examination</u>			
Quantity :	30	ml	0 - 500 ml
Colour :	Pale Yellow		Pale Yellow
Transparency :	Slight Turbid.		Clear
Reaction :	Acidic		4.6 - 8.0
Specific Gravity :	1.012		1.016 - 1.022
Sediment :	Present		
<u>Chemical Examination</u>			
Albumin :	Present (Faint Trace)		Absent
Sugar :	NIL		Absent
Acetone :	Absent		Absent
Bile Salts :	Absent		Absent
Bile Pigments :	Absent		Absent
Urobilogen :	Absent		Absent
Nitrites :	Absent		Absent
<u>Microscopic Examination</u>			
Red blood Cells :	1-2	/h.p.f	Absent
Pus Cells :	2-3	/h.p.f	Absent
Epithelial Cells :	1-2	/h.p.f	< 10.0
Amorphous :	Absent	/h.p.f	Absent
Bacteria :	Absent	/h.p.f	Absent
Crystals :	Absent	/h.p.f	Absent
Casts :	Absent	/h.p.f	Absent
Fungus :	Not seen	/h.p.f	Absent

Dr. Gayatri M. Mehta
M. D. (Patho)

DR GAYATRI MEHTA - 32215



DR. ANAND D. PARIKH
MD (PATHOLOGY)



ONLY (Entered by :GM Enter Date/Time:23/03/2024 6:49:00 PM) (Verify by :GM Verify Date/Time:23/03/2024 6:49:00 PM)

Vidhi Diagnostics | Pathology Department

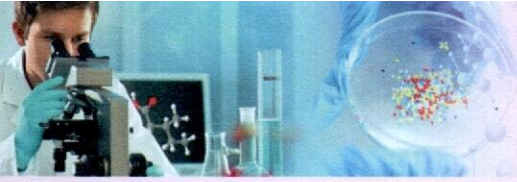L-86, Swatantra Senani Nagar, Opp. Akhbarnagar Petrol Pump, Nr. Akhbarnagar Circle, Nava-Vadaj, Ahmedabad - 380 013.

M. - Pathology : 8849893954, Ph. : 079-27621406, M. 98799 29406, 98250 09406, E-mail : vidhidiagnostics@gmail.com, Web. : www.vidhidiagnostics.com

Time (Pathology) : Mon. to Sat. 8.30 am to 8.00 pm, Sunday 9 am to 12 Noon

Pathology means science behind medicine

CT SCAN & CBCT FACILITY NOW AVAILABLE



Pathology Department

Patient's name : PATEL DINESHBHAI KANJIBHAI
 Age/Sex : 57 Years/Male
 Referred by : MEDI WHEEL
 Collection Time : 09:57

Reg. ID : P-6846-23
 Accession : 24675
 Order Dt/time : 23/03/2024 09:57

Stool Examination

Sample Type: Stool

Test Name	Result	Units	Biological Reference Interval
-----------	--------	-------	-------------------------------

PHYSICAL EXAMINATION

Quantity	10 gms
Colour	Brown
Consistency	Solid
Mucus	Nil
Occult Blood	Negative
Peroxidase Reaction with o-Dianisidine	
Reaction	Acidic
pH Strip Method	

MICROSCOPIC EXAMINATION

Pus Cells	2 - 3/hpf
RBCs	Nil
Vegetable Cells	Absent
Trophozoites	Nil
Cysts	Nil
Ova	Nil
Fat Globules	Nil

----- End Of Report -----

Dr. Gayatri M. Mehta
 M. D. (Patho)

DR GAYATRI MEHTA
 MD(PATHOLOGY)

DR. ANAND D. PARIKH
 MD(PATHOLOGY)

LAB USE ONLY (Entered by : GM Enter Date/Time:23/03/2024 6:47:00 PM) (Verify by : GM Verify Date/Time:23/03/2024 6:47:00 PM)



Vidhi Diagnostics | Pathology Department

L-86, Swatantra Senani Nagar, Opp. Akhbarnagar Petrol Pump, Nr. Akhbarnagar Circle, Nava-Vadaj, Ahmedabad - 380 013.

M. - Pathology : 8849893954, Ph. : 079-27621406, M. 98799 29406, 98250 09406, E-mail : vidhidiagnostics@gmail.com, Web. : www.vidhidiagnostics.com

Time (Pathology) : Mon. to Sat. 8.30 am to 8.00 pm, Sunday 9 am to 12 Noon

Pathology means science behind medicine

CT SCAN & CBCT FACILITY NOW AVAILABLE

Dr. Dinesh S. Modh

M.D., D.M.R.E. (Radiodiagnosis)
Consultant Radiologist & Sonologist
Ex. Junior Lecturer, B.J. Medical College, Civil Hospital, A'bad.



DATE: 23/3/2024		
NAME: Patel Dimeshbhai Kamsibhai		
AGE: 57 yrs male		
MEDICAL EXAMINATION:-		
HEIGHT: 177 cm	WEIGHT: 79 kg	
BP: 128/82 mmHg	PULSE: 64 per min	
SPO2: 98	TEMPERATURE: (N)	
RS: (N)	CVS: (N)	
ASYMTOMATIC		
HISTORY: No H/O DM, HTN, Thyroid or TB		
EYE CHECK-UP:-	RIGHT	LEFT
DISTANCE:	6/6	6/6
NEAR:	N/6	N/6
COLOR VISION:	(N)	(N)
DENTAL CHECK-UP: (N)		
ADV: HE/SHE IS MEDICALLY FIT		

Dr. Vidhi D. Modh
MBBS
Reg. No. C-71540

Vidhi Diagnostics
L-86, Swatantra-Senani Nagar,
Nr. Akhbarnagar Bus Terminals
Nr. Akhbarnagar Circle,
New Wadaj, Ahmedabad-13.

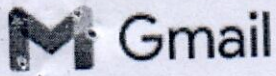
ISO 9001:2015 Certified Diagnostics Center
Vidhi Imaging Center

L-86, Swatantra Senani Nagar, Opp. Indian Oil Petrol Pump, Akhbarnagar Circle, Nava Vadaj, Ahmedabad - 380 013.

Phone : (Radiology) 079-2762 1406 | M. 98799 29406, 98250 09406 | Time (Radiology) : Mon. to Sat. 9 am to 2 pm, 5 to 9 pm, Sunday 9 am to 12 Noon
E-mail : vidhidiagnostics@gmail.com, Website : www.vidhidiagnostics.com

Multislice CT Scan | CBCT-Dental Scan | Live 3D-4D Sonography | Colour Doppler | Echo Cardiography | Interventional Radiology | Maxillofacial Radiology | Fetal Medicine
Digital X-Ray | Digital Mammography | Digital OPG/TMJ | ECG/TMT/PFT/EEG/EMG | Audiometry | Pathology Laboratory | Health Check Up Plans | Pre Employment Check Up

CT SCAN & CBCT FACILITY NOW AVAILABLE



vidhi diagnostics <vidhidiagnostics@gmail.com>

Health Check up Booking Request(bobE18078)

1 message

Mediwheel <wellness@mediwheel.in>
To: vidhidiagnostics@gmail.com
Cc: customercare@mediwheel.in

22 March 2024 at 14:40



Mediwheel
...Your wellness partner

011-41195959

Dear VIDHI DIAGNOSTICS

We have received a booking request with the following details. Provide your confirmation by clicking on the Yes button.

You confirm this booking? Yes No

Name : MR. PATEL DINESH KANJIBHAI

Contact Details : 9265388807

Hospital Package Name : Mediwheel Full Body Health Checkup Male Above 40

Location : L-86 Swatantra - Senani Nagar , Opp- Akhbarnagar Bus Terminals, New Wadaj , Ahmedabad -13

Appointment Date : 23-03-2024

Member Information		
Booked Member Name	Age	Gender
MR. PATEL DINESH KANJIBHAI	57 year	Male

Tests included in this Package -

- Stool Test
- Thyroid Profile
- ESR
- Blood Glucose (Fasting)
- General Physician Consultation
- TMT OR 2D ECHO
- Blood Group
- Blood Glucose (Post Prandial)
- Chest X-ray
- ECG
- USG Whole Abdomen
- Eye Check-up consultation
- Urine Sugar Fasting
- Urine Sugar PP
- Dental Consultation
- Urine analysis
- CBC
- HbA1c

ભારત સરકાર
Government of India

પટેલ દિનેશભાઈ કાનજીભાઈ
Patel Dineshbhai Kanjibhai

જન્મ તારીખ / DOB : 04/10/1966
પુરુષ / Male

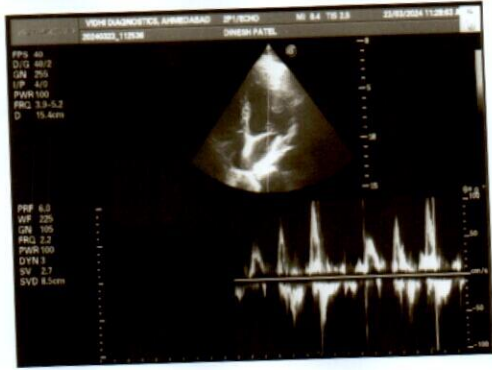
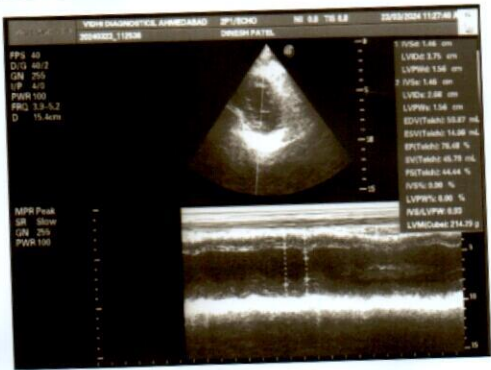
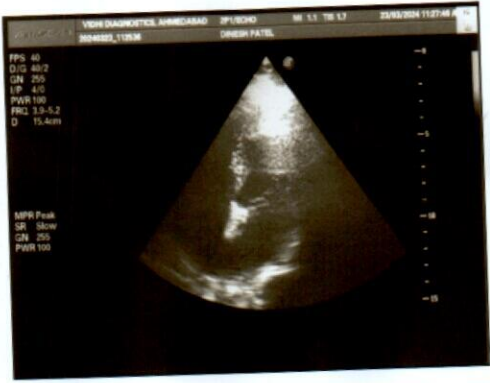
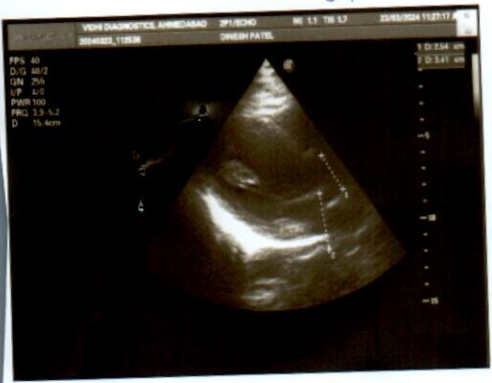
6564 5312 1002

આધાર - સામાન્ય માણસનો અધિકાર

Vidhi Diagnostics
L-86, Swatantra-Senani Nagar,
Nr. Akhbarnagar Bus Terminals
Nr. Akhbarnagar Circle,
New Wadaj, Ahmedabad-13.

Dimash



Dr. Dinesh S. Modh

M.D., D.M.R.E. (Radiodiagnosis)

Consultant Radiologist & Sonologist

Ex. Junior Lecturer, B.J. Medical College, Civil Hospital, A'bad.



Patient's name : PATEL DINESHBHAI KANJIBHAI
Reg. ID : R-14850-23
Referred by : MEDI WHEEL

Age/Sex : 57 Years/Male
Accession : 24703
Date : 23/03/2024

USG ABDOMEN

LIVER:- Liver appears normal in size & echo texture. No evidence of focal lesion is seen. IHBR appear normal. Portal vein and CBD appear normal. No e/o calculus is seen in bile duct.

GALL BLADDER:- Gall bladder is distended & appears normal. No evidence of calculus or cholecystitis is seen.

SPLEEN:- Spleen appears normal in size & shows normal echo texture. No evidence of diffuse or focal lesion is seen.

PANCREAS:- Pancreas appears normal size and echo pattern. No e/o diffuse or focal lesion is seen. Main pancreatic duct appears normal.

KIDNEY:- Both Kidneys appear normal in size & echo texture.

Right kidney shows 45x43mm cortical cyst in upper pole.

- No e/o calculus or hydronephrosis/ hydroureter is seen on both sides.

Cortico-medullary differentiation is maintained on both sides.

Both suprarenal regions appear normal.

No evidence of pre & para aortic lymphadenopathy is seen.

Both suprarenal regions appear normal.

No evidence of pre & para aortic lymphadenopathy is seen.

RIF & BOWEL LOOPS (By high frequency probe):-Normal.

No evidence of dilated or thickened bowel loops is seen.

No evidence of free fluid is seen in abdomen.

Urinary bladder:- appears normal. No e/o calculus or mass lesion is seen in bladder.

Prostate appears normal size and echopattern.

Thanks for reference.

Dr. Dinesh S. Modh
MD, DMRE (Radiodiagnosis)
DR DINESH S. MODH
G-23825
M.D. DMRE(RADIODIAGNOSIS)

Vidhi Diagnostics
L-86, Swatantra-Senani Nagar,
Nr. Akhbarnagar Bus Terminals
Nr. Akhbarnagar Circle,
New Wadaj, Ahmedabad-13.

ISO 9001:2015 Certified Diagnostics Center

Vidhi Imaging Center

L-86, Swatantra Senani Nagar, Opp. Indian Oil Petrol Pump, Akhbarnagar Circle, Nava Vadaj, Ahmedabad - 380 013.

Phone : (Radiology) 079-2762 1406 | M. 98799 29406, 98250 09406 | Time (Radiology) : Mon. to Sat. 9 am to 2 pm, 5 to 9 pm, Sunday 9 am to 12 Noon
E-mail : vidhidiagnostics@gmail.com, Website : www.vidhidiagnostics.com

Multislice CT Scan | CBCT-Dental Scan | Live 3D-4D Sonography | Colour Doppler | Echo Cardiography | Interventional Radiology | Maxillofacial Radiology | Fetal Medicine
Digital X-Ray | Digital Mammography | Digital OPG/TMJ | ECG/TMT/PFT/EEG/EMG | Audiometry | Pathology Laboratory | Health Check Up Plans | Pre Employment Check Up

CT SCAN & CBCT FACILITY NOW AVAILABLE

Dr. Dinesh S. Modh

M.D., D.M.R.E. (Radiodiagnosis)

Consultant Radiologist & Sonologist

Ex. Junior Lecturer, B.J. Medical College, Civil Hospital, A'bad.

VIDHI
DIAGNOSTICS



Patient's name : PATEL DINESHBHAI KANJIBHAI
Reg. ID : R-14850-23
Referred by : MEDI WHEEL

Age/Sex : 57 Years/Male
Accession : 24703
Date : 23/03/2024

X-RAY CHEST (PA VIEW)

- Both lung fields show prominence broncho-vascular markings with prominence both hila.
- Cardiomegaly is noted in transverse diameter.

Both C-P angles appear clear.

Both domes of diaphragm appear normal.

Bony thoracic cage appears normal.

Thanks for reference.

Dr. Dinesh S. Modh
MD DMRE (Radiodiagnosis)
DR DINESH S. MODH
G-23825
M.D. DMRE(RADIODIAGNOSIS)

Vidhi Diagnostics
L-86, Swatantra-Senani Nagar,
Nr. Akhbarnagar Bus Terminals
Nr. Akhbarnagar Circle,
New Wadaj, Ahmedabad-13.

ISO 9001:2015 Certified Diagnostics Center

Vidhi Imaging Center

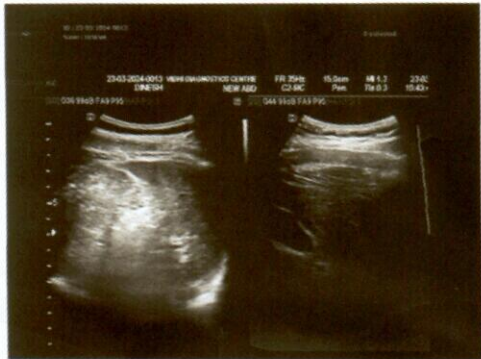
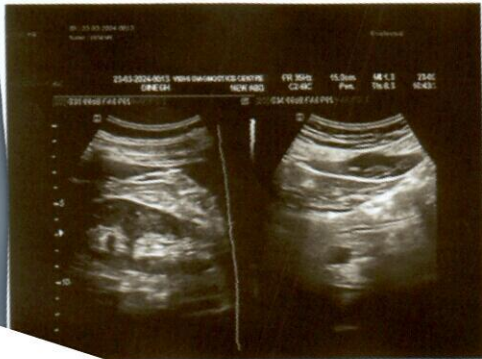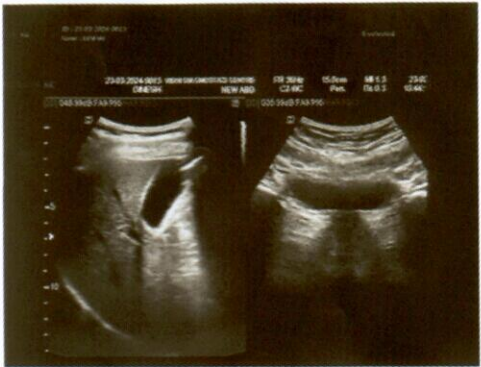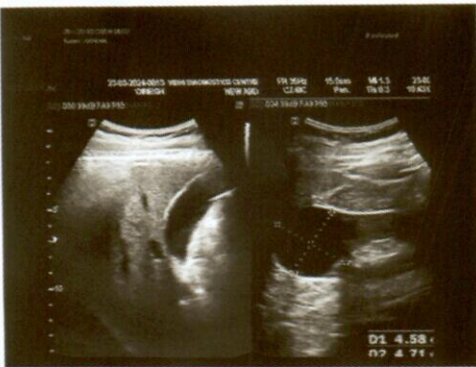L-86, Swatantra Senani Nagar, Opp. Indian Oil Petrol Pump, Akhbarnagar Circle, Nava Vadaj, Ahmedabad - 380 013.

Phone : (Radiology) 079-2762 1406 | M. 98799 29406, 98250 09406 | Time (Radiology) : Mon. to Sat. 9 am to 2 pm, 5 to 9 pm, Sunday 9 am to 12 Noon

E-mail : vidhidiagnostics@gmail.com, Website : www.vidhidiagnostics.com

Multislice CT Scan | CBCT-Dental Scan | Live 3D-4D Sonography | Colour Doppler | Echo Cardiography | Interventional Radiology | Maxillofacial Radiology | Fetal Medicine
Digital X-Ray | Digital Mammography | Digital OPG/TMJ | ECG/TMT/PFT/EEG/EMG | Audiometry | Pathology Laboratory | Health Check Up Plans | Pre Employment Check Up

CT SCAN & CBCT FACILITY NOW AVAILABLE



ID: 13171

Name: dinesh oarel

Age: 54yrs

Sex: Male

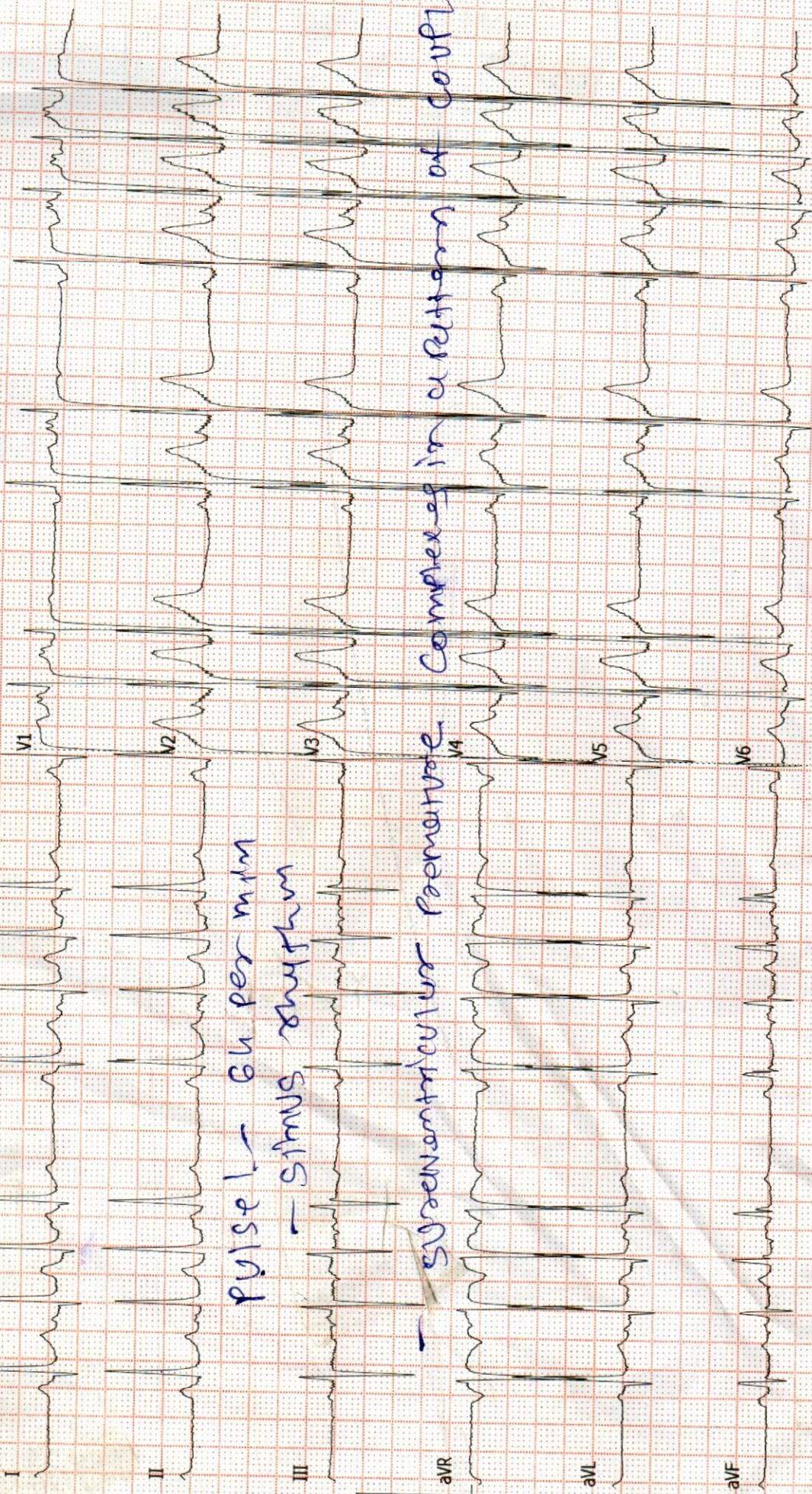
Hospital:

Dr. Avinash Bhaskar
Avinash Radio

Reg. No.: G-45946

HR : 64 bpm
PR : 140 ms
QRS : 94 ms
QT/QTc : 334/344 ms
P/QRS/T : 35/10/24 deg.
RV5/SV1 : 1.712/-1.285 mv
RV5+SV1 : 2.997 mv

0.67Hz - 35Hz AC 50Hz 25 mm/s 20 mm/mv



Pulse - 64 per min
- sinus rhythm

- supraventricular premature complexes in a pattern of couplet

Need to be confirmed by doctor. Doctor Name: _____

<< Analysis Result >>

** abnormal ECG **

Sinus rhythm

Supraventricular premature complexes in a pattern of couplet

Short QT interval

Multi-Diagnosics

L-86, Swatantra Main Road,
Opp. Akhbar, Bus Terminals,
Nr. Akhbar, Far Circle,
New Wadaj, Ahmedabad-13.