



Aravali Hospital

332, Ambamata Scheme, Udaipur - 313 004

T: 91 294 2430222, 2431222

email : aravalihospital@yahoo.com



गुणवत्ता पूर्ण चिकित्सा सेवाओं के लिये
भारत सरकार की
क्वालिटी काउंसिल ऑफ इण्डिया (QCI-NABH)
द्वारा प्रमाणित

Date : 13/04/2024			
Patient's Name :	MS. PRIYANKA JI	Age: 32 yrs	Sex: Female
Ref. By :	Dr. Y.K.BOLIYA (MD)		

ULTRA SONOGRAPHY REPORT -WHOLE ABDOMEN

Liver	Liver is normal in size, shape, position & contour with normal homogenous echopattern. No evidence of any focal lesion is seen. IHBR are not dilated. Portal vein measures 13 mm. IVC is normal.
Gall bladder	GB is normal in size & shape. Its wall thickness is normal. No evidence of any calculi is seen. No pericholecystic fluid collection is seen.
Pancreas	Pancreas is normal in size, shape, position & contour with normal homogenous echo pattern. Pancreatic duct is not dilated.
Spleen	Spleen is normal in size, shape, position and contour with normal homogenous echopattern. Splenic vein is not dilated.
Kidneys	Both kidneys are normal in size, shape, position & contour with well differentiated corticomedullary junction and normal cortical thickness. Pelvicalyceal system is not dilated. No evidence of any calculi is seen. Visualized portion of ureters appears normal. Right kidney measures 100x42 mm. Left kidney measures 108x47 mm.
Urinary Bladder	Urinary bladder is well distended with urine & is normal in size, shape & contour with normal & smooth walls.
Uterus	Uterus is normal in size, shape & contour. It is anteverted & anteflexed in position. It reveals homogenous echopattern. Uterus measures 83x53x39 mm
Endometrium	Endometrium is normal & its thickness measures 5 mm. Copper-T is seen in uterine cavity.
Ovaries	Left ovary is normal in size, shape & position. A cyst of size 29x21 mm is seen in right ovary. Left ovary measures 42x21 mm

IMPRESSION

Follicular cyst right ovary

Dr. SURESH CHANDRA BASER

MBBS,MD
Consultant Radiologist
(RMC-7219)

Dr. ANAND GUPTA

MBBS,DMRE
Consultant Radiologist
(RMC-17548)

Note: The foetal gender has not been detected nor disclosed to the patient.

This report is not valid for medico legal purpose.
Every report needs to be correlated and interpreted clinically.
In case of any query, investigation may be repeated.



Helpline : 9352 108 108

www.aravalihospital.in

BOB

PRIYANKA 32 YRS
Female

4/13/2024 9:41:27 AM

Rate 75 . Age not entered, assumed to be 50 years old for purpose of ECG interpretation
Sinus rhythm.....normal P axis, V-rate 50- 99

PR 156
QRSD 93
QT 380
QTc 425

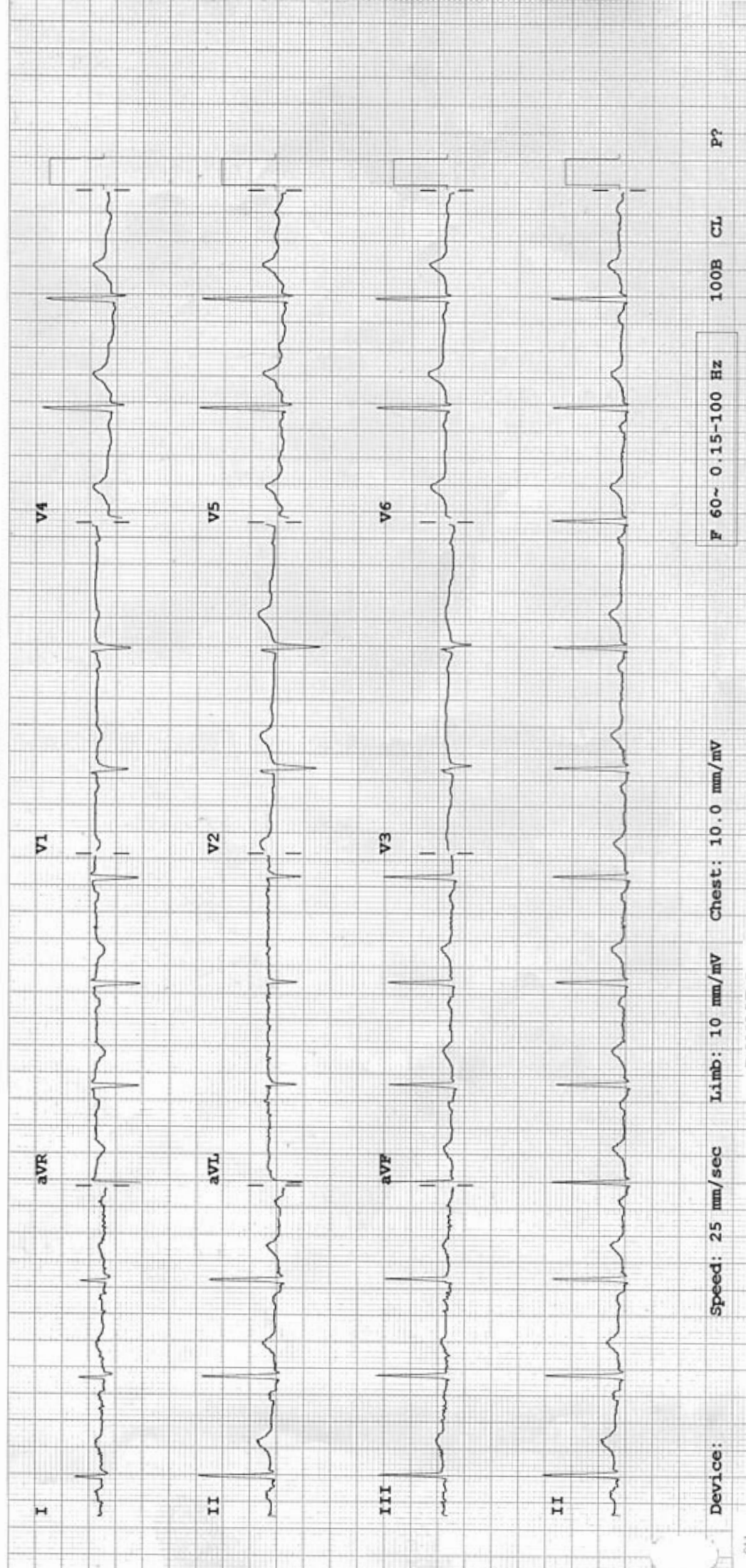
--AXIS--

P 43
QRS 78
T 55

12 Lead; Standard Placement

- NORMAL ECG -

Unconfirmed Diagnosis



Device:

Speed: 25 mm/sec

Limb: 10 mm/mV

Chest: 10.0 mm/mV

F 60~ 0.15-100 Hz

100B CL

P?



Aravali Hospital

332, Ambamata Scheme, Udaipur - 313 004

T: 91 294 2430222, 2431222

email : aravalihospital@yahoo.com



गुणवत्ता पूर्ण चिकित्सा सेवाओं के लिये
भारत सरकार की
क्वालिटी काउंसिल ऑफ इण्डिया (QCI-NABH)
द्वारा प्रमाणित

LABORATORY REPORT



Name : Mrs PRIYANKA CHANDALIYA	Sex/Age : Female/ 32 Years	H.ID :	Case ID : 40401502044
Ref By :	Dis.Loc. :		Pt ID :
Bill. Loc. : Aravali pathlabs Udaipur			Pt. Loc. :
Registration Date & Time : 13-Apr-2024 12:59	Sample Type : Slide		Ph # :
Sample Date & Time : 13-Apr-2024 12:59	Sample Coll. By :		Ref Id : 1124446
Report Date & Time : 13-Apr-2024 15:03	Acc. Remarks :		Ref Id2 :

Cytopathology Report

Specimen :

Pap smear for cytology (conventional)

Clinical Data :

NA

Macroscopic Examination :

Received 1 unstained smears.

Microscopic Examination :

See below in diagnosis

Impression :

The Bethesda System (TBS 2014) (Conventional Pap)

Specimen type: Conventional Pap smear.

Specimen adequacy: Satisfactory for evaluation with partially obscuring inflammation

Transformation zone elements: Not present

Infection associated changes: Trichomonas or Monilia are not seen.



Reactive cellular changes: Present, mild inflammation related.

Epithelial cell abnormality: Nil

Other cells: Nil

Grossing By :

For test performed on specimens received or collected from non-NSRL locations, it is presumed that the specimen belongs to the patient named or identified as labeled on the container/test request and such verification has been carried out at the point generation of the said specimen by the sender. NSRL will be responsible Only for the analytical part of test carried out. All other responsibility will be of referring Laboratory.


 Dr Khyati Shah
 MD Pathology 2


Helpline : 9352 106108 Printed On : 13-Apr-2024 15:07

www.aravalihospital.in



Aravali Hospital

332, Ambamata Scheme, Udaipur - 313 004

T: 91 294 2430222, 2431222

email : aravalihospital@yahoo.com



गुणवत्ता पूर्ण चिकित्सा सेवाओं के लिये
भारत सरकार की
क्वालिटी काउंसिल ऑफ इण्डिया (QCI-NABH)
द्वारा प्रमाणित

LABORATORY REPORT

Name : Mrs PRIYANKA CHANDALIYA	Sex/Age : Female/ 32 Years	H.ID :	Case ID : 40401502044
Ref By :	Dis.Loc. :		Pt ID :
Bill. Loc. : Aravali pathlabs Udaipur			Pt. Loc. :
Registration Date & Time : 13-Apr-2024 12:59	Sample Type : Slide		Ph # :
Sample Date & Time : 13-Apr-2024 12:59	Sample Coll. By :		Ref Id : 1124446
Report Date & Time : 13-Apr-2024 15:03	Acc. Remarks :		Ref Id2 :


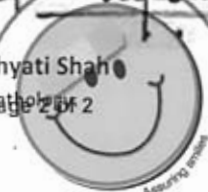
Interpretation/result: Negative for intraepithelial lesion or malignancy.

Pap test is a screening test for cervical cancer with inherent false negative results.

----- End Of Report -----

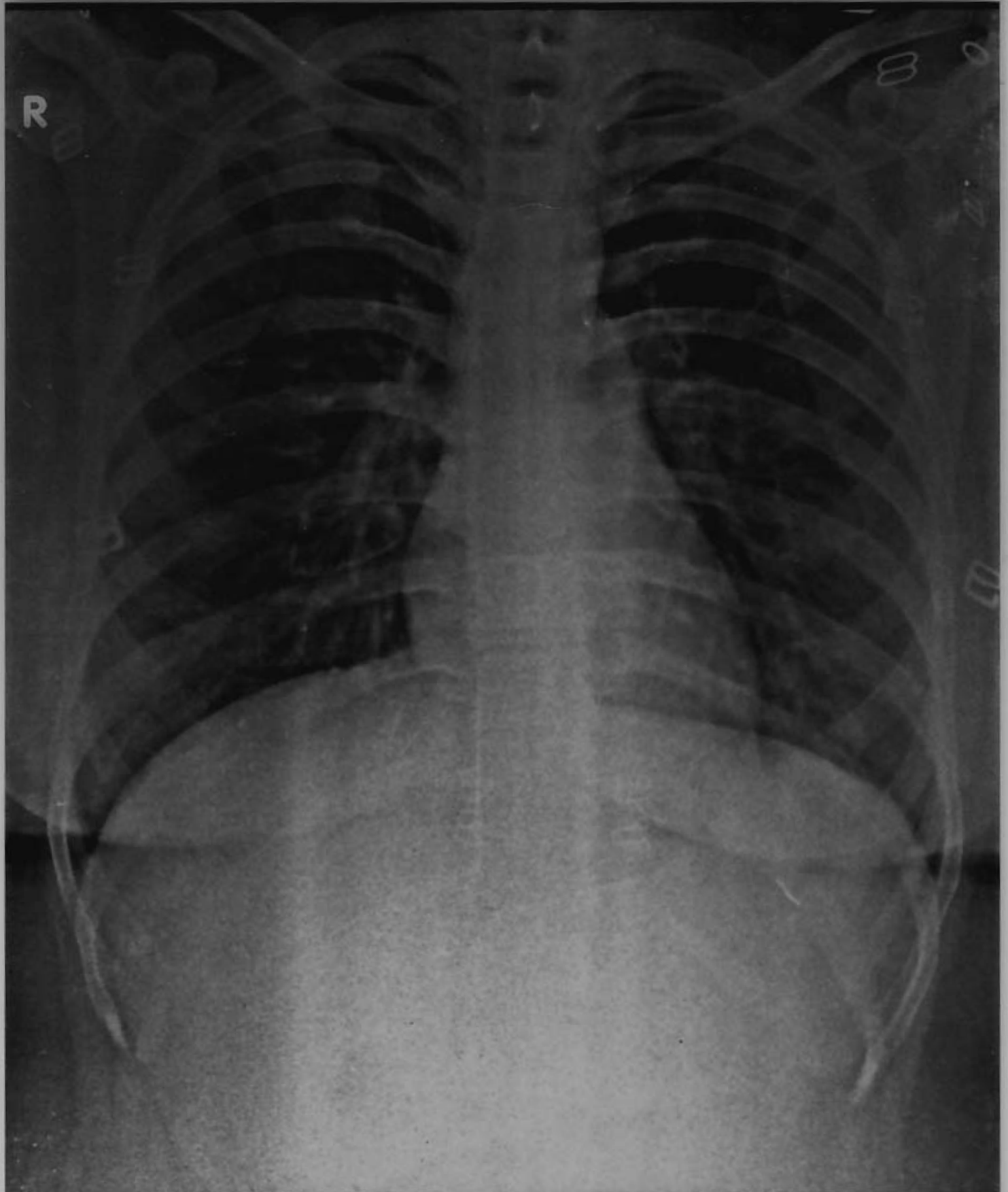
Grossing By :

For test performed on specimens received or collected from non-NSRL locations, it is presumed that the specimen belongs to the patient named or identified as labeled on the container/test request and such verification has been carried out at the point generation of the said specimen by the sender. NSRL will be responsible Only for the analytical part of test carried out. All other responsibility will be of referring Laboratory.


 Dr Khyati Shah
 MD Pathology


Helpline : 9352 18108 On : 13-Apr-2024 15:07

www.aravalihospital.in



PRIYANKA CHAMDALIYA 32YRS OPD2910 F CHEST PA 13-Apr
ARAVALI HOSPITAL, 332 AMBAMATA SCHEME, UDAIPUR



Aravali Hospital

332, Ambamata Scheme, Udaipur - 313 004
T: 91 294 2430222, 2431222
email : aravalihospital@yahoo.com



गुणवत्ता पूर्ण चिकित्सा सेवाओं के लिये
भारत सरकार की
क्वालिटी काउंसिल ऑफ इण्डिया (QCI-NABH)
द्वारा प्रमाणित

Name Ms. PRIYANKA CHANDALIYA	Visit Date & Time 13/04/2024	PATIENT ID 1124446
Age 32 Yrs Sex Female	Test Authenticated at : 13/04/2024 16:49:44	Ref. By



HAEMATOLOGY

Test Name	Value	Status	Unit	Biological Ref Interval
HAEMOGLOBIN (HB)	11.4		gm %	11.0 - 16.0
RBC Count	3.64		X10 ⁶ /UL	3.50 - 5.50
PCV	32.5	L	%	36.0 - 48.0
MEAN CORP. VOLUME (MCV)	89.2		fL	80.0 - 99.0
MEAN CORP. HB (MCH)	31.3		pg	27.0 - 32.0
MEAN CORP. HB CON. (MCHC)	35.1		g/dL	32.0 - 36.0
RDW-CV	11.7		%	11.0 - 16.0
RDW-SD	40.5		fl	35.0 - 56.0
TLC Count	4.24		/cmm	4.00 - 11.00
Differential Leucocyte Count (DLC)				
POLYMORPH	61		%	45 - 75
LYMPHOCYTE	30		%	20 - 45
EOSINOPHIL	03		%	01 - 06
MONOCYTE	06		%	01 - 10
BASOPHIL	00		%	00 - 01
TOTAL PLATELET COUNT	227		x10 ³ /uL	150 - 450
MPV	11.1	H		7.4 - 10.4
PDW	13.6		%	10.0 - 17.0
PCT	0.3		%	0.1 - 0.3
P-LCR	39.1		%	11.0 - 45.0
P-LCC	89.0			30.0 - 90.0



DR. NARENDRA MOGRA
RMC NO5394



Aravali Hospital

332, Ambamata Scheme, Udaipur - 313 004
T: 91 294 2430222, 2431222
email : aravalihospital@yahoo.com



गुणवत्ता पूर्ण चिकित्सा सेवाओं के लिये
भारत सरकार की
क्वालिटी काउंसिल ऑफ इण्डिया (QCI-NABH)
द्वारा प्रमाणित

Name Ms. PRIYANKA CHANDALIYA	Visit Date & Time 13/04/2024	PATIENT ID 1124446
Age 32 Yrs Sex Female	Test Authenticated at : 13/04/2024 16:49:44	Ref. By



HAEMATOLOGY

Test Name	Value	Status	Unit	Biological Ref Interval
ESR	6		mm/Ist hr.	0 - 20
Blood Group (ABORH)	'A'	POSITIVE		



DR. NARENDRA MOGRA
RMC NO5394



Aravali Hospital

332, Ambamata Scheme, Udaipur - 313 004
T: 91 294 2430222, 2431222
email : aravalihospital@yahoo.com



गुणवत्ता पूर्ण चिकित्सा सेवाओं के लिये
भारत सरकार की
क्वालिटी काउंसिल ऑफ इण्डिया (QCI-NABH)
द्वारा प्रमाणित

Name Ms. PRIYANKA CHANDALIYA	Visit Date & Time 13/04/2024	PATIENT ID 1124446
Age 32 Yrs Sex Female	Test Authenticated at : 13/04/2024 16:49:44	Ref. By



Test Name	Value	Status	Unit	Biological Ref Interval
-----------	-------	--------	------	-------------------------

LIPID PROFILE

CHOLESTEROL TOTAL	144.00		mg/dl	<200.00
TRIGLYCERIDES	91.51		mg/dl	0.00 - 200.00
HDL CHOLESTEROL	57.46		mg/dl	30.00 - 65.00
LDL CHOLESTROL	68.00		mg/dl	35.00 - 100.00
VLDL CHOLESTEROL	18.00		mg/dl	12.00 - 35.00
CHOLESTEROL TOTAL / HDL RATIO	2.51			0.00 - 4.90
CHOLESTEROL LDL / HDL RATIO	1.18			0.00 - 5.00



DR. NARENDRA MOGRA
RMC NO5394



Aravali Hospital

332, Ambamata Scheme, Udaipur - 313 004
T: 91 294 2430222, 2431222
email : aravalihospital@yahoo.com



गुणवत्ता पूर्ण चिकित्सा सेवाओं के लिये
भारत सरकार की
क्वालिटी काउंसिल ऑफ इण्डिया (QCI-NABH)
द्वारा प्रमाणित

Name Ms. PRIYANKA CHANDALIYA	Visit Date & Time 13/04/2024	PATIENT ID 1124446
Age 32 Yrs Sex Female	Test Authenticated at : 13/04/2024 16:49:44	Ref. By



Test Name	Value	Status	Unit	Biological Ref Interval
-----------	-------	--------	------	-------------------------

LIVER FUNCTION TEST (LFT)

BILIRUBIN-TOTAL	0.37		mg/dl	0.20 - 1.20
BILIRUBIN-DIRECT	0.16		mg/dl	0.00 - 0.25
BILIRUBIN-INDIRECT	0.21		mg/dl	0.10 - 0.40
SGOT-AST	17.50		U/L	0.00 - 35.00
SGPT-ALT	13.44		U/L	0.00 - 45.00
ALKALINE PHOSPHATASE	50.00		IU/L	35.00 - 129.00
PROTIEN-TOTAL	7.70		gm/dl	6.00 - 8.50
ALBUMIN	4.12		gm/dl	3.50 - 5.20
GLOBULIN	3.58		gm/dl	2.50 - 4.00
A:G RATIO	1.15			1.10 - 2.20



DR. NARENDRA MOGRA
RMC NO5394



Aravali Hospital

332, Ambamata Scheme, Udaipur - 313 004
T: 91 294 2430222, 2431222
email : aravalihospital@yahoo.com



गुणवत्ता पूर्ण चिकित्सा सेवाओं के लिये
भारत सरकार की
क्वालिटी काउंसिल ऑफ इण्डिया (QCI-NABH)
द्वारा प्रमाणित

Name Ms. PRIYANKA CHANDALIYA	Visit Date & Time 13/04/2024	PATIENT ID 1124446
Age 32 Yrs Sex Female	Test Authenticated at : 13/04/2024 16:49:44	Ref. By



BIOCHEMISTRY

Test Name	Value	Status	Unit	Biological Ref Interval
CREATININE	0.65		mg/dl	0.50 - 1.30
URIC ACID	2.82		mg/dl	2.60 - 7.20
BUN	6.11	L	mg/dl	7.00 - 22.00
GAMMA GT	28.0		U/L	10.0 - 61.0



DR. NARENDRA MOGRA
RMC NO5394



Aravali Hospital

332, Ambamata Scheme, Udaipur - 313 004
T: 91 294 2430222, 2431222
email : aravalihospital@yahoo.com



गुणवत्ता पूर्ण चिकित्सा सेवाओं के लिये
भारत सरकार की
क्वालिटी काउंसिल ऑफ इण्डिया (QCI-NABH)
द्वारा प्रमाणित

Name Ms. PRIYANKA CHANDALIYA	Visit Date & Time 13/04/2024	PATIENT ID 1124446
Age 32 Yrs Sex Female	Test Authenticated at : 13/04/2024 16:49:44	Ref. By



BIOCHEMISTRY

Test Name	Value	Status	Unit	Biological Ref Interval
HBA1C				
GLYCOSYLATED HAEMOGLOBIN-A1C	4.20		%	Below 6.5% : Good Control 6.5% - 7% : Fair Control 7.0% - 8% : Unsatisfactory Control >8% Poor Control
AVERAGE BLOOD GLUCOSE (ABG) Method: Derived from HbA1c Value	73.84	L	%	90 - 120 Good Control 121 - 150 Fair Control 151 - 180 Unsatisfactory Control > 180 Poor Control



DR. NARENDRA MOGRA
RMC NO5394



Aravali Hospital

332, Ambamata Scheme, Udaipur - 313 004
T: 91 294 2430222, 2431222
email : aravalihospital@yahoo.com



गुणवत्ता पूर्ण चिकित्सा सेवाओं के लिये
भारत सरकार की
क्वालिटी काउंसिल ऑफ इण्डिया (QCI-NABH)
द्वारा प्रमाणित

Name Ms. PRIYANKA CHANDALIYA	Visit Date & Time 13/04/2024	PATIENT ID 1124446
Age 32 Yrs Sex Female	Test Authenticated at : 13/04/2024 16:49:44	Ref. By



IMMUNOLOGY

Test Name	Value	Status	Unit	Biological Ref Interval
T3	1.29		ng/ml	0.87 - 1.78
T4	10.25		ug/dl	4.82 - 15.65
TSH	1.430		micro U/ml	0.340 - 5.600

TSH levels may be affected by acute illness and drugs like dopamine and gluco corticoids.

Low or undetectable TSH is suggestive of Grave's disease

TSH between 5.5 to 15.0 with normal T3,T4 indicates impaired thyroid hormone or subclinical hypothyroidism or normal T3,T4 with slightly low TSH suggests subclinical hyperthyroidism

TSH suppression does not reflect severity of hyperthyroidism therefore, measurement of FT3,FT4 is important.

Free T3 is first hormone to increase in early hyperthyroidism.
Only TSH level can prove to be misleading in patients on treatment.

Therefore Free T3, Free T4 along with TSH should be checked.
During pregnancy clinically T3T4 can be high and TSH can be slightly low.



DR. NARENDRA MOGRA
RMC NO5394



Aravali Hospital

332, Ambamata Scheme, Udaipur - 313 004
T: 91 294 2430222, 2431222
email : aravalihospital@yahoo.com



गुणवत्ता पूर्ण चिकित्सा सेवाओं के लिये
भारत सरकार की
क्वालिटी काउंसिल ऑफ इण्डिया (QCI-NABH)
द्वारा प्रमाणित

Name Ms. PRIYANKA CHANDALIYA	Visit Date & Time 13/04/2024	PATIENT ID 1124446
Age 32 Yrs Sex Female	Test Authenticated at : 13/04/2024 16:49:44	Ref. By



CLINICAL PATHOLOGY

Test Name	Value	Status	Unit	Biological Ref Interval
-----------	-------	--------	------	-------------------------

URINE EXAMINATION

PHYSICAL EXAMINATION

QUANTITY	20
COLOUR	PALE YELLOW
SPECIFIC GRAVITY	QNS
APPEARANCE	HAZY
DEPOSITS	NIL
PH	ACIDIC

CHEMICAL EXAMINATION

ALBUMIN	TRACE
SUGAR	NIL

MICROSCOPY EXAMINATION

EPITHELIAL CELLS	10-15	/HPF
PUS CELLS	10-12	/HPF
RBC'S	NIL	/HPF
CASTS	ABSENT	
CRYSTALS	A.URATES+	
BACTERIA	+	
YEAST CELLS	NIL	
TRICHOMONAS VAGINALIS	NIL	
SPERMATOZOA	NIL	
OTHERS	NIL	



*** End of Report ***

DR. NARENDRA MOGRA
RMC NO5394
DR. HUSSAIN ALI RANGWALA