



# LIFE LINE

## Multispeciality Hospital Maternity Home & ICU

Plot No. 20, Gut No. 103, Opp. Surya Lawns Beed Bypass, Devlai, Chh. Sambhajinagar. Mob.: 9067028989, 9067038989

Rx


Date 29/03/2024

### Medical Fitness Certificate

This is to certify that below mentioned candidate has been examined on medical parameters and found free from contagious diseases there by medically fit for work. Final investigation reports will be forwarded to you at the earliest.

1. Name : SACHIN KHANDARE
2. Age : 35Yrs.
3. Sex : MALE
4. Physical Examination : Normal
5. Systemic Examination : Normal
6. Ophthalmic Examination: Normal
- 7 Vision /Colour Vision : I) Normal - Normal
- ii) Colour Blindness : Normal
- 8 ECG : Normal
- 9 X RAY CHEST : Normal
- 10 USG : Normal
- 11 2D ECHO : Normal

Remark- Person is fit to work in Company

  
DR. SACHIN BANGAR  
MD, MNB (MEDI.)  
Reg. No. 08/08/3045  
Dr. SACHIN BANGAR  
Medical officer



# LIFE LINE

## Multispeciality Hospital Maternity Home & ICU

Plot No. 20, Gut No. 103, Opp. Surya Lawns Beed Bypass, Devlai, Chh. Sambhajinagar. Mob.: 9067028989, 9067038989

Rx

NAME: SACHIN KHANDARE  
AGE/ SEX: 35/MALE

DATE: 29/03/2024

### PRE-EMPLOYMENT HEALTH CHECKUP 2024

**HISTORY** :- Nil

**ADDICATION:** - Nil

### GENERAL MEDICAL EXAMINATION

#### 1. Physical Examination

Height	: 170Cms	Skin Examination- Any diseases- :-No
Weight	: 88 Kg	Oral Examination Hygiene- Any diseases- :-No
Pulse	: 85 Min	ENT Examination- Any diseases- :-No
B.P.	: 120/70mmHg	

#### 2. SYSTEMIC EXMINATION

a) Abdomen :- Soft, No Organomegaly  
b) CVS :- Normal Heart sound  
c) Respiratory System :- Normal Air Entry Both Lungs  
d) Nervous System :- Normal Clinically

### INVESTIGATIONS (POSITIVE FINDING)

Pathological investigation :- (Reports Enclosed) Annexure  
Vision :- (Reports Enclosed) Annexure  
Color Vision :- (Reports Enclosed) Annexure  
E C G :- (Reports Enclosed) Annexure  
X-Ray Chest :- (Reports Enclosed) Annexure  
USG :- (Reports Enclosed) Annexure  
2D ECHO :- (Reports Enclosed) Annexure

Fit for employment

**DR. SACHIN BANGAR**  
MB, DNB (MEDI.)  
Medical Examiner  
110-27-038989



# LIFE LINE

## Multispeciality Hospital Maternity Home & ICU

Plot No. 20, Gut No. 103, Opp. Surya Lawns Beed Bypass, Devlai, Chh. Sambhajinagar. Mob.: 9067028989, 9067038989

Rx

### OPHTHALMIC EXAMINATION

NAME OF EMPLOYEE: SACHIN KHANDARE

AGE: 35/MALE

DATE OF EXAMINATION: -29/03/2024

		RE (RIGHT EYE)	LE (LEFT EYE)
NEAR VISION	WITH GLASSES		
	WITH OUT GLASSES	N/6	N/6
DISTANCE VISION	WITH GLASSES		
	WITH OUT GLASSES	6/6	6/6

COLOUR VISION: - NORMAL

DR. SACHIN BANGAR  
M.B.B.S. MD, DNB (MEDI.)  
REG. NO. 02/38/3045



# LIFE LINE

## Multispeciality Hospital Maternity Home & ICU

Plot No. 20, Gut No. 103, Opp. Surya Lawns Beed Bypass, Devlai, Chh. Sambhajinagar. Mob.: 9067028989, 9067038989

Rx

Patient Name	SACHIN KHANDARE	Date: 29/03/2024
Age / Sex	35Yrs /M	Performed By: DR. VIVEK JAJU

### USG ABDOMEN AND PELVIS

**LIVER:** Liver is normal in size measuring 13.4cm & shows normal echo texture. No evidence of any diffuse or focal pathology. Intrahepatic biliary radicals are not dilated. Portal vein & CBD are normal in diameter.

**GALL BLADDER:** is well-distended. No evidence of calculus or mass. Gall bladder wall thickness is normal.

**PANCREAS:** is normal in size and echo texture. Pancreatic duct is not dilated.

**SPLEEN:** Spleen is normal in size measuring 9.1cm & shows normal echo texture. No evidence of any focal lesion.

#### **KIDNEYS:**

Right Kidney measures 9.2 x 4.4 cm in size.

Left Kidney measures 9.5 x 5.4 cm in size.

Both kidneys are normal in size and echo texture. Corticomedullary differentiation is normal. No evidence of calculus or hydronephrosis on both sides.

**Urinary Bladder** is Well-distended.

**Prostate** is normal in size and echo texture.

IVC and aorta are normal. No Para aortic lymphadenopathy.

No evidence of any intra- abdominal or pelvic mass.

No e/o any free fluid in abdomen and pelvis.

High resolution USG was performed with high frequency linear transducer, which reveals normal bowel loops and mesenteric structures. No evidence of significant mesenteric lymphadenopathy.

#### **IMPRESSION:**

**No significant abnormality detected.**



Reg No.: 659/25/01/2021

# LIFE LINE

## Multispeciality Hospital Maternity Home & ICU

Plot No. 20, Gut No. 103, Opp. Surya Lawns Beed Bypass, Devlai, Chh. Sambhajinagar. Mob.: 9067028989, 9067038989

Rx

NAME OF THE PATIENT: SACHIN KHANDARE

AGE: 35/MALE

DATE: -29/03/2024

**REPORT:**

Condition of Lung pleura: WNL

**Heart & Aorta:**

Transverse Diameter of Heart: WNL

Transverse Diameter of Aortic Arch: WNL


Cardio-Thoracic Ratio: WNL

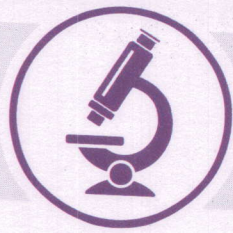Any changes of Arteriosclerosis or Calcification of Aorta etc.

WNL

**CONCLUSION & REMARK:**

X-RAY CHEST IS WITH IN NORMAL LIMITS.

  
DR. SACHIN BANGAR  
MD, DNB (MEDI.)  
Reg. No. 02/08/3045  
Medical Examiner



# Vaidyanath Diagnostics

PATHOLOGY LABORATORY

PATHOLOGY | X-RAY | SONOGRAPHY | 2-D ECHO | CTMT | PFT | AUDIOMETRY

Accession No : 2024032910

Patient Name : Mr. SACHIN KHANDARE

Age / Sex : 35 Year/Male

Referred by : LIFELINE MULTISPECIALITY HOSPITAL

Registered On : 29/03/2024

Reporting On : 29/03/2024

Printed On : 29/03/2024



Test Name	Patient value	Reference Range	Unit
SGPT	28		
ALKALINE PHOSPHATASE	96	06 - 40	mg/dl
TOTAL PROTINE	6.6	42 - 141	g/dL
ALBUMIN	3.8	6 - 8	g/dl
GLOBULIN	2.8	3.5 - 4.8	g/dl
		2.8 - 3.3	g/dL

## HEMATOLOGY

### COMPLETE BLOOD COUNTS

Hb	14.2	13.0 - 18.0	g/dL
RBC COUNT	4.96	4.50 - 5.50	10 <sup>6</sup> /uL
TLC	5200	4000 - 10000	10 <sup>3</sup> /uL

### RED CELL ABSOLUTE VALUES

HCT	38.9	35.0 - 60.0	%
MCV	78.43	83.0 - 101.0	f L
MCH	28.63	27.0 - 32.0	pg
MCHC	36.5	31.5 - 34.5	g/dL

### DLC (DIFFERENTIAL LEUKOCYTE COUNT)

NEUTROPHILS	55	40.0 - 80.0	%
LYMPHOCYTES	36	20.0 - 40.0	%
EOSINOPHILS	04	2.0 - 6.0	%
MONOCYTES	05	1.0 - 8.0	%
BASOPHILS	00	< 1.0	%

### PLATELET COUNT

PLATELET COUNT	196000	150000 - 450000	10 <sup>3</sup> /ul
E.S.R	10	1 - 20	MM/HRS

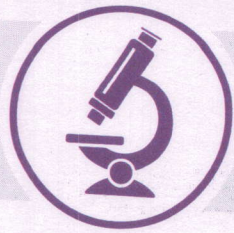## BIOCHEMISTRY

### Kidney Function Test

CREATININE	0.9	0.5 - 1.4	mg/dl
------------	-----	-----------	-------

Plot No.20, Gut No.103, Opp. Surya Lawns, Beed By Pass Road, Deolai, Aurangabad

24 HOURS EMERGENCY SERVICE ☎ Mob No. : 9067028989/9067038989



# Vaidyanath Diagnostics

PATHOLOGY LABORATORY

PATHOLOGY | X-RAY | SONOGRAPHY | 2-D ECHO | CTMT | PFT | AUDIOMETRY

Accession No : 2024032910

Patient Name : Mr. SACHIN KHANDARE

Age / Sex : 35 Year/Male

Referred by : LIFELINE MULTISPECIALITY HOSPITAL

Registered On : 29/03/2024

Reporting On : 29/03/2024


Printed On : 29/03/2024

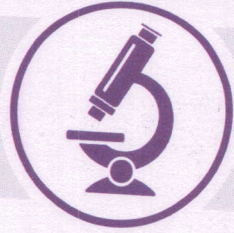

Test Name	Patient value	Reference Range	Unit
UREA	22	10 - 50	mg/dl
<b><u>ELECTROLYTE</u></b>			
<b><u>ELECTROLYTES</u></b>			
SODIUM	141	135 - 150	mMol/L
POTASSIUM	4.09	3.5 - 5.0	mMol/L
CHLORIDE	102	96 - 108	mmol/L

Kindly Correlate Clinically !  
Thanks for referral !

----- End of Report -----

  
DR. SANDIP AMBEKAR  
MBBS,DPB  
Reg.no 2001/02/0426



# Vaidyanath Diagnostics

PATHOLOGY LABORATORY

PATHOLOGY | X-RAY | SONOGRAPHY | 2-D ECHO | CTMT | PFT | AUDIOMETRY

Accession No : 2024032910

Patient Name : Mr. SACHIN KHANDARE

Age / Sex : 35 Year/Male

Referred by : LIFELINE MULTISPECIALITY HOSPITAL

Registered On : 29/03/2024

Reporting On : 29/03/2024

Printed On : 29/03/2024



Test Name	Patient value	Reference Range	Unit
-----------	---------------	-----------------	------

### Interpretation(s)

TSH stimulates the production and secretion of the metabolically active thyroid hormones, thyroxine (T4) and triiodothyronine (T3) by interacting with a specific receptor on the thyroid cell surface. The synthesis and secretion of TSH is stimulated by Thyrotropin releasing hormone (TRH), the hypothalamic tripeptid in response to low levels of circulating thyroid hormones. Elevated levels of T3 and T4 suppress the production of TSH via a classic negative feedback mechanism. Failure at any level of regulation of the hypothalamic-pituitary-thyroid axis will result in either underproduction (hypothyroidism) or overproduction (hyperthyroidism) of T4 and /or T3.

Clinical Condition T3 Levels T4 Levels TSH level

Primary hypothyroidism	Reduced	Reduced	Increased(Significantly)
Subclinical Hypothyroidism	Normal or Low	Normal	Normal or Low Normal High
Primary hyperthyroidism	Increased	Increased	Reduced( at times undetectable)
Subclinical Hyperthyroidism	Normal or High	Normal	Normal of High Normal Reduced

### Hba1c

#### GLYCOSYLATED HAEMOGLOBIN

Glycosylated Haemoglobin (HbA1c) 4.2

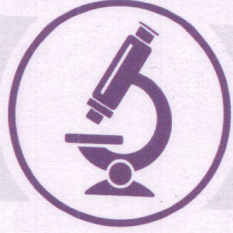Non-Diabetic : Upto 6%, %  
 Pre- Diabetic :6.0-6.5%,  
 Diabetic :>6.5%,  
 Good Control : 6.5-7.0%,  
 Moderate Control: 7-8%,  
 Poor Control:>8.0%

### BIOCHEMISTRY

#### LIVER FUNCTION TEST

BILIRUBIN TOTAL	0.8	0.1 - 1.2	mg/dl
DIRECT	0.2	0.0 - 0.3	mg/dl
INDIRECT	0.6	0.1 - 1.0	mg/dl
SGOT	36	10 - 40	mg/dl





# Vaidyanath Diagnostics

PATHOLOGY LABORATORY

PATHOLOGY | X-RAY | SONOGRAPHY | 2-D ECHO | CTMT | PFT | AUDIOMETRY

Accession No : 2024032910

Patient Name : Mr. SACHIN KHANDARE

Age / Sex : 35 Year/Male

Referred by : LIFELINE MULTISPECIALITY HOSPITAL

Registered On : 29/03/2024

Reporting On : 29/03/2024

Printed On : 29/03/2024



Test Name	Patient value	Reference Range	Unit
-----------	---------------	-----------------	------

## BIOCHEMISTRY

### LIPID PROFILE

S. Cholesterol	174	0 - 200	mg/dl
S. Triglycerides	122	25 - 160	mg/dl
HDL Cholesterol	34.8	30 - 60	md/dl
LDL Cholestrol	114.8	85 - 150	mg/dL

## HEMATOLOGY

### BLOOD GROUP

BLOOD GROUP "O" RH POSITIVE

Note : Grouping & Cross matching is absolutely essential prior to blood transfusion patient identity as disclosed by patients himself/herself.

## BIOCHEMISTRY

### BLOOD SUGAR

BLOOD SUGAR (FASTING)	96	70 - 110	mg/dl
BLOOD SUGAR (Post Meal )	111	70 - 140	mg/dl

### URINE SUGAR

URINE SUGAR ( Fasting )	SNR		NIL
URINE SUGAR ( Post Meal )	SNR		NIL

## URINE ROUTINE

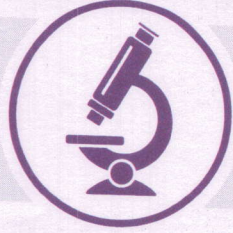### URINE ROUTINE EXAMINATION

### PHYSICAL EXAMINATIN

VOLUME	5 ML	( NORMAL : 2 TO 6 )
COLOUR	PALE YELLOW	
APPERANCE	CLEAR	

Plot No.20, Gut No.103, Opp. Surya Lawns, Beed By Pass Road, Deolai, Aurangabad

24 HOURS EMERGENCY SERVICE ☎ Mob No. : 9067028989/9067038989



# Vaidyanath Diagnostics

PATHOLOGY LABORATORY

PATHOLOGY | X-RAY | SONOGRAPHY | 2-D ECHO | CTMT | PFT | AUDIOMETRY

Accession No : 2024032910

Patient Name : Mr. SACHIN KHANDARE

Age / Sex : 35 Year/Male

Referred by : LIFELINE MULTISPECIALITY HOSPITAL

Registered On : 29/03/2024

Reporting On : 29/03/2024

Printed On : 29/03/2024



Test Name	Patient value	Reference Range	Unit
<b>CHEMICAL EXAMINATION</b>			
PROTEIN	NIL	NOT DETECTED	
GLUCOSE	NIL	NOT DETECTED	
<b>MICROSCPIC EXAMINATION</b>			
EPITHELIAL CELLS	1-2		/hpf
PUS CELL / LEUCOCYTES	2-4		/hpf/Leu/UL
RED BLOOD CELLS/BLD	ABSENT	NIL	/hpf/Ery/UL
CASTS	NOT DETECTED	NOT DETECTED	
CRYSTALS	NOT DETECTED	NOT DETECTED	
BACTERIA	NOT DETECTED	NOT DETECTED	
<b>T3 T4 TSH</b>			
<b>THYROID PROFILE</b>			
T3	98.0	87 - 178	ng/dL
T4	8.12	6.09 - 12.2	µg/dL
TSH	1.26	0.38 - 5.33	µIU/mL

Package name	Package Inculsions	Customer Name
ARCOFEMI - MEDIWHEEL - FULL BODY ANNUAL PLUS MALE - 2D ECHO - PAN INDIA - FY2324	Dietician consultation,Lipid Profile (all Parameters),Renal Function Test,Ultrasound - Whole Abdomen,Package Consultation - ENT,2 D ECHO,Consultation - Dental,Blood Grouping And Typing (Abo And Rh),ECG,Fitness by General Physician,URINE GLUCOSE(POST PRANDIAL),Urine Routine (CUE),GGTP: Gamma Glutamyl Transpeptidase - Serum,GLUCOSE - SERUM / PLASMA(FASTING AND POST PRANDIAL,THYROID PROFILE - I(T3,T4 AND TSH),Glycosylated Hemoglobin (HbA1C) - Whole Blood,LIVER FUNCTION TEST (PACKAGE),X-Ray Chest PA,HEMOGRAM (CBC+ESR),Ophthal by General Physician,URINE GLUCOSE(FASTING),BMI,GLUCOSE, POST PRANDIAL (PP), 2 HOURS (POST MEAL),GLUCOSE, FASTING,RENAL PROFILE/RENAL FUNCTION TEST (RFT/KFT),COMPLETE URINE EXAMINATION,LIVER FUNCTION TEST (LFT),Doctor,DIET CONSULTATION,THYROID PROFILE (TOTAL T3, TOTAL T4, TSH),PERIPHERAL SMEAR,HEMOGRAM + PERIPHERAL SMEAR,BLOOD GROUP ABO AND RH FACTOR,GAMMA GLUTAMYL TRANFERASE (GGT),HbA1c, GLYCATED HEMOGLOBIN,LIPID PROFILE,BODY MASS INDEX (BMI)	MR. KHANDARE SACHIN AMBADAS



सत्यमेव जयते  
भारत सरकार



आधार

भारतीय विशिष्ट ओळख प्राधिकरण

भारत सरकार  
Unique Identification Authority of India  
Government of India

नोंदविण्याचा क्रमांक / Enrollment No.: 2006/31625/01267

To  
सचिन अंबादासजी खंडारे  
Sachin Ambadasji Khandare  
S/O Ambadasji Khandare  
QT NO.B/12 POWER GRID COMPLEX SAMPRITI  
NAGAR  
Uppalwadi S.O  
Uppalwadi  
Nagpur  
Maharashtra 440026  
8793777992

27/10/2011

86489500



MD864895003FH



आपला आधार क्रमांक / Your Aadhaar No. :

**5830 8397 8171**

माझे आधार, माझी ओळख



भारत सरकार

Government of India



सचिन अंबादासजी खंडारे  
Sachin Ambadasji Khandare  
वडील : अंबादासजी खंडारे  
Father : AMBADASJI KHANDARE  
जन्म तारीख / DOB : 21/10/1989  
पुरुष / Male



**5830 8397 8171**

माझे आधार, माझी ओळख

Health Check up Booking Confirmed Request(bobE18505),Package Code-  
PKG10000474, Beneficiary Code-312159

Mediwheel <wellness@mediwheel.in>

Thu 28-03-2024 15:05

To:Sachin Ambadas Khandare <SACHIN.KHANDARE@bankofbaroda.com>

Cc:customercare@mediwheel.in <customercare@mediwheel.in>

वधान: यह मेल बैंक डोमेन के बाहर से आया है. अगर आप प्रेषक को नहीं जानते तो मेल में ;  
CAUTION: THIS MAIL IS ORIGINATED FROM OUTSIDE OF THE BANK'S DOMAIN

011-41195959

Dear MR. KHANDARE SACHIN AMBADAS,

We are pleased to confirm your health checkup booking request with the following details.

**Hospital Package Name** : Mediwheel Full Body Health Checkup Male Below 40  
**Patient Package Name** : Mediwheel Full Body Health Checkup Male Below 40  
**Name of Diagnostic/Hospital** : Life Line Multispeciality Hospital  
**Address of Diagnostic/Hospital** : Opposite Surya Lawns, Beed Bypass Rd, Near Oyo 15017 Hotel Nandini, Deolai, Aurangabad - 431007  
**City** : Aurangabad  
**State** : Maharashtra  
**Pincode** : 431007  
**Appointment Date** : 29-03-2024  
**Confirmation Status** : Booking Confirmed  
**Preferred Time** : 09:00:AM  
**Booking Status** : Booking Confirmed

**Member Information**

Booked Member Name	Age	Gender
MR. KHANDARE SACHIN AMBADAS	34 year	Male

Note - Please note to not pay any amount at the center.

Instructions to undergo Health Check:

- Please ensure you are on complete fasting for 10-To-12-Hours prior to check.
- During fasting time do not take any kind of medication, alcohol, cigarettes, tobacco or any other liquids (except Water) in the morning.

NAME: SACHIN KHANDARE

AGE: 35YRS/M

DATE: 30/03/2024

## 2D ECHO DOPPLER REPORT

Patient in tachycardia during study

La Ra Normal in Size and shape.

LV is normal in size and shape.

Good LV Systolic function.

LVEF > 55%

NO DIASTOLIC DYSFUNCTION.


NO regional wall motion abnormality

No intra cardiac shunts vegetation.

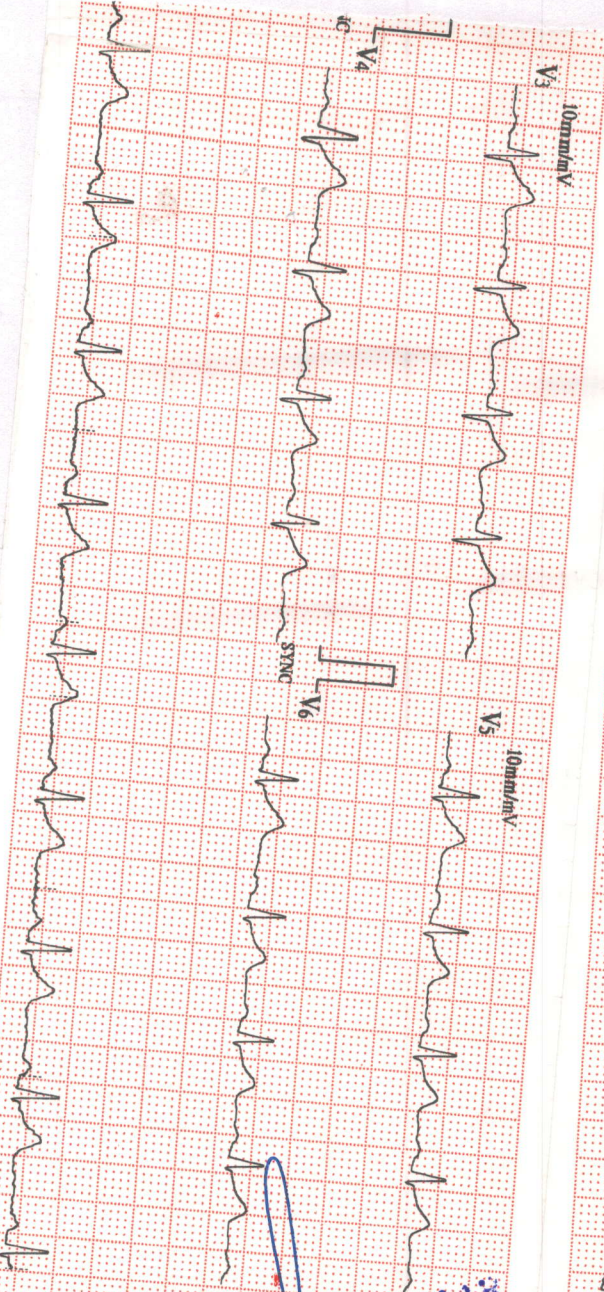
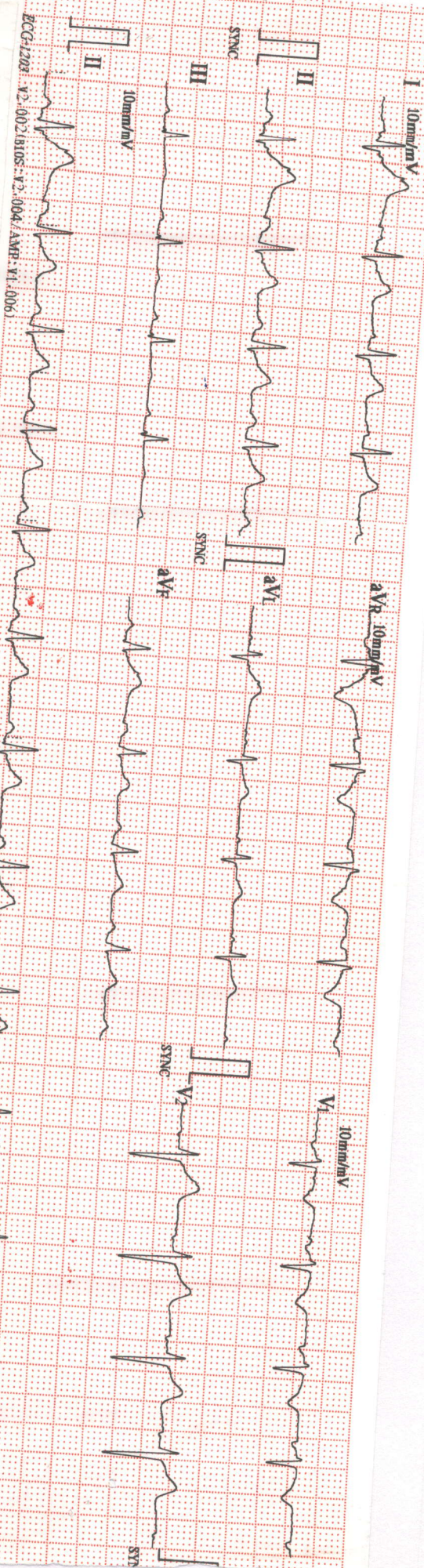
No MR/TR/AR

NO PERICARDIAL EFFUSION.

**IMPRESSION: ESSENTIALLY NORMAL 2D ECHO DOPPLER STUDY**

  
**DR. SACHIN BANGAR**  
MBBS MD, DNB (MEDI.)  
No. 02/08/3045  
(SIGNATURE)

25mm/s 0.5-25Hz



09/11/2024 20:55  
3003

**R. SACHINBANGAR**  
**MD, DNB (MED.)**  
 Reg. No. 02/08/3045

HR: 78  
 PR: 165  
 P-R: 165  
 QRS: 9  
 QT/QTc: 349/398  
 P-A/HS/T: 55/67/36  
 HV5/SV1: 0.520/0.500 mV  
 HV5-SV1: 1.020

Sinus Rhythm  
 Inspeci find ST-T Abnormality

*Sachin Handave*  
*Ambar Das*  
 \*Natch Interpretation Only  
 Consult with Physician  
 Date: 29/08/2024  
 Physician: B. Das