

Patient Name	: Mrs. V KAVITHA	Age	: 38 Y/F
UHID	: CKOR.0000252975	OP Visit No	: CKOROPV405300
Conducted By:	: Dr. MOHAN MURALI	Conducted Date	: 09-04-2024 15:51
Referred By	: SELF		

Original OP Credit Bill

Name : Mrs. V KAVITHA
Age/Gender : 38 Y F
Contact No : +919986840407
Address : kmg
UHID : CKOR.0000252975

Bill No : CKOR-OCR-81845
Bill/Reg Date : 29.03.2024 08:34
Referred by : SELF
Center : Koramangala
Emp No/Auth Code : bobE18691



CKOR.0000252975

Corporate Name : ARCOFEMI HEALTHCARE LIMITED
Plan : ARCOFEMI MEDIWHEEL FEMALE AHC CREDIT PAN INDIA OP AGREEMENT

#	Department	Service Name	Qty	Rate	Discount	Amount
1	Package Charges	ARCOFEMI - MEDIWHEEL - FULL BODY HEALTH ANNUAL PLUS CHECK - FEMALE - 2D ECHO - PAN INDIA - FY2324	1	2,400.00	0.00	2,400.00

Bill Amount: 2,400.00
Total Discount: 0.00
Net Payment: 0.00
Corporate Due: 2,400.00

Received with thanks: Zero Rupees only

Authorized Signature :(Tejaswini M)



ಭಾರತ ಚುನಾವಣಾ ಆಯೋಗ
ಸುರುಕ್ಷಿತ ಚೀಟಿ

ELECTION COMMISSION OF INDIA
IDENTITY CARD

ZUI0124743



ಮತದಾರ ಹೆಸರು : ಕವಿತಾ ವಿ.

Elector's Name : Kavitha V.

ಪಿತೃ ಹೆಸರು : ವಿಜಯಕುಮಾರ್

Father's Name : Vijayakumar

ಲಿಂಗ / Sex : ಸ್ತ್ರೀ / F

ಜನ್ಮ ದಿನಾಂಕ /Date of Birth: 02/11/1985

प्रति,

समन्वयक,
Mediwheel (Arcofemi Healthcare Limited)
हेल्पलाइन नंबर: 011-41195959

महोदय/ महोदया,

विषय: बैंक ऑफ़ बड़ौदा के कर्मचारियों के लिए वार्षिक स्वास्थ्य जांच।

हम आपको सूचित करना चाहते हैं कि हमारे कर्मचारी जिनका विवरण निम्नानुसार है हमारे करार के अनुसार आपके द्वारा उपलब्ध कराई गई कैशलेस वार्षिक स्वास्थ्य जांच सुविधा का लाभ लेना चाहते हैं।

	कर्मचारी विवरण
नाम	MS. V KAVITHA
क.कू.संख्या	160835
पदनाम	REGIONAL MERCHANT MANAGER
कार्य का स्थान	BENGALURU,RO BENGALURU CENTRAL
जन्म की तारीख	02-11-1985
स्वास्थ्य जांच की प्रस्तावित तारीख	29-03-2024
बुकिंग संदर्भ सं.	23M160835100105520E

यह अनुमोदन/ संस्तुति पत्र तभी वैध माना जाएगा जब इसे बैंक ऑफ़ बड़ौदा के कर्मचारी आईडी कार्ड की प्रति के साथ प्रस्तुत किया जाएगा। यह अनुमोदन पत्र दिनांक **25-03-2024** से **31-03-2024** तक मान्य है। इस पत्र के साथ किए जाने वाले चिकित्सा जांच की सूची अनुलग्नक के रूप में दी गई है। कृपया नोट करें कि उक्त स्वास्थ्य जांच हमारी टाई-अप व्यवस्था के अनुसार कैशलेस सुविधा है। हम अनुरोध करते हैं कि आप हमारे कर्मचारी के स्वास्थ्य जांच संबंधी आवश्यकताओं पर उचित कार्रवाई करें तथा इस संबंध में अपनी सर्वोच्च प्राथमिकता तथा सर्वोत्तम संसाधन उपलब्ध कराएं। उपर्युक्त सारणी में दी गई कर्मचारी कूट संख्या एवं बुकिंग संदर्भ संख्या का उल्लेख अनिवार्य रूप से इनवॉइस में किया जाना चाहिए।

हम इस संबंध में आपके सहयोग की अपेक्षा करते हैं।

भवदीय,

हस्ता/-

(मुख्य महाप्रबंधक)

मानव संसाधन प्रबंधन विभाग

बैंक ऑफ़ बड़ौदा

(नोट: यह कंप्यूटर द्वारा जनरेट किया गया पत्र है। हस्ताक्षर की आवश्यकता नहीं है। कृपया किसी भी स्पष्टीकरण के लिए Mediwheel (Arcofemi Healthcare Limited) से संपर्क करें।)

SUGGESTIVE LIST OF MEDICAL TESTS

FOR MALE	FOR FEMALE
CBC	CBC
ESR	ESR
Blood Group & RH Factor	Blood Group & RH Factor
Blood and Urine Sugar Fasting	Blood and Urine Sugar Fasting
Blood and Urine Sugar PP	Blood and Urine Sugar PP
Stool Routine	Stool Routine
Lipid Profile	Lipid Profile
Total Cholesterol	Total Cholesterol
HDL	HDL
LDL	LDL
VLDL	VLDL
Triglycerides	Triglycerides
HDL / LDL ratio	HDL / LDL ratio
Liver Profile	Liver Profile
AST	AST
ALT	ALT
GGT	GGT
Bilirubin (total, direct, indirect)	Bilirubin (total, direct, indirect)
ALP	ALP
Proteins (T, Albumin, Globulin)	Proteins (T, Albumin, Globulin)
Kidney Profile	Kidney Profile
Serum creatinine	Serum creatinine
Blood Urea Nitrogen	Blood Urea Nitrogen
Uric Acid	Uric Acid
HBA1C	HBA1C
Routine urine analysis	Routine urine analysis
USG Whole Abdomen	USG Whole Abdomen
General Tests	General Tests
X Ray Chest	X Ray Chest
ECG	ECG
2D/3D ECHO / TMT	2D/3D ECHO / TMT
Stress Test	Thyroid Profile (T3, T4, TSH)
PSA Male (above 40 years)	Mammography (above 40 years) and Pap Smear (above 30 years).
Thyroid Profile (T3, T4, TSH)	Dental Check-up consultation
Dental Check-up consultation	Physician Consultation
Physician Consultation	Eye Check-up consultation
Eye Check-up consultation	Skin/ENT consultation
Skin/ENT consultation	Gynaec Consultation

Name : Mrs. V KAVITHA

Age: 38 Y

UHID:CKOR.0000252975

Sex: F



Address : kmg

OP Number:CKOROPV405300

 Plan : ARCOFEMI MEDIWHEEL FEMALE AHC CREDIT PAN
 INDIA OP AGREEMENT

Bill No :CKOR-OCR-81845

Date : 29.03.2024 08:34

Sno	Service Type/ServiceName	Department
1	ARCOFEMI - MEDIWHEEL - FULL BODY HEALTH ANNUAL PLUS CHECK - FEMALE - 2D ECHO - PAN INDIA - FY2324	
✓1	GAMMA GLUTAMYL TRANSFERASE (GGT)	
2	D ECHO <i>Trms</i> - R.10	
✓3	LIVER FUNCTION TEST (LFT)	
✓4	GLUCOSE, FASTING	
✓5	HEMOGRAM + PERIPHERAL SMEAR	
✓6	GYNAECOLOGY CONSULTATION <i>u</i> - 10.45 ground floor	
7	DIET CONSULTATION	
✓8	COMPLETE URINE EXAMINATION	
9	URINE GLUCOSE(POST PRANDIAL)	
✓10	PERIPHERAL SMEAR	
✓11	EKG <i>A</i>	
✓12	LBC PAP TEST- PAPSURE <i>u</i> -	
✓13	RENAL PROFILE/RENAL FUNCTION TEST (RFT/KFT)	
14	DENTAL CONSULTATION	
✓15	GLUCOSE, POST PRANDIAL (PP), 2 HOURS (POST MEAL)	
✓16	URINE GLUCOSE(FASTING)	
✓17	HbA1c, GLYCATED HEMOGLOBIN	
✓18	X-RAY CHEST PA	
19	ENT CONSULTATION <i>Dr. Nijam</i> - R. 23.11.30	
20	FITNESS BY GENERAL PHYSICIAN	
✓21	BLOOD GROUP ABO AND RH FACTOR	
✓22	LIPID PROFILE	
23	BODY MASS INDEX (BMI)	
✓24	OPHTHAL BY GENERAL PHYSICIAN	
✓25	ULTRASOUND - WHOLE ABDOMEN	
✓26	THYROID PROFILE (TOTAL T3, TOTAL T4, TSH)	

I - Dental - 15
 II - Physio - 17
 Opthal
 Advio - 19 (N)

Ht - 152 cm
 Wt - 74.5 kg
 Bp - 129/83 mmHg
 pulse - 98/mt

BP - 10:30
 PP - 12:00



DR VIJAYA LAKSHMI M
M.B.B.S, D.L.O, D.N.B(ENT)
Phone No.9972044580,080-25633823/24/23

29/03/24

HEALTH CHECK- ENT

NAME: *V. Kavitha* **P** **AGE:** *38*

EAR: **RE:** **LE:**

EXTERNAL EAR

MIDDLE EAR

INNER EAR (FN)

} Normal

HEARING ASSESSMENT: **RE:** **LE:**

RHINNE

WEBER

ABC

} Normal

NOSE

AIRWAY

SEPTUM

TURBINATES

OTHERS

NECK

NECK NODES

OTHER

} Normal

AUDIOMETRY

IMPRESSION

Normal

THROAT

ORAL CAVITY

OROPHARYNX

PHARYNX

LARYNX

} Normal

[Signature]
SIGNATURE:

Patient Name : Mrs.V Kavitha Patient ID :252975
Age : 38Year(s) Sex : Female
Referring Doctor : H/C Date : 29.03.2024

ULTRASOUND ABDOMEN AND PELVIS

Liver is normal in size and shows normal echo pattern. No biliary dilatation .No focal lesion

Portal vein is normal in size, course and caliber. CBD is not dilated.

Gall bladder is normal without evidence of calculi, wall thickening or pericholecystic fluid

Pancreas to the extent visualized, appears normal in size, contour and echogenicity

Spleen is normal in size, shape, contour and echopattern. No evidence of mass or focal lesion.

Right kidney is normal in size, position, shape and echopattern. Corticomedullary differentiation is maintained. No evidence of calculi or hydronephrosis.

Left kidney is normal in size, position, shape and echopattern.corticomedullary differentiation is maintained. No evidence of calculi or hydronephrosis.

Urinary Bladder is well distended. wall thickness is normal. No internal echoes.

Uterus: measures 7.4x 4.6 x 3.3cm and there is a 2.3 x 2.4 cms fundal fibroid. Endometrial echoes are normal

Endometrium: measures 3mm.

Both ovaries normal in size and echopattern,

Both adnexa: Normal, no mass seen.

There is no ascites.

IMPRESSION: FIBROID UTERUS

DR VINOD JOSEPH DNB,DMRD
RADIOLOGIST

OPHTHAL REPORT

NAME: V. Kavitha

AGE: 38 GENDER: MALE/FEMALE ✓

RIGHT EYE

	SPH	CYL	AXIS	VA
DV		Plano		6/6
NV	—————			NS

LEFT EYE

	SPH	CYL	AXIS	VA
DV		Plano		6/6
NV	—————			NS

REMARK: blue black lens

DATE: 29/03/24

Optometrist
OPTOMETRIST

BRING THIS PRESCRIPTION IN YOUR NEXT VISIT

etc

Date : 29/3/24
MR No :
Name : *M. Kavitha*
Age/Gender : 38yo
Mobile no :

Department : OBSTETRICS & GYNAECOLOGY
Consultant : DR JYOTHI RAJESH
REG NO; KMC-42823
Qualification : DGO, (DNB)
Consulting Timings: 9.30am TO 12.00PM
phone no: 9972044580, 7338064558

Height :	Weight :	BMI :	Waist Circum :
Temp :	Pulse :	Resp :	B.P :

General Examination / Allergies
History

Clinical Diagnosis & Management Plan

scanty flow during periods - 6-8 days
mm. mnc. regular c/m 17B
OBV: P₂ F120 W-940 BAI done
Post 4-1112 on dp
Family H. mntn - 1112
Old P/A - 50%
P/S - Gp
vapna 1 ⊖ WBC tabes
plu - 06 bulley

Follow up date: *29/03/24*

[Signature]
Doctor Signature

Patient Name	: Mrs. V KAVITHA	Age	: 38 Y F
UHID	: CKOR.0000252975	OP Visit No	: CKOROPV405300
Reported on	: 29-03-2024 13:28	Printed on	: 29-03-2024 13:41
Adm/Consult Doctor	:	Ref Doctor	: SELF

DEPARTMENT OF RADIOLOGY

X-RAY CHEST PA

Both lungs fields appear normal.

Both hila are normal.

Both costophrenic and cardiophrenic angles are normal.


The cardiac mediastinal shadows appear normal.

Bones and soft tissues appear normal.

IMPRESSION : NORMAL STUDY.

Printed on:29-03-2024 13:28

---End of the Report---

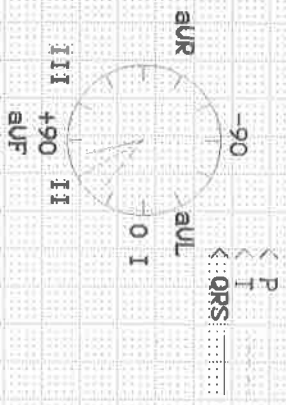

Dr. VINOD P JOSEPH
MBBS, DNB, DMRD
Radiology

Female

AGE: 38

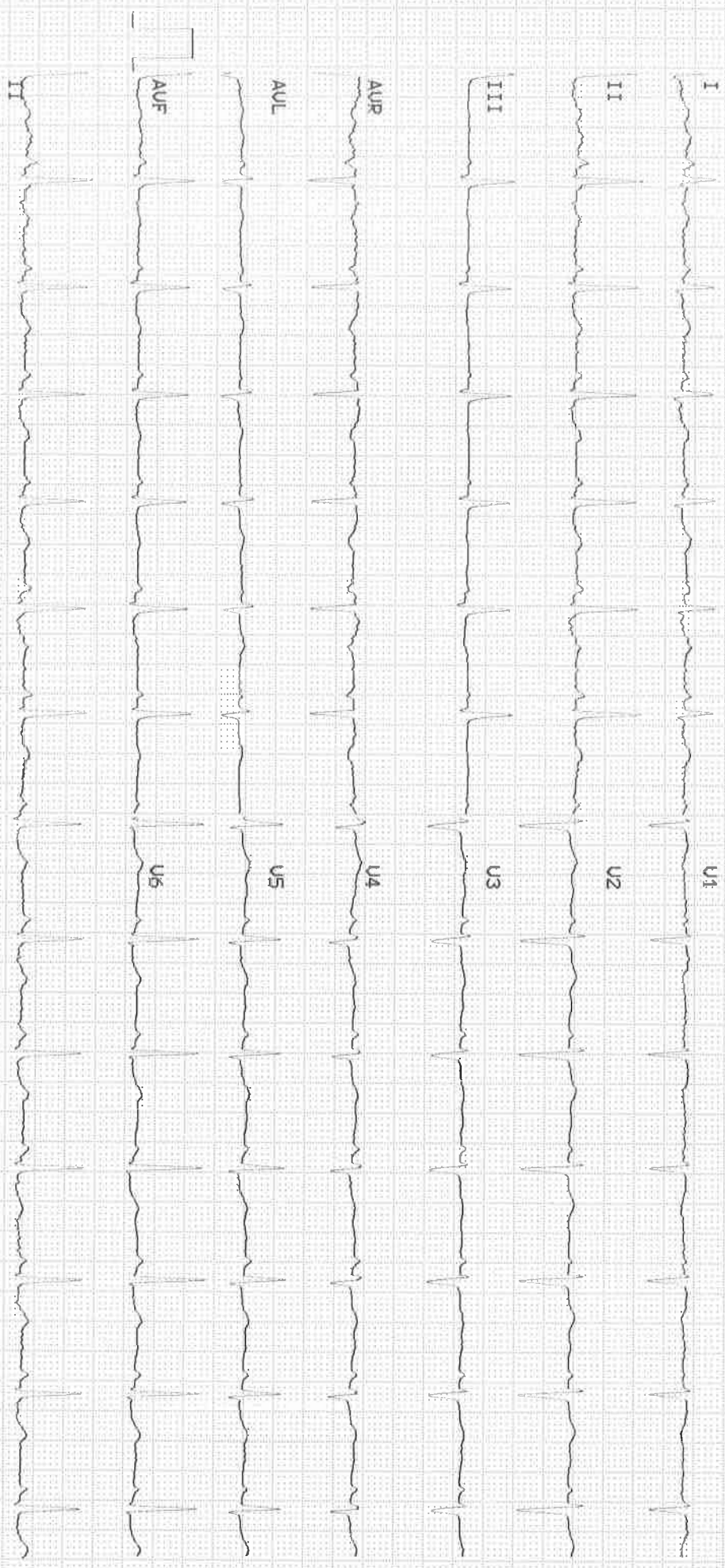
Measurement Results:

PPS	96	ms
QT/QTcB	396 /	460 ms
PR	122	ms
P	98	ms
RR/PP	740 /	750 ms
P/QRS/T	60 / 75 /	40 degrees
QTd/QTcBd	58 /	67 ms
Sokolow	1.6	mV
NK	11	



QSR

Unconfirmed Report.





Patient Name	: Mrs. V KAVITHA	Age	: 38 Y/F
UHID	: CKOR.0000252975	OP Visit No	: CKOROPV405300
Reported By:	: Dr. MOHAN MURALI	Conducted Date	: 29-03-2024 11:56
Referred By	: SELF		

ECG REPORT

Observation :-

1. Normal Sinus Rhythm.
2. Heart rate is 80beats per minutes.
3. No pathological Q wave or S-T,T changes seen.
4. Normal P,Q,R,S,T waves and axis.
5. No evidence of chamber, hypertrophy or enlargement seen.

Impression:

NORMAL RESTING ECG.

Dr MOHAN MURALI
CARDIOLOGIST

NOTE:KINDLY TAKE A PHOTOCOPY OF THE GRAPH
FOR FUTURE REFERENCE IF NEEDED.

----- END OF THE REPORT -----

APOLLO MEDICAL CENTRE
KORAMANGALA
BANGALORE

Station
Telephone:

EXERCISE STRESS TEST REPORT

Patient Name: MRS, V KAVITHA
Patient ID: 252975
Height: 152 cm
Weight: 74.5 kg

DOB: 02.11.1985
Age: 38 yrs
Gender: Female
Race: Asian

Study Date: 29.03.2024
Test Type: --
Protocol: BRUCE
Medications:
TAB TAZLOC 40

Referring Physician: --
Attending Physician: --
Technician: AKHILA

Medical History:
NIL

Reason for Exercise Test:

--

Exercise Test Summary

Phase Name	Stage Name	Time in Stage	Speed [mph]	Grade [%]	HR [bpm]	BP [mmHg]	Comment
PRETEST	SUPINE	03:23	0.00	0.00	102	130/80	
	STANDING	00:03	0.00	0.00	102	130/80	
	HYPERV.	00:04	0.00	0.00	104	130/80	
	WARM-UP	00:08	0.00	0.00	109	130/80	
EXERCISE	STAGE 1	03:00	1.70	10.00	148	140/80	
	STAGE 2	02:09	2.50	12.00	164	150/80	
	STAGE 3	03:00	3.40	14.00	196	160/80	
	STAGE 4	00:03	4.00	14.40	196		
RECOVERY		03:41	0.00	0.00	127	160/90	2:45 No symptoms

The patient exercised according to the BRUCE for 8:12 min:s, achieving a work level of Max. METS: 10.20. The resting heart rate of 111 bpm rose to a maximal heart rate of 200 bpm. This value represents 109 % of the maximal, age-predicted heart rate. The resting blood pressure of 130/80 mmHg, rose to a maximum blood pressure of 170/80 mmHg. The exercise test was stopped due to Target heart rate achieved.

Interpretation

Summary: Resting ECG: normal.

Functional Capacity: normal.

HR Response to Exercise: appropriate.

BP Response to Exercise: NORMAL HR AND BP RESPONSE.

Chest Pain: none.

Arrhythmias: NO ANGINA OR ARRHYTHMIA.

ST Changes: SIGNIFICANT ST DEPRESSION DURING EXC AND REC.

Overall impression: GOOD EFFORT TOLERANCE.

Conclusions

STRESS TEST POSITIVE FOR INDUCIBLE ISCHEMIA

Physician _____

Technician _____

MRS, V KAVITHA

Patient ID: 252975

29.03.2024 Female 152 cm 74.5 kg

11:22:47am 38 yrs Asian

Exercise Test / Linked Medians

PRETEST

SUPINE

03:21

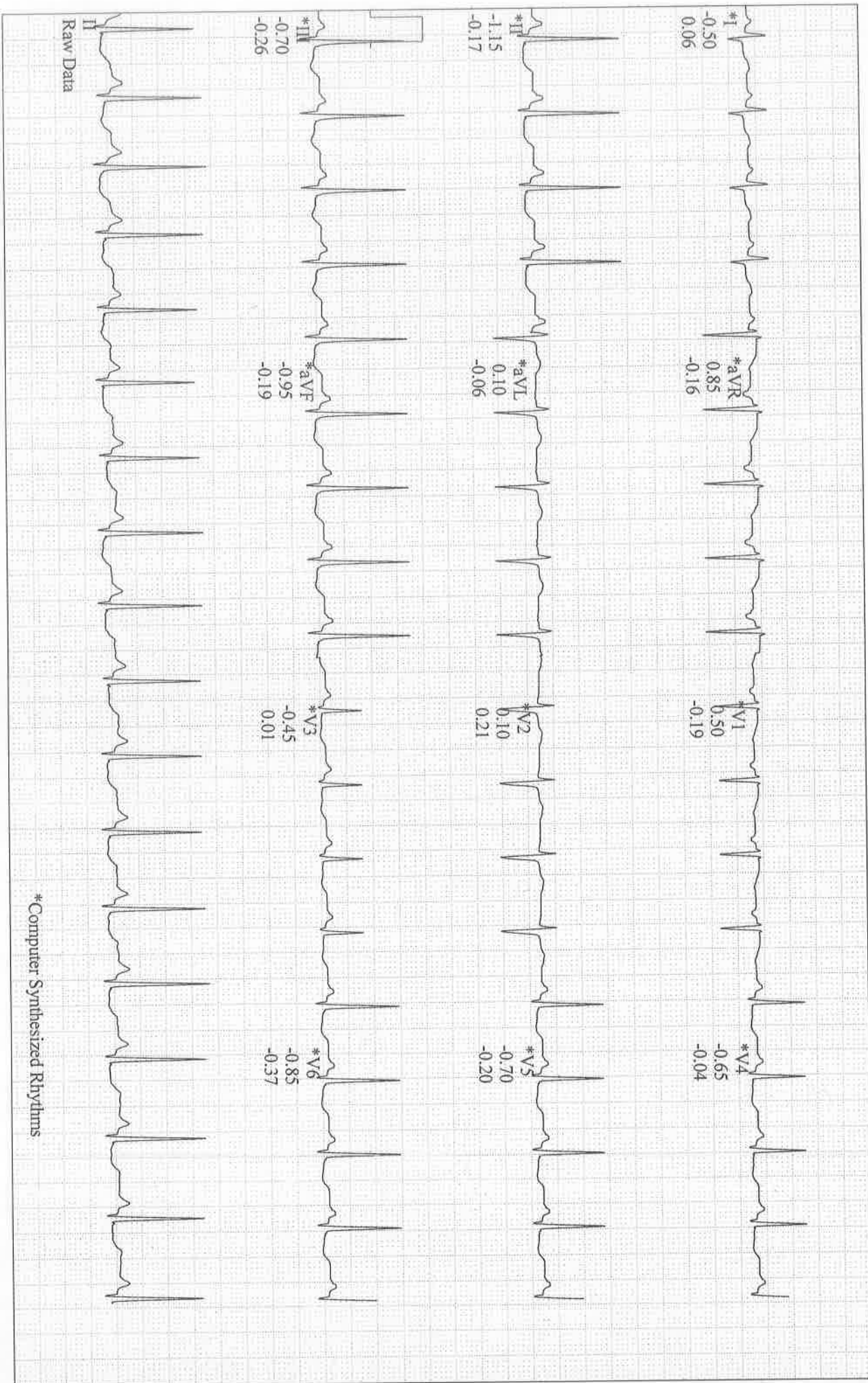
BRUCE

0.0 mph

0.0%

APOLLO MEDICAL CENTRE

Lead
ST Level (mm)
ST Slope (mV/s)



GE CardioSoft V7.0 (10)
25 mm/s 10 mm/mV 50 Hz 0.05Hz FRF+ HR(V1,V5)

Start of Test: 11:19:25am

MRS, V KAVITHA

Patient ID: 252975

29.03.2024 Female 152 cm 74.5 kg

11:25:53am 38 yrs Asian

Exercise Test / Linked Medians

EXERCISE

STAGE 1

02:50

148 bpm
140/80 mmHg

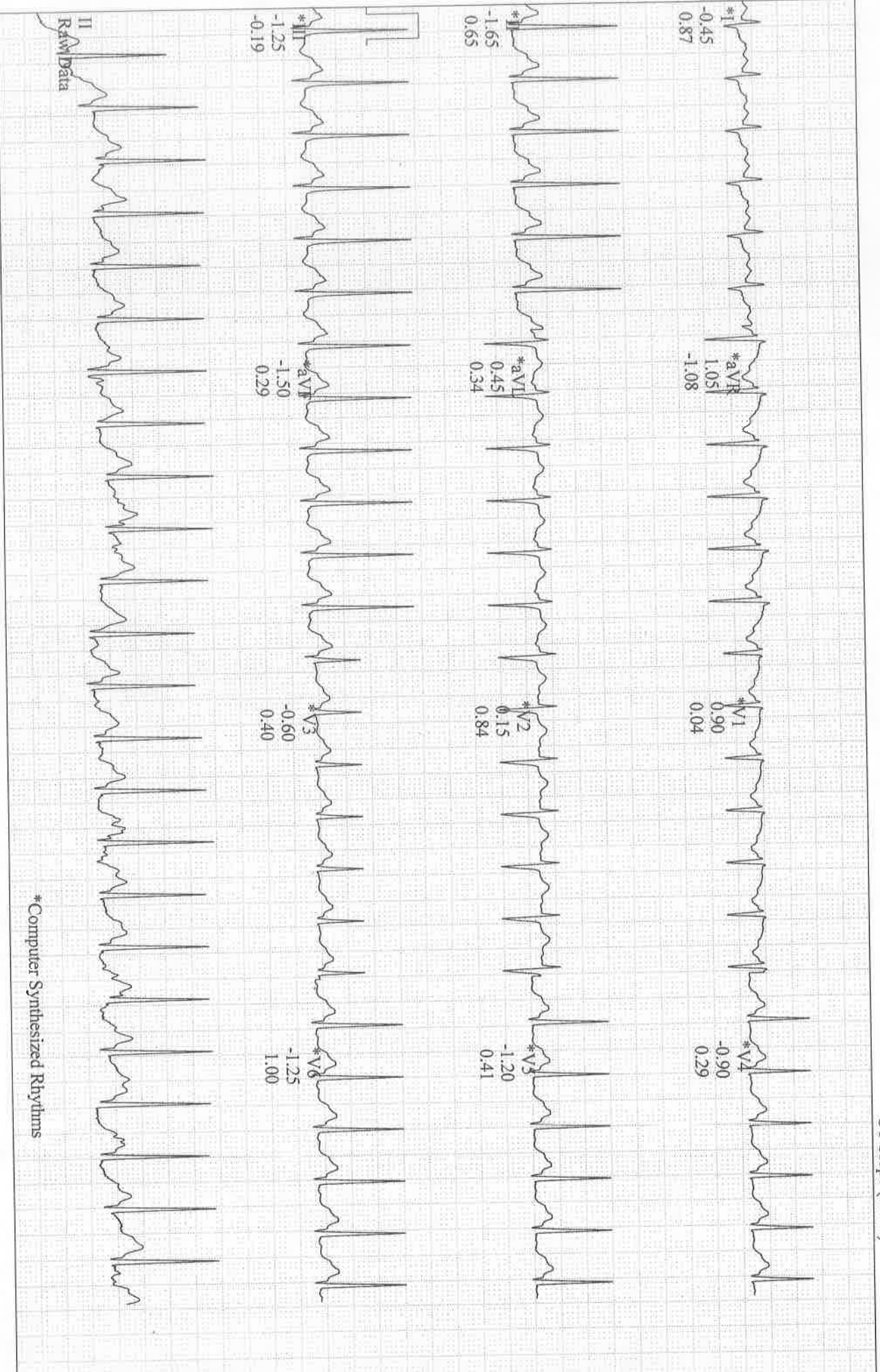
BRUCE

1.7 mph

10.0 %

APOLLO MEDICAL CENTRE

Lead
ST Level (mm)
ST Slope (mV/s)



*Computer Synthesized Rhythms

GE CardioSoft V7.0 (10)
25 mm/s 10 mm/mV 50 Hz 0.05Hz FRF+ HR(LL,V6)

Start of Test: 11:19:25am

MRS, V KAVITTHA

Patient ID: 252975

29.03.2024

11:28:10am

Female 152 cm 74.5 kg

38 yrs Asian

Exercise Test / Linked Medians

EXERCISE

STAGE 2

05:07

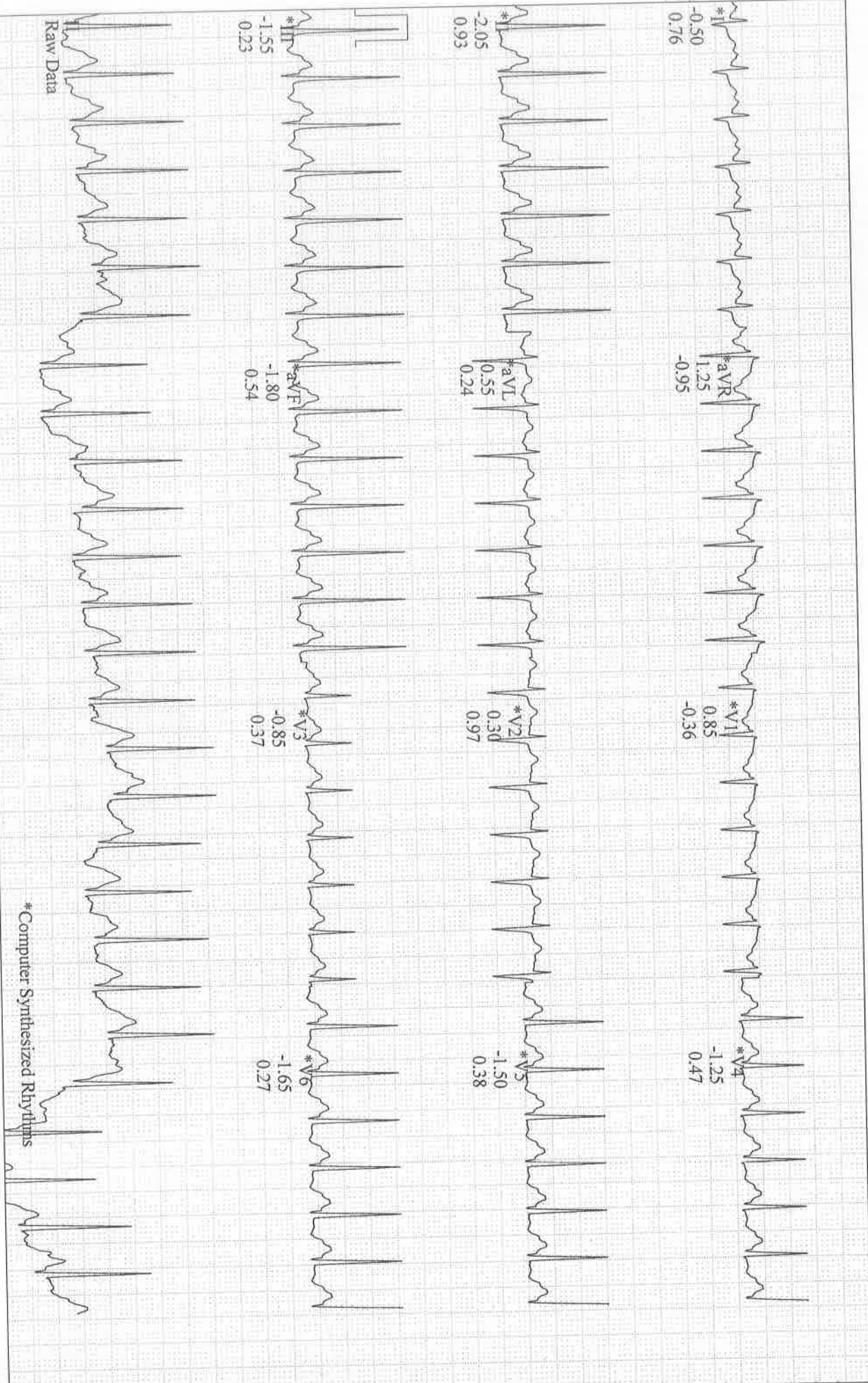
BRUCE

2.5 mph

12.0 %

APOLLO MEDICAL CENTRE

Lead
ST Level (mm)
ST Slope (mV/s)



MRS, V KAVITHA

Patient ID: 252975

29.03.2024 Female 152 cm 74.5 kg

11:31:02am 38 yrs Asian

Exercise Test / Linked Medians

EXERCISE

STAGE 3

07:59


BRUCE

3.4 mph

14.0 %

APOLLO MEDICAL CENTRE

Lead
ST Level (mm)
ST Slope (mV/s)



GE CardioSoft V7.0 (10)
25 mm/s 10 mm/mV 50 Hz 0.05Hz PRF+ HR(V6,II)

Start of Test: 11:19:25am

MRS, V KAVITHA

Patient ID: 252975

29.03.2024 Female 152 cm 74.5 kg

11:31:15am 38 yrs Asian

Exercise Test / Linked Medians (PEAK EXERCISE)

EXERCISE

STAGE 4

08:12

BRUCE


4.0 mph

14.4 %

APOLLO MEDICAL CENTRE

196 bpm
160/80 mmHg

Lead
ST Level (mm)
ST Slope (mV/s)



MRS, V KAVITHA

Patient ID: 252975

Female 152 cm 74.5 kg

29.03.2024 11:32:15am 38 yrs Asian

Exercise Test / Linked Medians

RECOVERY

#1

01:00

BRUCE

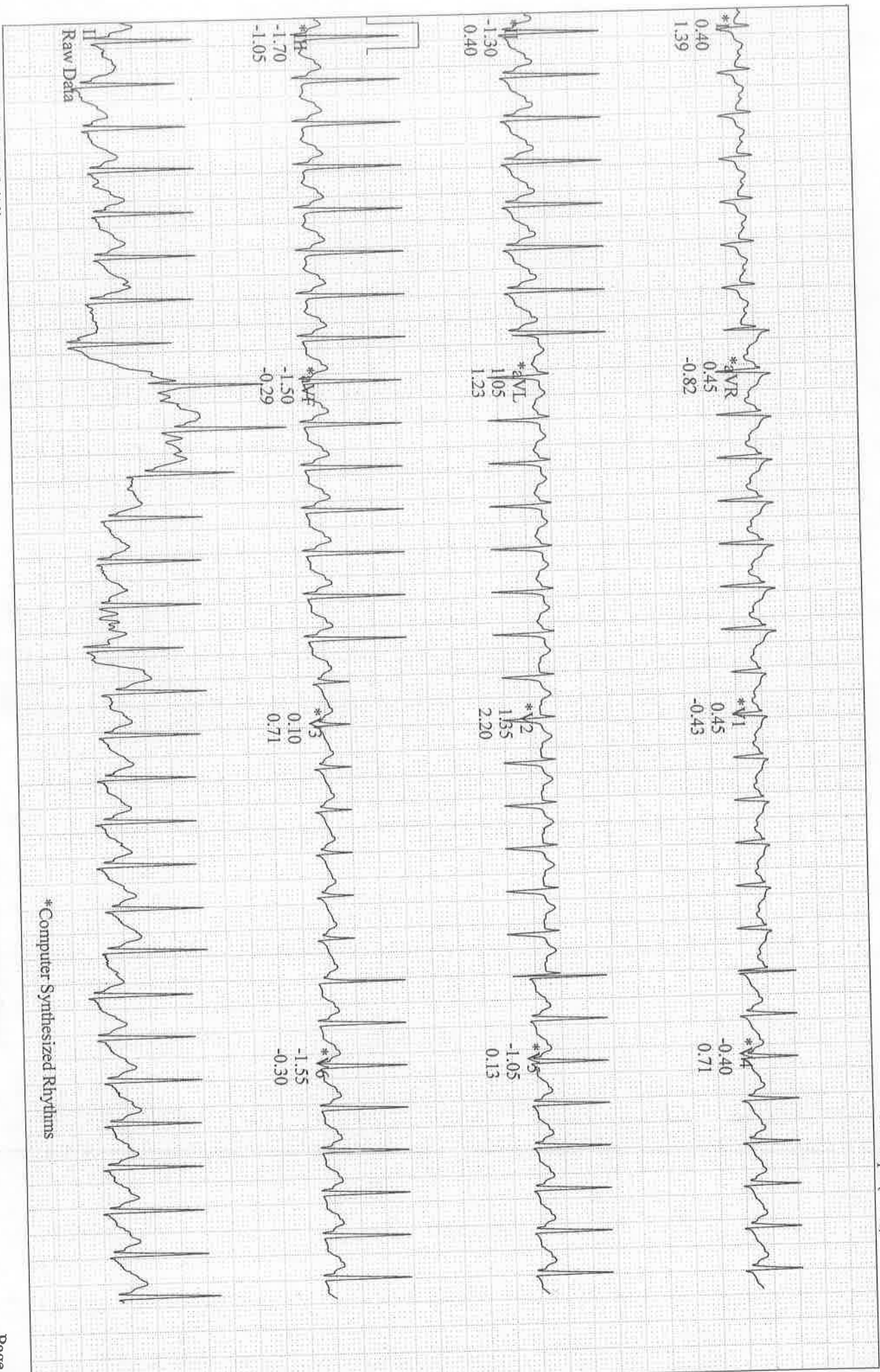
0.0 mph

0.0 %

APOLLO MEDICAL CENTRE

179 bpm
170/80 mmHg

Lead
ST Level (mm)
ST Slope (mV/s)



MRS, V KAVITHA

Patient ID: 252975

29.03.2024

11:34:15am

02:45 No symptoms

Female 152 cm 74.5 kg

38 yrs Asian

Exercise Test / Linked Medians

RECOVERY

#1

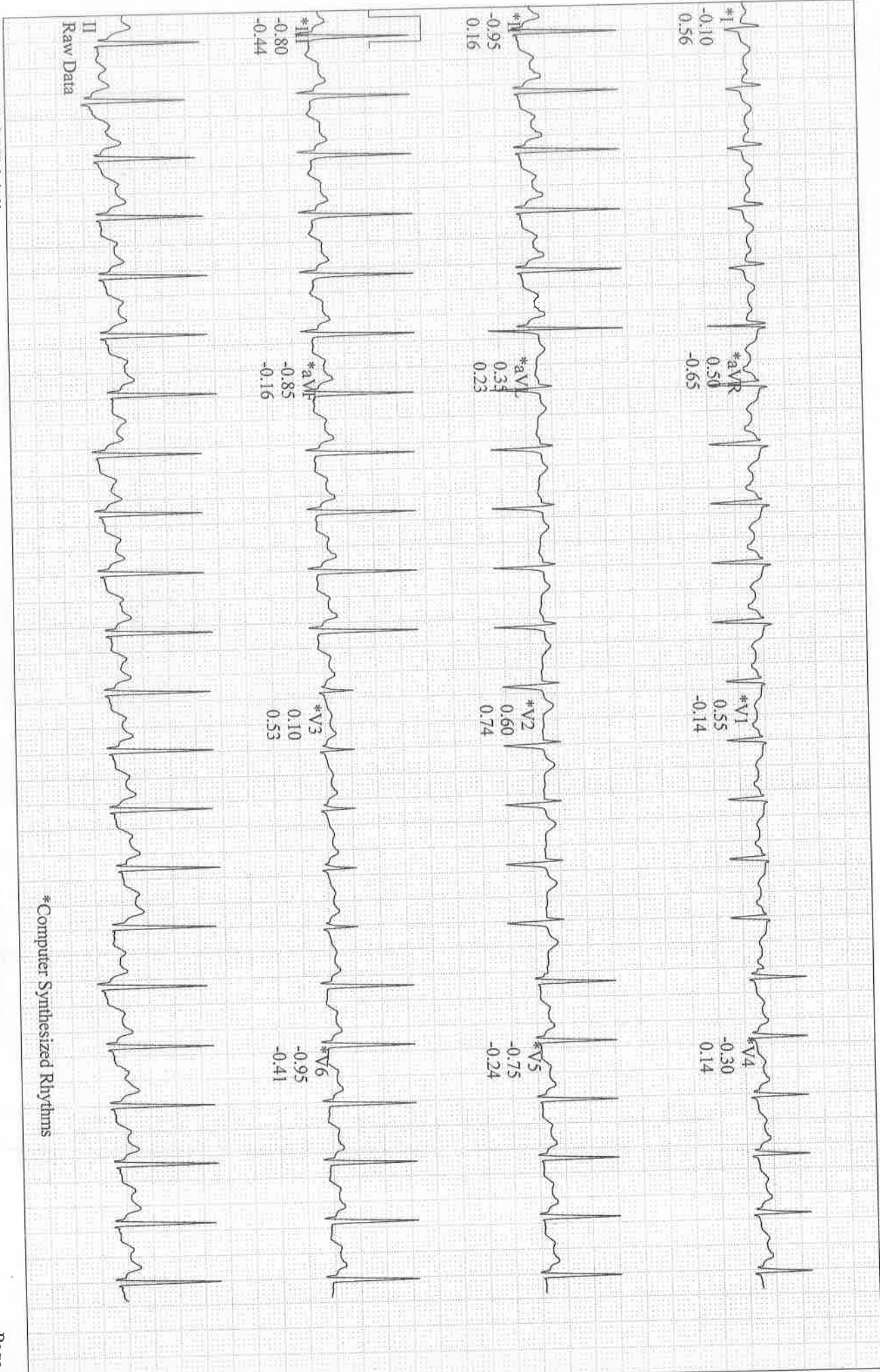
03:00

130 bpm
160/90 mmHg

BRUCE
0.0 mph
0.0 %

APOLLO MEDICAL CENTRE

Lead
ST Level (mm)
ST Slope (mV/s)



GE CardioSoft V7.0 (10)
25 mm/s 10 mm/mV 50 Hz 0.05Hz FRF+ HR(V6,II)

*Computer Synthesized Rhythms

Start of Test: 11:19:25am

MRS, V KAVITHA

Patient ID: 252975
 29.03.2024 Female 152 cm 74.5 kg
 11:19:25am 38 yrs Asian
 Meds: TAB TAZLOC 40

Test Reason:
 Medical History: NIL

Ref. MD: Ordering MD:
 Technician: AKHILA Test Type:
 Comment:

BRUCE: Exercise Time 08:12
 Max HR: 200 bpm 109 % of max predicted 182 bpm HR at rest: 111
 Max BP: 170/80 mmHg BP at rest: 130/80 Max RPP: 33320 mmHg*pbm
 Maximum Workload: 10.20 METS
 Max. ST: -3.40 mm, 1.01 mV/s in II; RECOVERY 0:50
 Arrhythmia: A:103, PVC:2
 ST/HR index: 1.68 μ V/bpm
 ST/HR slope: 1.46 μ V/bpm (III)
 HR reserve used: 118 %
 HR recovery: 17 bpm
 VE recovery: 0 VE/min

BASELINE EXERCISE	MAX. ST RECOVERY	PEAK EXERCISE EXERCISE	TEST END RECOVERY	BASELINE EXERCISE	MAX. ST RECOVERY	PEAK EXERCISE EXERCISE	TEST END RECOVERY
110 bpm 130/80 mmHg	181 bpm 170/80 mmHg	196 bpm 160/80 mmHg	129 bpm 160/90 mmHg	110 bpm 130/80 mmHg	181 bpm 170/80 mmHg	196 bpm 160/80 mmHg	129 bpm 160/90 mmHg
I -0.35 mm -0.01 mV/s	I -0.40 0.79	I 0.05 2.15	I -0.05 0.64	V1 0.55 -0.34	V1 1.05 -0.74	V1 0.85 -0.80	V1 0.55 -0.08
II -1.00 -0.06	II -3.40 1.01	II -2.00 0.62	II -0.85 0.34	V2 0.10 0.23	V2 0.65 1.05	V2 0.45 2.19	V2 0.45 0.58
III -0.70 -0.42	III -2.95 0.35	III -1.90 -1.58	III -0.75 -0.58	V3 -0.35 0.03	V3 -1.55 0.83	V3 -1.15 0.42	V3 0.15 0.43
aVR 0.65 -0.28	aVR 1.85 -1.01	aVR 0.95 -1.32	aVR 0.45 -0.65	V4 -0.60 -0.05	V4 -1.75 0.69	V4 -1.65 -0.18	V4 -0.50 0.23
aVL 0.15 -0.17	aVL 1.25 0.06	aVL 1.05 2.13	aVL 0.35 0.25	V5 -0.70 -0.16	V5 -2.20 0.25	V5 -1.95 -1.39	V5 -0.75 -0.30
aVF -0.85 -0.19	aVF -3.20 0.61	aVF -1.95 -0.39	aVF -0.80 -0.12	V6 -0.80 -0.23	V6 -2.60 -0.36	V6 -2.35 -2.10	V6 -0.95 -0.48

GE CardioSoft V7.0 (10)
 10 mm/mV 50 Hz 0.04Hz FRF HEART V5.41.1

Unconfirmed

Attending MD:

MRS, V KAVITHA

Patient ID: 252975

29.03.2024 Female 152 cm 74.5 kg

11:19:25am 38 yrs Asian

Meds: TAB TAZLOC 40

Test Reason:

Medical History: NIL

Ref. MD: Ordering MD:

Technician: AKHILA Test Type:

Comment:

BRUCE: Exercise Time 08:12

Max HR: 200 bpm 109 % of max predicted 182 bpm HR at rest: 111

Max BP: 170/80 mmHg BP at rest: 130/80 Max RPP: 33320 mmHg*⁴bpm

Maximum Workload: 1020 METS

Max. ST: -3.40 mm, 1.01 mV/s in II; RECOVERY 0:50

Arrhythmia: A:103, PVC:2

ST/HR index: 1.68 μ V/bpmST/HR slope: 1.46 μ V/bpm (III)

HR reserve used: 118 %

HR recovery: 17 bpm

VE recovery: 0 VE/min

ST/HR hysteresis: -0.008 mV (III)

QRS duration: BASELINE: 84 ms, PEAK EX: 76 ms, REC: 88 ms

Reasons for Termination: Target heart rate achieved

Summary:**Resting ECG:** normal **Functional Capacity:** normal. **HR Response to Exercise:**appropriate. **BP Response to Exercise:** NORMAL HR AND BP RESPONSE. **Chest****Pain:** none. **Arrhythmias:** NO ANGINA OR ARRHYTHMIA. **ST Changes:** NO**SIGNIFICANT ST DEPRESSION DURING EXC AND REC. Overall impression:****GOOD EFFORT TOLERANCE.****Conclusion:** STRESS TEST NEGATIVE FOR INDUCIBLE ISCHEMIA

Room:

Location: * 0 *

CLIENT HAS TOLD CONSULTATION NOT REQUIRED CONCERN FORM NOT GIVEN

Patient Name : Mrs. V KAVITHA

Age/Gender : 38 Y/F

UHID/MR No. : CKOR.0000252975

OP Visit No : CKOROPV405300

Sample Collected on :

Reported on : 29-03-2024 13:29

LRN# : RAD2285814

Specimen :

Ref Doctor : SELF

Emp/Auth/TPA ID : bobE18691

DEPARTMENT OF RADIOLOGY

X-RAY CHEST PA

Both lungs fields appear normal.

Both hila are normal.

Both costophrenic and cardiophrenic angles are normal.

The cardiac mediastinal shadows appear normal.

Bones and soft tissues appear normal.

IMPRESSION : NORMAL STUDY.

Dr. VINOD P JOSEPH
MBBS, DNB, DMRD
Radiology

Patient Name	: Mrs. V KAVITHA	Age/Gender	: 38 Y/F
UHID/MR No.	: CKOR.0000252975	OP Visit No	: CKOROPV405300
Sample Collected on	:	Reported on	: 29-03-2024 13:12
LRN#	: RAD2285814	Specimen	:
Ref Doctor	: SELF		
Emp/Auth/TPA ID	: bobE18691		

DEPARTMENT OF RADIOLOGY

ULTRASOUND - WHOLE ABDOMEN

Liver is normal in size and shows normal echo pattern. No biliary dilatation. No focal lesion

Portal vein is normal in size, course and caliber. CBD is not dilated.

Gall bladder is normal without evidence of calculi, wall thickening or pericholecystic fluid

Pancreas to the extent visualized, appears normal in size, contour and echogenicity

Spleen is normal in size, shape, contour and echopattern. No evidence of mass or focal lesion.

Right kidney is normal in size, position, shape and echopattern. Corticomedullary differentiation is maintained. No evidence of calculi or hydronephrosis.

Left kidney is normal in size, position, shape and echopattern. corticomedullary differentiation is maintained. No evidence of calculi or hydronephrosis.

Urinary Bladder is well distended. wall thickness is normal. No internal echoes.

Uterus: measures 7.4x 4.6 x 3.3cm and there is a 2.3 x 2.4 cms fundal fibroid. Endometrial echoes are normal

Endometrium: measures 3mm.

Both ovaries normal in size and echopattern,

Both adnexa: Normal, no mass seen.

There is no ascites.

IMPRESSION: FIBROID UTERUS

**DR VINOD JOSEPH DNB,DMRD
RADIOLOGIST**

Dr. VINOD P JOSEPH
MBBS, DNB, DMRD
Radiology

Name: Mrs. V KAVITHA
Age/Gender: 38 Y/F
Address: kmg
Location: BANGALORE, KARNATAKA
Doctor:
Department: GENERAL
Rate Plan: KORAMANGALA_06042023
Sponsor: ARCOFEMI HEALTHCARE LIMITED
Consulting Doctor: Dr. RINITHA RAJAN

MR No: CKOR.0000252975
Visit ID: CKOROPV405300
Visit Date: 29-03-2024 08:33
Discharge Date:
Referred By: SELF

HT-CHIEF COMPLAINTS AND PRESENT KNOWN ILLNESS

SYSTEMIC REVIEW

Eye

-: ...,

Ent

:-:,

**Weight

--->: Stable,

HT-HISTORY

Past Medical History

PAST MEDICAL HISTORY: Nil,

**Cancer: NO,

Family History

B.P	120/80,
-----	---------

PHYSICAL EXAMINATION

SYSTEMIC EXAMINATION

Eye:

Squint:,

IMPRESSION

RECOMMENDATION

DISCLAIMER

Disclaimer: The health checkup examinations and routine investigations have certain limitations and may not be able to detect all the diseases. Any new or persisting symptoms should be brought to the attention of the consulting physician. Additional tests, consultations and follow up may be required in some cases.,

Doctor's Signature

Name: Mrs. V KAVITHA
Age/Gender: 38 Y/F
Address: kmg
Location: BANGALORE, KARNATAKA
Doctor:
Department: GENERAL
Rate Plan: KORAMANGALA_06042023
Sponsor: ARCOFEMI HEALTHCARE LIMITED
Consulting Doctor: Dr. MAHABALESWAR

MR No: CKOR.0000252975
Visit ID: CKOROPV405300
Visit Date: 29-03-2024 08:33
Discharge Date:
Referred By: SELF

Eye

-: ...,

Eye:

Squint:,

Doctor's Signature

Name: Mrs. V KAVITHA
Age/Gender: 38 Y/F
Address: kmg
Location: BANGALORE, KARNATAKA
Doctor:
Department: GENERAL
Rate Plan: KORAMANGALA_06042023
Sponsor: ARCOFEMI HEALTHCARE LIMITED
Consulting Doctor: Dr. VIJAYA LAKSHMI M

MR No: CKOR.0000252975
Visit ID: CKOROPV405300
Visit Date: 29-03-2024 08:33
Discharge Date:
Referred By: SELF

Ent

:-:

Doctor's Signature

Name: Mrs. V KAVITHA
Age/Gender: 38 Y/F
Address: kmg
Location: BANGALORE, KARNATAKA
Doctor:
Department: GENERAL
Rate Plan: KORAMANGALA_06042023
Sponsor: ARCOFEMI HEALTHCARE LIMITED
Consulting Doctor: Dr. GAZALA ANJUM

MR No: CKOR.0000252975
Visit ID: CKOROPV405300
Visit Date: 29-03-2024 08:33
Discharge Date:
Referred By: SELF

HT-CHIEF COMPLAINTS AND PRESENT KNOWN ILLNESS

SYSTEMIC REVIEW

**Weight

--->: Stable,

HT-HISTORY

Past Medical History

PAST MEDICAL HISTORY: Nil,

**Cancer: NO,

Family History

B.P	120/80,
-----	---------

PHYSICAL EXAMINATION

SYSTEMIC EXAMINATION

IMPRESSION

RECOMMENDATION

DISCLAIMER

Disclaimer: The health checkup examinations and routine investigations have certain limitations and may not be able to detect all the diseases. Any new or persisting symptoms should be brought to the attention of the consulting physician. Additional tests, consultations and follow up may be required in some cases.,

Doctor's Signature

Name: Mrs. V KAVITHA
Age/Gender: 38 Y/F
Address: kmg
Location: BANGALORE, KARNATAKA
Doctor:
Department: GENERAL
Rate Plan: KORAMANGALA_06042023
Sponsor: ARCOFEMI HEALTHCARE LIMITED
Consulting Doctor: Dr. JYOTHI RAJESH

MR No: CKOR.0000252975
Visit ID: CKOROPV405300
Visit Date: 29-03-2024 08:33
Discharge Date:
Referred By: SELF

Family History

B.P	120/80,
-----	---------

Doctor's Signature

Patient Name	: Mrs. V KAVITHA	Age	: 38 Y/F
UHID	: CKOR.0000252975	OP Visit No	: CKOROPV405300
Reported By:	: Dr. MOHAN MURALI	Conducted Date	: 29-03-2024 11:56
Referred By	: SELF		

ECG REPORT

Observation :-

1. Normal Sinus Rhythm.
2. Heart rate is 80beats per minutes.
3. No pathological Q wave or S-T,T changes seen.
4. Normal P,Q,R,S,T waves and axis.
5. No evidence of chamber, hypertrophy or enlargement seen.

Impression:

NORMAL RESTING ECG.

Dr MOHAN MURALI
CARDIOLOGIST

Patient Name	: Mrs. V KAVITHA	Age	: 38 Y/F
UHID	: CKOR.0000252975	OP Visit No	: CKOROPV405300
Reported By:	: Dr. MOHAN MURALI	Conducted Date	: 29-03-2024 11:56
Referred By	: SELF		

NOTE:KINDLY TAKE A PHOTOCOPY OF THE GRAPH
FOR FUTURE REFERENCE IF NEEDED.

----- END OF THE REPORT -----