

# DAKSH HOSPITAL

396 - 397, Gandhi Nagar, Scheme No. 8, ALWAR -301001

Ref. No.

Date.....

## MEDICAL EXAMINATION REPORT Mediwheel (BOB)

Name: Mr. Kuldeep Jain      Age: 33 yrs      Sex: Male      Date: 13/04/2024

### General Physical Examination

Height : 173 cm  
Pulse : 86 mt  
Respiration : 18/mt

Weight : 85 kg  
BP : 124/80 mm/hg  
BMI : 28.4 kg/m<sup>2</sup>

Systemic Exam:-      *NORMAL*

Dental Check up:-      *NORMAL*

Eye check-up:-      *NORMAL*

Skin Check up:-      *NORMAL*

ENT Check up:-      *NORMAL*

Impression:-      *Sugar, Diabetes  
Fatty liver, NAFLD 28/46*

Recommendation:-      *Lifestyle modification*

- Sugar control
- Fibroskan
- tab VORAKIN OD
- Cas EUCAR 400 (1-1)
- tab Lipogard (OD)
- X/mar
- + Glym 3 OD

*W*  
Dr. Mukesh Kumar Gupta  
MD Gen. Medicine  
Reg. No 5423/16262

डॉ० मुकेश गुप्ता  
M.D.F.C.C.S.  
फिजिशियन एवं मधुमेह रोग विशेषज्ञ  
दक्ष हॉस्पिटल, अलवर  
रजि० नं०-5423/16262

## Results

Run Date 13/04/2024 10:44:01 AM

Operator DAKSH

Last Name

Sample ID 6

First Name KULDEEP JAIN

Department

Gender Male

Age

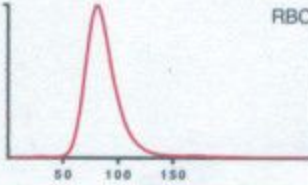
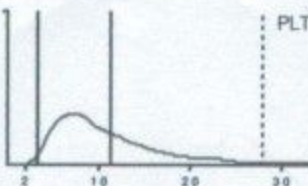
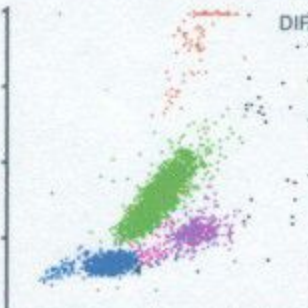
Physician DR. MUKESH GUPTA M.D

Patient ID AUTO\_PID20881

Type Man

Date of birth

Sample comments

			Range		
RBC	5.41	10 <sup>9</sup> /μL	3.80 - 5.50	 <p>RBC</p>	
HGB	15.2	g/dL	13.0 - 17.0		
HCT	47.2	%	39.0 - 52.0		
MCV	87.2	μm <sup>3</sup>	76.0 - 100.0		
MCH	28.0	pg	26.0 - 34.0		
MCHC	32.1	g/dL	32.0 - 35.0		
RDW-CV	15.6	%	11.0 - 16.0		
RDW-SD	53.1	h μm <sup>3</sup>	37.0 - 49.0	 <p>PLT</p>	
PLT	200	10 <sup>3</sup> /μL	150 - 450		
PCT	0.21	%	0.15 - 0.40		
MPV	10.3	μm <sup>3</sup>	8.0 - 11.0		
PDW	17.4	μm <sup>3</sup>	11.0 - 22.0		
P-LCC	71	10 <sup>3</sup> /μL	44 - 140		
P-LCR	35.4	%	18.0 - 50.0	 <p>DIF</p>	
WBC	8.36	10 <sup>3</sup> /μL	3.50 - 10.00		
	#	Range	%		Range
NEU	5.26	1.60 - 7.00	63.3		40.0 - 75.0
LYM	2.56	1.00 - 3.00	30.9		20.0 - 45.0
MON	0.23	0.20 - 0.80	2.7		2.0 - 10.0
EOS	0.16	0.00 - 0.50	2.0		1.0 - 6.0
BAS	0.09	0.00 - 0.15	1.1		0.0 - 1.0
LIC	0.06	0.00 - 0.10	0.7	0.0 - 1.0	

*Dr. R.S. Gupta*  
**Dr. R.S. GUPTA**  
 MD (Pathology) (MAHE)  
 RMC No. 7924/19778

Date :-13/04/2024

Name :- MR.KULDEEP JAIN

Age & Sex :- 34 Yrs/ male

Refd. :- Dr Mukesh Gupta M.D.

	TEST NAME	RESULT	REFERENCE RANGE	
	ESR	18	00 -20 mm/hrs	
	Blood Group & Rh Factor	AB * POSITIVE		
	HbA1C	6.2	4 - 5.6%	
	Blood Sugar (R)	150.1	< 140 mg/dl	
	Blood Sugar (PP)	-	< 140 mg/dl	
	Urine Sugar (F)	2+ ✓	-	
	Urine Sugar (PP)	-	-	
<b>LIVER</b>	S.Bilirubin Total	1.3	0.30 - 1.20 mg/dl	
	S.Bilirubin Direct	0.4	0.10 - 0.30 mg/dl	
	S.Bilirubin Indirect	0.9	0.30 - 0.90 mg/dl	
	S.G.O.T.	38 ✓	> 37 u/l	
	S.G.P.T.	46 ✓	> 40 u/l	
	S.Alk. Phosp.	245	80 - 306 u/l	
	G.G.T.	25	5 -40 u/l	
	Total Protein	6.9	6.5 - 8.5 gm/dl	
	Albumin	3.7	3.8 - 5.4 gm/dl	
	Globulin	3.2	2.3 - 3.5 gm/dl	
A/G Ratio	1.1	-		
	AST/ALT Ratio	0.8	-	
<b>KIDNEY</b>	Blood Urea	35.1	15 -45 mg/dl	
	S.Creatinine	0.98	0.60 - 1.30 mg/dl	
	BUN	17.1	6 -24 mg/dl	
	S.Uric Acid	5.5	M 3.1 - 7.0, F 2.5 - 5.6 mg/dl	
	BUN/Creatinine Ratio	17.3	-	
<b>LIPID PROFILE</b>	Total Cholesterol	160.1	Up to 200 mg/dl	
	S.HDL	44.1	30 - 70 mg/dl	
	S.LDL	88.0	Up to 170 mg/dl	
	S.VLDL	28.1	5.0 - 40 mg/dl	
	S. Triglycerides	140.01	Up to 170 mg/dl	
	LDL/HDL Ratio	2.0	-	
	Total Cholesterol/ HDL Ratio	3.6	-	
<b>THYROID</b>	T3	98.1	40 - 181 ng/dl	
	T4	7.1	4.6 - 10.5 µg/dl	
	TSH	1.65	0.30 - 5.0 mIU/l	
	<b>URINE EXAMINATION</b>		<i>Microscopic Examination:</i>	
<b>General/Chemical Examination:</b>			RBC	Absent
	Colour	Pale Yellow	WBC	3 - 4
	Reaction	Acidic	Epithelial Cells	0 - 1
	Specific Gravity	QNS	Cast	Absent
	Appearance	Clear	Crystal	Absent
	Albumin	Nil	Spermatozoa	Absent
	Sugar	Nil	Amorphous Sediments	Absent
			Other	Absent
<b>X-RAY CHEST</b>	NORMAL STUDY			
	<b>STOOL EXAMINATION</b>		<i>Microscopic Examination:</i>	
<b>General/ Chemical Examination:</b>			RBC	-
	Colour	-	WBC	-
	Consistency	-	Ova & Parasites	-

*Signature*  
**Dr. R.S. GUPTA**  
 MD (Pathology) (MAHE)  
 REG No. 7924/19778

**TECHNOLOGIST**

All investigation have their own limitations regarding the sensitivity & specificity of individual assay procedures. Isolated laboratory investigations never confirm the final diagnosis of the disease. They only help in arriving at a diagnosis in conjunction with clinical presentation and other related investigations. Report is not valid for medico-legal purpose subject to ALWAR jurisdiction only.



# दक्ष हॉस्पिटल

396, गाँधी नगर स्क्रीम नं.8, अलवर (राज०) ☎ 0144-2703340

## Sonography / 2D Echo Cardiography / Doppler Report

### 2D/ ECHO REPORT

Name: - Mr Kuldeep Jain

Age: - 33 Yrs

Date: - 13-Apr-24

Reg. No.:- Alw/2009/04

BOB health checkup

PROCEDURES:

M-MODE/2D/DOPPLER/COLOR/CONTRAST B.A.S. M<sup>2</sup>

MEASUREMENT:		DOPPLER:	
AOD	26	NORMAL	NORMAL (cm/sec.)
LA	24	(20- 37mm)	MV 0.9 (0.8- 1.3) MR No
AVO	20	(19- 40mm)	AV 1.4 (1.2- 1.8) AR No
RVDD.	17.5	(12- 25mm)	TV 0.6 (0.3- 0.8) TR No
		(03- 09mm)	PV 0.8 (0.7- 1.1) PR No
LVDd	50	(37- 56mm)	MITRAL VALVE-
LVDs	31.7	(22- 40mm)	AML Normal
IVS d	11	(06- 12mm)	PML Normal
IVS s	14		
PWd	7.8	(05- 10mm)	AORTIC VALVE Normal
LV FUNCTION		TV & PV are normal.	
M- E- S Separation		<0.9cm	
Minor		24.42%	
LV Ejection Fraction	67%	65 +/- 12%	

MITRAL E>A

LV WALL MOTION: NO RWMA

ALL CARDIAC CHAMBERS ARE NORMAL

ALL VALVES ARE NORMAL

NO CLOT, VEGETATION, PERICARDIAL EFFUSION

Adv: - Follow up/ review at higher center for confirmation

Note:- Please Correlate clinically. Due to technical limitations as well as inaccuracies inherent in the laboratory and statistical analysis of biological process. Diagnostic accuracy of ECHO is up to 95% only.  
Report is not valid for medico-legal purpose.

DR. MUKESH GUPTA

PHYSICIAN

Dr. Mukesh Kumar Gupta

Physician & Sonologist

RM 5423/16262



"भ्रूण लिंग परीक्षण की शिकायत

104 टोल फ्री सेवा पर भी की

जा सकती है"

भ्रूण लिंग परीक्षण की शिकायत 104 टोल फ्री सेवा पर भी की जा सकती है।



# दक्ष हॉस्पिटल

396, गाँधी नगर स्कीम नं.8, अलवर ( राज० ) ☎ 0144-2703340

## Sonography / 2D Echo Cardiography / Doppler Report

Name: MR. KULDEEP JAIN /M/34 YRS

Date: 13-Apr-24

BOB HEALTH CHECK UP

### U.S.G. OF ABDOMEN & PELVIS

#### LIVER

Liver is **16.2 cm with mild to moderate echogenicity**. Intra hepatic biliary radicals are not dilated. No evidence of focal or diffuse lesion.

#### GALL BLADDER

Gall bladder is normal dilated. Lumen clear. Wall thickness normal. CBD normal

#### PANCREAS

Pancreas is normal in size, shape & echo-texture.

#### SPLEEN

8.8 cm in size with normal shape & echo- texture.

#### BOTH KIDNEY

Both kidney normal shape, size & echo texture. CMD maintained

PROSTATE is normal shape, size & echo texture..

URINARY BLADDER is normal shape, size & echo texture..

Impression:- Grade II fatty liver.

Please correlate clinically. USG accuracy is 95 % due to technical limitations as well as inaccuracies inherent in the laboratory and statistical analysis biological process.

This report is not valid for medico-legal cases.

DR. MUKESH GUPTA

SONOLOGIST

Dr. Mukesh Kumar Gupta

Physician & Sonologist

RM 5423/16262



"भ्रूण लिंग परीक्षण की शिकायत  
104 टोल फ्री सेवा पर भी की  
जा सकती है"

भ्रूण लिंग परीक्षण की शिकायत 104 टोल फ्री सेवा पर भी की जा सकती है।

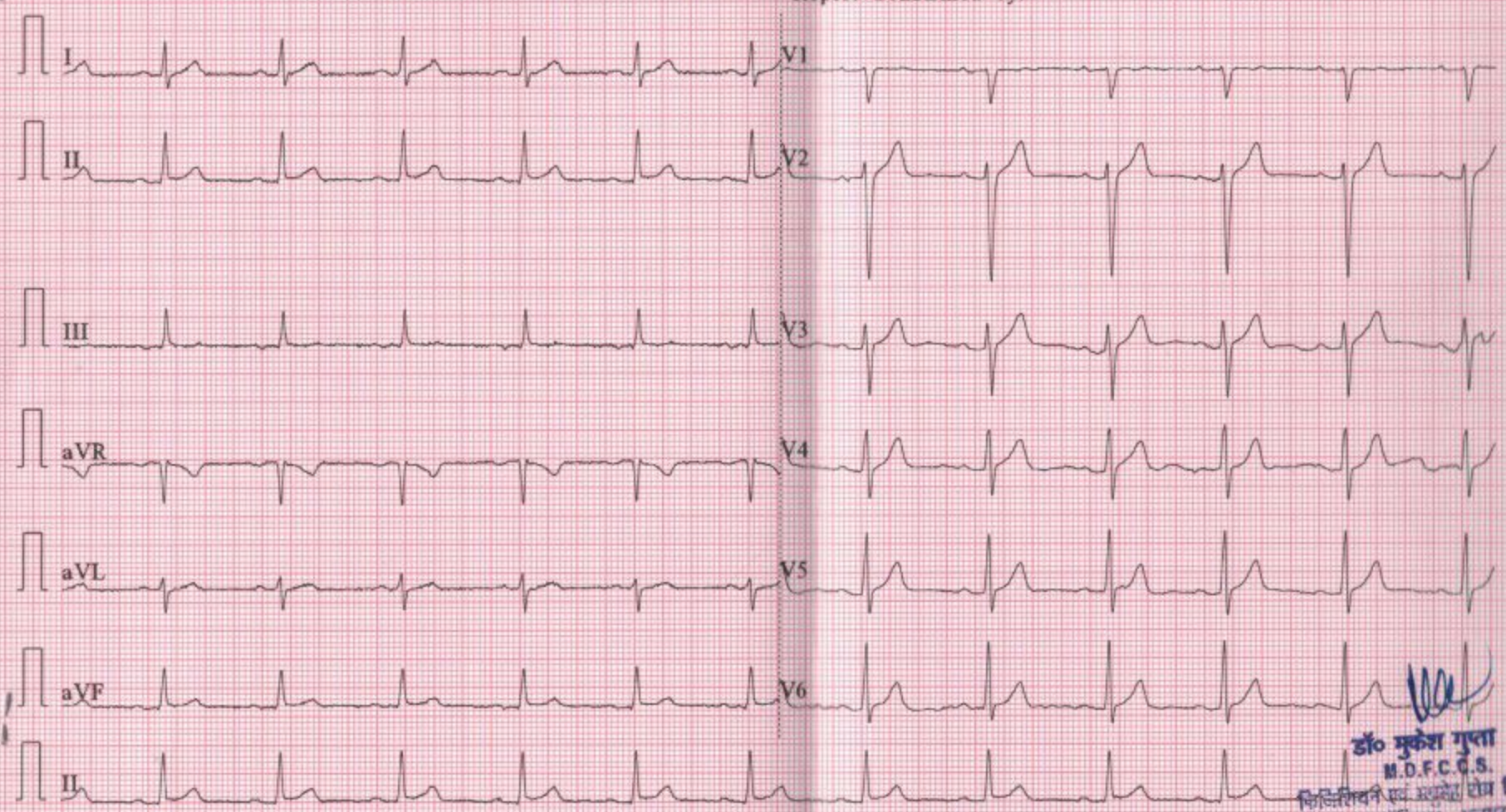
06-04-2024 02:39:10 PM  
ID: 3

Female      Years

HR	:	72	bpm
P	:	115	ms
PR	:	178	ms
QRS	:	84	ms
QT/QTc	:	340/374	ms
P/QRS/T	:	22/69/41	°
RV5/SV1	:	1.077/0.539	mV

Diagnosis Information:  
Sinus Rhythm  
\*\*\*Normal ECG\*\*\*

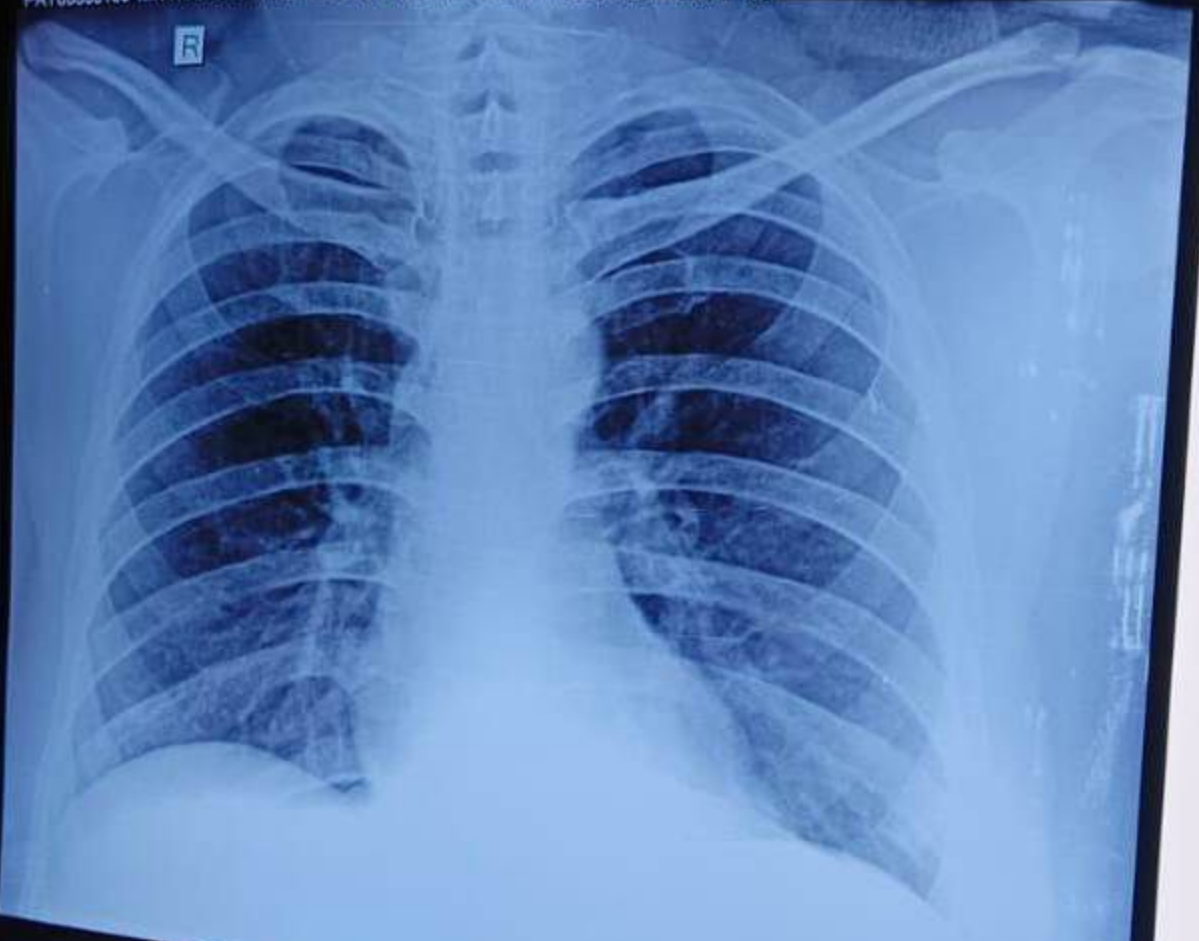
Report Confirmed by:



*(Signature)*  
**डॉ० मुकेश गुप्ता**  
 M.D.F.C.C.S.  
 चिकित्सक एवं अणुशुद्ध रोग विशेषज्ञ  
 दश हॉस्पिटल, अनापूर  
 रजि० नं०-542316262

PAT00868106 MR KULDEEP REFD BY DR MUKESH GUPTA MD. CHEST. 13.04.2024

R



VIJAY DIAGNOSTIC CENTRE 1/16 KALA KUAN .ALWAR

1324