

MR. SIF YUAN SUNDAR

Sex: M cm Birth date: / / mntg 959m years

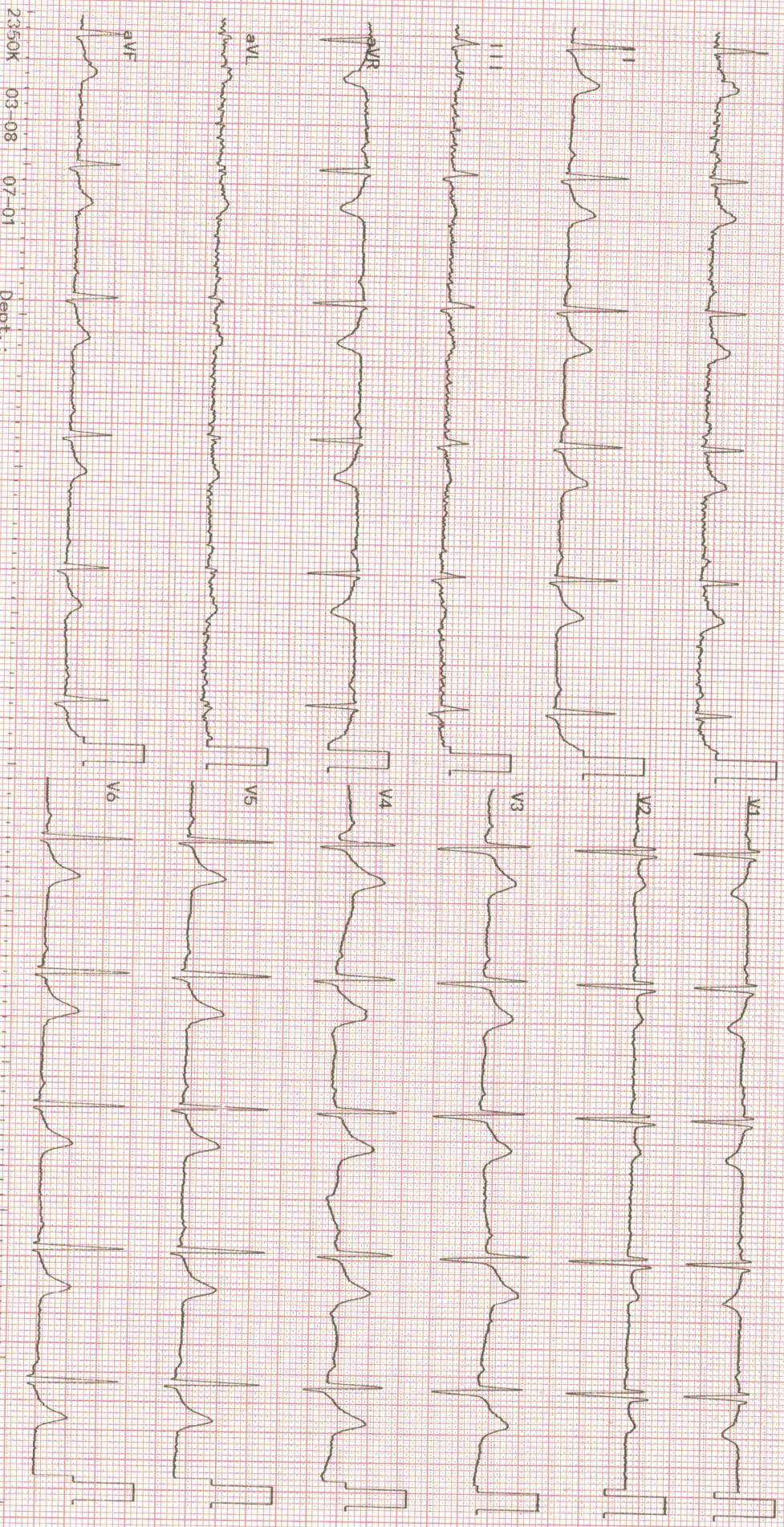
1100 Sinus rhythm
2420 RSR (QR) in lead V1/V2, consistent with right ventricular
conduction delay
9130 ** borderline ECG **

Indications:
Symptoms:
History:
Inte. rate 66 bpm
HR int 166 ms
QRS dur 88 ms
H1/QTc(E) int 392/406 ms
I/QRs/T axis 15/ 52/ 39 °
IV5/SV1 amp 1.52/ 0.95 mV
IV5+SV1 amp 2.47 mV

10 mm/mV 25 mm/s Filter: H50 D 35 Hz

Unconfirmed Report
Reviewed by:

10 mm/mV



2350K 03-08 07-01 Dept.:

Exam: UNIFIED HOSPITAL

DEPARTMENT OF RADIODIAGNOSIS

Name	S Shyam Sundar	Date	09/03/24
Age	35 years	Hospital ID	UHJA23020016
Sex	Male	Ref.	Healthcheck

ULTRASOUND ABDOMEN AND PELVIS

FINDINGS:

Liver is normal in size and echopattern. No intra or extra hepatic biliary duct dilatation. No focal lesions. **Portal vein** is normal in size, course and caliber. **CBD** is not dilated.

Gall bladder is contracted. No obvious calculi are seen in the visualized portion of the lumen. Suggested review scan if any gallbladder pathology is suspected.

Pancreas - Visualized part of the pancreatic head and body appears normal in size, contour and echogenicity. Rest of the pancreas is obscured by bowel gas.

Spleen is normal in size, shape, contour and echopattern. No focal lesion.

Right Kidney is normal in size (9.5 x 3.5 cms), position, shape and echopattern. Corticomedullary differentiation is maintained. No calculus or hydronephrosis.

Left Kidney is normal in size (9.5 x 4.8 cms), position, shape and echopattern. Corticomedullary differentiation is maintained. No calculus or hydronephrosis.

Retroperitoneum - Visualized aorta appeared normal. No obvious enlarged para-aortic nodes.

Urinary Bladder is distended, normal in contour and wall thickness. No evidence of calculi, mass or mural lesion.

Prostate is normal in echopattern and size, measures ~ 9 cc.

No ascites or pleural effusion. Appendix could not be localized. No RIF probe tenderness.

IMPRESSION:

- No definite sonological abnormality detected.




Dr. Elluru Santosh Kumar
Consultant Radiologist



NABH



NABL



No.1



UNITED HOSPITAL

Care Par Excellence
Jayanagar, Bangalore

Out Patient Record

Patient Name : Mr.MR. S SHYAM SUNDAR

UHID : UHJA23020016

Age / Sex : 35 Years / Male

OP NO/Reg Dt : 09-03-2024 10:17 AM

Spouse / Father Name : SHIVALINGAIAH

Department :

Address : peenya 2nd stage , , Bengaluru Urban,
Karnataka, INDIA,

Referred By : *opthal*

Consultant : Dr.Preventive Health Check Up

KMC No. :

Complaints / Findings / Observations :

Vn < 6/6 } 4/6

Investigations:

Al: 00 normal.

Treatment / Care of Plan / Provisional Diagnosis :

Fund's ou cont 0.3:1

FN-PP

Follow Up Advice :

ou cont normal

[Signature]
Signature of the Doctor



NABH



NABL



No.1

**UNITED
HOSPITAL**Care Par Excellence
Jayanagar, Bangalore

Patient name :	Mr. S SHYAM SUNDAR	Date :	09/03/24
Age :	35 years GENDER: MALE	Patient ID :	20016
Ref by :	DR. CMO	OP/IP :	HEALTH CHECK

2D- ECHOCARDIOGRAPHY**M - MODE AND DOPPLER MEASUREMENTS**


(c.m)	(c.m)	(cm/sec)		
AO : 2.9 (2.5-3.7)	LVIDD : 4.6 (3.5-5.5)	MV EV : 79.8	AV : 52.8	MR : TRIVIAL MR
LA : 3.1 (1.9-4.0)	LVIDS : 2.9 (2.4-4.2)	AV : 90.7		AR : TRIVIAL AR
RA : 2.2 (<4.4)	IVSD : 1.0 (0.6-1.1)	PV : 100		PR : NORMAL
RV : 2.0 (<3.5)	IVSS : 1.1 (0.9-1.2)	TV EV : -----	AV : -----	TR : TRIVIAL TR
TAPSE: 1.7 (>1.6)	LVPWD : 1.1 (0.6-1.1)	Diastolic Function : NO LVDD		
	LVPWS : 1.2 (0.9-1.2)			
	EF : 60%			

DESCRIPTIVE FINDINGS

Left Ventricle	: NORMAL
Right Ventricle	: NORMAL
Left Atrium	: NORMAL
Right Atrium	: NORMAL
Wall motion analysis:	NO RWMA
Mitral Valve	: NORMAL, TRIVIAL MR
Aortic Valve	: NORMAL, TRIVIAL AR
Tricuspid Valve	: NORMAL, TRIVIAL TR, PASP-15mmHg
Pulmonary Valve	: NORMAL
IAS	: INTACT
IVS	: INTACT
Pericardium	: NORMAL
Other Findings	: IVC NORMAL

IMPRESSION :

NORMAL CHAMBER DIMENSIONS
 NORMAL LV SYSTOLIC FUNCTION EF : 60%
 NORMAL LV DIASTOLIC FUNCTION
 NO PULMONARY HYPERTENSION
 NO REGIONAL WALL MOTION ABNORMALITIES
 NO CLOTS/ PERICARDIAL EFFUSION /VEGETATION


DR. RAHUL PATIL
 CONSULTANT CARDIOLOGIST



NABH



NABL



No.1

Out Patient Record

Patient Name : Mr.MR. S SHYAM SUNDAR

UHID : UHJA23020016

Age / Sex : 35 Years / Male

OP NO/Reg Dt : 09-03-2024 10:17 AM

Spouse / Father Name : SHIVALINGAIAH

Department :

Address : peenya 2nd stage , , Bengaluru Urban, Karnataka, INDIA,

Referred By :

Consultant : Dr.Preventive Health Check Up

KMC No. :

Complaints / Findings / Observations :

BP - 108/77 mmHg
 SpO2 97 %
 P - 71 bpm
 Ht - 164 cm
 W - 63.3 kg

Investigations:

Treatment / Care of Plan / Provisional Diagnosis :

Follow Up Advice :

Signature of the Doctor

DEPARTMENT OF RADIODIAGNOSIS

Name	S Shyam Sundar	Date	09/03/24
Age	35 years	Hospital ID	UHJA23020016
Sex	Male	Ref.	Healthcheck

RADIOGRAPH OF THE CHEST (PA - VIEW)

FINDINGS:

Bilateral lung fields are normal.

Bilateral costo-phrenic angles are normal.

Cardia and mediastinal contours are normal.

The bony thorax is grossly normal.

IMPRESSION:

- No radiographic abnormality.



Dr. Elluru Santosh Kumar
Consultant Radiologist