



537 / ROHIT KUMAR / 32 Yrs / M / 0 Cms / 0 Kg Date: 16-Feb-2024

Non-Cardiac Pain, Angina / Non-Hypercholesterolemia / Non-Diabetic / Negative Estrogen / Non-Athlete

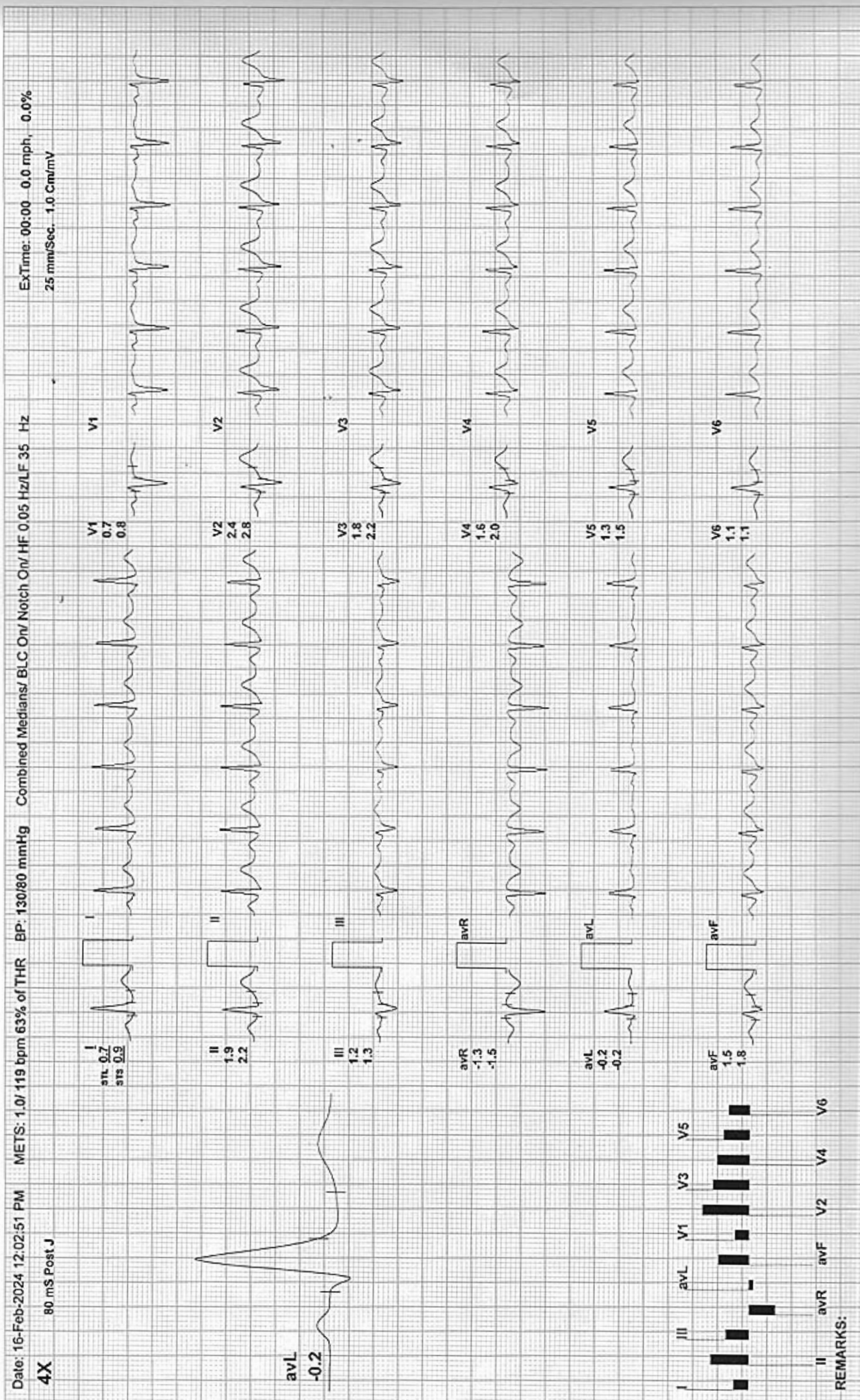
Stage	Time	Duration	Speed(mph)	Elevation	METs	Rate	% THR	BP	RPP	PVC	Comments
Supine	02:34	2:34	00.0	00.0	01.0	119	63 %	130/80	154	00	
Standing	04:08	1:34	00.0	00.0	01.0	137	73 %	130/80	178	00	
HV	04:41	0:33	00.0	00.0	01.0	136	72 %	130/80	176	00	
ExStart	04:47	0:06	01.7	10.0	01.2	139	74 %	130/80	180	00	
BRUCE Stage 1	07:47	3:00	01.7	10.0	04.7	167	89 %	140/85	233	00	
BRUCE Stage 2	10:47	3:00	02.5	12.0	07.1	185	98 %	155/90	286	00	
PeakEX	12:41	1:54	03.4	14.0	09.1	201	107 %	170/95	341	00	
Recovery	13:41	1:00	00.0	00.0	01.1	172	91 %	170/95	292	00	
Recovery	14:41	2:00	00.0	00.0	01.0	149	79 %	170/95	253	00	
Recovery	15:41	3:00	00.0	00.0	01.0	140	74 %	170/95	238	00	
Recovery	16:41	4:00	00.0	00.0	01.0	144	77 %	140/85	201	00	
Recovery	17:31	4:51	00.0	00.0	01.0	133	71 %	140/85	186	00	

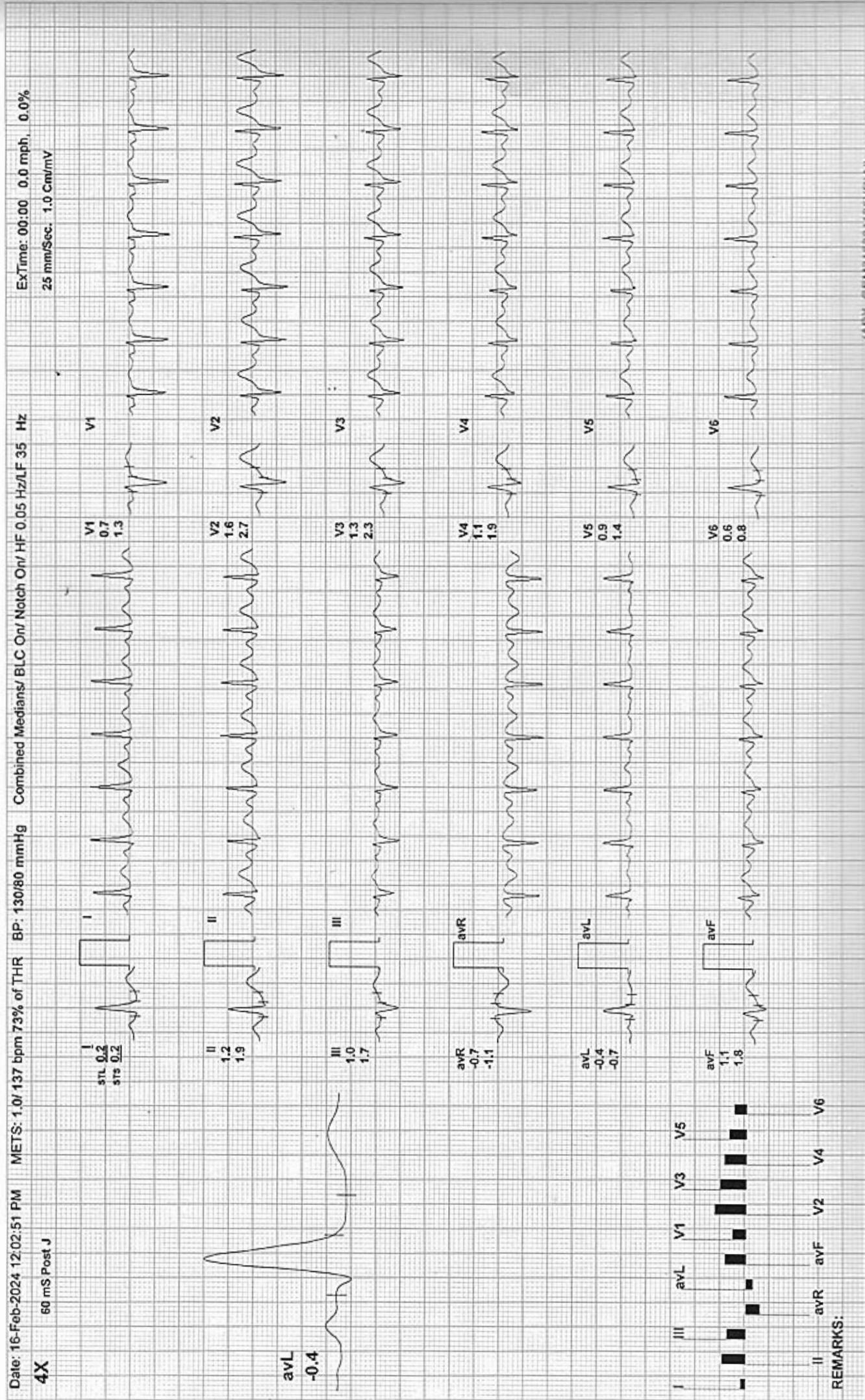
FINDINGS :

- Exercise Time : 07:54
- Max HR Attained : 201 bpm 107% of Target 188
- Max BP Attained : 170/95
- Max WorkLoad Attained : 9.1 Good response to induced stress
- Test Objective : RULED OUT IHD
- History : None
- Test End Reasons : Test Complete, Test Complete

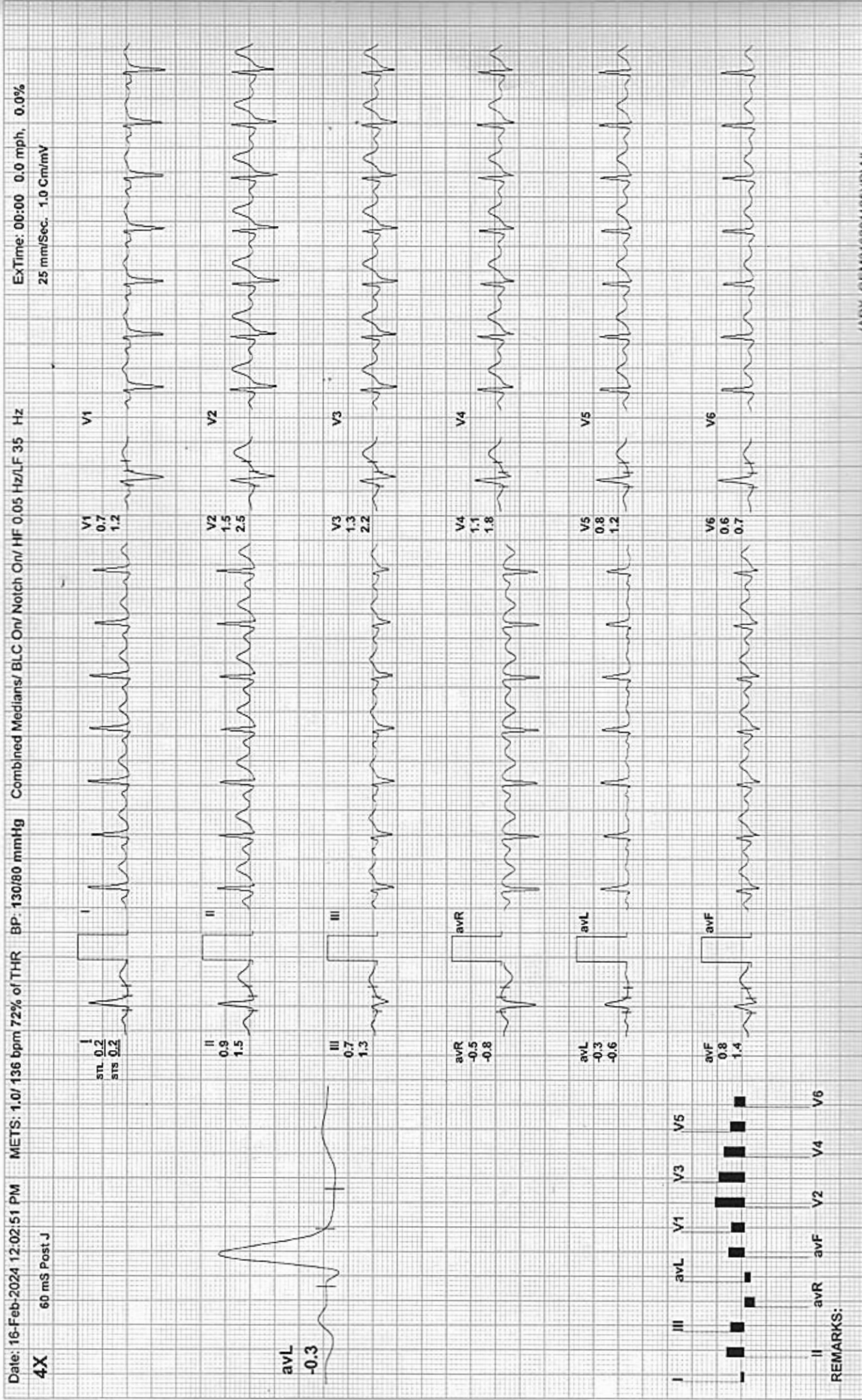
REPORT :

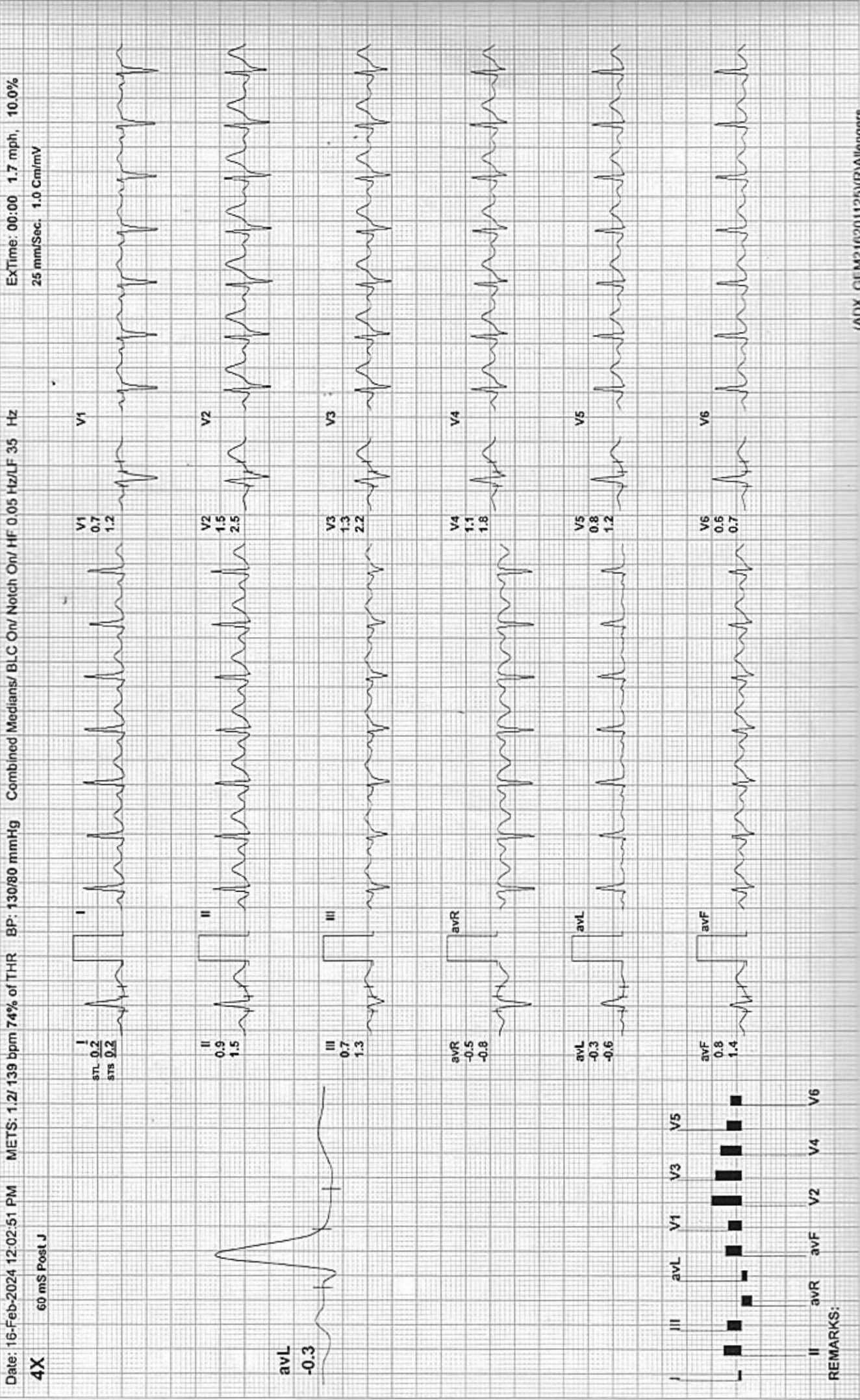
Stress test is Negative for exercise induced ischemia.





REMARKS:



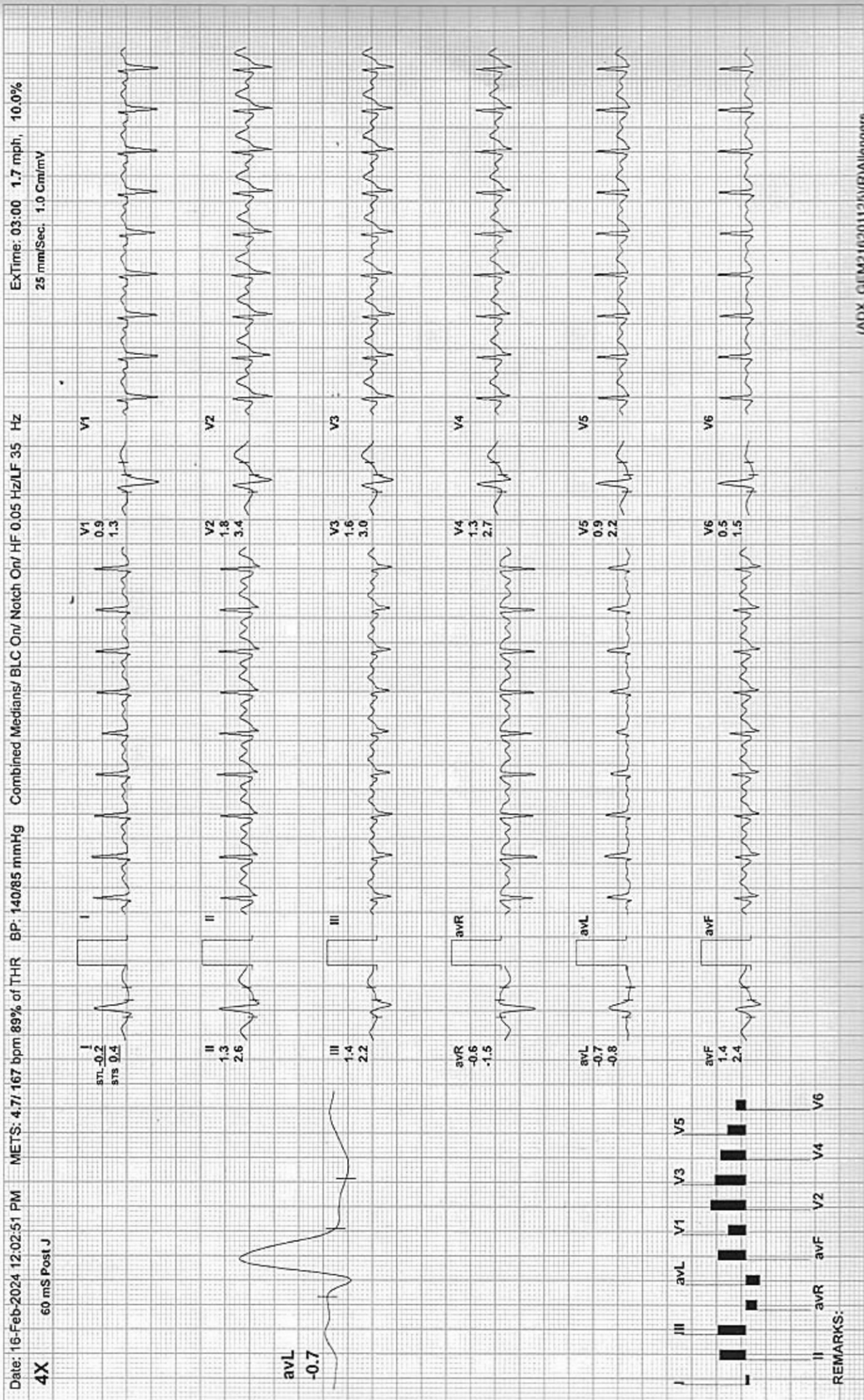




BRUCE: Stage 1(3:00)

ARAVALI HOSPITAL

537 / ROHIT KUMAR / 32 Yrs / M / 0 Cms / 0 Kg / HR : 167

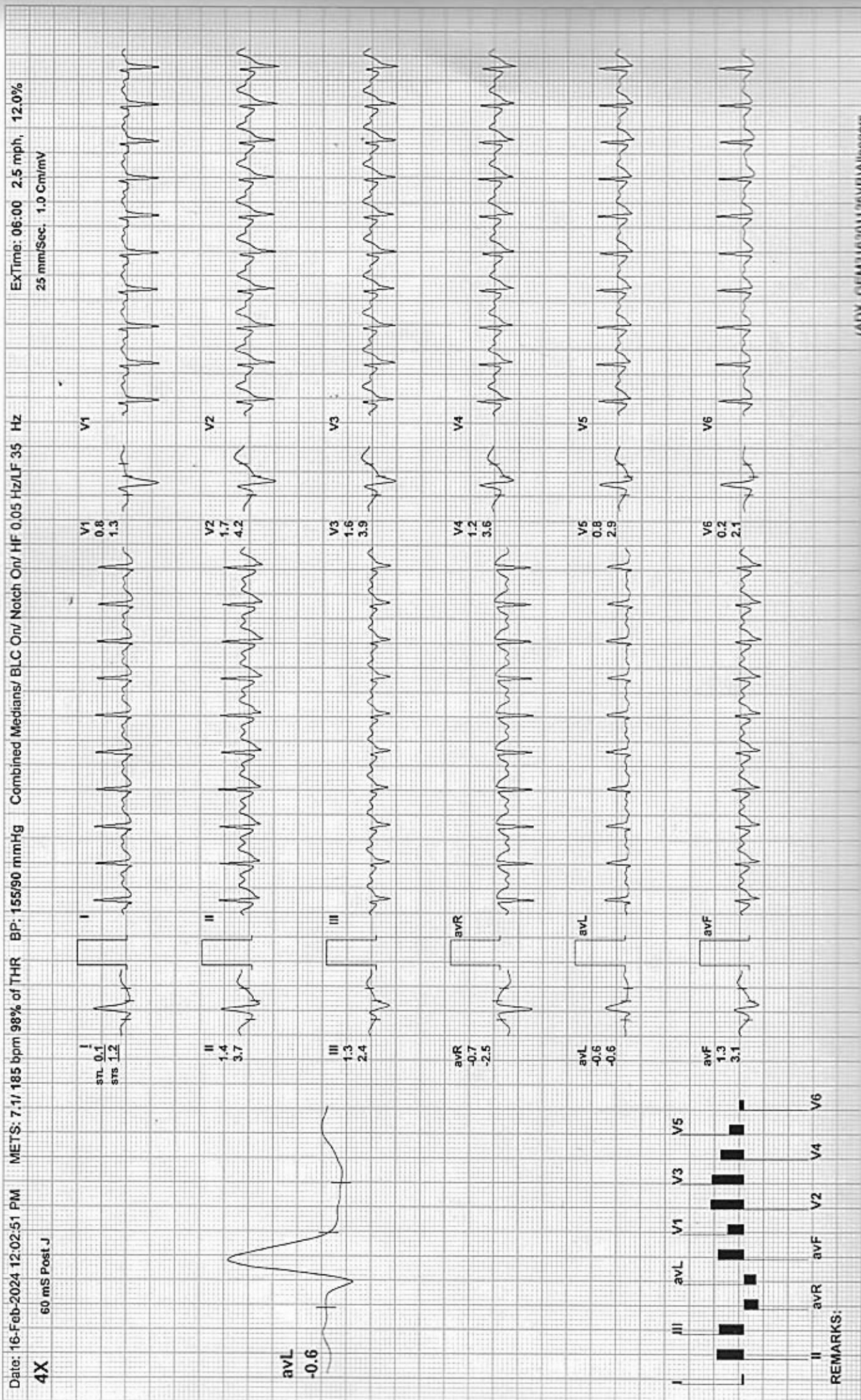





BRUCE: Stage 2(3:00)


ARAVALI HOSPITAL

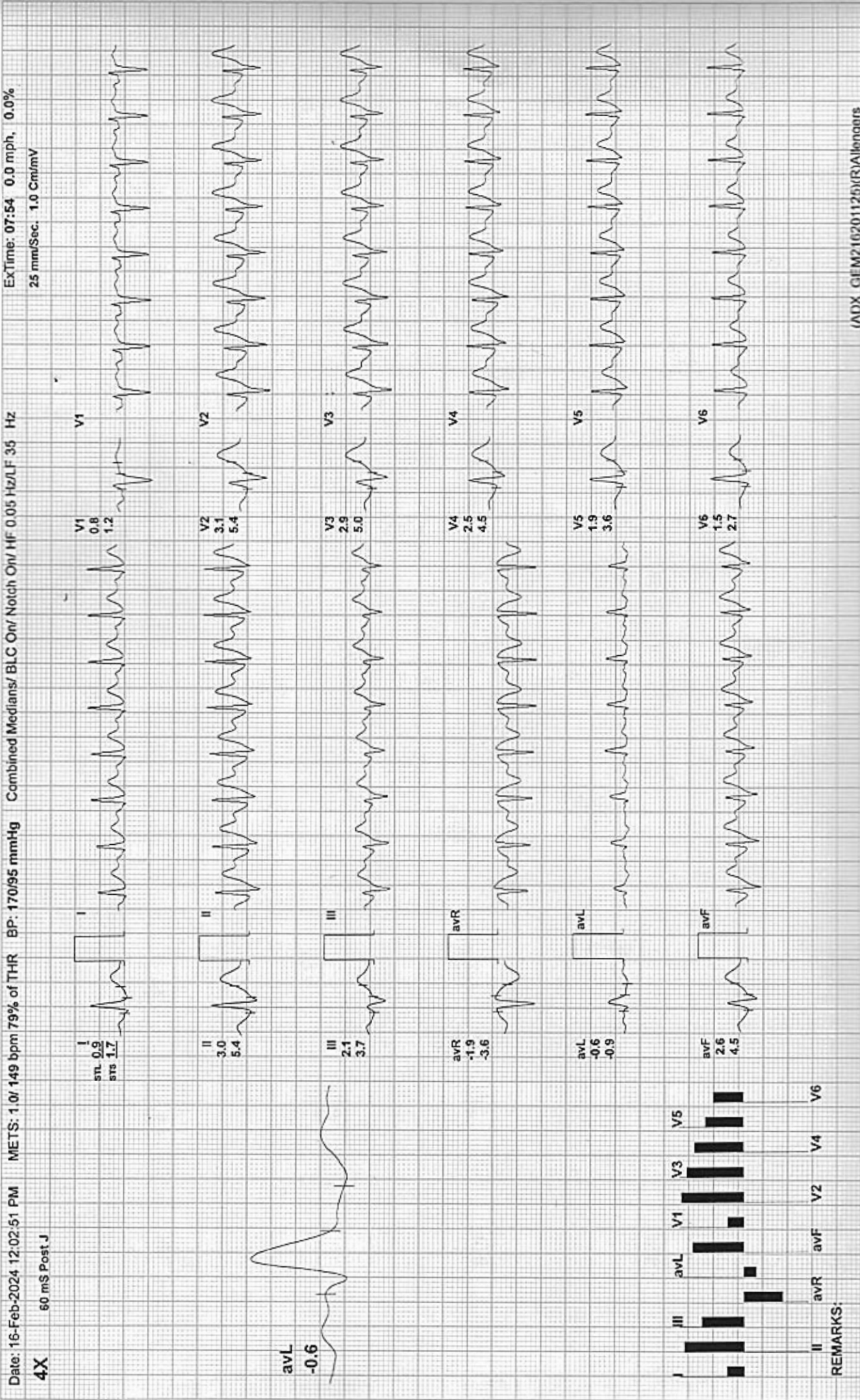
537 / ROHIT KUMAR / 32 Yrs / M / 0 Cms / 0 Kg / HR : 185

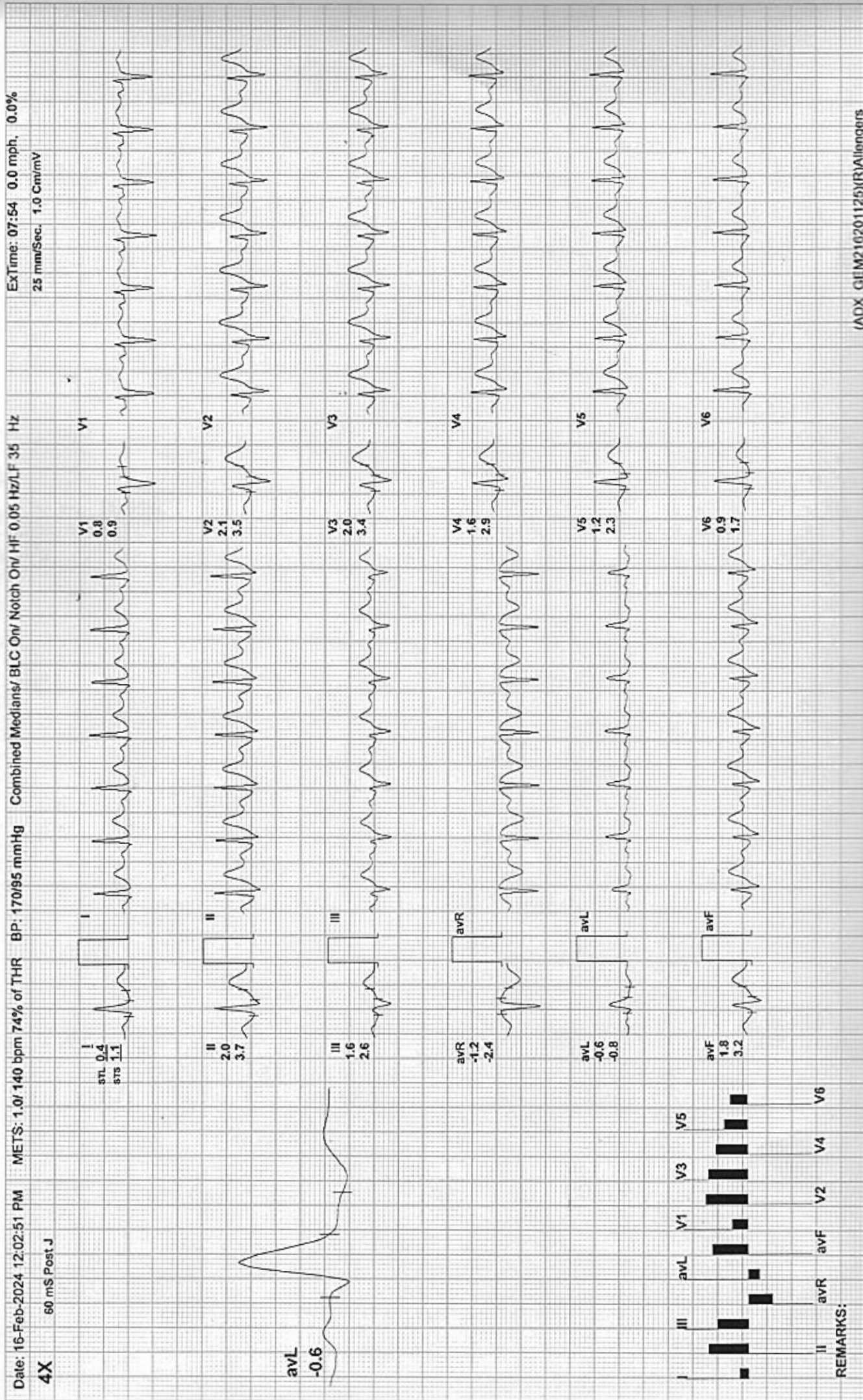


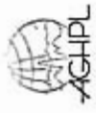REMARKS:







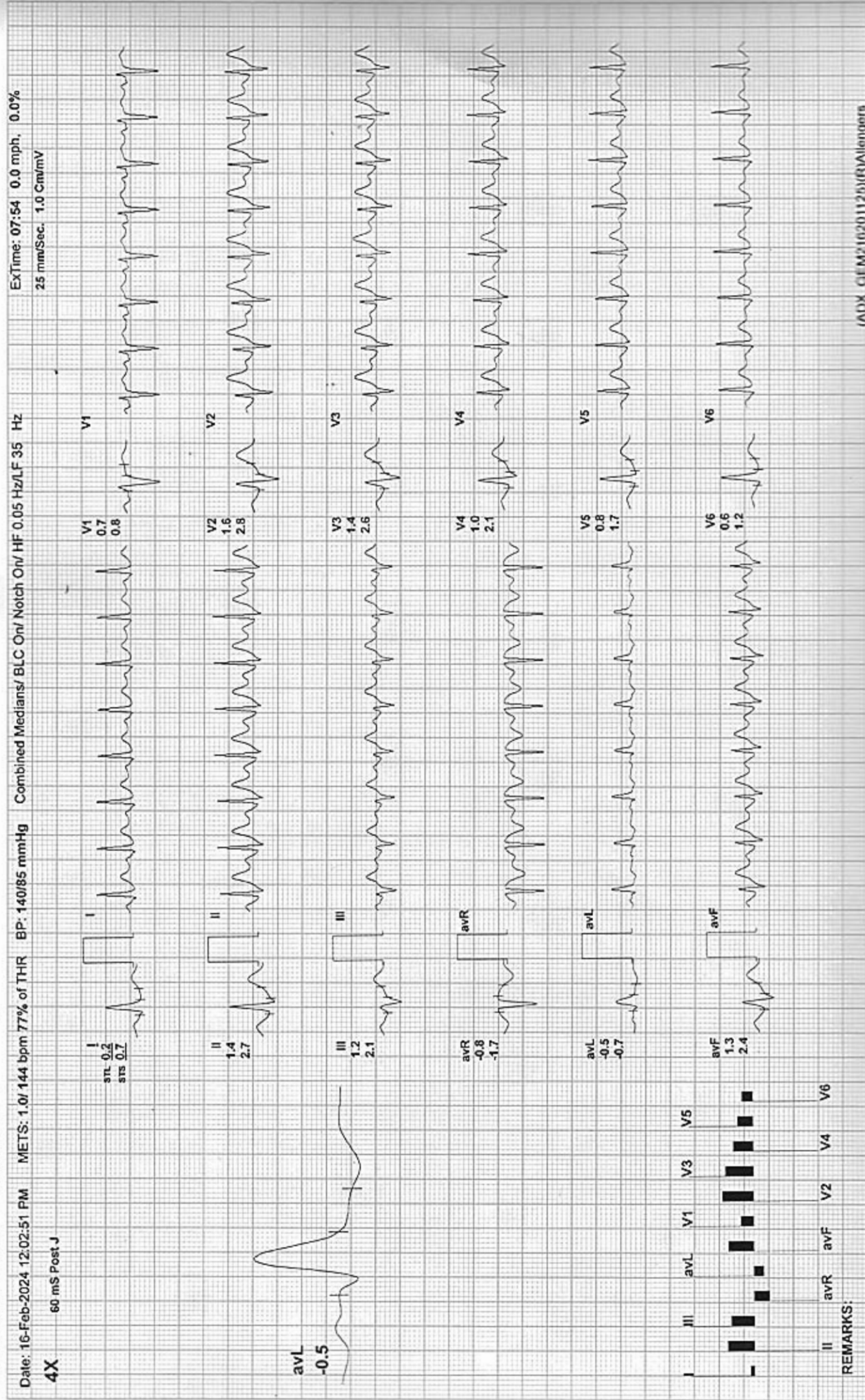




Recovery(4:00)

ARAVALI HOSPITAL

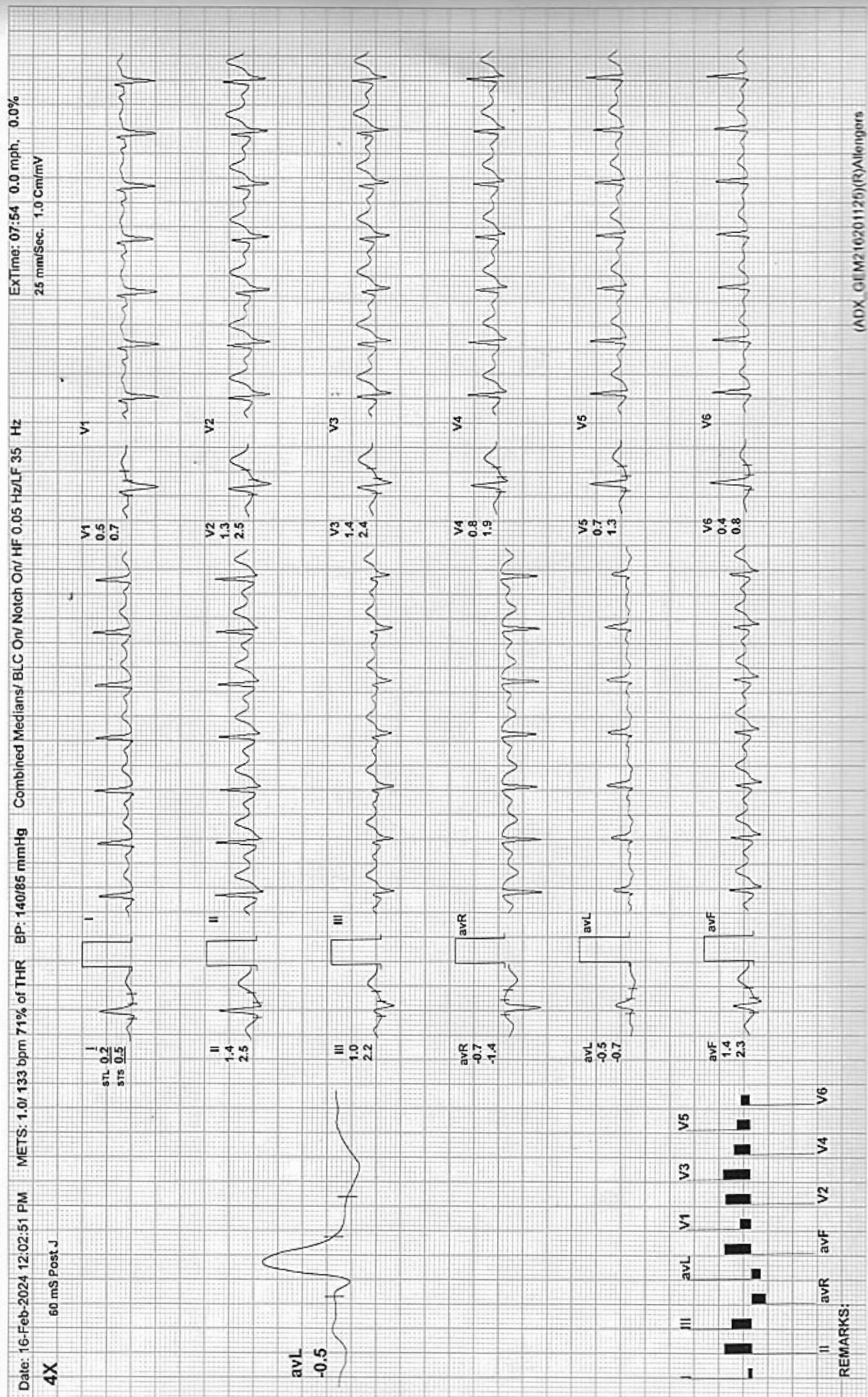
537 / ROHIT KUMAR / 32 Yrs / M / 0 Cms / 0 Kg / HR : 144



ARAVALI HOSPITAL

537 / ROHIT KUMAR / 32 Yrs / M / 0 Cms / 0 Kg / HR : 133

Recovery(4:51)



Rate 75 . Age not entered, assumed to be 50 years old for purpose of ECG interpretation
 . Sinus rhythm.....normal P axis, V-rate 50- 99
 . Abnormal R-wave progression, early transition.....QRS area>0 in V2

PR 120
 QRSD 89
 QT 350
 QTc 391

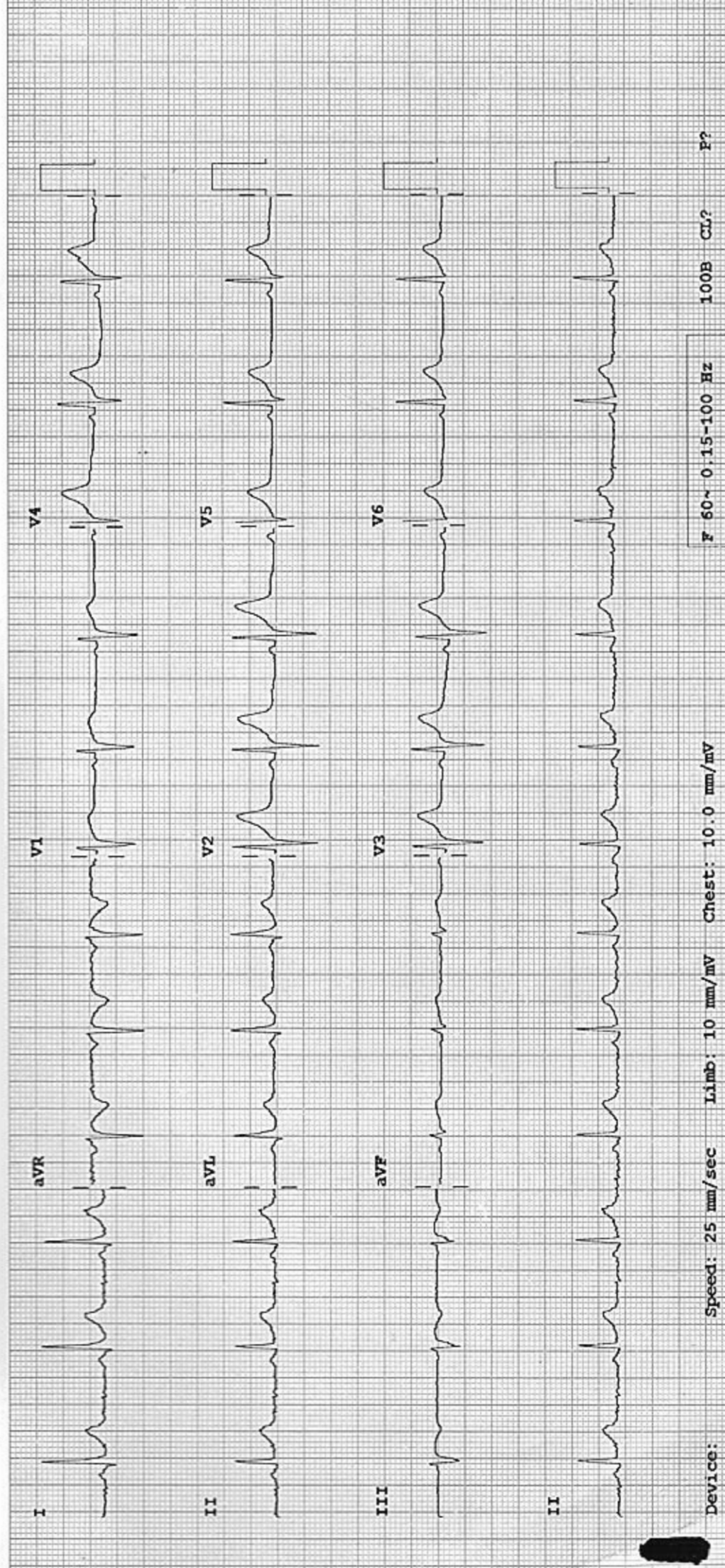
--AXIS--

P 17
 QRS 8
 T 24

12 Lead; Standard Placement

- OTHERWISE NORMAL ECG -

Unconfirmed Diagnosis





Aravali Hospital

332, Ambamata Scheme, Udaipur - 313 004
T: 91 294 2430222, 2431222
email : aravalihospital@yahoo.com



गुणवत्ता पूर्ण चिकित्सा सेवाओं के लिये
भारत सरकार की
क्वालिटी काउंसिल ऑफ इण्डिया (QCI-NABH)
द्वारा प्रमाणित

Date : 16/02/2024			
Patient's Name :	MR ROHIT KUMAR	Age: 31 yrs	Sex: Male
Ref. By :	Dr. Y.K.BOLYA (MD)		

ULTRA SONOGRAPHY REPORT - UPPER AND LOWER ABDOMEN

Liver	Liver is mildly enlarged and reveals bright echotexture. No focal lesion is noted in liver parenchyma. IHBR are not dilated. Portal vein measures 12 mm.
Gall bladder	GB is normal in size & shape. Its wall thickness is normal. No evidence of any calculi is seen. No pericholecystic fluid collection is seen.
Pancreas	Pancreas is normal in size, shape, position & contour with normal homogenous echopattern. Pancreatic duct is not dilated.
Spleen	Spleen is normal in size, shape, position and contour with normal homogenous echopattern. Splenic vein is not dilated.
Kidneys	Both kidneys are normal in size, shape, position & contour with well differentiated corticomedullary junction and normal cortical thickness. Pelvicalyceal system is not dilated. No evidence of any calculi is seen. Visualized portion of ureters appears normal. Right kidney measures 101x47 mm. Left kidney measures 97x45 mm.
Urinary Bladder	Urinary bladder is well distended with urine & is normal in size, shape & contour with normal & smooth walls.
Prostate	Prostate is normal in size, shape, position & contour with normal homogenous echo pattern. It reveals normal & smooth capsule. Seminal vesicles are normal.
Prostate	Prostate is normal in size, shape, position & contour with normal homogenous echo pattern. It reveals normal & smooth capsule. Seminal vesicles are normal. Prostate measures 31x25x24 mm ,Vol- 09 cc

IMPRESSION Mild Fatty liver

Dr. SURESH CHANDRA BASER
MBBS,MD
Consultant Radiologist
(RMC-7219)

Dr. ANAND GUPTA
MBBS,DMRE
Consultant Radiologist
(RMC-17548)

Note: The foetal gender has not been detected nor disclosed to the patient.
This report is not valid for medico legal purpose.
Every report needs to be correlated and interpreted clinically.
In case of any query, investigation may be repeated.

Helpline : 9352 108 108

www.aravalihospital.in



R

ROHIT KUMAR 31YRS BOB M CHEST PA 16-Feb-24 09:33 AM
ARAVALI HOSPITAL, 332 AMBAMATA SCHEME, UDAIPUR

 भारत सरकार
GOVERNMENT OF INDIA



रोहित कुमार
Rohit Kumar
जन्म तिथि/DOB: 10/09/1992
पुरुष / MALE



7752 8262 1994

मेरा आधार, मेरी पहचान

 भारतीय विशिष्ट पहचान प्राधिकरण
UNIQUE IDENTIFICATION AUTHORITY OF INDIA

पता:
हरपवरूप सिंह, बी- 262,
निकट नया अशोक नगर
पोलीस स्टेशन, कोंडली,
कोंडली, पूर्वी दिल्ली,
दिल्ली - 110096

Address:
S/O, Harshwarup Singh, B-262,
Near New Ashok Nagar Police
Station, Kondli, Kondli, East
Delhi,
Delhi - 110096

7752 8262 1994

MEERA AADHAAR, MERI PEHACHAN

Rohit Kumar