



Creating life in
samples



Pathology Department

Patient's name : DIMPAL BHARGAV
Age/Sex : 21 Years/Female
Referred by : MEDI WHEEL
Collection Time : 09:55

Reg. ID : P-6845-23
Accession : 24674
Order Dt/time : 23/03/2024 09:55

Complete Blood Count

Sample Type: EDTA

Test Name	Result	Units	Biological Reference Interval
Blood Counts			
Haemoglobin :	11.3	Gms%	12.5 - 16.0
Total R.B.C. :	4.32	mill/c.mm	4.2 - 5.4
Total W. B. C. :	6400	/cu mm	4000 - 10500
Platelet Count :	252000	/cu.mm	1,50,000 - 4,50,000
Differential Count			
Neutrophils :	55	%	40 - 70
Lymphocytes :	40	%	20 - 40
Eosinophils :	03	%	1 - 4
Monocytes :	02	%	2 - 6
Basophils :	00	%	0 - 01
Blood Indices			
P. C. V :	35.7	%	37 - 47
M. C. V. :	82.5	fl	78 - 100
M.C.H :	26.2	pg	27 - 31
M. C. H. C :	31.8	%	32 - 36
R.D.W :	13.5	%	11.5 - 14.0

E.S.R.(Westergren Method)

After one hour : 08 mm/hr 3 - 12

TESTS DONE ON FULLY AUTOMATED HEMATOLOGY ANALYZER.

Dr. Gayatri M. Mehta
M. D. (Patho)
Reg. No. G-32215

DR GAYATRI MEHTA
MD(PATHOLOGY)

DR. ANAND D. PARIKH
MD(PATHOLOGY)

LAB USE ONLY (Entered by :GM Enter Date/Time:23/03/2024 5:58:00 PM) (Verify by :GM Verify Date/Time:23/03/2024 5:58:00 PM)



Vidhi Diagnostics | Pathology Department

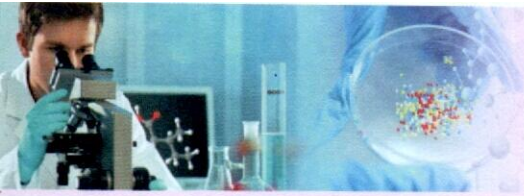L-86, Swatantra Senani Nagar, Opp. Akhbarnagar Petrol Pump, Nr. Akhbarnagar Circle, Nava-Vadaj, Ahmedabad - 380 013.

M. - Pathology : 8849893954, Ph. : 079-27621406, M. 98799 29406, 98250 09406, E-mail : vidhidiagnostics@gmail.com, Web. : www.vidhidiagnostics.com

Time (Pathology) : Mon. to Sat. 8.30 am to 8.00 pm, Sunday 9 am to 12 Noon

Pathology means science behind medicine

CT SCAN & CBCT FACILITY NOW AVAILABLE



Creating Life in Changes



Pathology Department

Patient's name	: DIMPAL BHARGAV	Reg. ID	: P-6845-23
Age/Sex	: 21 Years/Female	Accession	: 24674
Referred by	: MEDI WHEEL	Order Dt/time	: 23/03/2024 09:55
Collection Time	: 09:55		

Blood Group

Sample Type: EDTA sample.

Test Name	Result
BG :	" A "
RH :	POSITIVE
Remarks	Done by forward grouping method.

Blood Glucose

Sample Type: Serum

Test Name	Result	Units	Biological Reference Interval
Fasting Blood Glucose :	91.6	mg/dl	70 - 110
Urine Sugar :	NIL		Absent
<i>GOD-POD Method.</i>			

Blood Glucose

Sample Type: Serum

Test Name	Result	Units	Biological Reference Interval
Post Prandial Blood Glucose After 2hr. :	89.8	mg/dl	80 - 140
Urine Sugar :	NIL		Absent
<i>GOD-POD Method.</i>			

Dr. Gayatri M. Mehta

M. D. (Patho)

Reg. No. G-32215

DR GAYATRI MEHTA
MD(PATHOLOGY)

DR. ANAND D. PARIKH
MD(PATHOLOGY)

LAB USE ONLY (Entered by :GM Enter Date/Time:23/03/2024 6:38:00 PM) (Verify by :GM Verify Date/Time:23/03/2024 6:38:00 PM)



Vidhi Diagnostics | Pathology Department

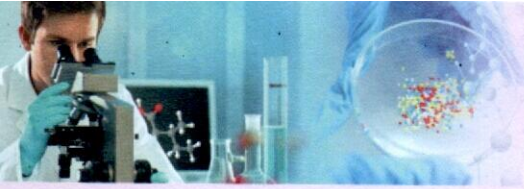L-86, Swatantra Senani Nagar, Opp. Akhbarnagar Petrol Pump, Nr. Akhbarnagar Circle, Nava-Vadaj, Ahmedabad - 380 013.

M. - Pathology : 8849893954, Ph. : 079-27621406, M. 98799 29406, 98250 09406, E-mail : vidhidiagnostics@gmail.com, Web. : www.vidhidiagnostics.com

Time (Pathology) : Mon. to Sat. 8.30 am to 8.00 pm, Sunday 9 am to 12 Noon

Pathology means science behind medicine

CT SCAN & CBCT FACILITY NOW AVAILABLE



Creating life in Gujarat



Pathology Department

Patient's name : DIMPAL BHARGAV
 Age/Sex : 21 Years/Female
 Referred by : MEDI WHEEL
 Collection Time : 09:55

Reg. ID : P-6845-23
 Accession : 24674
 Order Dt/time : 23/03/2024 09:55

HbA1C

Sample Type: EDTA

Test Name	Result	Units	Biological Reference Interval
HbA1C :	5.0	%	Non-diabetic: 4.2-6.2 Pre-diabetic : 6.3-7.2 Diabetic : 7.3-8.2
Mean Blood Glucose of Last 03 months.	96.8	mg/dl	

Comment

*As per the new 2009 update of American Diabetes Association regarding HbA1C & Mean Blood Glucose relationship.

NOTE:

This test is used to monitor diabetic patients compliance with the therapeutic regimen and logo It's level is proportional to both the average blood glucose concentration and the life span of the red blood cells (RBC) in circulation. HbA1c values are free of day to day glucose fluctuations and are unaffected by exercise or recent food intake.

Dr. Gayatri M. Mehta
 M. D. (Patho)
 Reg. No. G-32215

DR GAYATRI MEHTA
 MD(PATHOLOGY)

DR. ANAND D. PARIKH
 MD(PATHOLOGY)

LAB USE ONLY (Entered by :GM Enter Date/Time:23/03/2024 6:37:00 PM) (Verify by :GM Verify Date/Time:23/03/2024 6:37:00 PM)



Vidhi Diagnostics | Pathology Department

L-86, Swatantra Senani Nagar, Opp. Akhbarnagar Petrol Pump, Nr. Akhbarnagar Circle, Nava-Vadaj, Ahmedabad - 380 013.

M. - Pathology : 8849893954, Ph. : 079-27621406, M. 98799 29406, 98250 09406, E-mail : vidhidiagnostics@gmail.com, Web. : www.vidhidiagnostics.com

Time (Pathology) : Mon. to Sat. 8.30 am to 8.00 pm, Sunday 9 am to 12 Noon

Pathology means science behind medicine

CT SCAN & CBCT FACILITY NOW AVAILABLE



Patient's name : DIMPAL BHARGAV
Age/Sex : 21 Years/Female
Referred by : MEDI WHEEL
Collection Time : 09:55

Reg. ID : P-6845-23
Accession : 24674
Order Dt/time : 23/03/2024 09:55

Lipid Profile

Sample Type: Serum

Test Name	Result	Units	Biological Reference Interval
S. Cholesterol : Oxidase-esterase method.	132	mg/dl	0 - 200
S. Triglyceride : Enzymatic Colorimetry method	45.7	mg/dL	0 - 200
S. HDL - Cholesterol : Serum by Enzymatic method.	43.9	mg/dL	35 - 65
S. LDL - Cholesterol : Serum by Enzymatic method	78.96	mg/dL	0 - 130
S. VLDL - Cholesterol :	9.14	mg/dL	0 - 30
S. Chole/HDL.Ratio :	3.01		1 - 6
S. LDL / HDL Cholesterol Ratio :	1.8		0 - 3.5

Dr. Gayatri M. Mehta
M. D. (Patho)

DR GAYATRI MEHTA
MD(PATHOLOGY)

Reg No. G-32215

DR. ANAND D. PARIKH
MD(PATHOLOGY)

LAB USE ONLY (Entered by :GM Enter Date/Time:23/03/2024 6:37:00 PM) (Verify by :GM Verify Date/Time:23/03/2024 6:37:00 PM)



Vidhi Diagnostics | Pathology Department

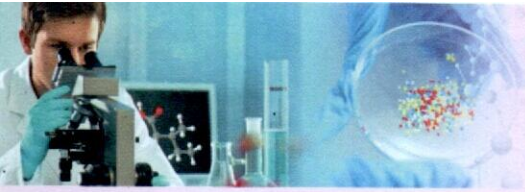L-86, Swatantra Senani Nagar, Opp. Akhbarnagar Petrol Pump, Nr. Akhbarnagar Circle, Nava-Vadaj, Ahmedabad - 380 013.

M. - Pathology : 8849893954, Ph. : 079-27621406, M. 98799 29406, 98250 09406, E-mail : vidhidiagnostics@gmail.com, Web. : www.vidhidiagnostics.com

Time (Pathology) : Mon. to Sat. 8.30 am to 8.00 pm, Sunday 9 am to 12 Noon

Pathology means science behind medicine

CT SCAN & CBCT FACILITY NOW AVAILABLE



Patient's name : DIMPAL BHARGAV
Age/Sex : 21 Years/Female
Referred by : MEDI WHEEL
Collection Time : 09:55

Reg. ID : P-6845-23
Accession : 24674
Order Dt/time : 23/03/2024 09:55

BIOCHEMISTRY

Sample type : Serum

Test Name	Result	Units	Biological Reference Interval
Urea, (Serum by GLDH method) :	16.5	mg/dl	10 - 50
S.Uric acid, (Serum by Uricase method) :	3.7	mg/dl	2.6-6.0
Bun :	7.7	mg/dl	6-20
Creatinine, (Serum by Enzymatic reaction) :	0.62	mg/dl	0.5-1.2
S.G.P.T (ALT) : (Serum by IFCC method) .	13.4	U/L	0 - 40
S.G.O.T (AST) : (Serum by IFCC method)	16.3	U/L	0 - 37
ALK.PHOSPHATASE : (Serum by PNP method)	82	U/L	35-104
G.G.T :	13.2	U/L	8 -78
<u>BILIRUBIN</u>			
Total :	0.39	mg/dl	Up to 1.2
Direct :	0.21	mg/dl	0-0.7
Indirect :	0.18	mg/dl	0 - 0.5
<u>SERUM PROTEINS</u>			
Total Protein (Serum by Biuret method) :	6.60	gms/dl	6.4 - 8.5
Albumin (Serum by BCG method) :	3.98	gms/dl	3.97-4.94
Globulins :	2.62	gms/dl	2.3 - 3.5
A/G Ratio :	1.519		0.9 - 2.9

Dr. Gayatri M. Mehta
M. D. (Patho)

Reg. No. G-32215

DR GAYATRI MEHTA
MD(PATHOLOGY)

DR. ANAND D. PARIKH
MD(PATHOLOGY)

LAB USE ONLY (Entered by :GM Enter Date/Time:23/03/2024 6:37:00 PM) (Verify by :GM Verify Date/Time:23/03/2024 6:37:00 PM)



Vidhi Diagnostics | Pathology Department

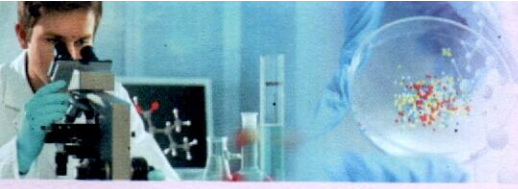L-86, Swatantra Senani Nagar, Opp. Akhbarnagar Petrol Pump, Nr. Akhbarnagar Circle, Nava-Vadaj, Ahmedabad - 380 013.

M. - Pathology : 8849893954, Ph. : 079-27621406, M. 98799 29406, 98250 09406, E-mail : vidhidiagnostics@gmail.com, Web. : www.vidhidiagnostics.com

Time (Pathology) : Mon. to Sat. 8.30 am to 8.00 pm, Sunday 9 am to 12 Noon

Pathology means science behind medicine

CT SCAN & CBCT FACILITY NOW AVAILABLE



Pathology Department



Patient's name : DIMPAL BHARGAV
Age/Sex : 21 Years/Female
Referred by : MEDI WHEEL
Collection Time : 09:55

Reg. ID : P-6845-23
Accession : 24674
Order Dt/time : 23/03/2024 09:55

Thyroid Function Test

Sample Type: Serum

Test Name	Result	Units	Biological Reference Interval
TOTAL T3 :	<u>0.92</u>	ng/ml	1.07 - 1.86
TOTAL T4 :	<u>3.14</u>	µg/dL	6.09 - 12.23
TSH(Ultra sensitive) :	1.47	µIU/mL	0.4001 - 4.049

Dr. Gayatri M. Mehta

M. D. (Patho)

Reg. No. G-32215

DR GAYATRI MEHTA
MD(PATHOLOGY)

DR. ANAND D. PARIKH
MD(PATHOLOGY)

LAB USE ONLY (Entered by :AP Enter Date/Time:23/03/2024 5:39:00 PM) (Verify by :GM Verify Date/Time:23/03/2024 6:04:00 PM)



Vidhi Diagnostics | Pathology Department

L-86, Swatantra Senani Nagar, Opp. Akhbaragar Petrol Pump, Nr. Akhbaragar Circle, Nava-Vadaj, Ahmedabad - 380 013.

M. - Pathology : 8849893954, Ph. : 079-27621406, M. 98799 29406, 98250 09406, E-mail : vidhidiagnostics@gmail.com, Web. : www.vidhidiagnostics.com

Time (Pathology) : Mon. to Sat. 8.30 am to 8.00 pm, Sunday 9 am to 12 Noon

Pathology means science behind medicine

CT SCAN & CBCT FACILITY NOW AVAILABLE



Pathology Department



Patient's name : DIMPAL BHARGAV
Age/Sex : 21 Years/Female
Referred by : MEDI WHEEL
Collection Time : 09:55

Reg. ID : P-6845-23
Accession : 24674
Order Dt/time : 23/03/2024 09:55

Urine Analysis

Sample Type: Urine

Test Name	Result	Units	Biological Reference Interval
Physical Examination			
Quantity :	20	ml	0 - 500 ml
Colour :	Pale Yellow		Pale Yellow
Transparency :	Slight Turbid.		Clear
Reaction :	Acidic		4.6 - 8.0
Specific Gravity :	1.030		1.016 - 1.022
Sediment :	Present		
Chemical Examination			
Albumin :	Present (Faint Trace)		Absent
Sugar :	NIL		Absent
Acetone :	Absent		Absent
Bile Salts :	Absent		Absent
Bile Pigments :	Absent		Absent
Urobilogen :	Absent		Absent
Nitrites :	Absent		Absent
Microscopic Examination			
Red blood Cells :	2-3	/h.p.f	Absent
Pus Cells :	2-3	/h.p.f	Absent
Epithelial Cells :	1-2	/h.p.f	< 10.0
Amorphous :	Absent	/h.p.f	Absent
Bacteria :	Absent	/h.p.f	Absent
Crystals :	Absent	/h.p.f	Absent
Casts :	Absent	/h.p.f	Absent
Fungus :	Not seen	/h.p.f	Absent

Dr. Gayatri M. Mehta
M. D. (Patho)

Reg. No. G-32215

DR GAYATRI MEHTA
MD(PATHOLOGY)



DR. ANAND D. PARIKH
MD(PATHOLOGY)

AB ONLY (Entered by :GM Enter Date/Time:23/03/2024 6:42:00 PM) (Verify by :GM Verify Date/Time:23/03/2024 6:42:00 PM)

Vidhi Diagnostics | Pathology Department

L-86, Swatantra Senani Nagar, Opp. Akhbarnagar Petrol Pump, Nr. Akhbarnagar Circle, Nava-Vadaj, Ahmedabad - 380 013.

M. - Pathology : 8849893954, Ph. : 079-27621406, M. 98799 29406, 98250 09406, E-mail : vidhidiagnostics@gmail.com, Web. : www.vidhidiagnostics.com

Time (Pathology) : Mon. to Sat. 8.30 am to 8.00 pm, Sunday 9 am to 12 Noon

Pathology means science behind medicine

CT SCAN & CBCT FACILITY NOW AVAILABLE





Patient's name : DIMPAL BHARGAV
Age/Sex : 21 Years/Female
Referred by : MEDI WHEEL
Collection Time : 09:55

Reg. ID : P-6845-23
Accession : 24674
Order Dt/time : 23/03/2024 09:55

Stool Examination

Sample Type: Stool

Test Name	Result	Units	Biological Reference Interval
-----------	--------	-------	-------------------------------

PHYSICAL EXAMINATION

Quantity	30 gms
Colour	Brownish yellow
Consistency	Solid
Mucus	Nil
Occult Blood	Negative
Peroxidase Reaction with o-Dianisidine	
Reaction	Acidic
pH Strip Method	

MICROSCOPIC EXAMINATION

Pus Cells	2 - 3/hpf
RBCs	Nil
Vegetable Cells	Absent
Trophozoites	Nil
Cysts	Nil
Ova	Nil
Fat Globules	Nil

----- End Of Report -----

Dr. Gayatri M. Mehta
M. D. (Patho)
No. G-32215

DR GAYATRI MEHTA
MD(PATHOLOGY)

DR. ANAND D. PARIKH
MD(PATHOLOGY)

LAB USE ONLY (Entered by :GM Enter Date/Time:23/03/2024 6:40:00 PM) (Verify by :GM Verify Date/Time:23/03/2024 6:40:00 PM)



Vidhi Diagnostics | Pathology Department


L-86, Swatantra Senani Nagar, Opp. Akhbarnagar Petrol Pump, Nr. Akhbarnagar Circle, Nava-Vadaj, Ahmedabad - 380 013.

M. - Pathology : 8849893954, Ph. : 079-27621406, M. 98799 29406, 98250 09406, E-mail : vidhidiagnostics@gmail.com, Web. : www.vidhidiagnostics.com

Time (Pathology) : Mon. to Sat. 8.30 am to 8.00 pm, Sunday 9 am to 12 Noon

Pathology means science behind medicine

CT SCAN & CBCT FACILITY NOW AVAILABLE



vidhi diagnostics <vidhidiagnostics@gmail.com>

Health Check up Booking Confirmed Request(bobS14132),Package Code-PKG10000475, Beneficiary Code-309963

Mediwheel <wellness@mediwheel.in>
To: vidhidiagnostics@gmail.com
Cc: customercare@mediwheel.in

20 March 2024 at 17:19



Mediwheel
...Your wellness partner

011-41195959

Hi **VIDHI DIAGNOSTICS,**

The following booking has been confirmed. It is requested to honor the said booking & provide priority services to our client

Hospital Package Name : Mediwheel Full Body Health Checkup Female Below 40

Patient Package Name : Mediwheel Full Body Health Checkup Female Below 40

Hospital Address : L-86 Swatantra - Senani Nagar , Opp- Akhbarnagar Bus Terminals, New Wadaj , Ahmedabad -13

Contact Details : 9782228003

Appointment Date : 23-03-2024

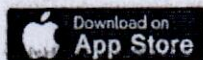Confirmation Status : Booking Confirmed

Preferred Time : 8:00am

Member Information		
Booked Member Name	Age	Gender
Dimpal bhargava	21 year	Female

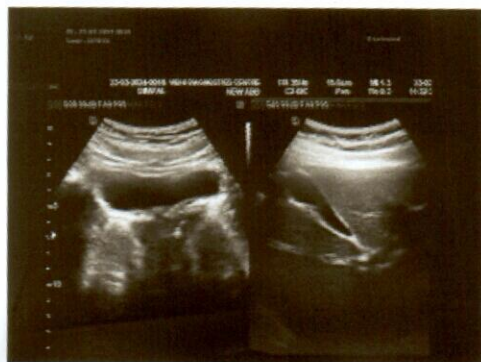
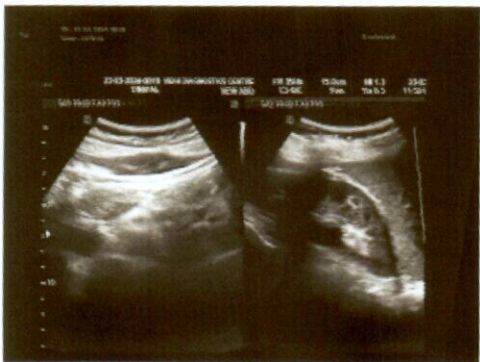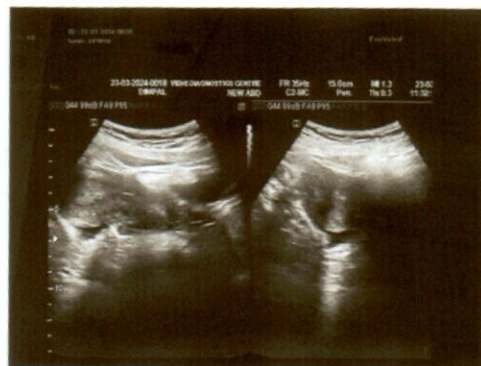
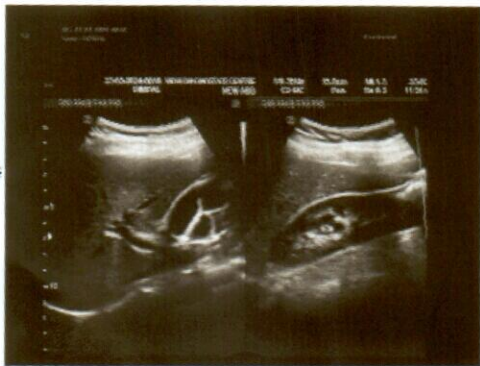We request you to facilitate the employee on priority.

Thanks,
Mediwheel Team
Please Download Mediwheel App

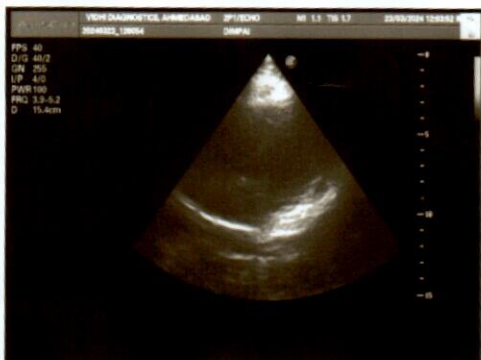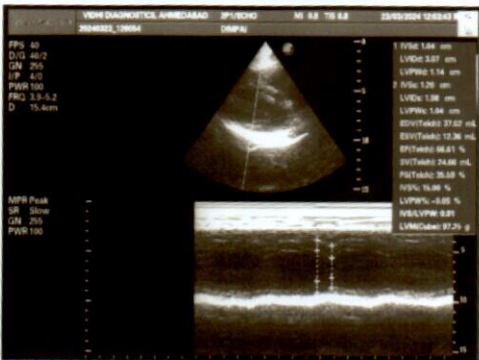
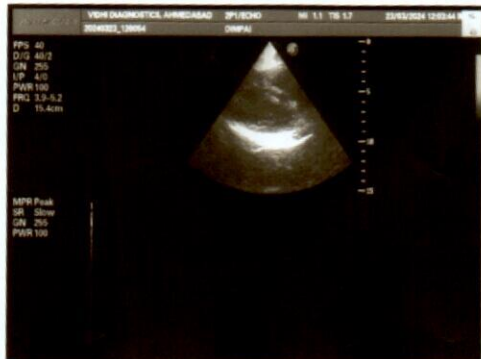

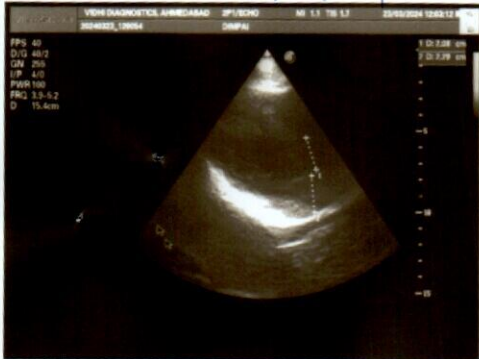
You have received this mail because your e-mail ID is registered with **Arcofemi Healthcare Limited** This is a system-generated e-mail please don't reply to this message.

Diagnosis



D'impeu



Dr. Dinesh S. Modh

M.D., D.M.R.E. (Radiodiagnosis)
Consultant Radiologist & Sonologist
Ex. Junior Lecturer, B.J. Medical College, Civil Hospital, A'bad.



DATE: 23/03/2024		
NAME: Dimpal Bhasgav		
AGE: 27 yrs female		
MEDICAL EXAMINATION:-		
HEIGHT: 164 cm	WEIGHT: 72 kg	
BP: 106/62 mmHg	PULSE: 78 per min	
SPO2: 96	TEMPERATURE: N	
RS: N	CVS: N	
ASYMTOMATIC		
HISTORY: No H/O pm, HTN, Thyroid or TB		
EYE CHECK-UP:-	RIGHT	LEFT
DISTANCE:	Normal 6/6	Normal 6/6
NEAR:	N/G	N/G
COLOR VISION:	Normal	Normal
DENTAL CHECK-UP:	Normal	
ADV: HE/SHE IS MEDICALLY FIT		

Dr. Vidhi D. Modh
MBBS
Reg. No. G-74540

Vidhi Diagnostics
L-86, Swatantra Senani Nagar,
Nr. Akhbarnagar Bus Terminals
Nr. Akhbarnagar Circle,
New Vadaj, Ahmedabad-13.

ISO 9001:2015 Certified Diagnostics Center
Vidhi Imaging Center

L-86, Swatantra Senani Nagar, Opp. Indian Oil Petrol Pump, Akhbarnagar Circle, Nava Vadaj, Ahmedabad - 380 013.
Phone : (Radiology) 079-2762 1406 | M. 98799 29406, 98250 09406 | Time (Radiology) : Mon. to Sat. 9 am to 2 pm, 5 to 9 pm, Sunday 9 am to 12 Noon
E-mail : vidhidiagnostics@gmail.com, Website : www.vidhidiagnostics.com

Multislice CT Scan | CBCT-Dental Scan | Live 3D-4D Sonography | Colour Doppler | Echo Cardiography | Interventional Radiology | Maxillofacial Radiology | Fetal Medicine
Digital X-Ray | Digital Mammography | Digital OPG/TMJ | ECG/TMT/PFT/EEG/EMG | Audiometry | Pathology Laboratory | Health Check Up Plans | Pre Employment Check Up

CT SCAN & CBCT FACILITY NOW AVAILABLE

HR : 79 bpm
 PR : 122 ms
 QRS : 92 ms
 QT/QTc : 364/416 ms
 P/QRS/T : 35/46/-10 deg.
 RV5/SV1 : 0.811/-0.760 mv
 RV5+SV1 : 1.571 mv

** borderline ECG **
 Sinus rhythm
 Nonspecific T wave abnormality

ID: 13201

Name: dimpal bhrgav

Age: 21yrs

Sex: Female

Hospital: **Dr. Avinash Bhargava**

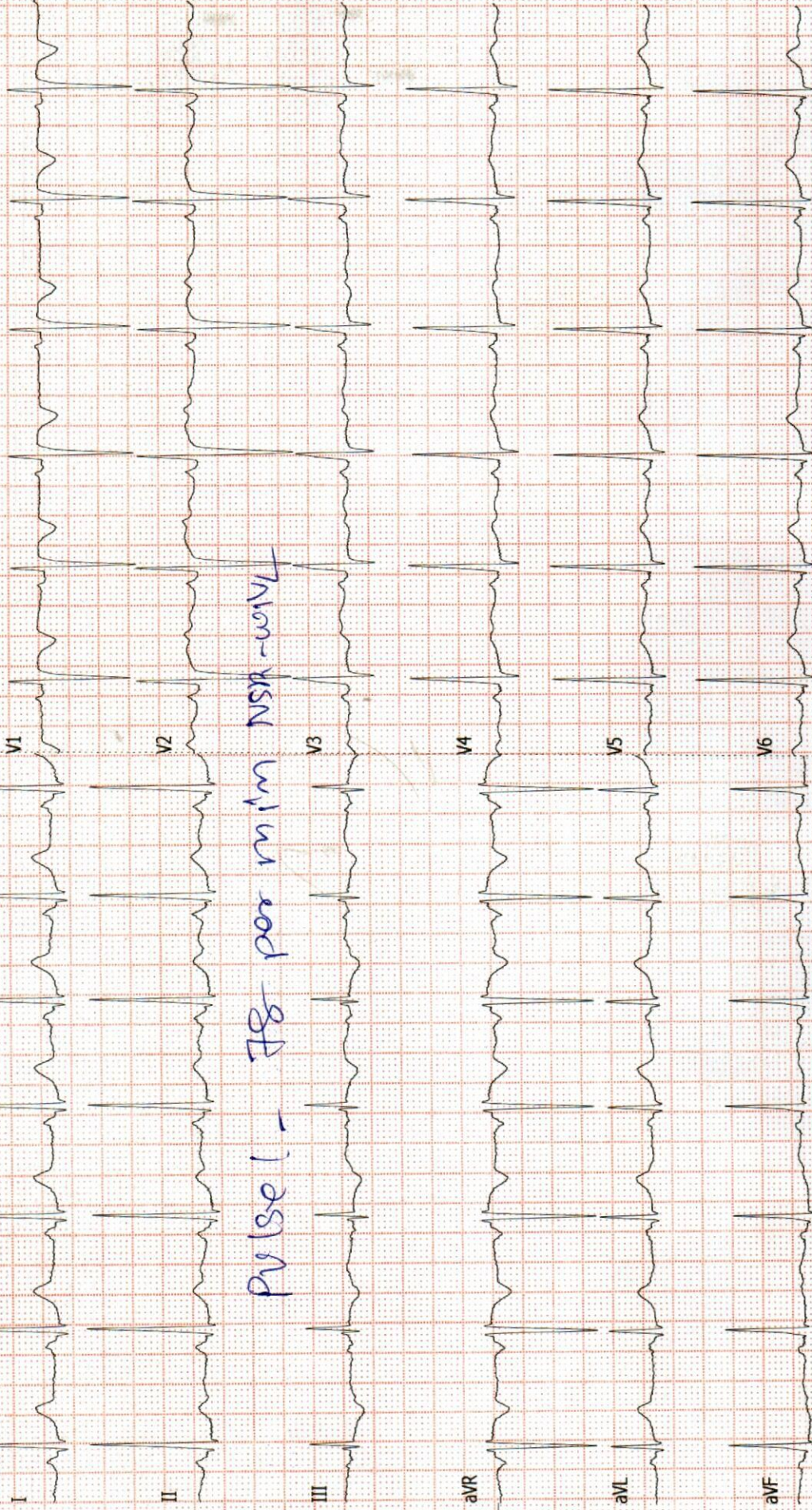
Department: Reg. No. G-45946

Vidhi Diagnostics

L-86, Swatantra-Sonani Nagar,
 Nr. Akhbarnagar Bus Terminals
 Nr. Akhbarnagar Circle,
 New Wadaj, Ahmedabad-13.

Need to be confirmed by doctor. Doctor Name: _____

0.67Hz 35Hz AC 50Hz 25 mm/s 20 mm/mv



Dr. Dinesh S. Modh

M.D., D.M.R.E. (Radiodiagnosis)

Consultant Radiologist & Sonologist

Ex. Junior Lecturer, B.J. Medical College, Civil Hospital, A'bad.



Patient's name: DIMPAL BHARGAV
Reg. ID : R-14855-23
Referred by : Dr. MEDIWHEEL

Age/Sex : 21 Years/Female
Accession : 24714
Date : 23/03/2024

USG ABDOMEN

LIVER: - Liver appears normal in size & show normal echotexture. No evidence of diffuse or focal lesion is seen. Intrahepatic biliary radicals appear normal. Portal vein and CBD appear normal. No e/o calculus is seen in bile duct.

GALL BLADDER: - Gall bladder is distended & appears normal. No evidence of calculus or cholecystitis is seen. No evidence of pericholecystic fluid is seen.

SPLEEN: - Spleen appears normal in size & shows normal echotexture. No evidence of diffuse or focal lesion is seen.

PANCREAS: - Pancreas appears normal size and echopattern. No e/o diffuse or focal lesion is seen. Main pancreatic duct appears normal.

KIDNEY: - Both Kidneys appear normal in size & echotexture.

No e/o calculus or hydronephrosis or hydroureter is seen in either side.

Cortico-medullary differentiation is maintained on either side.

Both suprarenal regions appear normal.

RIF & BOWEL LOOPS (By high frequency probe): - Normal.

No evidence of pre & para aortic lymphadenopathy is seen.

No evidence of free fluid is seen in abdomen.

No evidence of dilated or thickened bowel loops is seen.

Urinary bladder: - appears normal. No e/o calculus or mass lesion is seen in bladder.

Uterus appears normal in size and echopattern.

No evidence of diffuse or focal lesion is seen.

Cervical region appears normal.

Endometrial thickness is 6.4mm.

Both ovaries and adnexal regions appear normal.

No e/o free fluid is seen in pouch of Douglas.

Thanks for reference.


Dr. Dinesh S. Modh
MD DMRE (Radiodiagnosis)
G-23825

DR DINESH S. MODH

M.D. DMRE(RADIODIAGNOSIS)

ISO 9001:2015 Certified Diagnostics Center

Vidhi Imaging Center

L-86, Swatantra Senani Nagar, Opp. Indian Oil Petrol Pump, Akhbarnagar Circle, Nava Vadaj, Ahmedabad - 380 013.

Phone : (Radiology) 079-2762 1406 | M. 98799 29406, 98250 09406 | Time (Radiology) : Mon. to Sat. 9 am to 2 pm, 5 to 9 pm, Sunday 9 am to 12 Noon

E-mail : vidhidiagnostics@gmail.com, Website : www.vidhidiagnostics.com

Multislice CT Scan | CBCT-Dental Scan | Live 3D-4D Sonography | Colour Doppler | Echo Cardiography | Interventional Radiology | Maxillofacial Radiology | Fetal Medicine
Digital X-Ray | Digital Mammography | Digital OPG/TMJ | ECG/TMT/PFT/EEG/EMG | Audiometry | Pathology Laboratory | Health Check Up Plans | Pre Employment Check Up

CT SCAN & CBCT FACILITY NOW AVAILABLE

Dr. Dinesh S. Modh

M.D., D.M.R.E. (Radiodiagnosis)

Consultant Radiologist & Sonologist

Ex. Junior Lecturer, B.J. Medical College, Civil Hospital, A'bad.



Patient's name: DIMPAL BHARGAV
Reg. ID : R-14855-23
Referred by : Dr. MEDIWHEEL

Age/Sex : 21 Years/Female
Accession : 24714
Date : 23/03/2024

X-RAY CHEST (PA VIEW)

Both lung fields appear normal.
No e/o consolidation or cavitations is seen.
Both costo-phrenic angles appear clear.
Cardiac size is within normal limits.
Both domes of diaphragm appear normal.
Bony thoracic cage appears normal.

Thanks for reference.


Dr. Dinesh S. Modh
MD DMRE (Radiodiagnosis)
G-23825
DR DINESH S. MODH
M.D. DMRE(RADIODIAGNOSIS)

ISO 9001:2015 Certified Diagnostics Center

Vidhi Imaging Center

L-86, Swatantra Senani Nagar, Opp. Indian Oil Petrol Pump, Akhbarnagar Circle, Nava Vadaj, Ahmedabad - 380 013.

Phone : (Radiology) 079-2762 1406 | M. 98799 29406, 98250 09406 | Time (Radiology) : Mon. to Sat. 9 am to 2 pm, 5 to 9 pm, Sunday 9 am to 12 Noon

E-mail : vidhidiagnostics@gmail.com, Website : www.vidhidiagnostics.com

Multislice CT Scan | CBCT-Dental Scan | Live 3D-4D Sonography | Colour Doppler | Echo Cardiography | Interventional Radiology | Maxillofacial Radiology | Fetal Medicine
Digital X-Ray | Digital Mammography | Digital OPG/TMJ | ECG/TMT/PFT/EEG/EMG | Audiometry | Pathology Laboratory | Health Check Up Plans | Pre Employment Check Up

CT SCAN & CBCT FACILITY NOW AVAILABLE

Dr. Dinesh S. Modh

M.D., D.M.R.E. (Radiodiagnosis)

Consultant Radiologist & Sonologist

Ex. Junior Lecturer, B.J. Medical College, Civil Hospital, A'bad.



Patient's name : DIMPAL BHARGAV
Reg. ID : R-14855-23
Referred by : Dr. MEDIWHEEL

Age/Sex : 21 Years/Female
Accession : 24714
Date : 23/03/2024

2D- ECHO REPORT

FINAL CONCLUSION:

LV IS NORMAL SIZE. GOOD LV SYSTOLIC FUNCTION NO RWMA.
LVEF - 60%. NO CONCENTRIC LVH.
NORMAL LV COMPLIANCE.
LA IS NORMAL SIZE. NO LA CLOT.
RV IS NORMAL SIZE. GOOD RV SYSTOLIC FUNCTION.
RA IS NORMAL SIZE.
MITRAL VALVE IS NORMAL. NO MS. NO MR. NO MVP.
AORTIC VALVE IS NORMAL. NO AS. NO AR.
TRICUSPID VALVE IS NORMAL. NO TR. RVSP-18mmHg. NO PAH.

NO CLOT, NO VEGETATION, NO PERICARDIAL EFFUSION.

DIMENSIONS:

AORTA	2.2 C.M
LEFT ATRIUM	2.4 C.M
LVDD	4.0 C.M.
IVSD	1.0 C.M
PWD	1.0 C.M
LVDS	2.6 C.M.

COLOUR DOPPLER FINDING:

STRUCTURE	VELOCITY m/sec
	Max
PULMONARY VALVE	0.8
MITRAL VALVE	E : 0.5 A: 0.4
AORTIC VALVE	1.1

Dr. Avinash Bhaskar
Dr. Avinash Bhaskar
MBBS, D Cardio
Reg. No. : G-45946
DR AVINASH BHASKAR
CLINICAL CARDIOLOGIST
9924836431

ISO 9001:2015 Certified Diagnostics Center

Vidhi Imaging Center

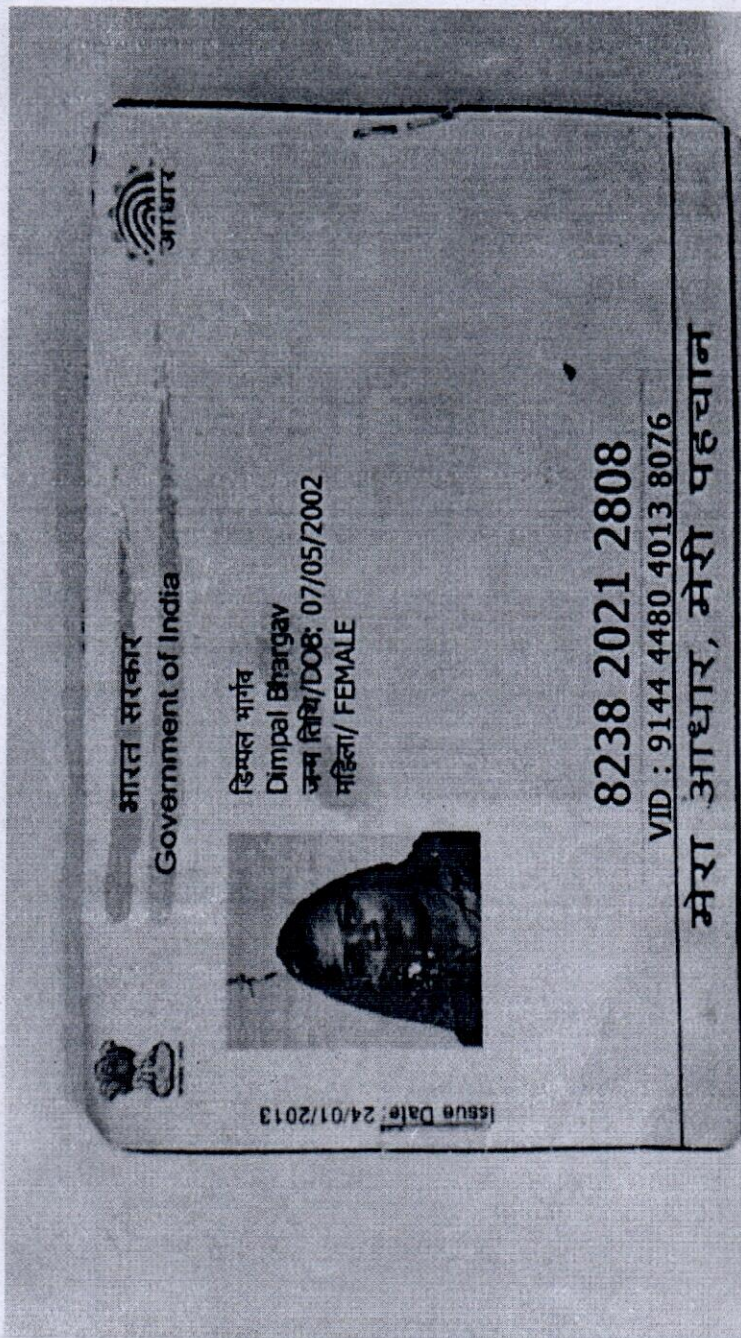
L-86, Swatantra Senani Nagar, Opp. Indian Oil Petrol Pump, Akhbarnagar Circle, Nava Vadaj, Ahmedabad - 380 013.

Phone : (Radiology) 079-2762 1406 | M. 98799 29406, 98250 09406 | Time (Radiology) : Mon. to Sat. 9 am to 2 pm, 5 to 9 pm, Sunday 9 am to 12 Noon

E-mail : vidhidiagnostics@gmail.com, Website : www.vidhidiagnostics.com

Multislice CT Scan | CBCT-Dental Scan | Live 3D-4D Sonography | Colour Doppler | Echo Cardiography | Interventional Radiology | Maxillofacial Radiology | Fetal Medicine
Digital X-Ray | Digital Mammography | Digital OPG/TMJ | ECG/TMT/PFT/EEG/EMG | Audiometry | Pathology Laboratory | Health Check Up Plans | Pre Employment Check Up

CT SCAN & CBCT FACILITY NOW AVAILABLE



Vidhi Diagnostics
L-86, Swatantra-Senani Nagar,
Nr. Akharnagar Bus Terminals
New Wadaj, Ahmedabad-13.