



CITI MULTI SPECIALITY HOSPITAL

MIG -215 216, Gautam Nagar, Govindpura, Bhopal-462023 (M.P.)
Phone No. : 0755 - 4250134
Mobile No. : 7771008660, 8319214664, 9303135719



NAME - MRS, GARIMA

AGE - 27Y/F

REF: BY-APOLLO CLINIC

DATE- 29/03/24

2D- ECHO COLOUR DOPPLER EVALUATION:-

- ❖ Normal great vessel relationship
- ❖ ALL cardiac valve are normal
- ❖ Normal Four chambered heart
- ❖ Normal LV size with normal LV function LVEF- 85%
- ❖ No intracardiac shunt
- ❖ No LV thrombus or clot seen
- ❖ No Pericardium effusion
- ❖ FINAL IMPRESSION
- ❖ Normal LV size with normal LV function LVEF- 85%


DR. S. S. GUPTA (M.D.)

CONSULTANT ECHOCARDIOLOGIST

Empanelled with : State Government, M.P. Police, ESIC, HPCL, Punjab National Bank, Indian Bank
Food Corporation of India, Ayushman Bharat



CITI MULTI SPECIALITY HOSPITAL
MIG-215-216 GAUTAM NAGAR GOVINDPURA, BHOPAL
MOB-7987913713

Name: MRS GARIMA 27Y
Birthdate:
Perf.Physician:

Patient Id: 290324-115628
Sex: Female
Ref.Physician:

Date: 29/03/2024
Accession #:
Operator: ADM

M-MODE & PW

D-E Excursion	1.23 cm
E-F Slope	0.12 m/s
EPSS	0.43 cm
Ao Diam	2.25 cm
LA Diam	2.14 cm
AV Cusp	0.96 cm
LA/Ao	0.95
Ao/LA	1.05
RVIDd	2.19 cm
IVSd	0.59 cm
LVIDd	3.80 cm
LVPWd	0.86 cm
IVSs	1.02 cm
LVIDs	1.77 cm
LVPWs	0.91 cm
EDV(Teich)	61.93 ml
ESV(Teich)	9.25 ml
EF(Teich)	85.06 %
%FS	53.52 %
SV(Teich)	52.67 ml
Time	737.02 ms
HR	81 BPM
CO(Teich)	0.00 l/min

Print Date: 3/29/2024





CITI MULTI SPECIALITY HOSPITAL

MIG -215 216, Gautam Nagar, Govindpura, Bhopal-462023 (M.P.)
Phone No. : 0755 - 4250134
Mobile No. : 7771008660, 8319214664, 9303135719



Name of Patient : MRS.GARIMA
Age/Sex : 27YEAR/F
Date : 29/03/24

USG ABDOMEN

Liver : The liver is normal in size, shape, and normal in echogenecity. No intra hepatic biliary radical dilation seen.

Gall Bladder : Gall bladder Normal in size, shape and echotexture.

Spleen . Normal in size, shape and echotexture.

Kidneys : Both the kidneys are normal in size, shape,axis and position. Cortico medullary differentiation are both kidney fine concretion .

Urinary bladder : Suspicious shadow seen in bladder needs further evaluation

Uterus & Ovaries: Normal in size, shape and echotexture

Pancreas : Normal in size, shape and echotexture.

IVC & ABDOMINAL AORTA:-IVC and abdominal aorta are normal.

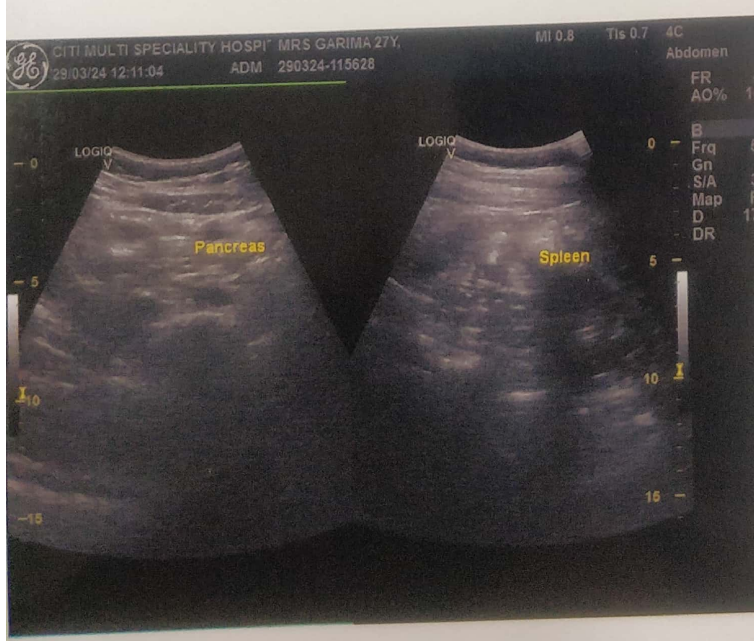
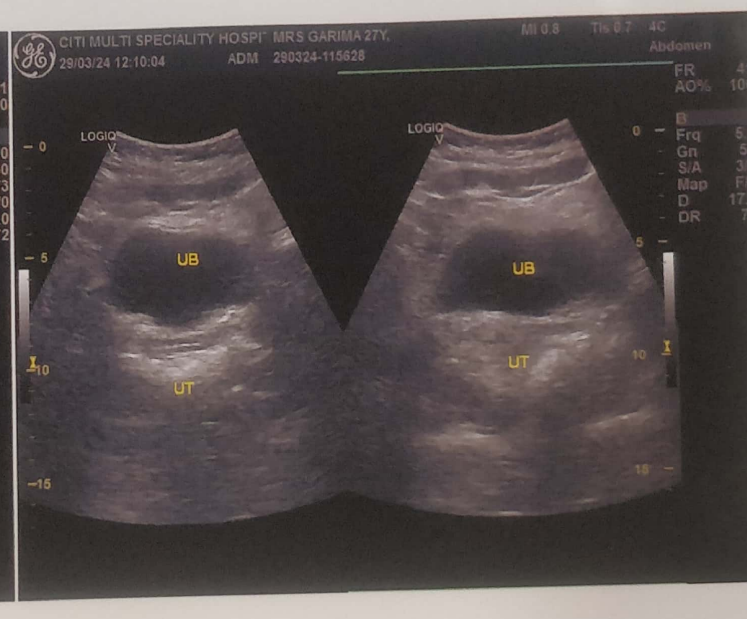
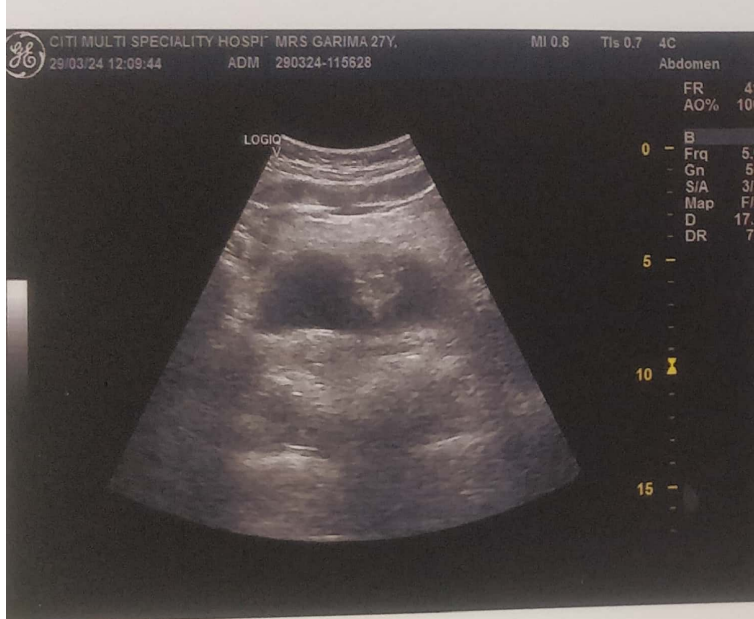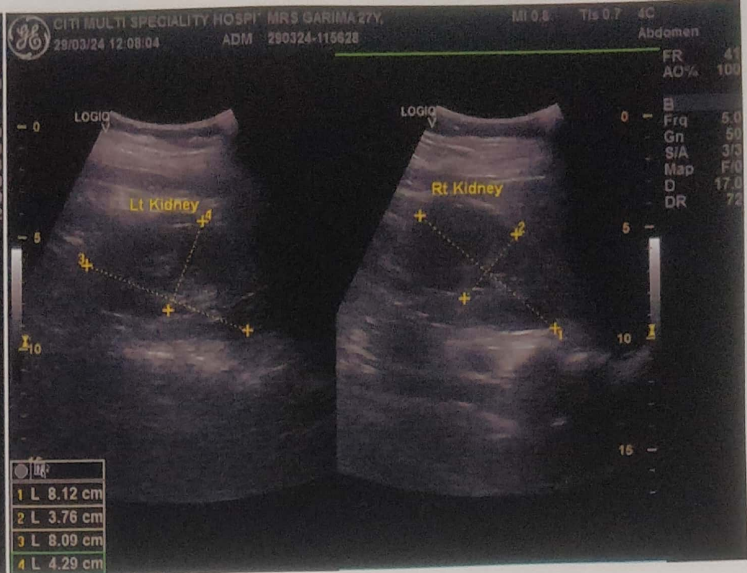
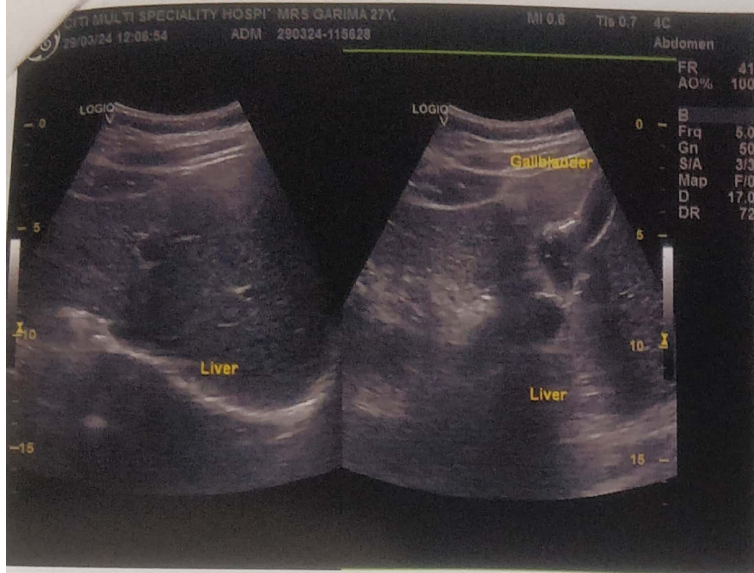
Retroperitoneum: No lymphadenopathy seen. No free fluid or ascites seen.

IMPRESSION:

Suspicious shadow seen in bladder needs further evaluation


CONSULTANT RADIOLOGIST

Empanelled with : State Government, M.P.Police, ESIC, HPCL, Punjab National Bank, Indian Bank
Food Corporation of India, Ayushman Bharat





CITI MULTI SPECIALITY HOSPITAL

MIG -215 216, Gautam Nagar, Govindpura, Bhopal-462023 (M.P.)
Phone No. : 0755 - 4250134
Mobile No. : 7771008660, 8319214664, 9303135719



Carima - pathology
27/10

29-3-2024

elb
no, complaint
in eye



ole

VA { R.E. = HAD
L.E. = HAD

no, any-any fresh complaint
in both-eye.

no, water-discharge. in eye

no, clear-discharge. vision
in both-eye, clear vision
in clear

Empanelled with : State Government, M.P. Police, ESIC, HPCL, Punjab National Bank, Indian Bank
Food Corporation of India, Ayushman Bharat

381 - MRS. GARIMA SHUKLA

27 Years / Female / Ht 156 Cms / 56 Kgs / Non-Smoker

FVC TEST

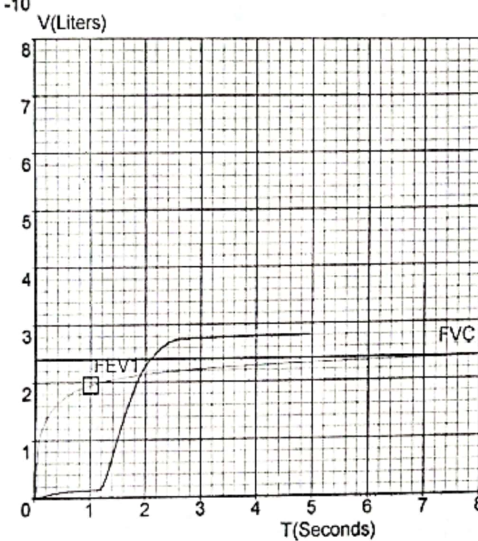
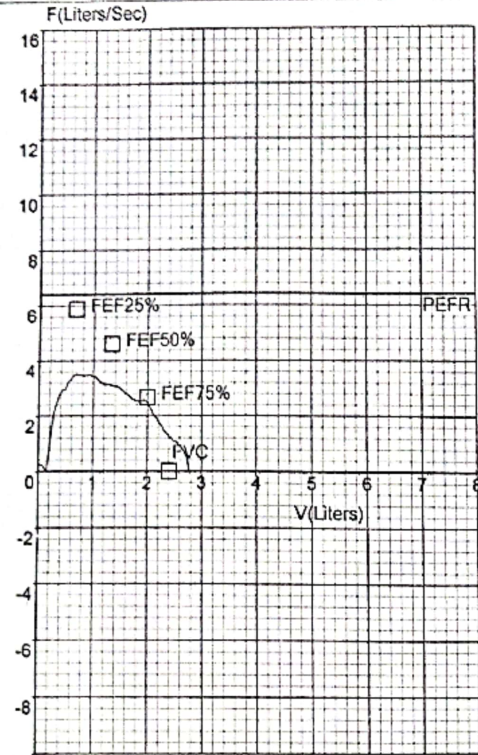
Date: 29-03-2024 (T1)

Pred Eqn : CLARITY

Eth.Corr : 100

Temp : 36°C

Ref By : NONE



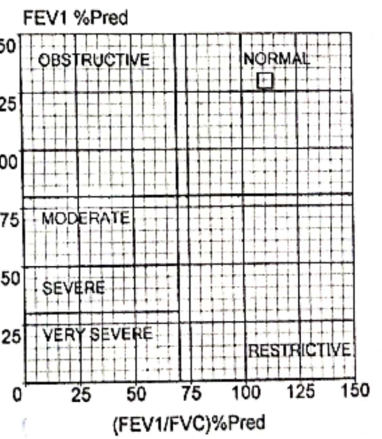
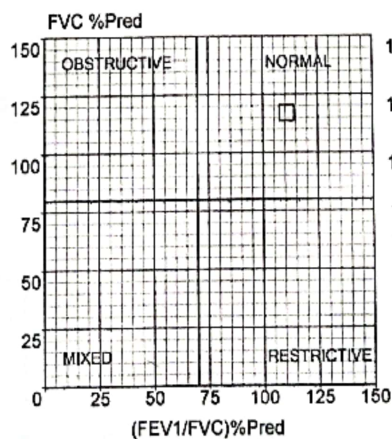
Parameter	Pred	Pre	Pre%	Post	Post%	Imp%
FVC [L]	2.40	2.81	117	--	--	--
FEV1 [L]	1.95	2.53	130	--	--	--
FEV.5 [L]	--	1.70	--	--	--	--
FEV3 [L]	2.33	--	--	--	--	--
FEV6 [L]	--	--	--	--	--	--
PEFR [L/s]	6.39	3.51	55	--	--	--
FEF25-75 [L/s]	2.94	2.96	101	--	--	--
FEF75-85 [L/s]	--	1.66	--	--	--	--
FEF.2-1.2 [L/s]	5.34	3.04	57	--	--	--
FEF25% [L/s]	5.85	3.56	61	--	--	--
FEF50% [L/s]	4.58	3.47	76	--	--	--
FEF75% [L/s]	2.68	2.08	78	--	--	--
FEV.5/FVC [%]	--	60.57	--	--	--	--
FEV1/FVC [%]	81.23	90.03	111	--	--	--
FEV3/FVC [%]	97.00	--	--	--	--	--
FEV6/FVC [%]	--	--	--	--	--	--
FEV1/FEV6 [%]	--	--	--	--	--	--
FET [S]	--	2.75	--	--	--	--
ExptTime [S]	--	1.39	--	--	--	--
LungAge [Y]	27.00	19.00	70	--	--	--
FIVC [L]	--	--	--	--	--	--
PIFR [L/s]	--	--	--	--	--	--
FIF25% [L/s]	--	--	--	--	--	--
FIF50% [L/s]	--	--	--	--	--	--
FIF75% [L/s]	--	--	--	--	--	--
FIV.5 [L]	--	--	--	--	--	--
FIV1 [L]	--	--	--	--	--	--
FIV3 [L]	--	--	--	--	--	--
FIV.5/FIVC [%]	--	--	--	--	--	--
FIV1/FIVC [%]	--	--	--	--	--	--
FIV3/FIVC [%]	--	--	--	--	--	--

- Pre Medication Report :
Early Small Airway Obstruction. Spirometry within Normal range as FVC% >= 80 And FEV1/FVC% > 70

Sabyasachi Gupta
29-03-24

- Pre COPD Severity Report:
Pre Test within Normal range

- Doctor's Comments : *Normal*

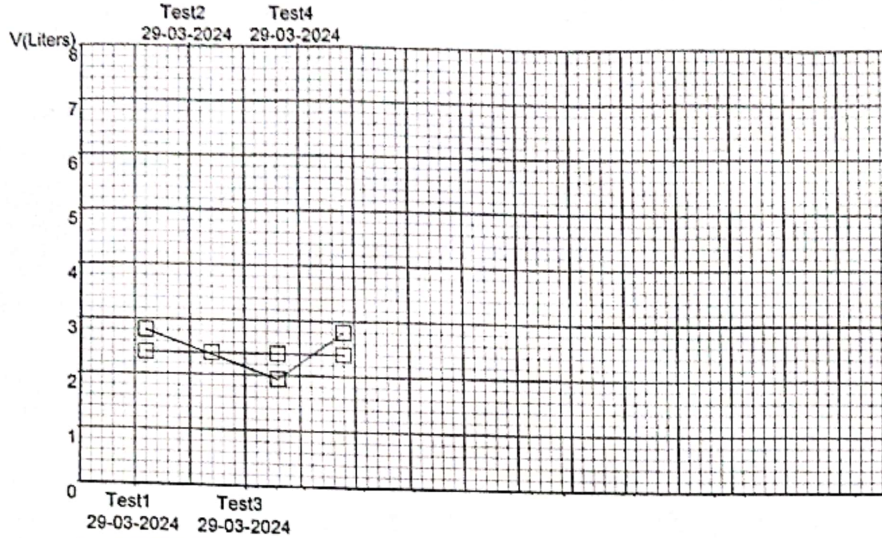


Dr. SABYASACHI GUPTA
MBBS (Gold Medalist), MD (Med.) RCGP (U.K.)
Reg. No. 116
Dr. S.S. GUPTA
MD MEDICINE

381 - MRS. GARIMA SHUKLA
27 Years / Female / Ht 156 Cms / 56 Kgs / Non-Smoker

TRENDS [Pre]
Date: 29-03-2024 (T1)

Pred Eqn : CLARITY Eth.Corr : 100 Temp : 36°C
Ref By : NONE



Parameter	Test1	Test2	Test3	Test4	Test5	Test6	Test7	Test8	Test9	Test10
FVC [L]	2.81	--	1.94	2.81	--	--	--	--	--	--
FEV1 [L]	2.53	--	1.78	2.53	--	--	--	--	--	--
FEV.5 [L]	1.70	--	1.43	1.70	--	--	--	--	--	--
FEV3 [L]	--	--	--	--	--	--	--	--	--	--
FEV6 [L]	--	--	--	--	--	--	--	--	--	--
PEFR [L/s]	3.51	--	4.15	3.51	--	--	--	--	--	--
FEF25-75 [L/s]	2.96	--	2.78	2.96	--	--	--	--	--	--
FEF75-85 [L/s]	1.66	--	1.00	1.66	--	--	--	--	--	--
FEF.2-1.2 [L/s]	3.04	--	3.34	3.04	--	--	--	--	--	--
FEF25% [L/s]	3.56	--	4.20	3.56	--	--	--	--	--	--
FEF50% [L/s]	3.47	--	3.21	3.47	--	--	--	--	--	--
FEF75% [L/s]	2.08	--	1.21	2.08	--	--	--	--	--	--
FEV.5/FVC [%]	60.57	--	73.57	60.57	--	--	--	--	--	--
FEV1/FVC [%]	90.03	--	91.93	90.03	--	--	--	--	--	--
FEV3/FVC [%]	--	--	--	--	--	--	--	--	--	--
FEV6/FVC [%]	--	--	--	--	--	--	--	--	--	--
FEV1/FEV6 [%]	--	--	--	--	--	--	--	--	--	--
FET [S]	2.75	--	1.64	2.75	--	--	--	--	--	--
ExpiTime [S]	1.39	--	0.09	1.39	--	--	--	--	--	--
LungAge [Y]	19.00	--	29.00	19.00	--	--	--	--	--	--
FIVC [L]	--	--	--	--	--	--	--	--	--	--
PIFR [L/s]	--	--	--	--	--	--	--	--	--	--
FIF25% [L/s]	--	--	--	--	--	--	--	--	--	--
FIF50% [L/s]	--	--	--	--	--	--	--	--	--	--
FIF75% [L/s]	--	--	--	--	--	--	--	--	--	--
FIV.5 [L]	--	--	--	--	--	--	--	--	--	--
FIV1 [L]	--	--	--	--	--	--	--	--	--	--
FIV3 [L]	--	--	--	--	--	--	--	--	--	--
FIV.5/FIVC [%]	--	--	--	--	--	--	--	--	--	--
FIV1/FIVC [%]	--	--	--	--	--	--	--	--	--	--
FIV3/FIVC [%]	--	--	--	--	--	--	--	--	--	--

Dr. SARYASACHI GUPTA
MBBS (Gold Medalist), MD (Med), FRCGP (UK)
Dr. S.S. GUPTA
Reg. No. 110
MD MEDICINE



Clarity Medical Pvt. Ltd.

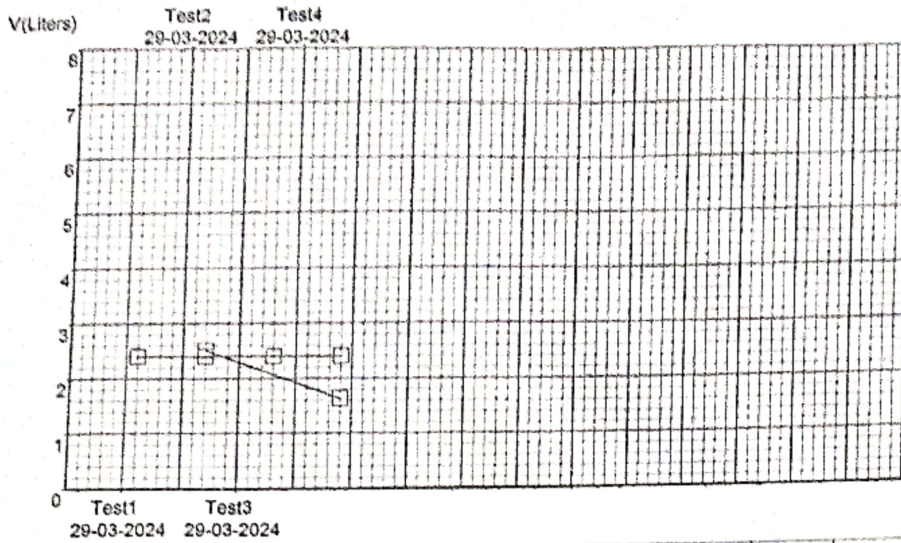
SHIVAM CT Scan And Diagnostic Centre

MIG-215 GUTAM NAGAR GOVINDPURA BHOPAL PHONE 777108660

381 - MRS. GARIMA SHUKLA
27 Years / Female / Ht 156 Cms / 56 Kgs / Non-Smoker

TRENDS [Post]
Date: 29-03-2024 (T1)

Pred Eqn : CLARITY Eth.Corr : 100 Temp : 36°C
Ref By : NONE



Parameter	Test1	Test2	Test3	Test4	Test5	Test6	Test7	Test8	Test9	Test10
FVC [L]	--	2.52	--	1.64	--	--	--	--	--	--
FEV1 [L]	--	2.13	--	1.63	--	--	--	--	--	--
FEV.5 [L]	--	1.17	--	1.36	--	--	--	--	--	--
FEV3 [L]	--	2.13	--	1.63	--	--	--	--	--	--
FEV6 [L]	--	--	--	--	--	--	--	--	--	--
PEFR [L/s]	--	2.29	--	3.94	--	--	--	--	--	--
FEF25-75 [L/s]	--	2.14	--	2.94	--	--	--	--	--	--
FEF75-85 [L/s]	--	1.72	--	1.46	--	--	--	--	--	--
FEF.2-1.2 [L/s]	--	2.07	--	3.08	--	--	--	--	--	--
FEF25% [L/s]	--	2.49	--	4.04	--	--	--	--	--	--
FEF50% [L/s]	--	2.36	--	3.00	--	--	--	--	--	--
FEF75% [L/s]	--	1.85	--	1.73	--	--	--	--	--	--
FEV.5/FVC [%]	--	46.52	--	83.04	--	--	--	--	--	--
FEV1/FVC [%]	--	84.69	--	99.05	--	--	--	--	--	--
FEV3/FVC [%]	--	84.69	--	99.05	--	--	--	--	--	--
FEV6/FVC [%]	--	--	--	--	--	--	--	--	--	--
FEV1/FEV6 [%]	--	--	--	--	--	--	--	--	--	--
FET [S]	--	4.47	--	4.28	--	--	--	--	--	--
ExpTime [S]	--	0.60	--	0.15	--	--	--	--	--	--
LungAge [Y]	--	25.00	--	32.00	--	--	--	--	--	--
FIVC [L]	--	1.97	--	1.53	--	--	--	--	--	--
PIFR [L/s]	--	1.01	--	1.90	--	--	--	--	--	--
FIF25% [L/s]	--	2.25	--	4.11	--	--	--	--	--	--
FIF50% [L/s]	--	2.49	--	3.80	--	--	--	--	--	--
FIF75% [L/s]	--	2.60	--	2.46	--	--	--	--	--	--
FIV.5 [L]	--	0.35	--	0.45	--	--	--	--	--	--
FIV1 [L]	--	0.78	--	1.32	--	--	--	--	--	--
FIV3 [L]	--	--	--	--	--	--	--	--	--	--
FIV.5/FIVC [%]	--	17.86	--	29.42	--	--	--	--	--	--
FIV1/FIVC [%]	--	39.55	--	86.01	--	--	--	--	--	--
FIV3/FIVC [%]	--	--	--	--	--	--	--	--	--	--

Dr. SABYASACHI GUPTA
MBBS (Gold Medalist), MD (Med), DNB (Chest)
Dr. S.S. GUPTA
Reg. No. 116 MD MEDICINE

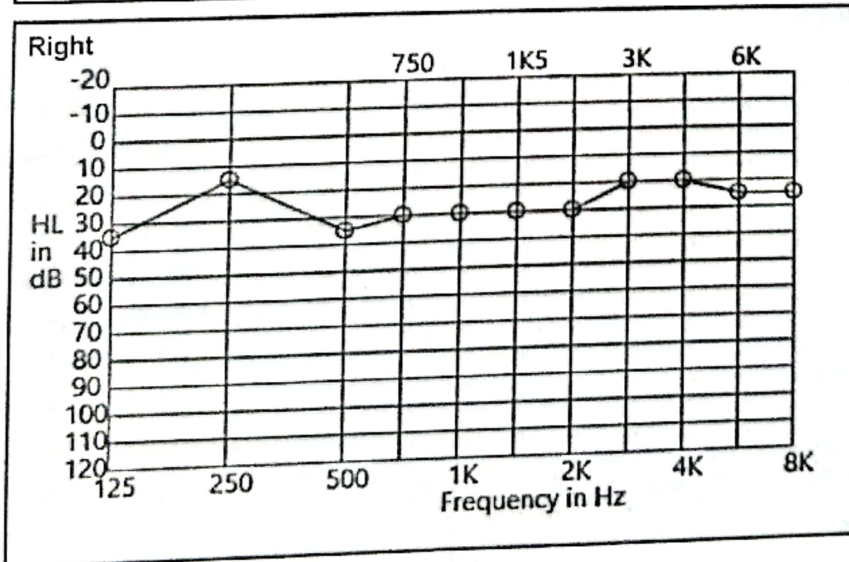
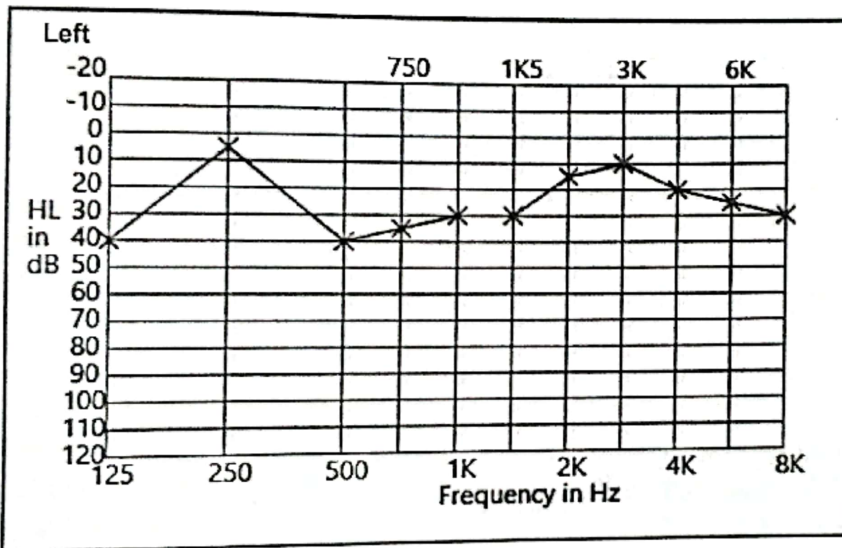
CITI MULTISPECIALITY HOSPITAL

MIG 216. Gautam Nagar

BHOPAL

462023

Name	Case No.	Age	Sex	Phone No.
MRS GARIMA SHUKLA	747	27	Fema	7489788859
Address	Referred By		Date & Time	
MINAL GATE NO 1 BHOPAL	APOLLO CLINIC		29/3/24	



Interpretation

NORMAL HEARING STUDY

Doctor/Audiologist
DR S S GUPTA (MD)

Dr. SBYASACHI GUPTA
MBBS (Gold Medalist), MD (Med.), RCGP (U.K.)
Reg. No. 11671



CITI MULTI SPECIALITY HOSPITAL

MIG -215 216, Gautam Nagar, Govindpura, Bhopal-462023 (M.P.)
Phone No. : 0755 - 4250134
Mobile No. : 7771008660, 8319214664, 9303135719



Patient- Name:	MRS. GARIMA	Age/Sex:	27 Y/F
Referred. By:	INS	Date:	29.03.2024

X-RAY CHEST PA VIEW

- Bilateral Lungs Fields Appear Clear.
- Bilateral Hilar Shadows Appear Clear.
- Bilateral CP Angels Appear Clear.
- Both The Domes Of Diaphragm Appear normal in shape and position.
- Visualized bony cage and soft tissue appear normal.

IMPRESSION

No Significant Abnormality.

Dr. SANJAY..
CONSULTANT RADIOLOGIST

Empanelled with : State Government, M.P.Police, ESIC, HPCL, Punjab National Bank, Indian Bank
Food Corporation of India, Ayushman Bharat



RT

PA

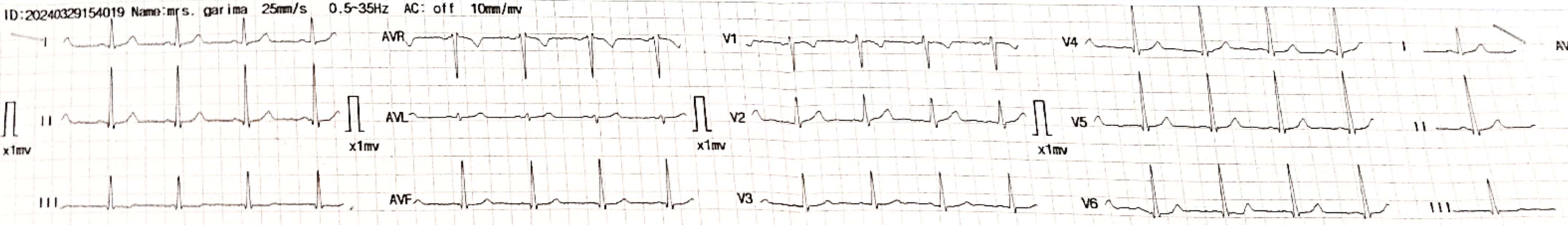
01103

29.03.2024

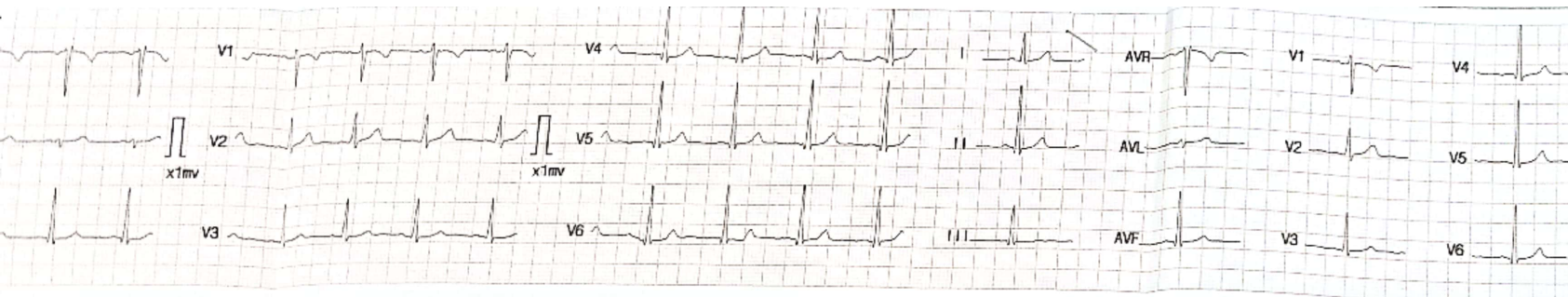
Name: MRS. GARIMA 27 Y/F
Sex: F



ID:20240329154019 Name:mrs. garima 25mm/s 0.5-35Hz AC: off 10mm/mv



Organization:cmh Doctor:DR S S GUPTA



ID : 20240329154019
 Name : mrs. garima
 Sex : Female
 Age : 29
 HR : 85 bpm
 R-R : 708 ms
 P-R : 114 ms
 QRS : 90 ms
 QT/QTc : 349/417 ms
 P/QRS/T : 22/ 60/ 27
 RV5/SV1 : 1.477/-0.713 mV
 RV5+SV1 : 0.764 mV
 QTcF : 0.492

001: Sinus Rhythm
 171: Normal ECG
 Dr. SABIYACHI GUPTA
 MBBS (Gold Medalist) (Med) (ACGP (U.K.))
 Reg. No. 11671
 Reference Report Confirmed by:
[Signature]
 03-29-2024 15:40:38
 29-03-24

CODE BLUE	CODE RED	MS. ADMINISTRATION STAFF NURSE / INCHARGE ICU NURSE / STAFF OPERATION MANAGER / GUARD	CODE BLUE AT "LOCATION" RESPOND IMMEDIATELY
CODE RED	FIRE	MS. OPERATION MANAGER ADMINISTRATOR / GUARD / FLOOR INCHARGE / MAINTENANCE	CODE RED - FIRE DETECTED AT "LOCATION" PLEASE ACTIVATE EMERGENCY RESPONSE TEAM
CODE YELLOW	DISASTER	MS. ADMINISTRATION NURSE OPERATION MANAGER / GUARD MAINTENANCE	
CODE PINK	DISCIPLINARY ACTION	MS. ADMINISTRATION MANAGER / GUARD	
CODE PINK	CHILD ABDUCTION	ADMINISTRATOR / OPERATION MANAGER / GUARD MAINTENANCE	
CODE BLACK	BOMB THREAT	MS. ADMINISTRATION NURSE / OPERATION MANAGER GUARD / MAINTENANCE	

3. Call for help

- Complete annual blood borne pathogen training.

4. Get treated

- Get your hepatitis B vaccines.

5. ID source patient

- Report all sharp related injuries to your supervisor to insure appropriate follow-up

6. Get follow-up exam

For BBPE Program information, contact the office of occupational health and safety

Bhopal, Madhya Pradesh, India

M-216, Janata Quarter Internal Rd, Gautam Nagar Housing Board Colony

Maharana Pratap Nagar, Bhopal, Madhya Pradesh 462016 India

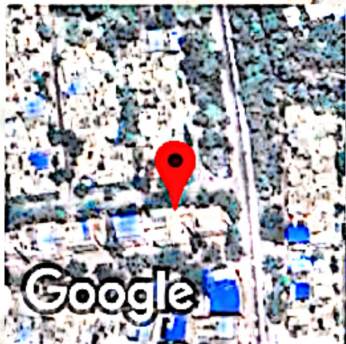
3 235 49°

Long 77 41088°

29/08/24 12:53 PM GMT+05:30



GPS Map Camera



Google



Scanned with OKEN Scanner

