



REVIVAL DIAGNOSTICS

Name	MEERASRI MANIVASAGAM	Age/Gender	29Yrs/Female
Reg No.	1804/24	Receipt No	17335
Referred By	Bank of Baroda (BOB) - MEDI WHEEL()	Mode of Payment	CREDIT
Collection Type	CENTER	Collection DateTime	24-Feb-2024 09:02 AM

PAP SMEAR - 240224204 Released at 01-Mar-2024 10:38 AM

Parameter	Result	Biological Ref.Range	Method
-Pap Smear Report	<p>PAP SMEAR: Specimen Two unstained slides received for pap smear evaluation</p> <p>Gross description Received two unstained slides for pap smear examination.Papanicolou stain done.</p> <p>Microscopic Description Smears are satisfactory for cellularity. Endocervical cells/ Transformation zone squamous metaplastic cells seen. There is presence of many sheets& singly scattered superficial and intermediate cells seen. No parasites/fungi. No evidence of intraepithelial lesion or malignancy.</p> <p>Diagnosis PAP smear- Negative for intraepithelial lesion malignancy – NILM. Moderate Inflammation. (The Bethesda system for the reporting of cervical cytology-2014). Note-The pap test is a screening procedure to aid in the detection of cervical cancer and its precursors.</p>		

Revival Diagnostics
401-Aqua Corridor,
Beside Star Bazar, Adajan,
Surat-395009. Mo. 9825947712

Dr. Shivangi Gandhi
M.B.B.S, M.D (Pathology)

0261-2747788, 98259 47712

4th Floor, Aqua Corridor, Hazira Road, Adajan Pal, Surat - 395009.

revivaldiagnostics.surat@gmail.com

www.revivaldiagnostics.com










Medical Form & EYE CHECK UP

Demographic Information:			
Name :	Meeravsi M,	Date :	24/02/24
Age :	29		
Sex :	F		

VITALS CHECKUP					
Blood Pressure	:-	110/70 mm/hg	HEIGHT [IN CM]	:-	155
Heart Rate	:-	80/min.	Weight (in Kgs)	:-	61
Spo2	:-	98%	BMI VALUE	:-	25
PULSE	:-	80/min.	BMI STATUS	:-	Normal

HISTORY	
Current Health Complaints	NO
Past History	NO
Family History	NO
Allergies	NO
Ongoing Medication	NO
Any other problems needing attention / Overall Assessment :	

REMARKS :- 

EYE TEST			
1. VISION :-			
A. NEAR VISION		B. DISTANCE VISION	
RIGHT EYE :-		RIGHT EYE :-	6/9 } with specs
LEFT EYE :-		LEFT EYE :-	6/9 } specs
2. COLOR VISION :-		3. NIGHT VISION :-	
RIGHT EYE :-		RIGHT EYE :-	
LEFT EYE :-		LEFT EYE :-	

REMARKS :- NAD

DOCTOR SIGN

Revival Diagnostic
401, Aqua Corridor,
S/s. Star Bazar, Surat-395009
Mo. 91062-28601


Dr. Chirag Patel
M.B.B.S. G-49432

help@healthledger.co.in
+91 916 907 5555



Dental Checkup

Reg. No. : _____ Date: 24-07-24
Patient Name Mr. /Mrs Meerashi M.
Age 29 Sex F Address _____
Mobile No. _____

Past Medical History

- 1) Smoking 2) Alcohol 3) Hepatitis B & C 4) Diabetics 6) Tobacco 5) Allergy 6) Asthma
7) Any Other: NO

PDH:- (S)

O/E :- (S)

Investigation :- NO

Treatment:- NO

Doctor's Sign and Stamp

Consent Form:

I, Meerashi M-----have given true & total information to the dentist regarding past & present illness as well as ongoing medical treatment. I have been fully informed regarding treatment for present illness. Along with benefit & possible risk from medicines / Surgery / Anesthetic drugs to be used by the dentist in my own understanding language. I hereby willingly permit the dentist to undertake the treatment or surgical intervention.

Patient Signature: Meerashi M

RADIOLOGY | PATHOLOGY | CARDIOLOGY | DENTAL | OHC | CORPORATE WELLNESS

Revival Diagnostic
401, Aqua Corridor,
G/s, Star Bazar, Surat-395009
Mo. 91062-28601



REVIVAL DIAGNOSTICS

Name	MEERASRI MANIVASAGAM	Age/Gender	29Yrs/Female
Reg No.	1804/24	Receipt No	17335
Referred By	Bank of Baroda (BOB) - MEDI WHEEL()	Mode of Payment	CREDIT
Collection Type	CENTER	Collection DateTime	24-Feb-2024 09:02 AM

BLOOD GROUP - 240224202 Released at 24-Feb-2024 11:24 AM

Parameter	Result	Biological Ref.Range	Method
-Blood Group	"B"		
-Rh Factor	POSITIVE		

CBC - 240224202 Released at 24-Feb-2024 10:55 AM

Parameter	Result	Biological Ref.Range	Method
-Haemoglobin	12.9 gm/dL	(12 - 16 gm/dL)	Auto
-RBC Count	4.38 mill/cumm	(4.2 - 5.4 mill/cumm)	Auto
-Total WBC Count	6700 /cumm	(4000 - 10000 /cumm)	Auto
-Platelet Count	2.54 lakh/cumm	(1.5 - 4.5 lakh/cumm)	Auto

Blood Indices

-HCT	40.1 %	(40 - 55 %)	Auto
-MCV	91.1 fl	(80 - 92 fl)	Auto
-MCH	29.4 pg	(27 - 31 pg)	Auto
-MCHC	32.2 gm/dL	(32 - 36 gm/dL)	Auto
-RDW	12.4 %	(11 - 15 %)	Auto

Diff WBC Count

-Polymorphs	55 %	(40 - 80 %)	Microscopically
-Lymphocytes	39 %	(20 - 40 %)	Microscopically
-Eosinophils	04 %	(1 - 6 %)	Microscopically
-Monocytes	02 %	(2 - 7 %)	Microscopically
-Basophils	00 %	(0 - 1 %)	Microscopically
-PLATELET ON SMEAR	Adequate		Microscopically
-MALARIAL PARASITES	Malarial Parasites Not Detected		Microscopically

[Test performed on Fully Automated Hematology Analyzer ERBA H-360]

Revival Diagnostics
401-Aqua Corridor,
Beside Star Bazar, Adajan,
Surat-395009. Mo. 9825947712

Dr. Shivangi Gandhi
M.B.B.S, M.D (Pathology)

0261-2747788, 98259 47712

4th Floor, Aqua Corridor, Hazira Road, Adajan Pal, Surat - 395009.

revivaldiagnostics.surat@gmail.com

www.revivaldiagnostics.com



REVIVAL DIAGNOSTICS

Name	MEERASRI MANIVASAGAM	Age/Gender	29Yrs/Female
Reg No.	1804/24	Receipt No	17335
Referred By	Bank of Baroda (BOB) - MEDI WHEEL()	Mode of Payment	CREDIT
Collection Type	CENTER	Collection DateTime	24-Feb-2024 09:02 AM

ESR - 240224202 Released at 24-Feb-2024 12:04 PM

Parameter	Result	Biological Ref.Range	Method
-E.S.R	04 mm/hr	(3 - 15 mm/hr)	

Revival Diagnostics
401-Aqua Corridor,
Beside Star Bazar, Adajan,
Surat-395009. Mo. 9825947712

Dr. Shivangi Gandhi
M.B.B.S, M.D (Pathology)

0261-2747788, 98259 47712

4th Floor, Aqua Corridor, Hazira Road, Adajan Pal, Surat - 395009.

revivaldiagnostics.surat@gmail.com

www.revivaldiagnostics.com



REVIVAL DIAGNOSTICS

Name	MEERASRI MANIVASAGAM	Age/Gender	29Yrs/Female
Reg No.	1804/24	Receipt No	17335
Referred By	Bank of Baroda (BOB) - MEDI WHEEL()	Mode of Payment	CREDIT
Collection Type	CENTER	Collection DateTime	24-Feb-2024 09:02 AM

FBS & PPBS - 240224203 Released at 24-Feb-2024 12:45 PM

Parameter	Result	Biological Ref.Range	Method
-Fasting Blood Sugar (FBS)	81 mg/dL	70-100 mg/dl Impaired Tolerance: 100-125 Diabetes Mellitus: \geq 126 (American diabetes association guidelines 2022)	
-Fasting Urine Sugar	Absent		
-Fasting Urine Acetone	Absent		
-PPBS	107 mg/dL	(90 - 140 mg/dL)	
-PP2BS URINE SUGAR	Absent		
-PP2BS URINE ACETONE	Absent		

HBA1C - 240224202 Released at 24-Feb-2024 12:45 PM

Parameter	Result	Biological Ref.Range	Method
-HBA1C	5.1 %	HbA1C Degree of Glucose Control <5.6 % Non Diabetics 5.7 - 6.4 % Prediabetics >=6.5 % Diabetics (REF:Wallace, 11th Edition) REMARKS: 6 - 7 % Excellent Control 7 - 8 % Good Control 8 - 10 % Unsatisfactory Control >10 % Poor Control	Immuno-Turbidometry method
-Method[]		High Performance Liquid Chromatography (HPLC)	

Revival Diagnostics
401-Aqua Corridor,
Beside Star Bazar, Adajan,
Surat-395009. Mo. 9825947712

Dr. Shivangi Gandhi
M.B.B.S, M.D (Pathology)

0261-2747788, 98259 47712

4th Floor, Aqua Corridor, Hazira Road, Adajan Pal, Surat - 395009.

revivaldiagnostics.surat@gmail.com

www.revivaldiagnostics.com



REVIVAL DIAGNOSTICS

Name	MEERASRI MANIVASAGAM	Age/Gender	29Yrs/Female
Reg No.	1804/24	Receipt No	17335
Referred By	Bank of Baroda (BOB) - MEDI WHEEL()	Mode of Payment	CREDIT
Collection Type	CENTER	Collection DateTime	24-Feb-2024 09:02 AM

LIVER FUNCTION TEST (LFT) - 240224205 Released at 24-Feb-2024 12:45 PM

Parameter	Result	Biological Ref.Range	Method
-Serum Total Bilirubin	1.4 mg/dL	H (0 - 1.3 mg/dL)	Diazo
-Serum Direct Bilirubin	0.4 mg/dL	(0 - 0.4 mg/dL)	Diazo
-Serum InDirect Bilirubin	1.0 mg/dL	(0.1 - 1.3 mg/dL)	Calculated
-Total Protein (TP)	6.6 gm/dL	(6.4 - 8.3 gm/dL)	Biuret
-Albumin (ALB)	3.8 gm/dL	(3.5 - 5.2 gm/dL)	BCG
-Globulin	2.8 gm/dL	(2.3 - 3.6 gm/dL)	Calculated
-A/G Ratio	1.36 gm/dL	(1 - 2.3 gm/dL)	Calculated
-SGPT(ALT)	25 U/L	(5 - 45 U/L)	IFCC, Kinetic without Pyridoxal Phosphate
-SGOT (AST)	19 U/L	(0 - 35 U/L)	IFCC, Without Pyridoxal Phosphate
-Alkaline Phosph.	76 U/L	(42 - 128 U/L)	ALP-AMP
-GGT	24 U/L	(5 - 50 U/L)	Glupa-C

[Test performed on Fully Automated Biochemistry Analyzer ERBA EM200]

Revival Diagnostics

401-Aqua Corridor,
Beside Star Bazar, Adajan,
Surat-395009. Mo. 9825947712

Dr. Shivangi Gandhi
M.B.B.S, M.D (Pathology)

0261-2747788, 98259 47712

4th Floor, Aqua Corridor, Hazira Road, Adajan Pal, Surat - 395009.

revivaldiagnostics.surat@gmail.com

www.revivaldiagnostics.com

This Medical Report is Not Intended for Medico-legal Purposes. Laboratory Test Results are Subject to Technical limitation and Should be Clinically Correlate for Final Diagnosis



REVIVAL DIAGNOSTICS

Name	MEERASRI MANIVASAGAM	Age/Gender	29Yrs/Female
Reg No.	1804/24	Receipt No	17335
Referred By	Bank of Baroda (BOB) - MEDI WHEEL()	Mode of Payment	CREDIT
Collection Type	CENTER	Collection DateTime	24-Feb-2024 09:02 AM

Creatinine - 240224205 Released at 24-Feb-2024 12:45 PM

Parameter	Result	Biological Ref.Range	Method
-Creatinine	0.6 mg/dL	(0.6 - 1.14 mg/dL)	ENZYMATIC

BUN - 240224205 Released at 24-Feb-2024 10:38 AM

Parameter	Result	Biological Ref.Range	Method
-Blood Urea Nitrogen (BUN)	7 mg/dL	(6 - 20 mg/dL)	Calculated

Uric Acid - 240224201 Released at 24-Feb-2024 12:45 PM

Parameter	Result	Biological Ref.Range	Method
-Uric Acid	4.2 mg/dL	(3.5 - 7.2 mg/dL)	Uricase-POD

Revival Diagnostics
401-Aqua Corridor,
Beside Star Bazar, Adajan,
Surat-395009. Mo. 9825947712

Dr. Shivangi Gandhi
M.B.B.S, M.D (Pathology)

0261-2747788, 98259 47712

4th Floor, Aqua Corridor, Hazira Road, Adajan Pal, Surat - 395009.

revivaldiagnostics.surat@gmail.com

www.revivaldiagnostics.com

This Medical Report is Not Intended for Medico-legal Purposes. Laboratory Test Results are Subject to Technical limitation and Should be Clinically Correlate for Final Diagnosis



REVIVAL DIAGNOSTICS

Name	MEERASRI MANIVASAGAM	Age/Gender	29Yrs/Female
Reg No.	1804/24	Receipt No	17335
Referred By	Bank of Baroda (BOB) - MEDI WHEEL()	Mode of Payment	CREDIT
Collection Type	CENTER	Collection DateTime	24-Feb-2024 09:02 AM

Lipid Profile - 240224205 Released at 24-Feb-2024 12:45 PM

Parameter	Result	Biological Ref.Range	Method
-Serum Cholesterol	207 mg/dL	Desirable < 200 mg/dl Borderline High : 200-239 mg/dl High : > 240 mg/dl	CHOD-PAP
-Serum Triglyceride	119 mg/dL	Normal < 150 mg/dl Borderline High : 150 - 199 mg/dl High : 200 - 499 mg/dl Very High : 500 mg/dl	GPO-POD Method
-Serum HDLD(Direct)	46 mg/dL	Normal :> 55 mg/dl Borderline : 35-55 mg/dl Undesirable: < 35 mg/dl	PVS-PEGME Precipitation with CHOD-POD
-Serum VLDL	24 mg/dL	(5 - 30 mg/dL)	Calculated
-Serum LDL(Direct)	137 mg/dL	Optimal:< 100 mg/dl Above Optimal : 100- 129 mg/dl Borderline High : 130-159 mg/dl High : > 160-189mg/dl Very High : >190 mg/dl	Calculated
-Chol/HDL	4.50	Low risk: <3.8 Medium Risk: 3.8 to 5.9 High Risk: > 6	Calculated
-LDL/Chol	1.51	Low risk: <3.55 Medium Risk: 3.55 to 4.0 High Risk: > 6	Calculated

[Test performed on Fully Automated Biochemistry Analyzer ERBA EM200]

Revival Diagnostics
401-Aqua Corridor,
Beside Star Bazar, Adajan,
Surat-395009. Mo. 9825947717

Dr. Shivangi Gandhi
M.B.B.S, M.D (Pathology)

0261-2747788, 98259 47712

4th Floor, Aqua Corridor, Hazira Road, Adajan Pal, Surat - 395009.

revivaldiagnostics.surat@gmail.com

www.revivaldiagnostics.com

This Medical Report is Not Intended for Medico-legal Purposes. Laboratory Test Results are Subject to Technical limitation and Should be Clinically Correlate for Final Diagnosis



REVIVAL DIAGNOSTICS

Name	MEERASRI MANIVASAGAM	Age/Gender	29Yrs/Female
Reg No.	1804/24	Receipt No	17335
Referred By	Bank of Baroda (BOB) - MEDI WHEEL()	Mode of Payment	CREDIT
Collection Type	CENTER	Collection DateTime	24-Feb-2024 09:02 AM

Urine Routine & Micro Examination - 240224207 Released at 24-Feb-2024 12:55 PM

Parameter	Result	Biological Ref.Range	Method
Physical Examination			
-Quantity	30		Manual
-Colour	Pale Yellow	Pale Yellow	Manual
-Appearance	Clear	Clear	Manual
-Reaction (pH)	Acidic		Dipstick
-Specific Gravity	1.030		Dipstick
Chemical Examination			
-Proteins.	Absent		Dipstick
-Sugar	Absent		Dipstick
-Acetone.	Absent		Dipstick
-Bile Salts	Absent	Absent	Dipstick
-Bile Pigments	Absent	Absent	Dipstick
-Occult Blood Test (OBT).	Negative		Dipstick
Microscopic Examination			
-Pus Cells	2-3		Microscopically
-Red Blood Cells	Absent		Microscopically
-Epithelial Cells	1-2		Microscopically
-Bacteria.	Absent		Microscopically
-Crystals	Absent	Absent	Microscopically
-Others	NIL	Absent	Microscopic Examination

Revival Diagnostics
401-Aqua Corridor,
Beside Star Bazar, Adajan,
Surat-395009. Mo. 9825947717

Dr. Shivangi Gan
M.B.B.S, M.D (Patholc

0261-2747788, 98259 47712

4th Floor, Aqua Corridor, Hazira Road, Adajan Pal, Surat - 395009.

revivaldiagnostics.surat@gm

www.revivaldiagnostics.com

This Medical Report is Not Intended for Medico-legal Purposes. Laboratory Test Results are Su
Technical limitation and Should be Clinically Correlate for Final Diagnosis



REVIVAL DIAGNOSTICS

Name	MEERASRI MANIVASAGAM	Age/Gender	29Yrs/Female
Reg No.	1804/24	Receipt No	17335
Referred By	Bank of Baroda (BOB) - MEDI WHEEL()	Mode of Payment	CREDIT
Collection Type	CENTER	Collection DateTime	24-Feb-2024 09:02 AM

Total T3 T4 TSH - 240224205 Released at 24-Feb-2024 11:17 AM

Parameter	Result	Biological Ref.Range	Method
-Total T3	0.99 ng/ml	(0.87 - 1.78 ng/ml)	Fluorescence Enzyme Immunoassay
-Total T4	6.51 ug/dl	(4.6 - 11 ug/dl)	Fluorescence Enzyme Immunoassay
-TSH	2.67 uIU/ml	0.50 - 5.50 uIU/ml 5.5 to 15 ul U/ml - Suggested Clinical co-relation or Repeat test with new sample as physiological factors can give false high TSH Above 15uIU/ml Hypothyroid PREGNANT WOMEN normal ranges for TSH: 1st Trimester : 0.0878 - 2.8293 uIU/ml 2nd Trimester : 0.1998 - 2.7915 uIU/ml 3rd Trimester : 0.307 - 2.9028 uIU/ml Ref: TIETZ Fundamentals of Clinical Chemistry	Fluorescence Enzyme Immunoassay

[Test performed on Fully Automated Immunology Analyzer Maglumi-600]

Revival Diagnostics
401-Aqua Corridor,
Beside Star Bazar, Adajan,
Surat-395009. Mo. 9825947717

Dr. Shivangi Gandhi
M.B.B.S, M.D (Pathology)

0261-2747788, 98259 47712

4th Floor, Aqua Corridor, Hazira Road, Adajan Pal, Surat - 395009.

@ revivaldiagnostics.surat@gmail.com

www.revivaldiagnostics.com



Name	MEERASRI MANIVASAGAM	Age/Gender	29Yrs/Female
Reg No.	1804/24	Receipt No	17335
Referred By	Bank of Baroda (BOB) - MEDI WHEEL()	Mode of Payment	CREDIT
Collection Type	CENTER	Collection DateTime	24-Feb-2024 08:42 AM

2D ECHO
2D ECHOCARDIOGRAPHY & COLOR DOPPLER REPORT

INDICATION: Preventive Health check up

- **CARDIAC CHAMBERS :** Left Ventricle : Normal size , Left Atrium: Normal size.
- NO e/o thrombus in LA/LV
- Right Atrium: Normal size. Right Ventricle: Normal Size,
- **Normal Right Ventricular function.** (TAPSE=20mm)
- **Normal Left Ventricular systolic function.** LVEF = 60%
- **No regional wall abnormality. No thinning / scarring / dyskinesia of LV wall**
- **No Left Ventricular Hypertrophy.** (IVSd= 09 mm),
- **LV Compliance:**
- **NO Left Ventricular Diastolic Dysfunction [LVDD].**

VALVES :

- Structurally Normal Mitral valve/ Aortic valve/Tricuspid valve/ Pulmonary valve .
- No significant Valvular Stenosis
- **Doppler findings: AV max = 1.23 m/s, PV max = 0.91 m/s.**
- Trivial MR, Trivial Tricuspid regurgitation.
- **No Pulmonary Arterial Hypertension. PASP by TRjet vel.method = 24 mmHg.**
- **SEPTAE:** IAS / IVS Appear Intact.
- **IVC :** Normal in dimension and shows good inspiratory 13mm collapse.
- **OTHERS:** No e/o Pericardial effusion / vegetation.

IMPRESSION:

**NORMAL LV SYSTOLIC FUNCTION, LVEF= 60 %, NO RWMA,
NO LVH , NO LVDD , NO PAH.**

DR. ADITYA S. BORA
Signature
MBBS, DCC
PHYSICIAN & CLINICAL CARDIOLOGIST
G-54906



Name	MEERASRI MANIVASAGAM	Age/Gender	29Yrs/Female
Reg No.	1804/24	Receipt No	17335
Referred By	Bank of Baroda (BOB) - MEDI WHEEL()	Mode of Payment	CREDIT
Collection Type	CENTER	Collection DateTime	24-Feb-2024 08:42 AM

USG OF ABDOMEN & PELVIS

LIVER:

Liver is normal in size, shape and echotexture.
No evidence of focal SOL or dilatation of IHBR seen.
Portahepatis appear normal.

GALLBLADDER:

Gallbladder is distended and appears normal.
No e/o calculus, mass lesion or changes of cholecystitis seen.

PANCREAS:

Pancreas appears normal in size, shape and echotexture.
No e/o focal lesion, mass or changes of pancreatitis seen.

SPLEEN:

Spleen appears normal in size, shape and echotexture.

PARAAORTIC REGION:

Aorta grossly appears normal. No e/o paraaortic lymphnodes seen.

KIDNEYS:

Both kidneys appear normal in size, shape, position and echotexture.
Cortex and collecting system of both kidneys appear normal.
No evidence of calculus or obstructive uropathy on either side.

URINARY BLADDER:

Bladder is distended and appears normal.
No calculus, mass lesion or changes of cystitis is seen.

UTERUS:

anteverted, Normal in size, shape and echotexture with empty central uterine cavity.
Cervix appears normal.

No e/o focal SOL. Endometrial thickness is normal

OVARIES:

Both adnexal region appear normal.
No e/o adnexal mass lesion seen on either side.
No evidence of free fluid seen in pelvis.

COMMENTS: NORMAL USG ABDOMEN AND PELVIS.

Dr. Chirag K. Patel

MBBS-DMPD

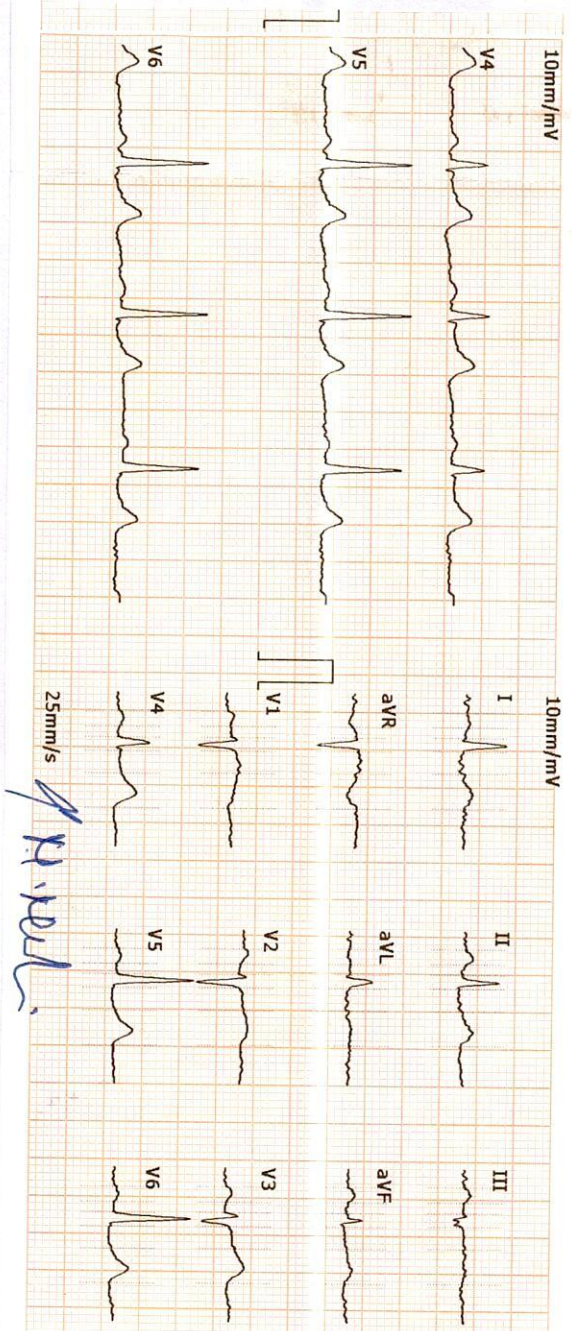
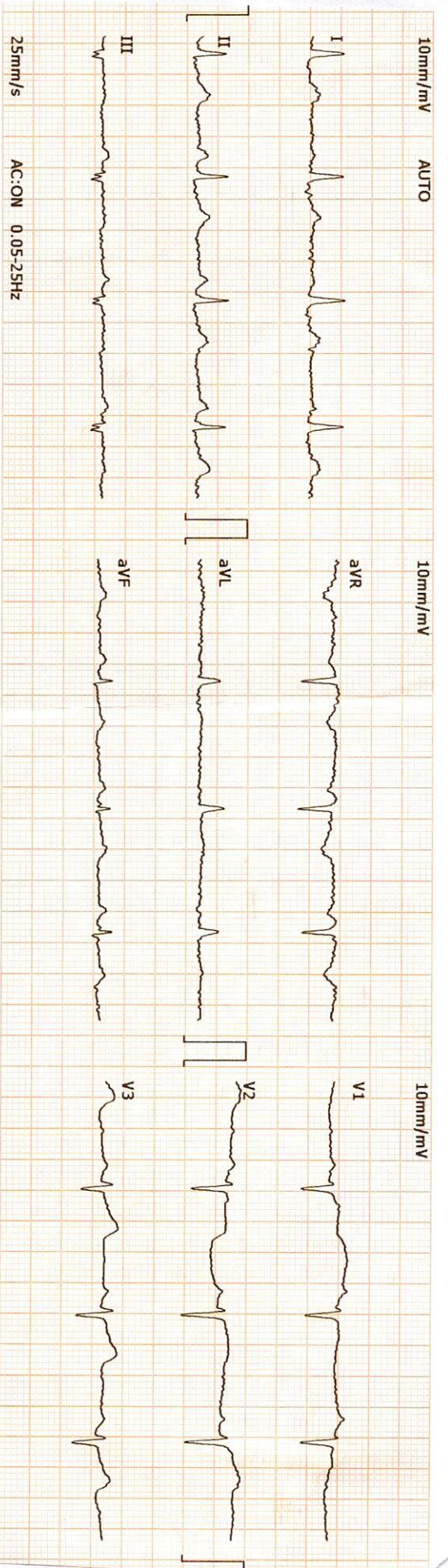
Reg. No. G-23509

Revival Diagnostic

4th Floor, Aqua Corridor,

Nr. Star Bazar, Hazira Road, Adajan, Surat-395009.

Mo. 97266 726683



2024-2-24 9:25:21 ID: 00008578

ID Card: _____ Name: MEERASRI Gender: Female

Age: 28 yrs Height(cm): _____

Weight(kg): _____ BP(mmHg): _____

HR: _____ bpm 72

P-R: _____ ms 130

Q-R-S: _____ ms 80

QT/QTc: _____ ms 370/403

P/QRS/T AXES: _____ deg 61/19/61

RV5/SV1: _____ mV -0.45

RV5+SV1: _____ mV ---

*The result must be confirmed by doctor!

Report Confirmed by: *M. R. V. L.*

Revival Diagnostics
 401-Aquã Corridor,
 Beside Star Bazar, Adajan,
 Surat-395009. Mo. 9825947712

DR. ADITYA S. BORA
 MBB, DNB, PGDCC
 PHYSICIAN & CLINICAL CARDIOLOGIST
 G-54906



REVIVAL DIAGNOSTICS

Name	MEERASRI MANIVASAGAM	Age/Gender	29Yrs/Female
Reg No.	1804/24	Receipt No	17335
Referred By	Bank of Baroda (BOB) - MEDI WHEEL()	Mode of Payment	CREDIT
Collection Type	CENTER	Collection DateTime	24-Feb-2024 08:42 AM

Ecg

1. The rhythm is sinus.
2. Heart rate is 72 beats per minute.
3. Normal P, QRS, T wave axis.
4. Normal PR, QRS, Q.T. Duration.
5. No pathological q wave or ST-T changes seen.
6. No evidence of chamber hypertrophy or enlargement seen.

IMPRESSION : ECG WITHIN NORMAL LIMITS

Revival Diagnostics
401-Aqua Corridor,
Beside Star Bazar, Adajan,
Surat-395009. Mo. 9825947712

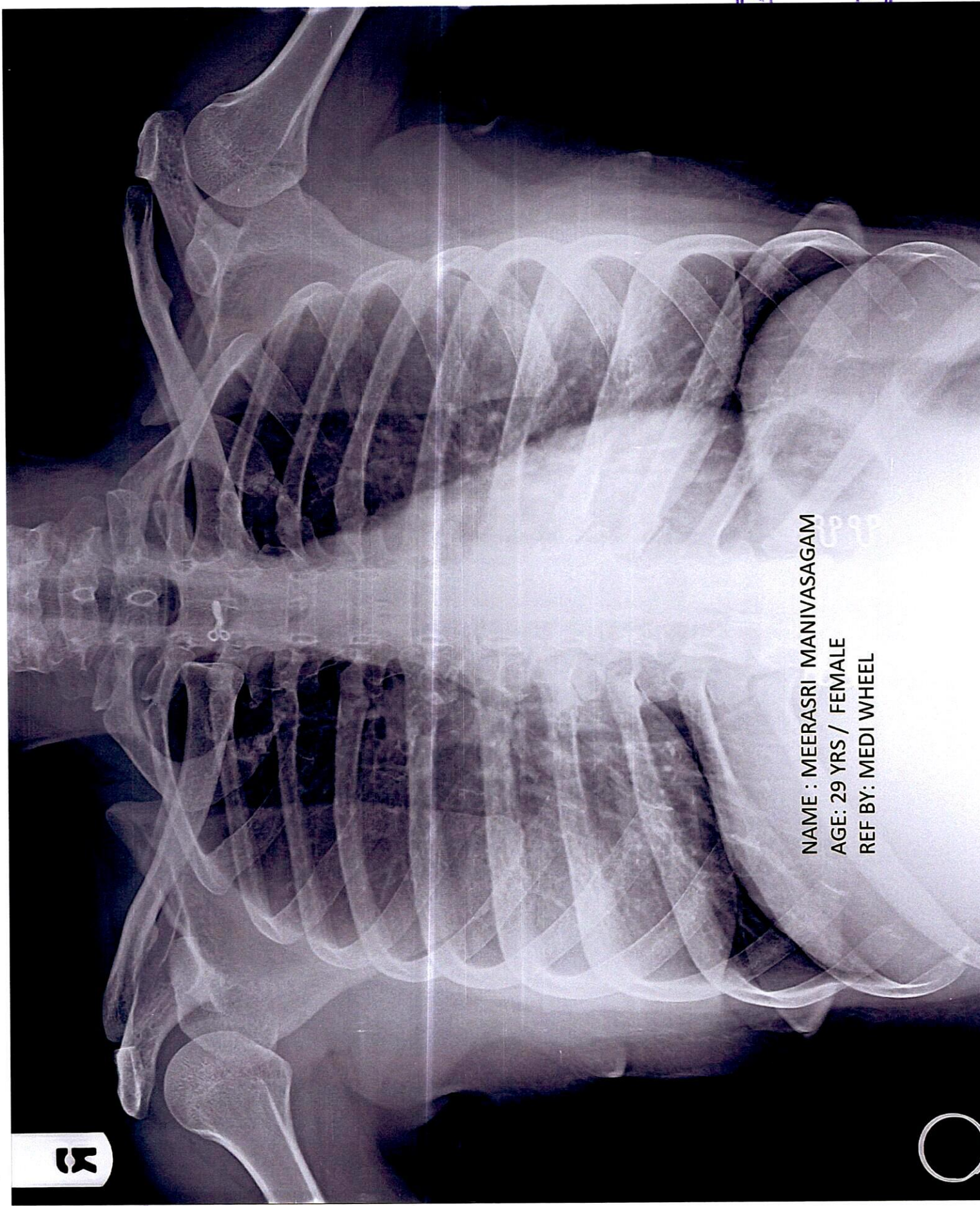
DR. ADITYA S. BORA
MBBS, DNB, DGPCC
PHYSICIAN & CLINICAL CARDIOLOGIST
G-54906

0261-2747788, 98259 47712

4th Floor, Aqua Corridor, Hazira Road, Adajan Pal, Surat - 395009.

revivaldiagnostics.surat@gmail.com

www.revivaldiagnostics.com



NAME : MEERASRI MANIVASAGAM
AGE: 29 YRS / FEMALE
REF BY: MEDI WHEEL

R





DR. CHIRAG K PATEL
RADIOLOGIST

IMPRESSION: NORMAL STUDY.

- Hilar shadows are within normal limits.
- Pulmonary vasculature appears normal.
- Cardiac appears normal in size.
- Both domes of the diaphragm are smooth.
- Both costophrenic recesses are clear.
- Both lung fields appear normal.
- Visualized bones and soft tissue shadows appear normal.

CHEST RADIOGRAPH (PA VIEW)

Name	MEERASRI MANIVASAGAM	Age/Gender	29Yrs/Female
Reg No.	1804/24	Receipt No	17335
Referred By	Bank of Baroda (BOB) - MEDI WHEEL()	Mode of Payment	CREDIT
Collection Type	CENTER	Collection DateTime	24-Feb-2024 08:42 AM

Dr. Chirag K. Patel
MBBS-DNB
Reg. No. G-23519
Revival Diagnostics
4th Floor, Hazira Main Road
Nr. Star Bazar, Adajan, Surat-395009.
Mo. 97266 726683

