



REVIVAL DIAGNOSTICS

HEALTH CHECK-UP SUMMARY

Name : Rakhi Prakash

Date: 16/02/2024

Email ID :

Sex : F Age : 30 Years Contact No: 9638866898

Remarks :

Under-weight

Normal

Over-weight

i> BMI

Height (in Cm) : 160	Weight (in Kg) : 69	BMI: 27
Hip (in Cm) : 99	Waist (in Cm) : 92	Hip to Waist Ratio: 1.07

ii> Blood Pressure & Pulse

120/76 mm/hg
74/min. Regular

If high or low, whether the person is on medication : YES / NO

iii> Blood Tests & Lung Function Remarks

RS }
CVS }
CNS } @

If abnormal, whether the person is on medication : YES / NO

iv> Eye Test Remarks

Eye Sight: RL 6/9 LA 6/9
Color Vision: @

v> Heart Disease

Whether any specific heart ailment detected (ECG findings) :
SAD

vi> Any other problems needing attention / Overall Assessment :

SO

Dr. Chirag Patel
M.B.B.S. G-49432

Rakhi Prakash

Revival Diagnostic
401, Aqua Corridor,
B/s. Star Bazar, Surat-395009
Mo. 91062-28601

0261-2747788, 98259 47712

@ revivaldiagnostics.surat@gmail.com

4th Floor, Aqua Corridor, Hazira Road, Adajan Pal, Surat - 395009.

www.revivaldiagnostics.com





Department Of Ophthalmology

Demographic Information:

Name : Rakhi Babbarh Date : 16/02/24
Age : 30
Sex : F

EYE TEST

1. VISION :-

RIGHT EYE :- 6/9

LEFT EYE :- 6/9

2. COLOR VISION :-

RIGHT EYE :- 2

LEFT EYE :- 2

3. NIGHT VISION :-

RIGHT EYE :- 2

LEFT EYE :- 2

REMARKS :-

[Handwritten signature]

Revival Diagnostic
401, Aqua Corridor,
B/s. Star Bazar, Surat - 395009
Mo. 91062-28601
DOCTOR SIGN



help@healthledger.co.in
+91 916 907 5555



Dental Checkup

Reg. No. : _____ Date: 16/02/24
Patient Name Mr./Mrs Rakhi Prabhash
Age 30 Sex F Address Surat
Mobile No. 9638866876

Past Medical History

- 1) Smoking 2) Alcohol 3) Hepatitis B & C 4) Diabetics 6) Tobacco 5) Allergy 6) Asthma
7) Any Other: NO

PDH:- (2)

O/E :- (2)

Investigation :- NO

Treatment:- NO

Doctor's Sign and Stamp

C.K. Patel

Dr. Chirag Patel
M.B.B.S. G-49432

Consent Form:

I Rakhi Prabhash

-----have given true & total information to the dentist regarding past & present illness as well as ongoing medical treatment. I have been fully informed regarding treatment for present illness. Along with benefit & possible risk from medicines / Surgery / Anesthetic drugs to be used by the dentist in my own understanding language. I hereby willingly permit the dentist to undertake the treatment or surgical intervention.

Patient Signature: Rakhi Prabhash

Revival Diagnostic
401, Aqua Corridor,
B/s. Star Bazar, Surat-395009
Mo. 91062-28601



REVIVAL DIAGNOSTICS

Name	RAKHI PRAKASH	Age/Gender	30Yrs/Female
Reg No.	1499/24	Receipt No	17022
Referred By	Bank of Baroda (BOB) - MEDI WHEEL()	Mode of Payment	CREDIT
Collection Type	CENTER	Collection DateTime	16-Feb-2024 09:15 AM

BLOOD GROUP - 16022463 Released at 16-Feb-2024 12:07 PM

Parameter	Result	Biological Ref.Range	Method
-Blood Group	"AB"		
-Rh Factor	POSITIVE		

CBC - 16022463 Released at 16-Feb-2024 11:28 AM

Parameter	Result	Biological Ref.Range	Method
-Haemoglobin	9.9 gm/dL	L (12 - 16 gm/dL)	Auto
-RBC Count	3.95 mill/cumm	L (4.2 - 5.4 mill/cumm)	Auto
-Total WBC Count	5800 /cumm	(4000 - 10000 /cumm)	Auto
-Platelet Count	1.72 lakh/cumm	(1.5 - 4.5 lakh/cumm)	Auto

Blood Indices

-HCT	32.6 %	L (40 - 55 %)	Auto
-MCV	82.5 fl	(80 - 92 fl)	Auto
-MCH	25.1 pg	L (27 - 31 pg)	Auto
-MCHC	30.5 gm/dL	L (32 - 36 gm/dL)	Auto
-RDW	13.6 %	(11 - 15 %)	Auto

Diff WBC Count

-Polymorphs	61 %	(40 - 80 %)	Microscopically
-Lymphocytes	32 %	(20 - 40 %)	Microscopically
-Eosinophils	05 %	(1 - 6 %)	Microscopically
-Monocytes	02 %	(2 - 7 %)	Microscopically
-Basophils	00 %	(0 - 1 %)	Microscopically
-PLATELET ON SMEAR	Adequate		Microscopically
-MALARIAL PARASITES	Malarial Parasites Not Detected		Microscopically

[Test performed on Fully Automated Hematology Analyzer ERBA H-360]

Revival Diagnostics
401-Aqua Corridor,
Beside Star Bazar, Adajan,
Surat-395009. Mo. 9825947717

Sg

Dr. Shivangi Gandhi
M.B.B.S, M.D (Pathology)

0261-2747788, 98259 47712

4th Floor, Aqua Corridor, Hazira Road, Adajan Pal, Surat - 395009.

revivaldiagnostics.surat@gmail.com

www.revivaldiagnostics.com



REVIVAL DIAGNOSTICS

Name	RAKHI PRAKASH	Age/Gender	30Yrs/Female
Reg No.	1499/24	Receipt No	17022
Referred By	Bank of Baroda (BOB) - MEDI WHEEL()	Mode of Payment	CREDIT
Collection Type	CENTER	Collection DateTime	16-Feb-2024 09:15 AM

ESR - 16022463 Released at 16-Feb-2024 12:28 PM

Parameter	Result	Biological Ref.Range	Method
-E.S.R	10 mm/hr	(3 - 15 mm/hr)	

Revival Diagnostics

401-Aqua Corridor,
Beside Star Bazar, Adajan,
Surat-395009. Mo. 9825947712

Dr. Shivangi Gandhi
M.B.B.S, M.D (Pathology)

0261-2747788; 98259 47712

4th Floor, Aqua Corridor, Hazira Road, Adajan Pal, Surat - 395009.

revivaldiagnostics.surat@gmail.com

www.revivaldiagnostics.com



REVIVAL DIAGNOSTICS

Name	RAKHI PRAKASH	Age/Gender	30Yrs/Female
Reg No.	1499/24	Receipt No	17022
Referred By	Bank of Baroda (BOB) - MEDI WHEEL()	Mode of Payment	CREDIT
Collection Type	CENTER	Collection DateTime	16-Feb-2024 09:15 AM

LIVER FUNCTION TEST (LFT) - 16022466 Released at 16-Feb-2024 12:53 PM

Parameter	Result	Biological Ref.Range	Method
-Serum Total Bilirubin	0.6 mg/dL	(0 - 1.3 mg/dL)	Diazo
-Serum Direct Bilirubin	0.3 mg/dL	(0 - 0.4 mg/dL)	Diazo
-Serum InDirect Bilirubin	0.3 mg/dL	(0.1 - 1.3 mg/dL)	Calculated
-Total Protein (TP)	6.4 gm/dL	(6.4 - 8.3 gm/dL)	Biuret
-Albumin (ALB)	3.9 gm/dL	(3.5 - 5.2 gm/dL)	BCG
-Globulin	2.5 gm/dL	(2.3 - 3.6 gm/dL)	Calculated
-A/G Ratio	1.56 gm/dL	(1 - 2.3 gm/dL)	Calculated
-SGPT(ALT)	12 U/L	(5 - 45 U/L)	IFCC, Kinetic without Pyridoxal Phosphate
-SGOT (AST)	17 U/L	(0 - 35 U/L)	IFCC, Without Pyridoxal Phosphate
-Alkaline Phosph.	100 U/L	(42 - 128 U/L)	ALP-AMP
-GGT	22 U/L	(5 - 50 U/L)	Glupa-C

[Test performed on Fully Automated Biochemistry Analyzer ERBA EM200]

Revival Diagnostics
401-Aqua Corridor,
Beside Star Bazar, Adajan,
Surat-395009. Mo. 9825947717

Dr. Shivangi Gandhi
M.B.B.S, M.D (Pathology)

0261-2747788, 98259 47712

4th Floor, Aqua Corridor, Hazira Road, Adajan Pal, Surat - 395009.

revivaldiagnostics.surat@gmail.com

www.revivaldiagnostics.com



REVIVAL DIAGNOSTICS

Name	RAKHI PRAKASH	Age/Gender	30Yrs/Female
Reg No.	1499/24	Receipt No	17022
Referred By	Bank of Baroda (BOB) - MEDI WHEEL()	Mode of Payment	CREDIT
Collection Type	CENTER	Collection DateTime	16-Feb-2024 09:15 AM

Creatinine - 16022466 Released at 16-Feb-2024 12:54 PM

Parameter	Result	Biological Ref.Range	Method
-Creatinine	0.6 mg/dL	(0.6 - 1.14 mg/dL)	ENZYMATIC

BUN - 16022466 Released at 16-Feb-2024 12:22 PM

Parameter	Result	Biological Ref.Range	Method
-Blood Urea Nitrogen (BUN)	9 mg/dL	(6 - 20 mg/dL)	Calculated

Uric Acid - 16022462 Released at 16-Feb-2024 12:54 PM

Parameter	Result	Biological Ref.Range	Method
-Uric Acid	6.3 mg/dL	(3.5 - 7.2 mg/dL)	Uricase-POD

Revival Diagnostics
401-Aqua Corridor,
Beside Star Bazar, Adajan,
Surat-395009. Mo. 9825947712

Dr. Shivangi Gandhi
M.B.B.S, M.D (Pathology)

☎ 0261-2747788, 98259 47712

📍 4th Floor, Aqua Corridor, Hazira Road, Adajan Pal, Surat - 395009.

@ revivaldiagnostics.surat@gmail.com

🌐 www.revivaldiagnostics.com



REVIVAL DIAGNOSTICS

Name	RAKHI PRAKASH	Age/Gender	30Yrs/Female
Reg No.	1499/24	Receipt No	17022
Referred By	Bank of Baroda (BOB) - MEDI WHEEL()	Mode of Payment	CREDIT
Collection Type	CENTER	Collection Date/Time	16-Feb-2024 09:15 AM

Lipid Profile - 16022466 Released at 16-Feb-2024 12:54 PM

Parameter	Result	Biological Ref.Range	Method
-Serum Cholesterol	155 mg/dL	Desirable < 200 mg/dl Borderline High : 200-239 mg/dl High : > 240 mg/dl	CHOD-PAP
-Serum Triglyceride	205 mg/dL	H Normal < 150 mg/dl Borderline High : 150 - 199 mg/dl High : 200 - 499 mg/dl Very High : 500 mg/dl	GPO-POD Method
-Serum HDLD(Direct)	54 mg/dL	Normal : > 55 mg/dl Borderline : 35-55 mg/dl Undesirable: < 35 mg/dl	PVS-PEGME Precipitation with CHOD-POD
-Serum VLDL	41 mg/dL	H (5 - 30 mg/dL)	Calculated
-Serum LDL(Direct)	60 mg/dL	Optimal:< 100 mg/dl Above Optimal : 100- 129 mg/dl Borderline High : 130-159 mg/dl High : > 160-189mg/dl Very High : >190 mg/dl	Calculated
-Chol/HDL	2.87	Low risk: <3.8 Medium Risk: 3.8 to 5.9 High Risk: > 6	Calculated
-LDL/Chol	2.58	Low risk: <3.55 Medium Risk: 3.55 to 4.0 High Risk: > 6	Calculated

[Test performed on Fully Automated Biochemistry Analyzer ERBA EM200]

Revival Diagnostics
401-Aqua Corridor,
Beside Star Bazar, Adajan,
Surat-395009. Mo. 9825947712

Dr. Shivangi Gandhi
M.B.B.S, M.D (Pathology)

0261-2747788, 98259 47712

4th Floor, Aqua Corridor, Hazira Road, Adajan Pal, Surat - 395009.

revivaldiagnostics.surat@gmail.com

www.revivaldiagnostics.com





REVIVAL DIAGNOSTICS

Name	RAKHI PRAKASH	Age/Gender	30Yrs/Female
Reg No.	1499/24	Receipt No	17022
Referred By	Bank of Baroda (BOB) - MEDI WHEEL()	Mode of Payment	CREDIT
Collection Type	CENTER	Collection DateTime	16-Feb-2024 09:15 AM

Total T3 T4 TSH - 16022466 Released at 16-Feb-2024 12:16 PM

Parameter	Result	Biological Ref.Range	Method
-Total T3	0.85 ng/ml	L (0.87 - 1.78 ng/ml)	Fluorescence Enzyme Immunoassay
-Total T4	4.69 ug/dl	(4.6 - 11 ug/dl)	Fluorescence Enzyme Immunoassay
-TSH	22.30 uIU/ml	H 0.50 - 5.50 uIU/ml 5.5 to 15 ul U/ml - Suggested Clinical co-relation or Repeat test with new sample as physiological factors can give falsely high TSH Above 15uIU/ml Hypothyroid PREGNANT WOMEN normal ranges for TSH: 1st Trimester : 0.0878 - 2.8293 uIU/ml 2nd Trimester : 0.1998 - 2.7915 uIU/ml 3rd Trimester : 0.307 - 2.9028 uIU/ml Ref: TIETZ Fundamentals of Clinical Chemistry	Fluorescence Enzyme Immunoassay

[Test performed on Fully Automated Immunology Analyzer Maglumi-600]

Revival Diagnostics
401-Aqua Corridor,
Beside Star Bazar, Adajan,
Surat-395009. Mo. 9825947712

Dr. Shivangi Gandhi
M.B.B.S, M.D (Pathology)

0261-2747788, 98259 47712

4th Floor, Aqua Corridor, Hazira Road, Adajan Pal, Surat - 395009.

revivaldiagnostics.surat@gmail.com

www.revivaldiagnostics.com



REVIVAL DIAGNOSTICS

Name	RAKHI PRAKASH	Age/Gender	30Yrs/Female
Reg No.	1499/24	Receipt No	17022
Referred By	Bank of Baroda (BOB) - MEDI WHEEL()	Mode of Payment	CREDIT
Collection Type	CENTER	Collection DateTime	16-Feb-2024 09:15 AM

Total T3 T4 TSH - 16022466 Released at 16-Feb-2024 12:16 PM

Parameter	Result	Biological Ref.Range	Method
-Total T3	0.85 ng/ml	L (0.87 - 1.78 ng/ml)	Fluorescence Enzyme Immunoassay
-Total T4	4.69 ug/dl	(4.6 - 11 ug/dl)	Fluorescence Enzyme Immunoassay
-TSH	22.30 uIU/ml	H 0.50 - 5.50 uIU/ml 5.5 to 15 ul U/ml - Suggested Clinical co-relation or Repeat test with new sample as physiological factors can give falsley high TSH Above 15uIU/ml Hypothyroid PREGNANT WOMEN normal ranges for TSH: 1st Trimester : 0.0878 - 2.8293 uIU/ml 2nd Trimester : 0.1998 - 2.7915 uIU/ml 3rd Trimester : 0.307 - 2.9028 uIU/ml Ref: TIETZ Fundamentals of Clinical Chemistry	Fluorescence Enzyme Immunoassay

[Test performed on Fully Automated Immunology Analyzer Maglumi-600]

Revival Diagnostics

401-Aqua Corridor,
Beside Star Bazar, Adajan,
Surat-395009. Mo. 9825947712

Sg

Dr. Shivangi Gandhi
M.B.B.S, M.D (Pathology)

0261-2747788, 98259 47712

4th Floor, Aqua Corridor, Hazira Road, Adajan Pal, Surat - 395009.

revivaldiagnostics.surat@gmail.com

www.revivaldiagnostics.com

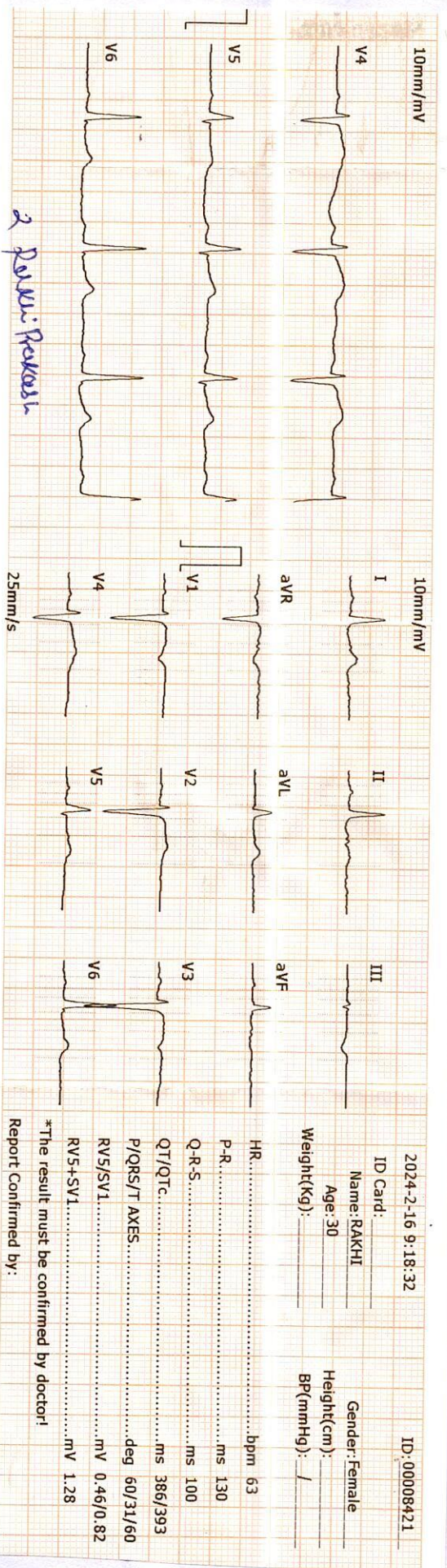
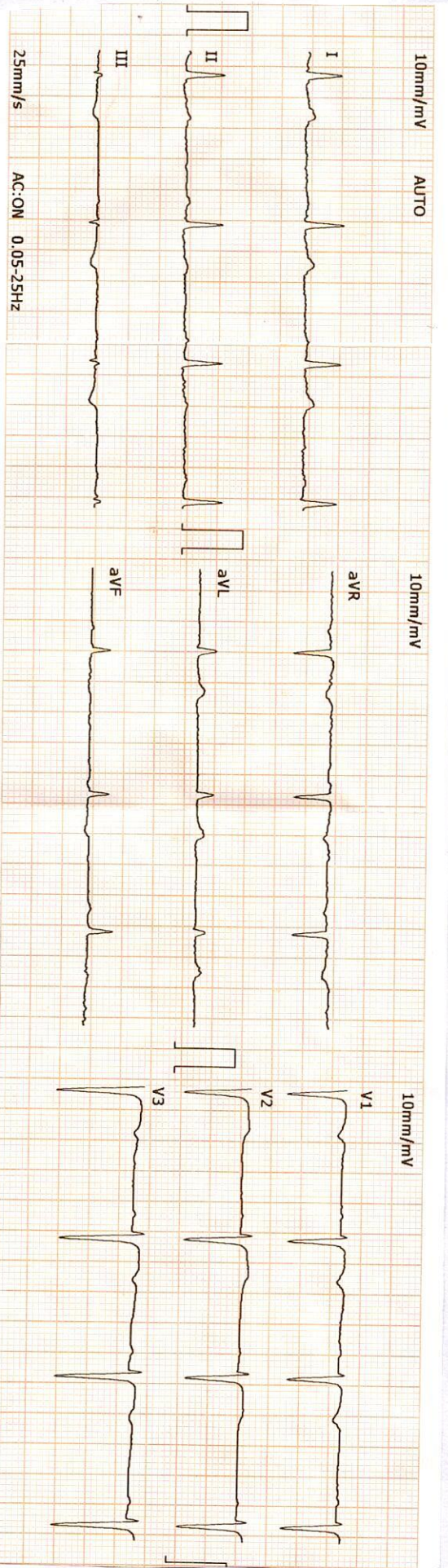
Received in payment of

the sum of

Five hundred dollars

for the purchase of the following described property

to-wit: One acre of land situated in the County of ... State of ...



2024-2-16 9:18:32 ID: 00008421

ID Card: _____
 Name: RAKHI _____
 Age: 30 _____
 Weight(kg): _____
 Height(cm): _____
 BP(mmHg): _____

HR: bpm 63
 P-R: ms 130
 Q-R-S: ms 100
 QT/QTc: ms 386/393
 P/QRS/T AXES: deg 60/31/60
 RV5/SV1: mV 0.46/0.82
 RV5+SV1: mV 1.28

*The result must be confirmed by doctor!
 Report Confirmed by: _____

Revival Diagnostics

401-Aquã Corridor,
 Beside Star Bazar, Adajan,
 Surat-395009. Mo. 9825947712

DR. ADITYA S. BORRA

MRS. DNB, PGDCC
 PHYSICIAN & SENIOR CARDIOLOGIST
 G-549D6

2015-03-2000 No. 88294411
Gedige Sree N. Sri Adityan
101-Annex Chennai

DR. ADITYAN S. BORA

0-24006
PHYSICIAN & DIRECTOR
MBBS DNB FRCG
DR. ADITYAN S. BORA



REVIVAL DIAGNOSTICS

Name	RAKHI PRAKASH	Age/Gender	30Yrs/Female
Reg No.	1499/24	Receipt No	17022
Referred By	Bank of Baroda (BOB) - MEDI WHEEL()	Mode of Payment	CREDIT
Collection Type	CENTER	Collection DateTime	16-Feb-2024 08:59 AM

Ecg

1. The rhythm is sinus.
2. Heart rate is 63 beats per minute.
3. Normal P,QRS,T wave axis.
4. Normal PR,QRS,Q.T. Duration.
5. No pathological q wave or ST-T changes seen.
6. No evidence of chamber hypertrophy or enlargement seen.

IMPRESSION : ECG WITHIN NORMAL LIMITS

Revival Diagnostics
401-Aqua Corridor,
Beside Star Bazar, Adajan,
Surat-395009. Mo. 9825947712

DR. ADITYA S. BORA
M.D.B.S, DNB, PGDCC
PHYSICIAN & CLINICAL CARDIOLOGIST
G-54906
Signature

 0261-2747788, 98259 47712

 4th Floor, Aqua Corridor, Hazira Road, Adajan Pal, Surat - 395009.

 revivaldiagnostics.surat@gmail.com

 www.revivaldiagnostics.com



Name	RAKHI PRAKASH	Age/Gender	30Yrs/Female
Reg No.	1499/24	Receipt No	17022
Referred By	Bank of Baroda (BOB) - MEDI WHEEL()	Mode of Payment	CREDIT
Collection Type	CENTER	Collection DateTime	16-Feb-2024 08:59 AM

2D ECHO
2D ECHOCARDIOGRAPHY & COLOR DOPPLER REPORT

INDICATION: Preventive Health check up

- **CARDIAC CHAMBERS :** Left Ventricle : Normal size , Left Atrium: Normal size.
- NO e/o thrombus in LA/LV
- Right Atrium: Normal size. Right Ventricle: Normal Size,
- **Normal Right Ventricular function.** (TAPSE=20mm)
- **Normal Left Ventricular systolic function.** LVEF = 60%
- **No regional wall abnormality. No thinning / scarring / dyskinesia of LV wall**
- **No Left Ventricular Hypertrophy.** (IVSd= 10 mm),
- **LV Compliance:**
- **NO Left Ventricular Diastolic Dysfunction [LVDD].**

VALVES :

- Structurally Normal Mitral valve/ Aortic valve/Tricuspid valve/ Pulmonary valve .
- No significant Valvular Stenosis
- **Doppler findings: AV max = 1.23 m/s, PV max = 0.91 m/s.**
- Trivial MR, Trivial Tricuspid regurgitation.
- **No Pulmonary Arterial Hypertension.** PASP by TRjet vel.method = 24 mmHg.
- **SEPTAE:** IAS / IVS Appear Intact.
- **IVC :** Normal in dimension and shows good inspiratory 13mm collapse.
- **OTHERS:** No e/o Pericardial effusion / vegetation.

IMPRESSION:

**NORMAL LV SYSTOLIC FUNCTION, LVEF= 60 %, NO RWMA,
NO LVH , NO LVDD , NO PAH.**

Revival Diagnostics
401-Aqua Corridor,
Beside Star Bazar, Adajan,
Surat-395009. Mo. 9825947712

DR. ADITYA S. BORA
MBBS, DNB, PGCC
PHYSICIAN & CLINICAL CARDIOLOGIST
G-54906
Signature

0261-2747788, 98259 47712

4th Floor, Aqua Corridor, Hazira Road, Adajan Pal, Surat - 395009.

revivaldiagnostics.surat@gmail.com

www.revivaldiagnostics.com

M

NAME : RAKHI PRAKASH
AGE: 30 YRS / FEMALE
REF BY : MEDI WHEEL





REVIVAL DIAGNOSTICS

Name	RAKHI PRAKASH	Age/Gender	30Yrs/Female
Reg No.	1499/24	Receipt No	17022
Referred By	Bank of Baroda (BOB) - MEDI WHEEL()	Mode of Payment	CREDIT
Collection Type	CENTER	Collection DateTime	16-Feb-2024 08:59 AM

CHEST RADIOGRAPH (PA VIEW)

- Hilar shadows are within normal limits.
- Pulmonary vasculature appears normal.
- Cardiac appears normal in size.
- Both dome of the diaphragm are smooth.
- Both costophrenic recesses are clear.
- Both lung fields appear normal.
- Visualized bones and soft tissue shadows appear normal.

IMPRESSION: NORMAL STUDY.

DR. CHIRAG K PATEL
RADIOLOGIST

Dr. Chirag K. Patel
MBBS-DMPD
Reg. No. G-23509
Signature
Revival Diagnostic
4th Floor, Aqua Corridor,
Nr. Star Bazar, Hazira Main Road,
Adajan, Surat-395009.
Mob: 97266 726683

0261-2747788, 98259 47712

4th Floor, Aqua Corridor, Hazira Road, Adajan Pal, Surat - 395009.

revivaldiagnostics.surat@gmail.com

www.revivaldiagnostics.com





Name	RAKHI PRAKASH	Age/Gender	30Yrs/Female
Reg No.	1499/24	Receipt No	17022
Referred By	Bank of Baroda (BOB) - MEDI WHEEL()	Mode of Payment	CREDIT
Collection Type	CENTER	Collection DateTime	16-Feb-2024 08:59 AM

USG OF ABDOMEN & PELVIS

LIVER:

Liver is normal in size, shape and echotexture.
No evidence of focal SOL or dilatation of IHBR seen.
Portahepatis appear normal.

GALLBLADDER:

Gallbladder is distended and appears normal.
No e/o calculus, mass lesion or changes of cholecystitis seen.

PANCREAS:

Pancreas appears normal in size, shape and echotexture.
No e/o focal lesion, mass or changes of pancreatitis seen.

SPLEEN:

Spleen appears normal in size, shape and echotexture.

PARAAORTIC REGION:

Aorta grossly appears normal. No e/o paraaortic lymphnodes seen.

KIDNEYS:

Both kidneys appear normal in size, shape, position and echotexture.
Cortex and collecting system of both kidneys appear normal.
No evidence of calculus or obstructive uropathy on either side.

URINARY BLADDER:

Bladder is distended and appears normal.
No calculus, mass lesion or changes of cystitis is seen.

UTERUS:

Retroverted, Normal in size, shape and echotexture with empty central uterine cavity.
Cervix appears normal.

No e/o focal SOL. Endometrial thickness is normal.

OVARIES:

Both adnexal region appear normal.
No e/o adnexal mass lesion seen on either side.
No evidence of free fluid seen in pelvis.

COMMENTS: NORMAL USG ABDOMEN AND PELVIS.

Dr. Chirag K. Patel
MBBS-DMPD
Reg. No. G-23509
Revival Diagnostic
4th Floor, Aqua Corridor,
Nr. Star Bazar, Hazira Main Road,
Adajan, Surat
Radiologist
Mo. 97266 72683

0261-2747788, 98259 47712

4th Floor, Aqua Corridor, Hazira Road, Adajan Pal, Surat - 395009.

revivaldiagnostics.surat@gmail.com

www.revivaldiagnostics.com

