



Mrs Supriya Kumar
38/f

11/4/24

Vitals :

BP - 110/70
wt - 71
Height - 5.3

Chief Complaints :

Routine eye checkup

H/O Present Illness :

6/6
6/6 uncorrected

Met 14.5
12.2

Past History :

6/6
6/6

Investigation :

Drug Allergies : (if any)

Treatment :

Colour vision - Normal (138)

Fundus - Normal (138)



Park Hospital

GROUP SUPER SPECIALITY HOSPITAL



Supriya Kumari 38yr

came for Routine check up

LMP - 5/4/2024

Cycle - 30 ± 2

Vitals:

Chief Complaints:

Dwn - 4 day

Flow - Heavy in

H/O Present Illness:

1st 2 day

D/E

Breast - B/L sqf

Past History:

P2+0 (Both LSCS)

LCB - 6yr

P/S - Cx & Vagina apparently healthy

Investigation:

Drug Allergies: (if any)

PMH - ~~NAD~~

Hypothyroid on 75mcg OD

PSH - NAD

Treatment:

Allergy - NAD

P/V - 2 ut A/V

(N) size

B/L Fornices free nontender

T_{nv}

Adv

S. Vit B12

S. Vit D3

S. TSH, T3, T4

- follow up to report
- To Report in OPD on
status of menses if willing
for MIRENA

Gurgaon

Q Block South City 11, Sohna Road, Main Sector-47, Gurgaon, Haryana Ph.: 0124-4900000 Fax: 0124-2218733
E-mail: parkmedcenters@gmail.com

● West Delhi ● South Delhi ● Faridabad ● Panipat ● Karnal

the health care providers

the health care providers

insertion
Julie



MIRENA (Contraception)

MIRENA-IUS 0.1%

Pg rele 3-5yr

30% - amenorrhea

2-3% in 3 months

- first 3 months - 30% spotting

30% - Amenorrhea

70% - lighter Period

helps in fade over perimenopausal transition Easily



Dental

Routine health checkup.

Vitals :

Chief Complaints :

O/E:- Plaque ++ Calculus ++

H/O Present Illness :

Supernumerary tooth present in 28.

Past History :

*Adv. Extraction in 28 & supernumerary tooth
Scaling & Polishing.*

Investigation :

Drug Allergies : (if any)

Treatment :



ENT

Routine ENT check up

O/E - Ear - (A) TM - Tympanosclerotic patch.

NOSP Throat N/A.

Vitals :

Chief Complaints :


H/O Present Illness :

Past History :

Investigation :

Drug Allergies : (if any)

Treatment :


11/04/24



11/14/29

DERMATOLOGY

Supriya Kumari

Age 38y/F

Vitals :

Chief Complaints :

H/O Present Illness :

- Irresistible gold
sunscreens
DI.

Past History :

Da shield
fisico
sunscreens

Investigation :

Drug Allergies : (if any)

Treatment :

8am - 12pm

- R/v 80s

[Signature]



Vitals :

Chief Complaints :

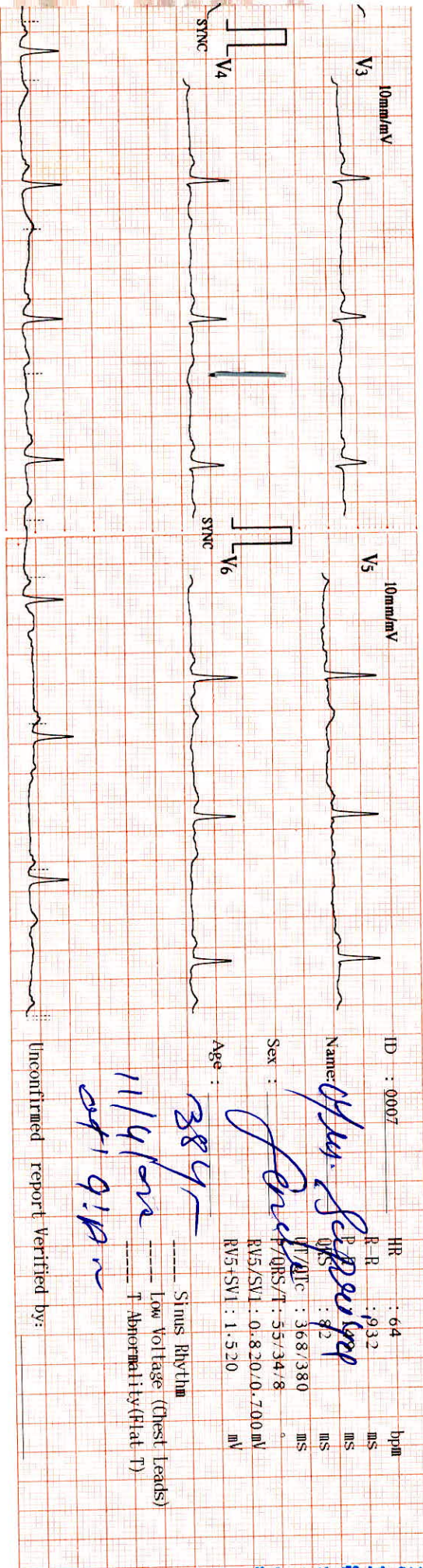
H/O Present Illness :

Past History :

Investigation :


Drug Allergies : (if any)

Treatment :

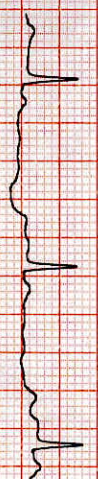


25mm/s 0.5-25Hz


I 10mm/mV



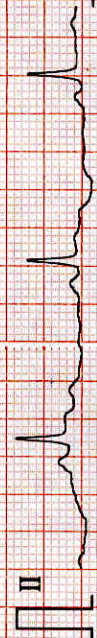aVR 40mm/mV



V1 10mm/mV



II



aVL



V2

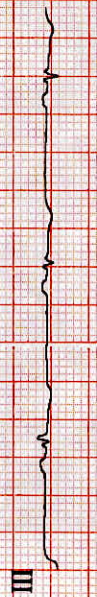


SYNC

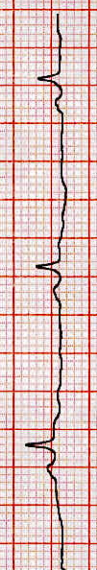SYNC

SYNC

III



aVF



10mm/mV



ECG-1205 V2-000(CBUS:V0-000/AMP:V1-001) 2016-00-00 00:00



DEPARTMENT OF BIOCHEMISTRY

Patient Name : Mrs. SUPRIYA KUMARI
MR No : 698393
Age/Sex : 38 Years / Female
Type : OPD
TPA/Corporate : MEDIWHEEL PVT LTD

Bill Date : 11/04/2024
Reporting Date : 11/04/2024
Sample ID : 271046
Bill/Req. No. : 25280354
Ref Doctor : Dr.RMO

Test	Result	Bio. Ref. Interval	Units	Method
BLOOD SUGAR FASTING				
PLASMA GLUCOSE FASTING	93.1	60 - 110	mg/dl	GOD TRINDERS

***** END OF THE REPORT *****



Sample no.

P Singh
Dr. JAY PRAKASH SINGH
MBBS, MD (PATHOLOGY)

Dr.ISHA RASTOGI
MD, MBBS MICROBIOLOGY
CONSULTANT CLINICAL MICROBIOLOGIST



MC - 4830

USER NM GAURAV

(This is only professional opinion and not the diagnosis, please correlate clinically)
Q Block, South City -II, Sohna Road, Sector-47, Gurgaon, Haryana

Ph.: 0124-4900000 (100 Lines), Toll Free No. : 1800-102-6767, Mob.: 62 62 82 82 35, Email: customercare@parkhospital.in Page 1 of 1

PARK GROUP OF HOSPITALS : West Delhi - Gurugram - Faridabad - Sonapat - Panipat - Karnal - Ambala - Patiala - Behror - Jaipur



DEPARTMENT OF BIOCHEMISTRY

Patient Name : Mrs. SUPRIYA KUMARI
MR No : 698393
Age/Sex : 38 Years / Female
Type : OPD
TPA/Corporate : MEDIWHEEL PVT LTD

Bill Date : 11/04/2024
Reporting Date : 11/04/2024
Sample ID : 271046
Bill/Req. No. : 25280354
Ref Doctor : Dr.RMO

Test	Result	Bio. Ref. Interval	Units	Method
BLOOD SUGAR 2 HR. PP				
BLOOD SUGAR P.P.	119	80 - 150	mg/dl	

***** END OF THE REPORT *****



Sample no.

Jay
Dr. JAY PRAKASH SINGH
MBBS, MD (PATHOLOGY)

Dr. ISHA RASTOGI
MD, MBBS MICROBIOLOGY
CONSULTANT CLINICAL MICROBIOLOGIST



MC - 4830

USER NM SONU

(This is only professional opinion and not the diagnosis, please correlate clinically)
Q Block, South City -II, Sohna Road, Sector-47, Gurgaon, Haryana

Ph.: 0124-4900000 (100 Lines), Toll Free No. : 1800-102-6767, Mob.: 62 62 82 82 35, Email: customercare@parkhospital.in

PARK GROUP OF HOSPITALS : West Delhi - Gurugram - Faridabad - Sonapat - Panipat - Karnal - Ambala - Patiala - Behror - Jaipur



DEPARTMENT OF HAEMATOLOGY

Patient Name : Mrs. SUPRIYA KUMARI
MR No : 698393
Age/Sex : 38 Years / Female
Type : OPD
TPA/Corporate : MEDIWHEEL PVT LTD

Bill Date : 11/04/2024
Reporting Date : 12/04/2024
Sample ID : 271046
Bill/Req. No. : 25280354
Ref Doctor : Dr.RMO

Test	Result	Bio. Ref. Interval	Units	Method
BLOOD GROUPING AND RH FACTOR				
BLOOD GROUP	" B " RH POSITIVE			ABO/Rh (D) SLIDE

***** END OF THE REPORT *****



Sample no.

Jay
Dr. JAY PRAKASH SINGH
MBBS, MD (PATHOLOGY)

Dr.ISHA RASTOGI
MD, MBBS MICROBIOLOGY
CONSULTANT CLINICAL MICROBIOLOGIST



USER NM GAURAV

(This is only professional opinion and not the diagnosis, please correlate clinically)
Q Block, South City -II, Sohna Road, Sector-47, Gurgaon, Haryana

Ph.: 0124-4900000 (100 Lines), Toll Free No. : 1800-102-6767, Mob.: 62 62 82 82 35, Email: customercare@parkhospital.in

PARK GROUP OF HOSPITALS : West Delhi - Gurugram - Faridabad - Sonapat - Panipat - Karnal - Ambala - Patiala - Behror - Jaipur



DEPARTMENT OF HAEMATOLOGY

Patient Name : Mrs. SUPRIYA KUMARI
MR No : 698393
Age/Sex : 38 Years / Female
Type : OPD
TPA/Corporate : MEDIWHEEL PVT LTD

Bill Date : 11/04/2024
Reporting Date : 11/04/2024
Sample ID : 271046
Bill/Req. No. : 25280354
Ref Doctor : Dr.RMO

Test	Result		Bio. Ref. Interval	Units	Method
CBC					
HAEMOGLOBIN	11.1	L	12 - 15	gm/dL	COLORIMETRY
TOTAL LEUCOCYTE COUNT	4800		4000-11000	/μL	LASER FLOW
DIFFERENTIAL COUNT					
NEUTROPHILS	70		40.0 - 70.0	%	FLOW CYTOMETRY
LYMPHOCYTES	25		20.0 - 40.0	%	FLOW CYTOMETRY
MONOCYTES	03		3.0 - 8.0	%	FLOW CYTOMETRY
EOSINOPHILS	02		0.5 - 5.0	%	FLOW CYTOMETRY
BASOPHILS	00		0.0 - 2.0	%	FLOW CYTOMETRY
RED BLOOD CELL COUNT	3.9		3.5 - 5.5	millions/μL	ELECTRICAL
PACKED CELL VOLUME	36.4		35.0 - 50.0	%	ELECTRICAL
MEAN CORPUSCULAR VOLUME	92.0		83 - 101	fL	ELECTRICAL
MEAN CORPUSCULAR HAEMOGLOBIN	28.0		27 - 31	Picograms	CALCULATED
MEAN CORPUSCULAR HB CONC	30.5	L	33 - 37	g/dl	CALCULATED
PLATELET COUNT	236		150 - 450	thou/μL	ELECTRICAL
RDW	13.4		11.6 - 14.5	%	CALCULATED
SAMPLE TYPE FOR C.B.C	Whole Blood EDTA				

***** END OF THE REPORT *****



Sample no.

Jay
Dr. JAY PRAKASH SINGH
 MBBS, MD (PATHOLOGY)

Dr. ISHA RASTOGI
 MD, MBBS MICROBIOLOGY
 CONSULTANT CLINICAL MICROBIOLOGIST

USER NM SONU



MC - 4830

(This is only professional opinion and not the diagnosis, please correlate clinically)
 Q Block, South City -II, Sohna Road, Sector-47, Gurgaon, Haryana

Ph.: 0124-4900000 (100 Lines), Toll Free No. : 1800-102-6767, Mob.: 62 62 82 82 35, Email: customercare@parkhospital.in

PARK GROUP OF HOSPITALS : West Delhi - Gurugram - Faridabad - Sonapat - Panipat - Karnal - Ambala - Patiala - Behror - Jaipur



DEPARTMENT OF HAEMATOLOGY

Patient Name : Mrs. SUPRIYA KUMARI
MR No : 698393
Age/Sex : 38 Years / Female
Type : OPD
TPA/Corporate : MEDIWHEEL PVT LTD

Bill Date : 11/04/2024
Reporting Date : 11/04/2024
Sample ID : 271046
Bill/Req. No. : 25280354
Ref Doctor : Dr.RMO

Test	Result	Bio. Ref. Interval	Units	Method
ESR (WESTERGREN)				
E.S.R. 1ST HRS.	20	0 - 20	mm/Hr.	Westergren
Method : (Capillary photometry)				

- Note** :
1. C-Reactive Protein (CRP) is the recommended test in acute inflammatory conditions.
 2. Test conducted on EDTA whole blood at 37C.
 3. ESR readings are auto- corrected with respect to Hematocrit (PCV) values.

***** END OF THE REPORT *****



Sample no.

Jay
Dr. JAY PRAKASH SINGH
MBBS, MD (PATHOLOGY)

Dr.ISHA RASTOGI
MD, MBBS MICROBIOLOGY
CONSULTANT CLINICAL MICROBIOLOGIST



MC - 4830

USER NM SONU

(This is only professional opinion and not the diagnosis, please correlate clinically)
Q Block, South City -II, Sohna Road, Sector-47, Gurgaon, Haryana

Ph.: 0124-4900000 (100 Lines), Toll Free No. : 1800-102-6767, Mob.: 62 62 82 82 35, Email: customercare@parkhospital.in

PARK GROUP OF HOSPITALS : West Delhi - Gurugram - Faridabad - Sonipat - Panipat - Karnal - Ambala - Patiala - Behror - Jaipur



DEPARTMENT OF IMMUNOLOGY

Patient Name : Mrs. SUPRIYA KUMARI
MR No : 698393
Age/Sex : 38 Years / Female
Type : OPD
TPA/Corporate : MEDIWHEEL PVT LTD

Bill Date : 11/04/2024
Reporting Date : 11/04/2024
Sample ID : 271046
Bill/Req. No. : 25280354
Ref Doctor : Dr.RMO

Test	Result	Bio. Ref. Interval	Units	Method
THYROID PROFILE				
TRI-IODOTHYRONINE (T3)	0.88	0.60 - 1.81	ng/ml	Chemiluminescence
THYROXINE (T4)	8.1	5.01 - 12.45	µg/dL	Chemiluminescence
THYROID STIMULATING HORMONE	3.45	0.5-5.50 ,	µIU/ml	
SPECIMEN TYPE	SERUM			
Method : chemiluminescent immunoassay				

Note : Clinical Significance:
 Thyroid function tests (TFTs) is a collective term for blood tests used to check the function of the thyroid. TFTs may be requested if a patient is thought to suffer from hyperthyroidism (overactive thyroid) or hypothyroidism (underactive thyroid), or to monitor the effectiveness of either thyroid-suppression or hormone replacement therapy. It is also requested routinely in conditions linked to thyroid disease, such as atrial fibrillation and anxiety disorder. A TFT panel typically includes thyroid hormones such as thyroid-stimulating hormone (TSH, thyrotropin) and thyroxine (T4), and triiodothyronine (T3) depending on local laboratory policy.

Note: Please correlate with clinical condition

***** END OF THE REPORT *****



Sample no.

Signature
Dr. JAY PRAKASH SINGH
 MBBS, MD (PATHOLOGY)

Dr. ISHA RASTOGI
 MD, MBBS MICROBIOLOGY
 CONSULTANT CLINICAL MICROBIOLOGIST



USER NM DINESH

(This is only professional opinion and not the diagnosis, please correlate clinically)
 Q Block, South City -II, Sohna Road, Sector-47, Gurgaon, Haryana

Ph.: 0124-4900000 (100 Lines), Toll Free No. : 1800-102-6767, Mob.: 62 62 82 82 35, Email: customercare@parkhospital.in

PARK GROUP OF HOSPITALS : West Delhi - Gurugram - Faridabad - Sonapat - Panipat - Karnal - Ambala - Patiala - Behror - Jaipur



DEPARTMENT OF BIOCHEMISTRY

Patient Name : Mrs. SUPRIYA KUMARI
MR No : 698393
Age/Sex : 38 Years / Female
Type : OPD
TPA/Corporate : MEDIWHEEL PVT LTD

Bill Date : 11/04/2024
Reporting Date : 11/04/2024
Sample ID : 271046
Bill/Req. No. : 25280354
Ref Doctor : Dr.RMO

Test	Result	Bio. Ref. Interval	Units	Method
LFT (LIVER FUNCTION TEST)				
LFT				
TOTAL BILIRUBIN	0.48	0 - 1.2	mg/dL	DIAZO
DIRECT BILIRUBIN	0.23	0 - 0.4	mg/dL	DIAZO
INDIRECT BILIRUBIN	0.25	0.10 - 0.6	mg/dL	CALCULATED
SGOT (AST)	10.9	0 - 45	U/L	IFCC WITHOUT
SGPT (ALT)	17.9	0 - 45	U/L	IFCC WITHOUT
ALKALINE PHOSPHATASE	74.7	30 - 170	IU/L	MODIFIED IFCC
TOTAL PROTEINS	7.1	6.4 - 8.0	g/dL	BIURET
ALBUMIN	3.7	3.3 - 5.5	g/dL	BCG DYE
GLOBULIN	3.4	2.3 - 4.5	g/dL	CALCULATED
A/G RATIO	1.09	L 1.1 - 2.2		CALCULATED
SAMPLE TYPE:	SERUM			

***** END OF THE REPORT *****



Sample no.

Pay
Dr. JAY PRAKASH SINGH
 MBBS, MD (PATHOLOGY)

Dr.ISHA RASTOGI
 MD, MBBS MICROBIOLOGY
 CONSULTANT CLINICAL MICROBIOLOGIST



USER NM GAURAV

(This is only professional opinion and not the diagnosis, please correlate clinically)
 Q Block, South City -II, Sohna Road, Sector-47, Gurgaon, Haryana

Ph.: 0124-4900000 (100 Lines), Toll Free No. : 1800-102-6767, Mob.: 62 62 82 82 35, Email: customercare@parkhospital.in

PARK GROUP OF HOSPITALS : West Delhi - Gurugram - Faridabad - Sonipat - Panipat - Karnal - Ambala - Patiala - Behror - Jaipur



DEPARTMENT OF BIOCHEMISTRY

Patient Name : Mrs. SUPRIYA KUMARI
MR No : 698393
Age/Sex : 38 Years / Female
Type : OPD
TPA/Corporate : MEDIWHEEL PVT LTD

Bill Date : 11/04/2024
Reporting Date : 11/04/2024
Sample ID : 271046
Bill/Req. No. : 25280354
Ref Doctor : Dr.RMO

Test	Result	Bio. Ref. Interval	Units	Method
KFT (RENAL PROFILE)				
KFT				
SERUM UREA	17.0	10 - 45	mg/dL	
SERUM CREATININE	0.7	0.4 - 1.4	mg/dL	MODIFIED JAFFES
SERUM URIC ACID	5.4	2.5 - 7.0	mg/dL	URICASE
SERUM SODIUM	136	135 - 150	mmol/L	ISE
SERUM POTASSIUM	3.5	3.5 - 5.5	mmol/L	ISE
SERUM CALCIUM	8.5	8.5 - 10.5	mg/dL	ARSENazo III
SERUM PHOSPHORUS	3.3	2.5 - 4.5	mg/dL	AMMONIUM
SAMPLE TYPE:	SERUM			

***** END OF THE REPORT *****



Jay
Dr. JAY PRAKASH SINGH
MBBS, MD (PATHOLOGY)

Dr. ISHA RASTOGI
MD, MBBS MICROBIOLOGY
CONSULTANT CLINICAL MICROBIOLOGIST



USER NM GAURAV

(This is only professional opinion and not the diagnosis, please correlate clinically)
Q Block, South City -II, Sohna Road, Sector-47, Gurgaon, Haryana

Ph.: 0124-4900000 (100 Lines), Toll Free No. : 1800-102-6767, Mob.: 62 62 82 82 35, Email: customercare@parkhospital.in

PARK GROUP OF HOSPITALS : West Delhi - Gurugram - Faridabad - Sonapat - Panipat - Karnal - Ambala - Patiala - Behror - Jaipur



NAME	: MRS.SUPRIYA KUMARI	DATE	: 11 / 4 / 2024
Age Sex	: 38 Years / Female	Inpatient No	: 698393
PERFORMED BY	: Dr. SWATI SINGH	BILL NO.	: 25280354

TRANS THORACIC ECHO CARDIOGRAPHY REPORT

MITRAL VALVE

Morphology AML: Normal / Thickening / Calcification / Flutter / Vegetation / Non significant Prolapse / SAM
PML: Normal / Thickening / Calcification / Prolapse / Paradoxical Motion / Fixed.
Subvalvular deformity: Present / Absent

Doppler Normal / Abnormal
Mitral Stenosis Present / Absent
Mitral Regurgitation; Absent / Normal / Mild / Trace / Moderate / Severe

TRICUSPID VALVE

Morphology Normal / Atresia / Thickening / Calcification / Prolapse / Vegetation / Doming.
Doppler Normal / Abnormal
Tricuspid Stenosis: Present / Absent.
Tricuspid Regurgitation: Absent / Mild / Trace / Moderate / Trivial
PASP – 12mm Hg + RAP

PULMONARY VALVE

Morphology Normal / Atresia / Thickening / Calcified / Doming / Vegetation.
Doppler Normal / Abnormal.
Pulmonary Stenosis: Present / Absent
Pulmonary regurgitation: Present / Absent

AORTIC VALVE

Morphology Normal / Thickened / Mildly / Calcified / Flutter / Vegetation / Restricted / Opening
No. of Cusps 1 / 2 / 3 / 4
Doppler Normal / Abnormal
Aortic Stenosis : Present / Absent
Aortic regurgitation : Present / Absent / Mild / Trace / Low Moderate / Severe



Cert. No. H-2016-0369

(This is only professional opinion and not the diagnosis, please correlate clinically)
Q Block, South City -II, Sohna Road, Sector-47, Gurgaon, Haryana

Ph.: 0124-4900000 (100 Lines), Toll Free No. : 1800-102-6767, Mob.: 62 62 82 82 35, Email: customercare@parkhospital.in

PARK GROUP OF HOSPITALS : West Delhi - Gurugram - Faridabad - Sonapat - Panipat - Karnal - Ambala - Patiala - Behror - Jaipur



Park Hospital

GROUP SUPER SPECIALITY HOSPITAL

<u>Measurements</u>	<u>Normal Values</u>	<u>Measurements</u>	<u>Normal Value</u>
IVSD : 0.8cm	(0.6-1.1cm)	LA : 3.4cm	(1.9-4.0cm)
LVIDd : 4.7cm	(3.7-5.6cm)	AORTA : 2.6cm	(2.0-3.7cm)
LVIDs : 2.3cm		IVSmotion :	Normal / Flat / Paradoxical
EF : 55-60%	(55% - 80%)		
Any Other			

CHAMBERS:-

LV **Normal** / Enlarged / **Clear** / Thrombus /
Contraction Normal LV shows concentric LVH, no gradient across LVOT / Inetic / Intra capillary
Regional wall motion abnormality: **Absent**/ Present

LA **Normal** / Enlarged / Clear / Thrombus / Myxoma; **LAA: Clear** / Thrombus

RA **Normal** / **Clear** / Thrombus, Dilated.

RV **Normal** / Mildly Dilated / Enlarged / **Clear** / Thrombus / Hypertrophied


PERICARDIUM **Normal** / Thickening / Calcification / Effusion.

SUMMARY:-

- All Cardiac Chambers dimensions are within normal limits.
- NO RWMA
- LVEF -55-60%
- NORMAL LV FUNCTION
- LVDD GRADE -I
- NO MR / NO AR
- TRIVIAL TR, PASP - 12mm Hg + RAP
- GOOD RV FUNCTION
- IAS/IVS. No Flow seen across IAS/IVS.
- No Thrombus/Mass in any chamber.
- No Pericardial Effusion.

COMMENTS:- Normal LV Function.

Please correlate clinically


Dr. SWATI SINGH
M.D. (Medicine)
D.M. (Cardiology)



Cert. No. H-2016-0369

(This is only professional opinion and not the diagnosis, please correlate clinically)
Q Block, South City -II, Sohna Road, Sector-47, Gurgaon, Haryana

Ph.: 0124-4900000 (100 Lines), Toll Free No. : 1800-102-6767, Mob.: 62 62 82 82 35, Email: customercare@parkhospital.in

PARK GROUP OF HOSPITALS : West Delhi - Gurugram - Faridabad - Sonapat - Panipat - Karnal - Ambala - Patiala - Behror - Jaipur

the **health** care providers the **health** care providers



DEPARTMENT OF RADIOLOGY

Patient Name	Mrs. SUPRIYA KUMARI	Billed Date	: 11/04/2024
Reg No	698393	Reported Date	: 11/04/2024
Age/Sex	38 Years / Female	Req. No.	: 25280354
Type	OPD	Consultant Doctor	: Dr. RMO

USG WHOLE ABDOMEN

The real time, B mode, gray scale sonography of the abdominal organs was performed.

LIVER : The liver is normal in size 14.8cm **with fatty infiltration**. No evidence of any focal lesion. IHBR is not dilated.

GALL BLADDER : The gall bladder is well distended. No evidence any calculus or mass seen. GB wall thickness within normal limits. No evidence of pericholecystic fluid is seen.

BILE DUCT : The common bile duct is normal in caliber. No evidence of calculus is noted in common bile duct.

SPLEEN : The spleen is normal in size 9.8cm and shape. Its echotexture is homogeneous. No evidence of focal lesion is noted.

PANCREAS : The pancreas is normal in size, shape, contours and echotexture. No evidence of solid or cystic mass lesion is noted. MPD is not dilated. No evidence of peripancreatic collection.

KIDNEYS : RK:10.1x4.4cm. LK:11.1x5.3cm.

The bilateral kidneys are normal in size and echotexture. Cortico-medullary differentiation is maintained. There is no evidence of obvious calculus or hydronephrosis.

URINARY BLADDER : The urinary bladder is well distended. It shows uniformly thin walls and sharp mucosa. No evidence of calculus is seen. No evidence of mass or diverticulum is noted.

UTERUS: The uterus is retroflexed. It measures 6.3x3.2x3.6__cms. in the longitudinal, anteroposterior and transverse dimensions respectively. The uterine margins are smooth and does not reveal any contour abnormalities.

The uterine myometrium shows homogeneous echotexture.

No evidence of leiomyoma is noted. No solid or cystic mass lesion is noted.

The endometrial echo is in the midline and measures _6.1_mm.

The ovaries on the either side show normal echotexture.

No adnexal mass is seen. No cyst is seen in ovaries.

No evidence of ascites or interpower free fluid is seen.

No evidence of obvious retroperitoneal or mesenteric lymphadenopathy is seen.

(This is only professional opinion and not the diagnosis, please correlate clinically)

Q Block, South City -II, Sohna Road, Sector-47, Gurgaon, Haryana

Ph.: 0124-4900000 (100 Lines), Toll Free No. : 1800-102-6767, Mob.: 62 62 82 82 35, Email: customercare@parkhospital.in

PARK GROUP OF HOSPITALS : West Delhi - Gurugram - Faridabad - Sonapat - Panipat - Karnal - Ambala - Patiala - Behror - Jaipur

Bowel loop distended with gas.



Park Hospital

GROUP SUPER SPECIALITY HOSPITAL

IMPRESSION- Fatty liver grade-I

To be correlated clinically.

MS

Dr. ANSHU K. SHARMA
MBBS, MD
CONSULTANT RADIOLOGIST
MC - 4830



Dr. MANJEET SEHRAWAT
MBBS, MD, PDCC
CONSULTANT RADIOLOGIST

ALISHA KHAN
MEDICAL TRANSCRIPTIONIST

Dr. NEENA SIKKA
MBBS, DNB
CONSULTANT RADIOLOGIST

RAJNISH SHARMA
MEDICAL
TRANSCRIPTIONIST

(This is only professional opinion and not the diagnosis, please correlate clinically.)
Q Block, South City -II, Sohna Road, Sector-47, Gurgaon, Haryana

Ph.: 0124-4900000 (100 Lines), Toll Free No. : 1800-102-6767, Mob.: 62 62 82 82 35, Email: customercare@parkhospital.in

PARK GROUP OF HOSPITALS : West Delhi - Gurugram - Faridabad - Sonapat - Panipat - Karnal - Ambala - Patiala - Behror - Jaipur



Park Hospital

GROUP SUPER SPECIALITY HOSPITAL

DEPARTMENT OF RADIOLOGY

Patient Name	Mrs. SUPRIYA KUMARI	Billed Date	: 11/04/2024
Reg No	698393	Reported Date	: 11/04/2024
Age/Sex	38 Years / Female	Req. No.	: 25280354
Type	OPD	Consultant Doctor	: Dr. RMO

X-RAY CHEST AP/PA

Bilateral lungs appears normal.

No focal lung lesion seen.

No evidence of free fluid is seen.

Both hila are normal in size, have equal density and bear normal relationship.

The heart and trachea are central in position and no mediastinal abnormality is visible.

The cardiac size is normal for patient age and view.

The domes of the diaphragms are normal in position, and show smooth outline.

To be correlated clinically

Dr. ANSHU K. SHARMA
MBBS, MD
CONSULTANT RADIOLOGIST



Dr. MANJEET SEHRAWAT
MBBS, MD, PDCC
CONSULTANT RADIOLOGIST

ALISHA KHAN
MEDICAL TRANSCRIPTIONIST

Dr. NEENA SIKKA
MBBS, DNB
CONSULTANT RADIOLOGIST

RAJNISH SHARMA
MEDICAL
TRANSCRIPTIONIST

(This is only professional opinion and not the diagnosis, please correlate clinically)

Q Block, South City -II, Sohna Road, Sector-47, Gurgaon, Haryana

Ph.: 0124-4900000 (100 Lines), Toll Free No. : 1800-102-6767, Mob.: 62 62 82 82 35, Email: customercare@parkhospital.in

PARK GROUP OF HOSPITALS : West Delhi - Gurugram - Faridabad - Sonipat - Panipat - Karnal - Ambala - Patiala - Behror - Jaipur