



भारत सरकार
Government of India



Issue Date: 21/09/2013



Namita
DOB : 20/05/1985
Female



6848 2657 1769



6848 2657 1769

मेरा **आधार**, मेरी पहचान

भारत सरकार
Government of India

आधार

Issue Date: 21/06/2013

Namita
DOB : 20/05/1985
Female

6848 2657 1769

मेरा आधार, मेरी पहचान

Handwritten signature

Handwritten signature
DR. NITIN AGARWAL
MBBS, MD
Regn. No. DMC-R-1436

भारतीय विशिष्ट पहचान प्राधिकरण
Unique Identification Authority of India

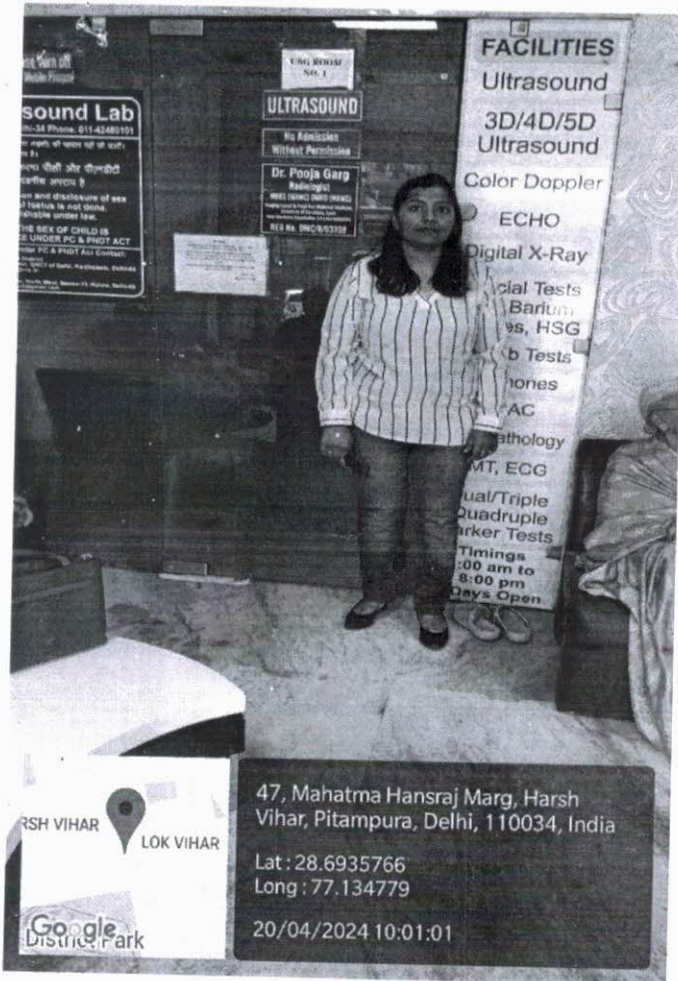
Address: Bhuvan Aggarwal, 5C-62, New
Rohtak Road, Karol Bagh, Central Delhi,
Delhi, 110005


Print Date: 18/12/2021

6848 2657 1769

1947 help@uidai.gov.in www.uidai.gov.in

ONEPLUS ULTRASOUND LAB
47 Harsh Vihar, Pitam Pura,
Delhi-110034
Ph. 011-42480101, 9599913051
E-mail onepusuk@gmail.com




Dr. NITIN AGARWAL
 MBBS, MD
 Regn. No. DMC-R-1436



ONEPLUS ULTRASOUND LAB
 47 Harsh Vihar, Pitam Pura,
 Delhi-110034
 Ph. 011-42480101, 9599913051
 E-mail onepusuk@gmail.com



NABL
MC - 6036



NAME	:Mrs. NAMITA	Barcode No	:10170062
AGE/GENDER	:38 YRS/Female	SPECIMEN DATE	:20/Apr/2024 09:51AM
PATIENT ID	:134402	SPECIMEN RECEIVED	:20/Apr/2024 10:07AM
REFERRED BY	:Dr. MEDIWHEEL	REPORT DATE	:20/Apr/2024 04:37PM
CENTRE NAME	:ONEPLUS ULTRASOUND LAB	LAB NO.	:012404200016

Test Name	Result	Unit	Ref. Range
-----------	--------	------	------------

HAEMATOLOGY

MediWheel Health checkup < 40 Female

Sample Type:EDTA Blood

Glycosylated Hemoglobin (HbA1c)
HPLC

5.5

%

Non Diabetic adults <5.7
Prediabetic (at risk) 5.7-6.4
Diabetes >6.4

Estimated average blood glucose (eag)
CALCULATED


111

Reference range (mg/dl):

90 - 120:Excellent control, 121 - 150:Good Control, 151 - 180:Average Control, 181 - 210:Action Suggested

>211:Panic value

Checked By.

Dr NITIN AGARWAL
MBBS
DMC/R/01436

DR. NITIN AGARWAL
MBBS,MD(PATHOLOGIST)

47, Harsh Vihar, Pitampura, Delhi-34 ☎ 011-4248 0101, 9599913051

✉ Email: oneplusul@gmail.com 🌐 www.oneplusul.in

Page 1 of 8
Page 3 of 3

- Clinical correlation is essential for final diagnosis. • If test results are unsatisfactory please contact personally or on phone.
- This report is for perusal of doctors only. • All disputes are subject to Delhi jurisdiction only. • Not for medico legal case.
- All congenital anomalies in a foetus may not be diagnosed in routine obstetric ultrasound.



OnePLUS

Ultrasound Lab

— QUALITY FIRST... ALWAYS! —

Dr. Nitin Agarwal

Pathologist & Director
MBBS, MD, FAGE
Ex. Chief of Lab
Dr. Lal Path labs.

Dr. Pooja (Garg) Agarwal

Radiologist & Director
MBBS (MAMC) DMRD (MAMC)
Imaging Expert In Fetal And Maternal Medicine.
University of Barcelona, Spain
Fetal Medicine Foundation (UK) Accreditation



NAME	:Mrs. NAMITA	Barcode No	:10170062
AGE/GENDER	:38 YRS/Female	SPECIMEN DATE	:20/Apr/2024 09:51AM
PATIENT ID	:134402	SPECIMEN RECEIVED	:20/Apr/2024 10:07AM
REFERRED BY	:Dr. MEDIWHEEL	REPORT DATE	:20/Apr/2024 04:37PM
CENTRE NAME	:ONEPLUS ULTRASOUND LAB	LAB NO.	:012404200016

Test Name	Result	Unit	Ref. Range
-----------	--------	------	------------

HAEMATOLOGY

BLOOD GROUP (ABO)

Forward and Reverse grouping (Slide & Tube)

Rh typing

O

POSITIVE

NOTE :

- * Apart from major A,B,H antigens which are used for ABO grouping and Rh typing, many minor blood group antigens exist. Agglutination may also vary according to titre of antigen and antibody.
- * So before transfusion, reconfirmation of blood group as well as cross-matching is needed.
- * Presence of maternal antibodies in newborns, may interfere with blood grouping.
- * Auto agglutination (due to cold antibody, falciparum malaria, sepsis, internal malignancy etc.) may also cause erroneous result.

Checked By.

Dr NITIN AGARWAL
MBBS, MD (Path)
DMG/R/01436

DR. NITIN AGARWAL
MBBS,MD(PATHOLOGIST)

47, Harsh Vihar, Pitampura, Delhi-34 ☎ 011-4248 0101, 9599913051

✉ Email: oneplusul@gmail.com 🌐 www.oneplusul.in

- Clinical correlation is essential for final diagnosis. • If test results are unsatisfactory please contact personally or on phone.
- This report is for perusal of doctors only. • All disputes are subject to Delhi jurisdiction only. • Not for medico legal case.
- All congenital anomalies in a foetus may not be diagnosed in routine obstetric ultrasound.



OnePLUS
Ultrasound Lab
— QUALITY FIRST... ALWAYS! —



NABL
MC - 6036

Dr. Nitin Agarwal

Pathologist & Director
MBBS, MD, FAGE
Ex. Chief of Lab
Dr. Lal Path labs.

Dr. Pooja (Garg) Agarwal

Radiologist & Director
MBBS (MAMC) DMRD (MAMC)
Imaging Expert In Fetal And Maternal Medicine,
University of Barcelona, Spain
Fetal Medicine Foundation (UK) Accreditation



NAME	:Mrs. NAMITA	Barcode No	:10170062
AGE/GENDER	:38 YRS/Female	SPECIMEN DATE	:20/Apr/2024 09:51AM
PATIENT ID	:134402	SPECIMEN RECEIVED	:20/Apr/2024 10:07AM
REFERRED BY	:Dr. MEDIWHEEL	REPORT DATE	:20/Apr/2024 04:37PM
CENTRE NAME	:ONEPLUS ULTRASOUND LAB	LAB NO.	:012404200016

Test Name	Result	Unit	Ref. Range
HAEMATOLOGY			
CBC			
Haemoglobin	11.3	g/dl	12.0-15.0
Non cyanide Hb analysis			
Total Leucocyte Count	6900	/cumm	4000-10000
Electrical Impedance			
Differential leucocyte count			
Neutrophils	68.8	%	40-80
Electrical Impedance & Microscopic			
Lymphocyte	25.10	%	20-40
Electrical Impedance & Microscopic			
Monocytes	4.00	%	2-10
Electrical Impedance & Microscopic			
Eosinophils	2.0	%	1-6
Electrical Impedance & Microscopic			
Basophils	0.1	%	0-2
Electrical Impedance & Microscopic			
RBC Count	4.10	million/cumm	4.5 - 5.5
Electrical Impedance			
Hematocrit(PCV)	35.7	%	36-46
Flow Cytometry			
MCV	86.8	fl	83-101
Calculated			
MCH	27.6	pg	27-32
Calculated			
MCHC	31.8	g/dL	31.5-34.5
Calculated			
RDW-CV	15.1	%	11.4-14.0
Calculated			
Platelet count	231000	/cumm	150000-410000
Electrical Impedance			

BIOCHEMISTRY

Sample Type:Fluoride F			
Blood sugar fasting	86	mg/dl	70-100 mg/dl
GOD-POD			

Checked By.

DR. NITIN AGARWAL
MBBS, MD (Path)
MBBS, MD (PATHOLOGY)
DPC/R/01436

47, Harsh Vihar, Pitampura, Delhi-34 ☎ 011-4248 0101, 9599913051

✉ Email: oneplusul@gmail.com 🌐 www.oneplusul.in

- Clinical correlation is essential for final diagnosis. • If test results are unsatisfactory please contact personally or on phone.
- This report is for perusal of doctors only. • All disputes are subject to Delhi jurisdiction only. • Not for medico legal case.
- All congenital anomalies in a foetus may not be diagnosed in routine obstetric ultrasound.



NAME	:Mrs. NAMITA	Barcode No	:10170062
AGE/GENDER	:38 YRS/Female	SPECIMEN DATE	:20/Apr/2024 09:51AM
PATIENT ID	:134402	SPECIMEN RECEIVED	:20/Apr/2024 10:07AM
REFERRED BY	:Dr. MEDIWHEEL	REPORT DATE	:20/Apr/2024 04:37PM
CENTRE NAME	:ONEPLUS ULTRASOUND LAB	LAB NO.	:012404200016

Test Name	Result	Unit	Ref. Range
Sample Type:Serum			
Bun (blood urea nitrogen) Calculated	13.50	mg/dl	8.9-21.6
Uric Acid, serum Uricase- PAP	4.6	mg/dl	3.5-7.2
Creatinine, serum Enzymatic	0.6	mg/dl	0.71-1.16
LFT(LIVER FUNCTION TEST)			
Bilirubin Total Modified tab	0.58	mg/dl	0.1-0.9
Bilirubin Conjugated Diazotied sulfanilic acid	0.24	mg/dl	0-0.4
Bilirubin Unconjugated Calculated	0.34	mg/dl	up to 0.7
SGOT (AST) Tris buffer	18	U/L	0-46
SGPT (ALT) Tris buffer	27	U/L	0-49
Alkaline phosphatase Amp buffer	95	U/L	40-129
GAMMA GT Szasz Method	28	U/L	10-45
Total Protein Biuret	6.9	gm/dl	6.60 - 8.70
Albumin serum BCG	3.8	g/dL	3.0-5.2
Globulin Calculated	3.10	gm/dl	1.8-3.4
Albumin/Globulin Ratio Calculated	1.23		1.10 - 2.50
LIPID PROFILE			
Cholesterol CHOD-PAP	123	mg/dl	50-200
Triglycerides GPO-PAP	56	mg/dL	25-150
HDL Cholesterol Selective Inhibition	46	mg/dL	40-60

Checked By.

DR. NITIN AGARWAL
MBBS, MD (Path)
DMC/R/01436
DR. NITIN AGARWAL
MBBS, MD (PATHOLOGIST)

47, Harsh Vihar, Pitampura, Delhi-34 ☎ 011-4248 0101, 9599913051

✉ Email: oneplusul@gmail.com 🌐 www.oneplusul.in

Page 4 of 8

- Clinical correlation is essential for final diagnosis. • If test results are unsatisfactory please contact personally or on phone.
- This report is for perusal of doctors only. • All disputes are subject to Delhi jurisdiction only. • Not for medico legal case.
- All congenital anomalies in a foetus may not be diagnosed in routine obstetric ultrasound.



NABL
MC - 6036



NAME	:Mrs. NAMITA	Barcode No	:10170062
AGE/GENDER	:38 YRS/Female	SPECIMEN DATE	:20/Apr/2024 09:51AM
PATIENT ID	:134402	SPECIMEN RECEIVED	:20/Apr/2024 10:07AM
REFERRED BY	:Dr. MEDIWHEEL	REPORT DATE	:20/Apr/2024 04:37PM
CENTRE NAME	:ONEPLUS ULTRASOUND LAB	LAB NO.	:012404200016

Test Name	Result	Unit	Ref. Range
LDL cholesterol Calculated	66	mg/dL	<130
VLDL cholesterol Calculated	11.2	mg/dL	5-40
Cholesterol/HDL Ratio Calculated	2.7		Low Risk 3.3-4.97 Average Risk 4.4-7.1 Moderate Risk 7.1-11.0 High Risk >11.0
LDL/HDL Ratio Calculated	1.4		0 - 3.55

LDL Cholesterol	Total Cholesterol	HDL Cholesterol
<100 Optimal	<200 Desirable	<40 Low
100-129 Near optimal	200-239 Borderline high	>60 High
130-159 Borderline high	>240 High	
160-189 High		
>190 Very high		

According to NCEP, ATP-III Guidelines

	BUN/Creatinine ratio		
UREA UREASE-GLDH	29.00	mg/dl	15-45
Bun (blood urea nitrogen) Calculated	13.55	mg/dl	8.9-21.6
CREATININE ENZYMATIC	0.60	mg/dl	0.30-1.10
Bun/Creatinine Ratio Calculated	22.58		10.0 - 20.0

Checked By.

Dr NITIN AGARWAL
MBBS, MD (Path)
DMC/R/01436
DR. NITIN AGARWAL
MBBS,MD(PATHOLOGIST)

47, Harsh Vihar, Pitampura, Delhi-34 ☎ 011-4248 0101, 9599913051

✉ Email: oneplusul@gmail.com 🌐 www.oneplusul.in



OnePLUS
Ultrasound Lab
— QUALITY FIRST... ALWAYS! —

Dr. Nitin Agarwal

Pathologist & Director
MBBS, MD, FAGE
Ex. Chief of Lab
Dr. Lal Path labs.

Dr. Pooja (Garg) Agarwal

Radiologist & Director
MBBS (MAMC) DMRD (MAMC)
Imaging Expert In Fetal And Maternal Medicine,
University of Barcelona, Spain
Fetal Medicine Foundation (UK) Accreditation



NAME	:Mrs. NAMITA	Barcode No	:10170062
AGE/GENDER	:38 YRS/Female	SPECIMEN DATE	:20/Apr/2024 09:51AM
PATIENT ID	:134402	SPECIMEN RECEIVED	:20/Apr/2024 10:07AM
REFERRED BY	:Dr. MEDIWHEEL	REPORT DATE	:20/Apr/2024 04:37PM
CENTRE NAME	:ONEPLUS ULTRASOUND LAB	LAB NO.	:012404200016

Test Name	Result	Unit	Ref. Range
-----------	--------	------	------------

ENDOCRINOLOGY

THYROID PROFILE(T3,T4,TSH)

Triiodothyronine total [t3] ECLIA	0.69	ng/dl	0.52-1.9
Thyroxine total [t4] ECLIA	8.60	µg/dl	4.8-11.6
TSH (Thyroid Stimulating Hormone) Enzyme linked fluorescent assay	3.60	µIU/ml	0.25-5.0

AGE WISE VARIATION IN TSH

AGE	TSH(µIU/ml)	AGE	TSH(µIU/ml)
1-4 weeks	1.00 - 19.0	16-20 yrs	0.25 - 5.0
1-12 mths	1.70 - 9.1	21 - 80 yrs	0.25- 5.0
1-5 yrs	0.80 - 8.2	I st trimester	0.25 - 5.0
6-10 yrs	0.25 - 5.0	II nd trimester	0.50 - 5.0
11-15 yrs	0.25 - 5.0	II rd trimester	0.4 - 6.0

Reference ranges - Interpretation of Diagnostic tests - (Jacques Wallach)

1. Primary hypothyroidism is accompanied by depressed serum T3 and T4 values and elevated serum TSH level.
2. Primary hyperthyroidism is accompanied by elevated serum T3 and T4 levels along with depressed TSH values.
3. Slightly elevated T3 levels may be found in pregnancy and estrogen therapy, while depressed levels may be encountered in severe illness, renal failure and during therapy with drugs like propranolol and propyl thiouracil.
4. Although elevated TSH levels are nearly always indicative of primary hypothyroidism, and may be seen in secondary thyrotoxicosis

Checked By.

Dr. NITIN AGARWAL
MBBS, MD (Path)
DMLR/01436
DR. NITIN AGARWAL
MBBS,MD(PATHOLOGIST)

47, Harsh Vihar, Pitampura, Delhi-34 ☎ 011-4248 0101, 9599913051

✉ Email: oneplusul@gmail.com 🌐 www.oneplusul.in

Page 6 of 8

- Clinical correlation is essential for final diagnosis. • If test results are unsatisfactory please contact personally or on phone.
- This report is for perusal of doctors only. • All disputes are subject to Delhi jurisdiction only. • Not for medico legal case.
- All congenital anomalies in a foetus may not be diagnosed in routine obstetric ultrasound.



NAME	:Mrs. NAMITA	Barcode No	:10170062
AGE/GENDER	:38 YRS/Female	SPECIMEN DATE	:20/Apr/2024 09:51AM
PATIENT ID	:134402	SPECIMEN RECEIVED	:20/Apr/2024 10:07AM
REFERRED BY	:Dr. MEDIWHEEL	REPORT DATE	:20/Apr/2024 04:37PM
CENTRE NAME	:ONEPLUS ULTRASOUND LAB	LAB NO.	:012404200016

Test Name	Result	Unit	Ref. Range
-----------	--------	------	------------

CLINICAL PATHOLOGY

URINE ROUTINE (Strip/microscopy)

Sample Type:Urine

Physical examination

Colour	PALE YELLOW		PALE YELLOW
Transparency	SLIGHTLY TURBID		CLEAR
Sp.gravity	1.015		1.005-1.030
BROMOTHYMOL BLUE			
pH	6.50		5.0-8.0
Double Indicators Test			
Reaction	ACIDIC		ACIDIC

Chemical examination

Urine protein	NIL		NIL
Protein Ionization			
Urine sugar	NIL		NIL
Oxidation Reaction			
Bilirubin, urine	NEGATIVE		NEGATIVE
Urobilinogen	NORMAL		NORMAL
P-Aminobenzoic Acid and Phenazopyridine Reaction			
Ketones	NEGATIVE		NEGATIVE
Acetoacetate and Dichlorobenzene Reaction			

Microscopic examination

Pus cells.	4-6	/HPF	1-2
Microscopy			
Epithelial cells	15-20	/HPF	0-5
Microscopy			
R.B.C.	NIL	/HPF	NIL
Microscopy			
Casts	NIL	/HPF	NIL
Microscopy			
Crystals	NIL	/HPF	NIL
Microscopy			
Bacteria	NIL	/HPF	NIL
Microscopy			

Checked By.

Dr. Nitin Agarwal
DR. NITIN AGARWAL
MBBS, MD (Path)
DMC/R/01436
MBBS,MD(PATHOLOGIST)

47, Harsh Vihar, Pitampura, Delhi-34 ☎ 011-4248 0101, 9599913051

✉ Email: oneplusul@gmail.com 🌐 www.oneplusul.in



NABL
MC - 6036

Dr. Nitin Agarwal

Pathologist & Director
MBBS, MD, FAGE
Ex. Chief of Lab
Dr. Lal Path labs.

Dr. Pooja (Garg) Agarwal

Radiologist & Director
MBBS (MAMC) DMRD (MAMC)
Imaging Expert In Fetal And Maternal Medicine,
University of Barcelona, Spain
Fetal Medicine Foundation (UK) Accreditation




NAME	:Mrs. NAMITA	Barcode No	:10170062
AGE/GENDER	:38 YRS/Female	SPECIMEN DATE	:20/Apr/2024 09:51AM
PATIENT ID	:134402	SPECIMEN RECEIVED	:20/Apr/2024 10:07AM
REFERRED BY	:Dr. MEDIWHEEL	REPORT DATE	:20/Apr/2024 04:37PM
CENTRE NAME	:ONEPLUS ULTRASOUND LAB	LAB NO.	:012404200016

Test Name	Result	Unit	Ref. Range
Others.	NIL		NIL

*** End Of Report ***

Checked By.

Dr NITIN AGARWAL
MBBS, MD (Path)
DMC/R/01436

DR. NITIN AGARWAL
MBBS,MD(PATHOLOGIST)

47, Harsh Vihar, Pitampura, Delhi-34 ☎ 011-4248 0101, 9599913051

✉ Email: oneplusul@gmail.com 🌐 www.oneplusul.in

Page 8 of 8

- Clinical correlation is essential for final diagnosis. • If test results are unsatisfactory please contact personally or on phone.
- This report is for perusal of doctors only. • All disputes are subject to Delhi jurisdiction only. • Not for medico legal case.
- All congenital anomalies in a foetus may not be diagnosed in routine obstetric ultrasound.



OnePLUS
Ultrasound Lab
— QUALITY FIRST... ALWAYS! —

Dr. Nitin Agarwal

Pathologist & Director
MBBS, MD, FAGE
Ex. Chief of Lab
Dr. Lal Path labs.

Dr. Pooja (Garg) Agarwal


Radiologist & Director
MBBS (MAMC) DMRD (MAMC)
Imaging Expert In Fetal And Maternal Medicine,
University of Barcelona, Spain
Fetal Medicine Foundation (UK) Accreditation

To Whomsoever it may concern

Hereby I Namita from BOB has
come for full body medical health
check up. I have not undergone
under follow's test.

- 1) Stool test
- 2) Blood Sugar PP

Namita


Dr. NITIN AGARWAL
MBBS, MD
Regn. No. DMC-R-1436

ONEPLUS ULTRASOUND LAB
47 Harsh Vihar, Pitam Pura,
Delhi-110034
Ph. 011-42480101, 9599913051
E-mail onepusul@gmail.com

47, Harsh Vihar, Pitampura, Delhi-34 ☎ 011-4248 0101, 9599913051

✉ Email: onepusul@gmail.com 🌐 www.oneplusul.in

- Clinical correlation is essential for final diagnosis.
- If test results are unsatisfactory please contact personally or on phone.
- This report is for perusal of doctors only.
- All disputes are subject to Delhi jurisdiction only.
- Not for medico legal case.
- All congenital anomalies in a foetus may not be diagnosed in routine obstetric ultrasound.



OnePLUS
Ultrasound Lab
— QUALITY FIRST... ALWAYS! —

Dr. Nitin Agarwal

Pathologist & Director
MBBS, MD, FAGE
Ex. Chief of Lab
Dr. Lal Path labs.

Dr. Pooja (Garg) Agarwal

Radiologist & Director
MBBS (MAMC) DMRD (MAMC)
Imaging Expert In Fetal And Maternal Medicine,
University of Barcelona, Spain
Fetal Medicine Foundation (UK) Accreditation

Name	: Mrs. NAMITA	Age/Sex	: 38 YRS/Female
Ref. By	: Dr. MEDIWHEEL	Lab No	: 012404200016
Date	: 20-Apr-2024	Patient ID	: LSHH1134402

ULTRASOUND EXAMINATION----WHOLE ABDOMEN

Liver is normal in size (14.7 cm) and outline **with altered echopattern. Diffuse increase in echogenicity of liver parenchyma is noted, suggestive of fatty infiltration (grade I).** No abscess or mass lesion seen. Hepatic veins, portal vein, IVC and aorta are normal. Intrahepatic biliary radicles are not dilated. CBD is normal in caliber.

Gall bladder is well distended with anechoic lumen. Wall thickness is normal.

Both kidneys are normal in size, shape, position, outline and echopattern. Corticomedullary differentiation is maintained. No pelvicalyceal dilation or calculus or mass lesion is seen.

Spleen is normal in size (8.7 cm) and echotexture. No mass lesion seen.

Pancreas is normal in size, outline and echotexture .

Urinary bladder is normal in shape and position. No evidence of intravesical stone or mass seen.


Uterus is normal in size (measures 8.2 x 4.3 x 4.1 cm), shape, position and echopattern. No mass seen.

Uterine cavity is empty. **Endometrial thickness** is 6.9 mm.

Both ovaries appear normal in size, shape and echopattern. No tubo-ovarian mass seen.

No abnormal bowel wall thickening seen in right iliac fossa.
No free fluid seen anywhere in abdomen.

IMPRESSION: Fatty infiltration of liver (grade I) with no hepatomegaly.

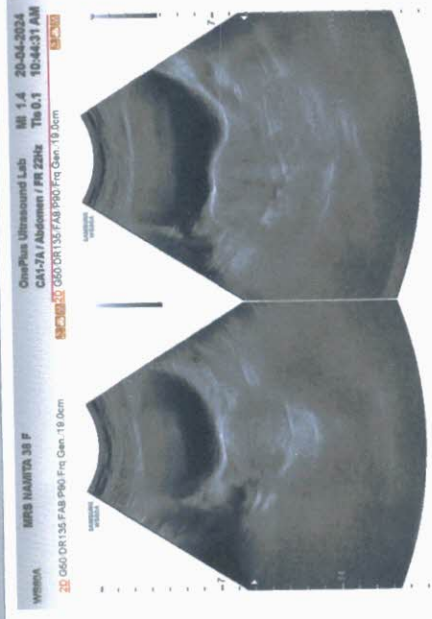

DR. RASHMI BANSAL
RADIOLOGIST
REG NO- DMC/R/10067

Dr RASHMI BANSAL
Radiologist
Reg. No. DMC/R/10067

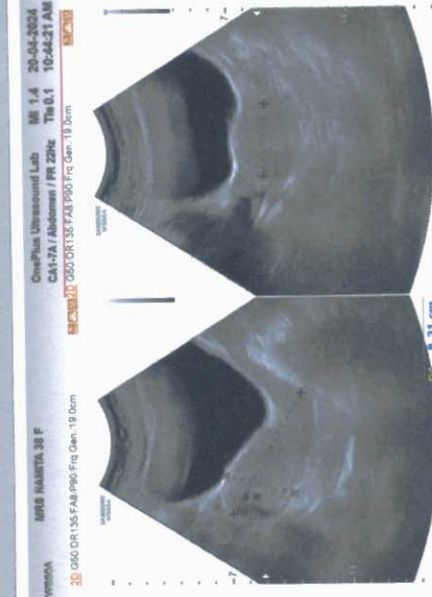47, Harsh Vihar, Pitampura, Delhi-34 ☎ 011-4248 0101, 9599913051

✉ Email: oneplusul@gmail.com 🌐 www.oneplusul.in

- Clinical correlation is essential for final diagnosis. • If test results are unsatisfactory please contact personally or on phone.
- This report is for perusal of doctors only. • All disputes are subject to Delhi jurisdiction only. • Not for medico legal case.
- All congenital anomalies in a foetus may not be diagnosed in routine obstetric ultrasound.



MRS NAMITA 38 F
 OnePlus Ultrasound Lab MI 1.4 20-04-2024
 CA1-7A / Abdomen / FR 22Hz Tls 0.1 10-44:21 AM
 20 G60-DR135 FAS P90 Frg Gen: 19.0cm

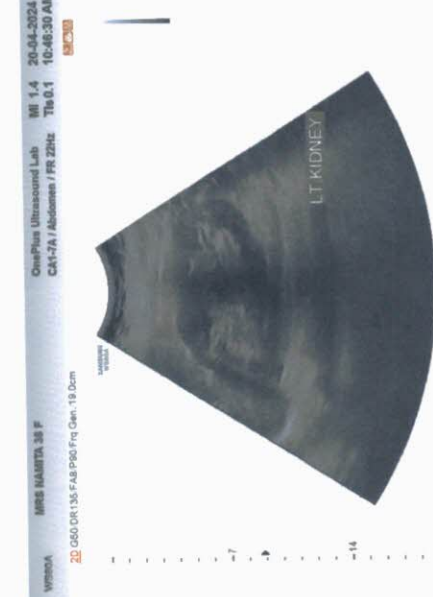

MRS NAMITA 38 F
 OnePlus Ultrasound Lab MI 1.4 20-04-2024
 CA1-7A / Abdomen / FR 22Hz Tls 0.1 10-44:21 AM
 20 G60-DR135 FAS P90 Frg Gen: 18.0cm

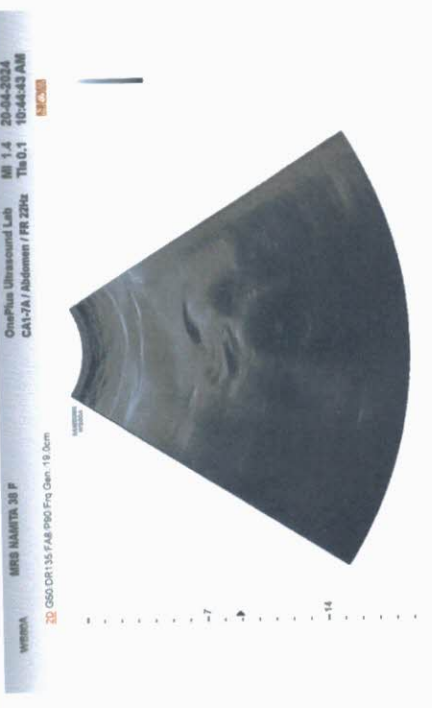D1 4.29 cm
 D2 4.15 cm
 D3 0.69 cm



MRS NAMITA 38 F
 OnePlus Ultrasound Lab MI 1.4 20-04-2024
 CA1-7A / Abdomen / FR 22Hz Tls 0.1 10-46:56 AM
 20 G60-DR135 FAS P90 Frg Gen: 19.0cm



MRS NAMITA 38 F
 OnePlus Ultrasound Lab MI 1.4 20-04-2024
 CA1-7A / Abdomen / FR 22Hz Tls 0.1 10-46:30 AM
 20 G60-DR135 FAS P90 Frg Gen: 19.0cm



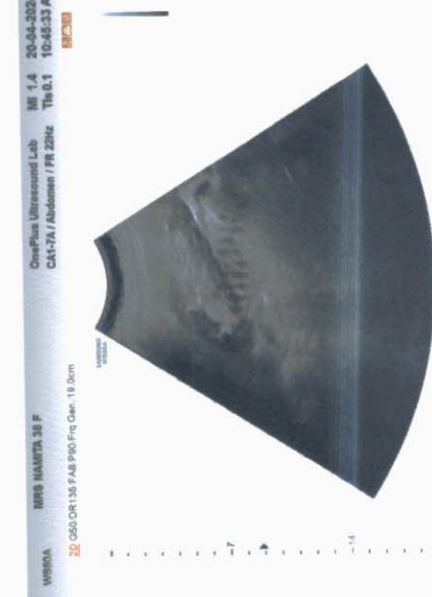MRS NAMITA 38 F
 OnePlus Ultrasound Lab MI 1.4 20-04-2024
 CA1-7A / Abdomen / FR 22Hz Tls 0.1 10-44:43 AM
 20 G60-DR135 FAS P90 Frg Gen: 19.0cm



MRS NAMITA 38 F
 OnePlus Ultrasound Lab MI 1.4 20-04-2024
 CA1-7A / Abdomen / FR 22Hz Tls 0.1 10-47:03 AM
 20 G60-DR135 FAS P90 Frg Gen: 19.0cm



MRS NAMITA 38 F
 OnePlus Ultrasound Lab MI 1.4 20-04-2024
 CA1-7A / Abdomen / FR 22Hz Tls 0.1 10-46:23 AM
 20 G60-DR135 FAS P90 Frg Gen: 19.0cm



MRS NAMITA 38 F
 OnePlus Ultrasound Lab MI 1.4 20-04-2024
 CA1-7A / Abdomen / FR 22Hz Tls 0.1 10-46:33 AM
 20 G60-DR135 FAS P90 Frg Gen: 18.0cm



MRS NAMITA 38 F
 OnePlus Ultrasound Lab MI 1.4 20-04-2024
 CA1-7A / Abdomen / FR 22Hz Tls 0.1 10-45:25 AM
 20 G60-DR135 FAS P90 Frg Gen: 19.0cm

D1 8.77 cm

D1 14.74 cm



100101 100101 100101

100101 100101 100101

100101 100101 100101

100101 100101 100101

100101 100101 100101



100101 100101 100101

100101 100101 100101

100101 100101 100101

100101 100101 100101



100101 100101 100101

100101 100101 100101

100101 100101 100101

100101 100101 100101





OnePLUS
Ultrasound Lab
— QUALITY FIRST... ALWAYS! —

Dr. Nitin Agarwal

Pathologist & Director
MBBS, MD, FAGE
Ex. Chief of Lab
Dr. Lal Path labs.

Dr. Pooja (Garg) Agarwal

Radiologist & Director
MBBS (MAMC) DMRD (MAMC)
Imaging Expert In Fetal And Maternal Medicine,
University of Barcelona, Spain
Fetal Medicine Foundation (UK) Accreditation

Name	: Mrs. NAMITA	Age/Sex	: 38 YRS/Female
Ref. By	: Dr. MEDIWHEEL	Lab No	: 012404200016
Date	: 20-Apr-2024	Patient ID	: LSHHI134402

X-ray-Chest PA view

Bony cage and soft tissues are normal.

Cardiothoracic ratio is normal.

Mediastinum is normal.


Both hila are normal.

Both costophrenic angles are clear.

Both domes of diaphragm are normal.

Lung fields are clear. No parenchymal lesion seen.

IMPRESSION: Normal Study.


DR. POOJA GARG
RADIOLOGIST
REG NO- DMC/R/03398

Type By : sangeeta

47, Harsh Vihar, Pitampura, Delhi-34 ☎ 011-4248 0101, 9599913051

✉ Email: oneplusul@gmail.com 🌐 www.oneplusul.in

- Clinical correlation is essential for final diagnosis. • If test results are unsatisfactory please contact personally or on phone.
- This report is for perusal of doctors only. • All disputes are subject to Delhi jurisdiction only. • Not for medico legal case.
- All congenital anomalies in a foetus may not be diagnosed in routine obstetric ultrasound.

ONEPLUS ULTRASOUND LAB

47, HARSH VIHAR, PITAMPURA, DELHI- 110034

Ms. NAMITA
Age : 38/F
Ref. by : MEDWHEEL
Indication1 :
Indication2 :
Indication3 :
COMMENTS : Normal ECG

ID : 2561
HWT : 155/79
Recorded : 20-4-2024 11:23
Medication1 :
Medication2 :
Medication3 :

BPM : 79
BP : 114/78
P Axis : 59 deg
QRS Axis : 36 deg
T Axis : 29 deg

P duration : 100 msec
PR duration : 150 msec
QRS duration : 93 msec
QT Interval : 350 msec
QTc Interval : 383 msec

Raw E.C.G.(Seq)

Unconfirmed Report Reviewed By:

Cardiologist

Dr. P.K. GUPTA
R:885, MD

Reg. No-1071

V4

aVR

V1

aVL

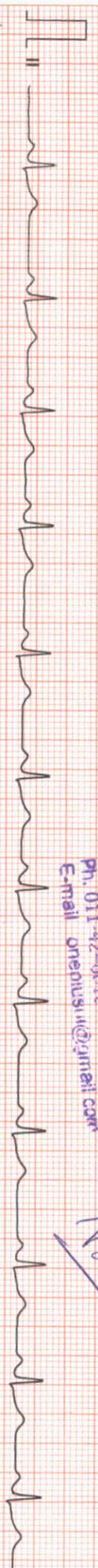V2

V5

aVF

V3

V6



ONEPLUS ULTRASOUND LAB
47 Harsh Vihar, Pitampura
Delhi-110034
Ph. 011-42480101-2599913051
E-mail onepplusul@gmail.com

Handwritten signature

Filtered

25mm/sec 10mm/mV

CardiCom, INDIA

ONEPLUS ULTRASOUND LAB

47, HARSH VIHAR PITAMPURA DELHI 110034

MS. NAMITA

ID : 998

HW#: 155/79

Recorded : 20-4-2024 11:25

Ref. by: MEDIWHEEL

Indication1 :

Indication2 :

Indication3 :

TREADMILL TEST SUMMARY REPORT

Protocol: BRUCE

History:

Medication1 :

Medication2 :

Medication3 :

PHASE	PHASE TIME	STAGE TIME	SPEED (Km./Hr.)	GRADE (%)	H.R. (BPM)	B.P. (mmHg)	RPP X100	H	ST LEVEL (mm) V2	V5	METS
SUPINE					78	114/78	88	0.1	0.2	0.1	
STANDING					79	114/78	90	0.1	0.3	0.2	
STAGE 1	2:59	2:59	2.70	10.00	126	126/82	156	-0.1	0.3	0.1	4.80
STAGE 2	5:59	2:59	4.00	12.00	146	138/86	201	-0.3	0.0	0.2	7.10
STAGE 3	7:44	1:44	5.40	14.00	156	150/88	234	-0.6	1.2	-0.2	8.78
PEAK EXER	7:58	1:58			158	150/88	237	0.3	0.5	0.3	
RECOVERY	2:59	2:59	0.00	0.00	75	120/80	90	-0.1	0.1	-0.2	9.01

RESULTS

Exercise Duration

Max Heart Rate

Max Blood Pressure

Max Work Load

Reason of Termination

7:58 Minutes

158 bpm 86 % of target heart rate 182 bpm

150/88 mmHg

9.01 METS

Negative for ischemia

IMPRESSIONS

Dr. P.K. GUPTA
MBBS, MD
Cardiologist
No-1071

Next

ONEPLUS ULTRASOUND LAB

47 Harsh Vihar Pitampura, Delhi-110034

Ph. 011-42480101, 9599913051

E-mail: oneplusul@gmail.com

Ms. NAMITA
I.D. : 998
AGE/SEX : 38/F
RECORDED : 20-4-2024 11:25

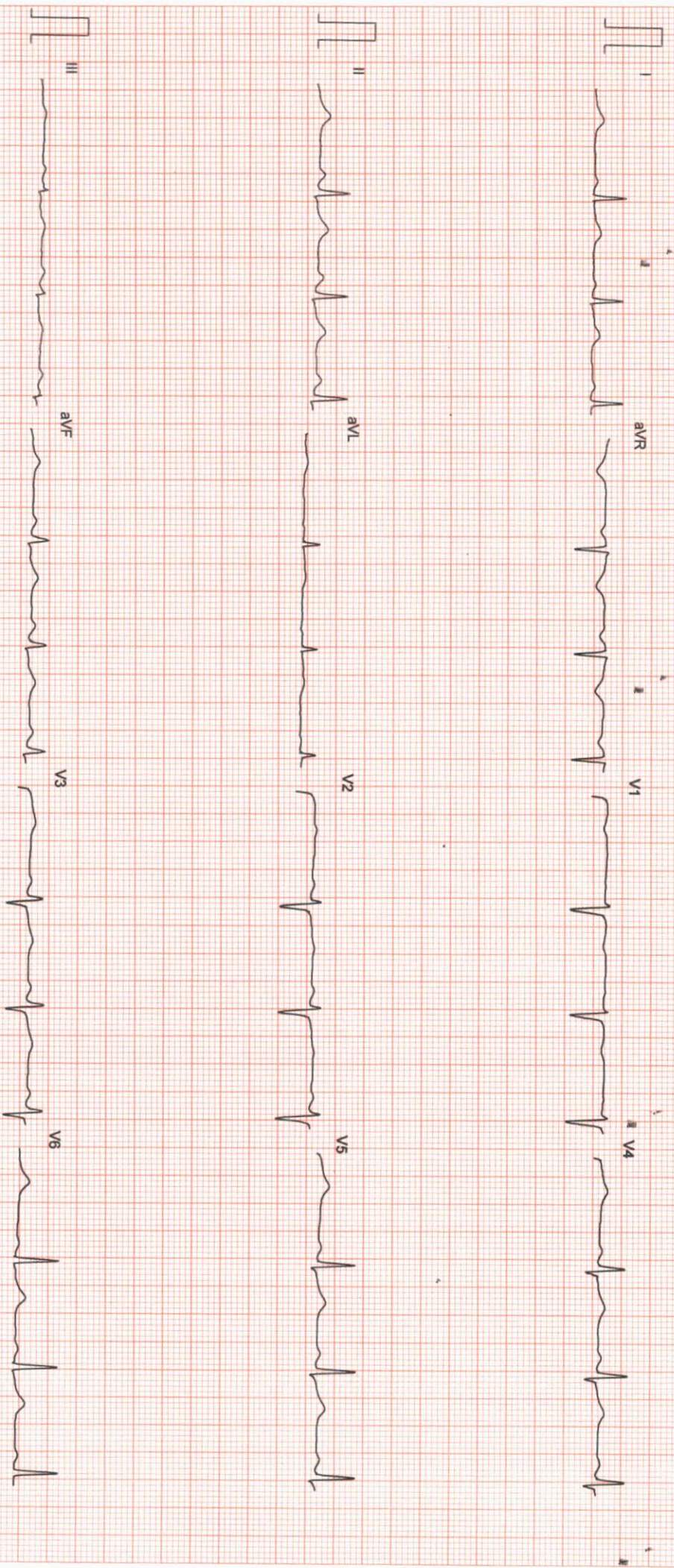
RATE : 78 BPM
B.P. : 114/78 mmHg

ONEPLUS ULTRASOUND LAB

SUPINE
PRETEST

ST @ 10mm/mV
80ms PostJ

RAW E.C.G.



Filtered

25mm/sec 10mm/mV

CardiCom, INDIA Ph.:091-731-2620740, TeleFax:091-731-2431214

ONEPLUS ULTRASOUND LAB
47 Harsh Vihar, Pitampura,
Delhi-110034
Ph. 011-42480101, 9549913051
E-mail oneplusuk@gmail.com

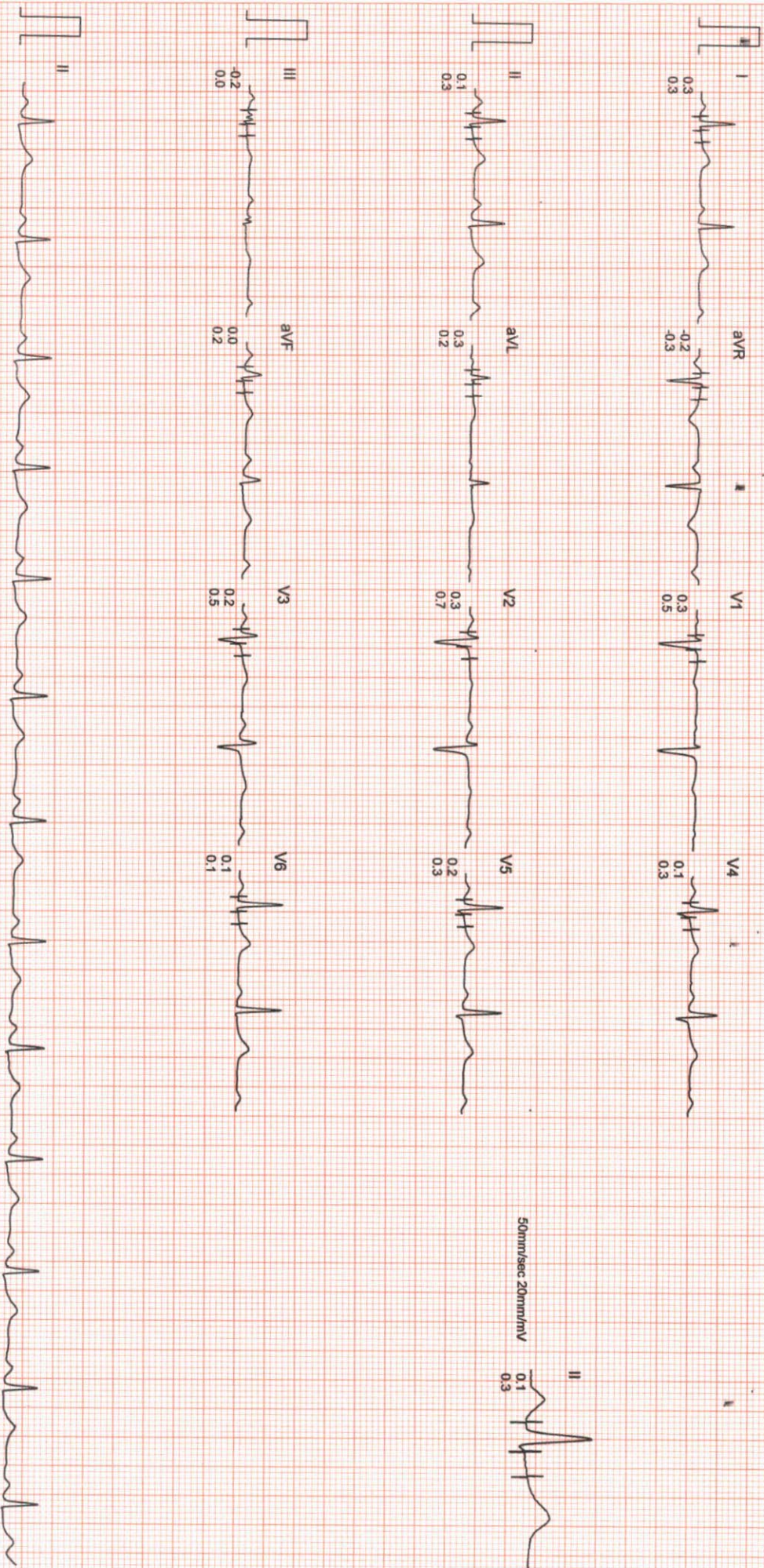
ONEPLUS ULTRASOUND LAB

STANDING
PRETEST

ST @ 10mm/mV
80ms PostI

Ms. NAMITA
I.D. : 998
AGE/SEX : 38/F
RECORDED : 20-4-2024 11:25
RATE : 79 BPM
B.P. : 114/78 mmHg

LINKED MEDIAN



Filtered Computer Corrected Baseline

25mm/sec 10mm/mV

CardiCom, INDIA Ph. 091-731-2620740, TeleFax 091-731-2431214

ONEPLUS ULTRASOUND LAB
47 Harsh Vihar Pitam Pura,
Delhi-110034

Ph. 011-42480101, 9599913051
E-mail onepiusul@gm ail com

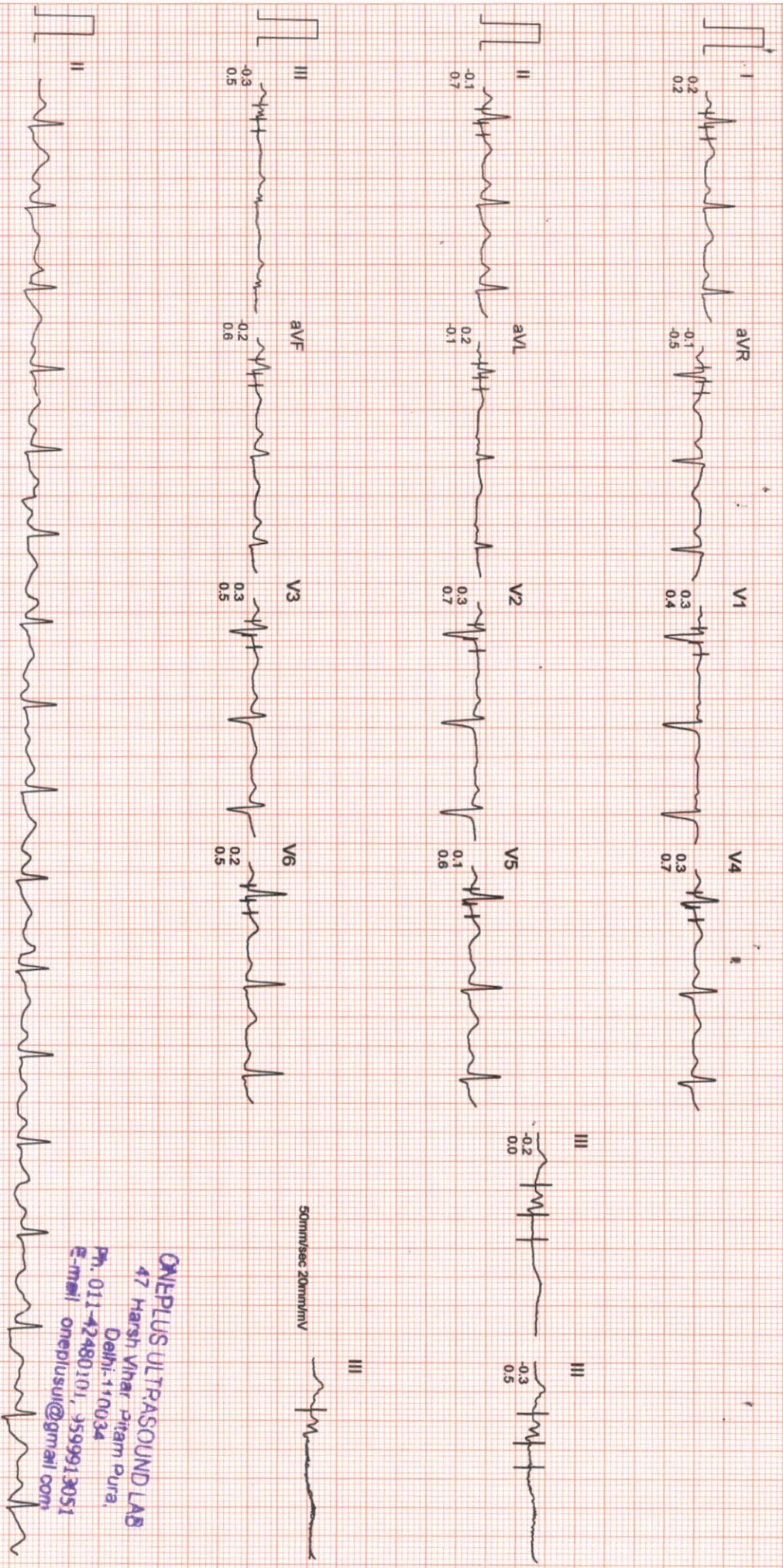
ONEPLUS ULTRASOUND LAB

Ms. NAMITA
I.D. : 998
AGE/SEX : 38/F
RECORDED : 20-4-2024 11:25

BRUCE
EXERCISE 1
PHASE TIME : 2:59
STAGE TIME : 2:59

ST @ 10mm/mV
80ms PostJ
SPEED : 2.7 Km./Hr.
GRADE : 10.0 %

LINKED MEDIAN



Filtered Computer Corrected Baseline 25mm/sec 10mm/mV Cardicom, INDIA Ph. :091-731-2620740, TeleFax:091-731-2431214

ONEPLUS ULTRASOUND LAB
47 Harsh Vihar Pitam Pura,
Delhi-110034
Ph. 011-42480101, 9599913051
E-mail oneplusul@gmail.com

ONEPLUS ULTRASOUND LAB

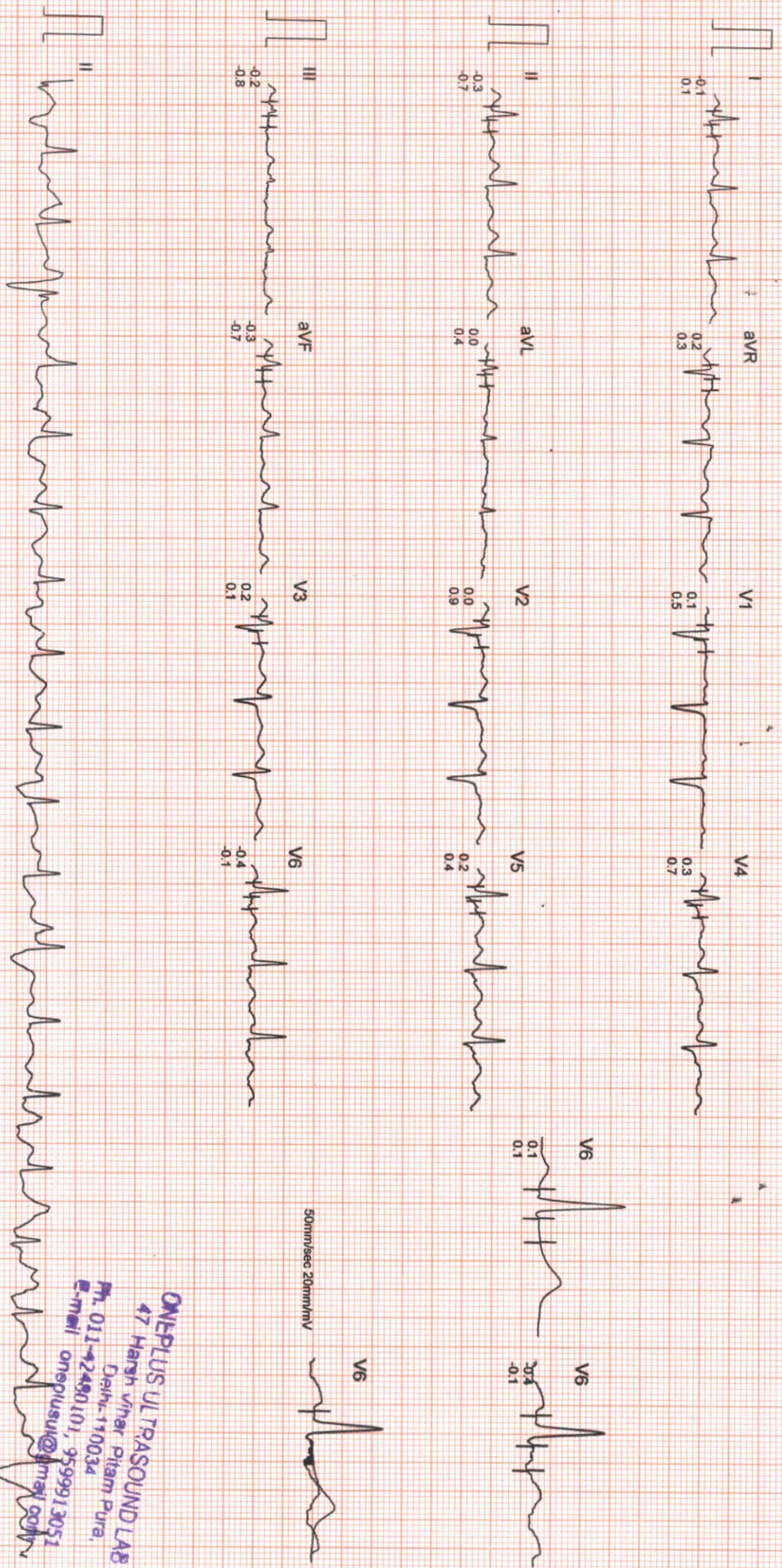
Ms. NAMITA
I.D. : 998
AGE/SEX : 38/F
RECORDED : 20-4-2024 11:25

RATE : 146 BPM
B.P. : 138/86 mmHg

BRUCE
EXERCISE 2
PHASE TIME : 5:59
STAGE TIME : 2:59

ST @ 10mm/mV
80ms PostJ
SPEED : 4.0 Km./Hr.
GRADE : 12.0 %

LINKED MEDIAN



Filtered Computer-Corrected Baseline

25mm/sec 10mm/mV

CardiCom, INDIA Ph.:091-731-2620740, TeleFax:091-731-2431214

ONEPLUS ULTRASOUND LAB
47 Harsh vihar Pitam Pura,
Delhi-110034
Ph. 011-2480101, 9599913051
E-mail onepiusul@jmail.co.in

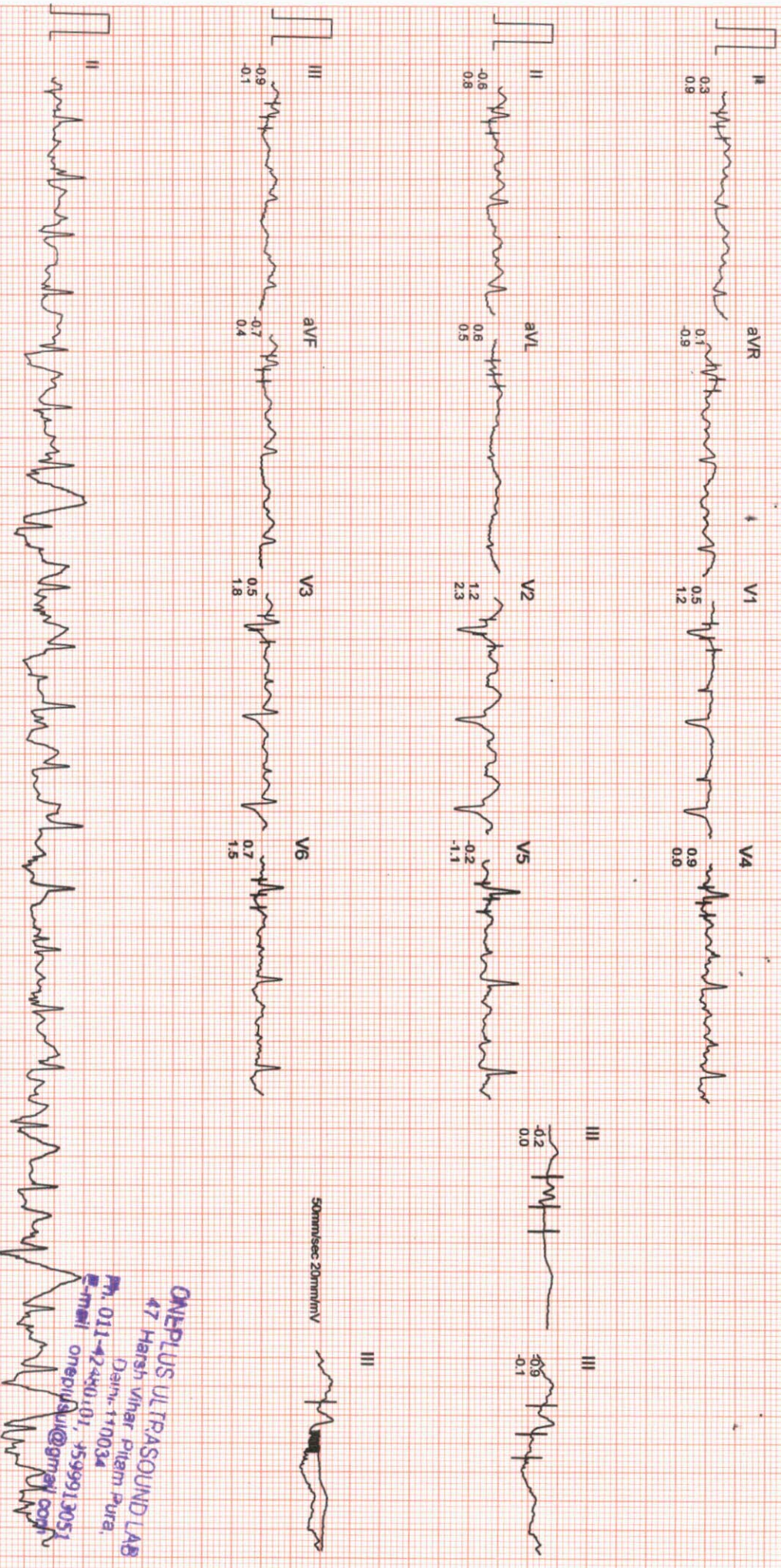
ONEPLUS ULTRASOUND LAB

Ms. NAMITA
 ID : 998
 AGE/SEX : 38/F
 RECORDED : 20-4-2024 11:25

BRUCE
 EXERCISE 3
 PHASE TIME : 7:44
 STAGE TIME : 1:44

ST @ 10mm/mV
 80ms PostJ
 SPEED : 5.4 Km./Hr.
 GRADE : 14.0 %

LINKED MEDIAN



ONEPLUS ULTRASOUND LAB
 47 Harsh Vihar Pitam Pura,
 Delhi-110034
 Ph. 011-42440101, +599913051
 Email onepiusul@gmail.com

ONEPLUS ULTRASOUND LAB

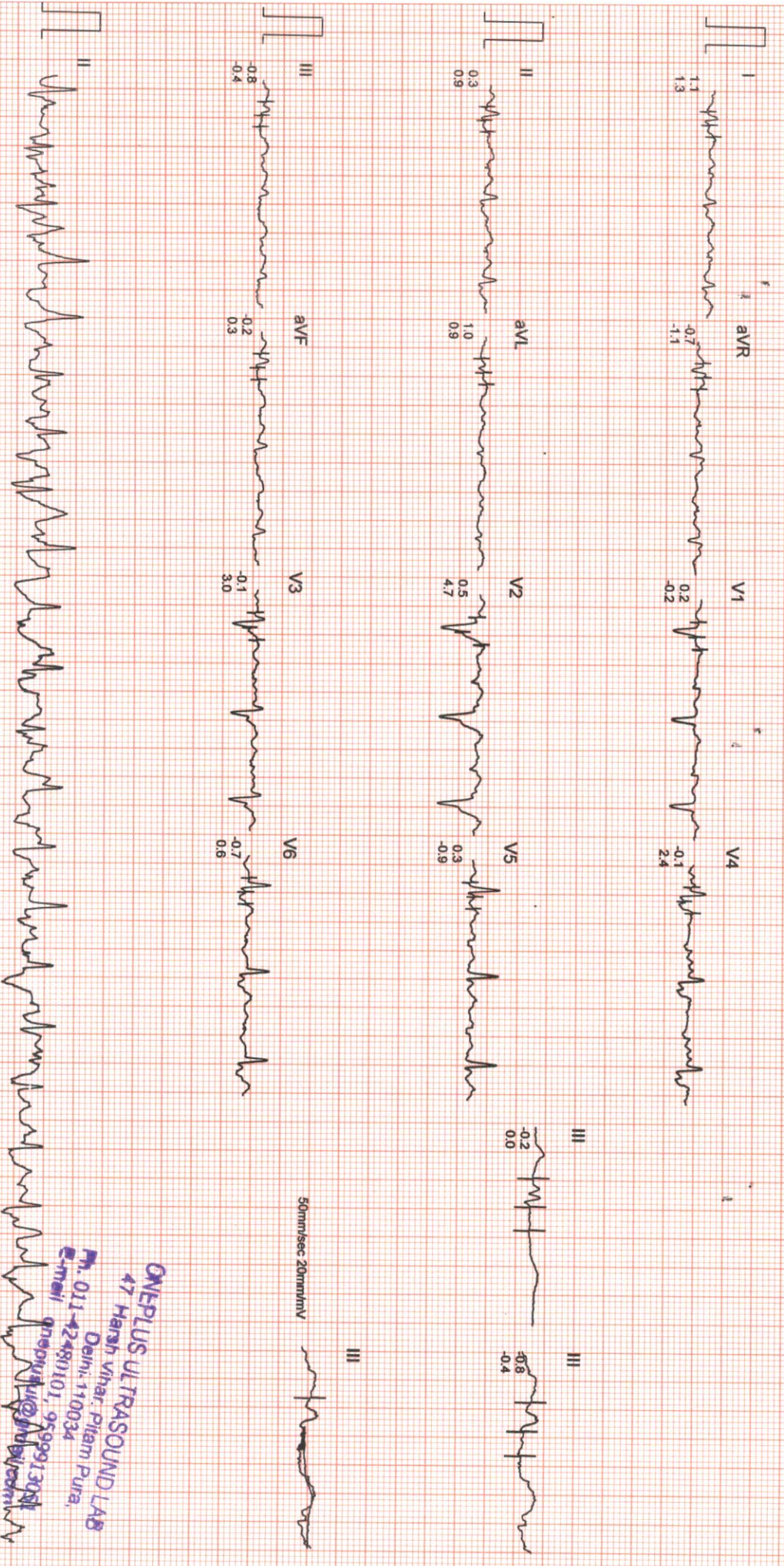
Ms. NAMITA
I.D. : 998
AGE/SEX : 38/F
RECORDED : 20-4-2024 11:25

RATE : 158 BPM
B.P. : 150/88 mmHg

BRUCE
PEAK EXERCISE
PHASE TIME : 7:58
STAGE TIME : 1:58

ST @ 10mm/mV
80ms PostJ
SPEED : 5.4 Km./Hr.
GRADE : 14.0 %

LINKED MEDIAN



ONEPLUS ULTRASOUND LAB
47 Harsh vihar, Pilem Pura,
Delhi, 110034
Ph. 011-42480101, 9599913051
E-mail: onepus@oneplusultrasound.com

Filtered Computer Corrected Baseline

25mm/sec 10mm/mV

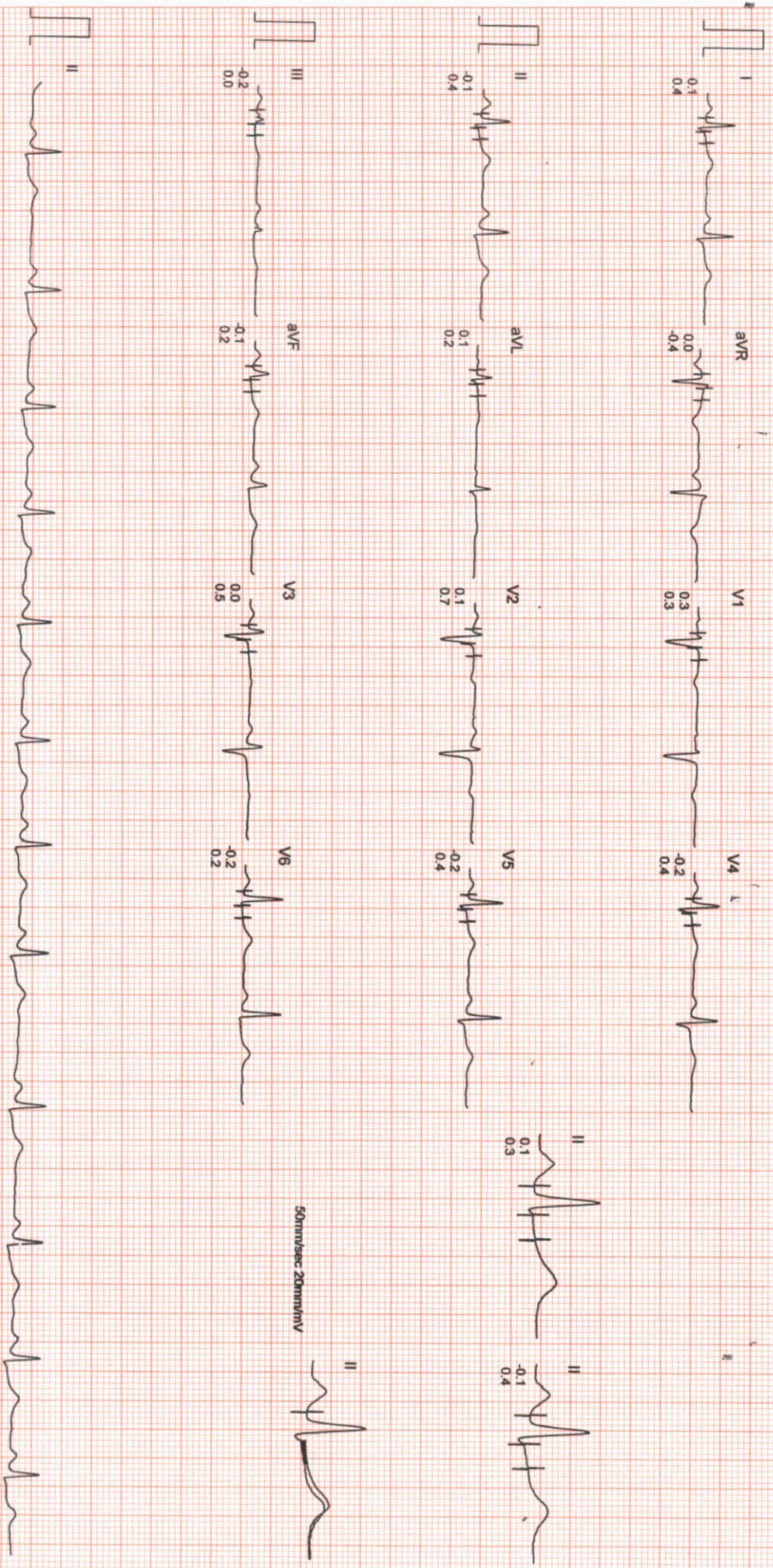
CardiCom, INDIA Ph. 091-731-2620740, TeleFax: 091-731-2431214

Ms. NAMITA
I.D. : 998
AGE/SEX : 38/F
RECORDED : 20-4-2024 11:25

ONEPLUS ULTRASOUND LAB

BRUCE
RECOVERY
PHASE TIME : 2:59

ST @ 10mm/mV
80ms PostJ
SPEED : 0.0 Km./Hr.
GRADE : 0.0%




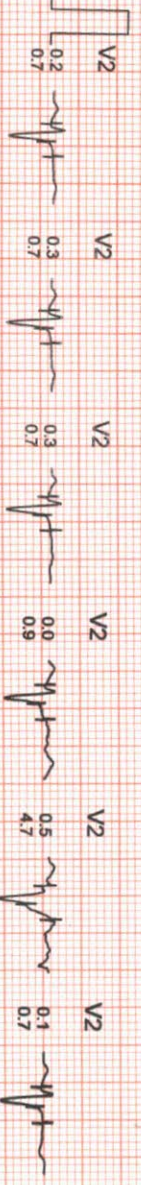
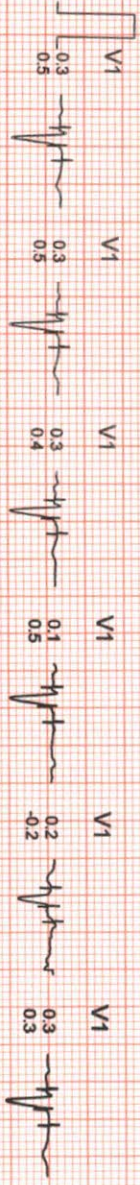
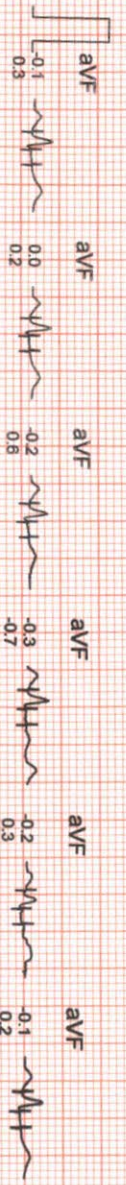
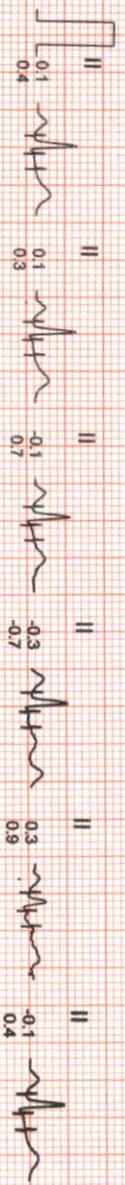
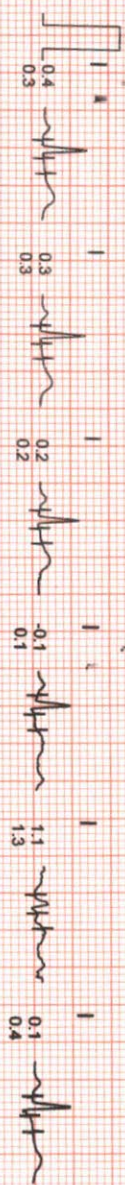
Filtered Computer Corrected Baseline 25mm/sec 10mm/mV

CardiCom, INDIA Ph.:091-731-2620740, TeleFax:091-731-2431124

ONEPLUS ULTRASOUND LAB
47 Harish Vihar, Pitam Pura,
Delhi-110034
Ph. 011-42480101, 9599913051
E-mail: dheppulsul@oneplusultrasound.com

ONEPLUS ULTRASOUND LAB

STAGE	0.0Kmph	0.0%	78 bpm	B.P. 114/78	80ms PostJ
SUPINE	0.0Kmph	0.0%	78 bpm <td>B.P. 114/78 <td>80ms PostJ</td> </td>	B.P. 114/78 <td>80ms PostJ</td>	80ms PostJ
STANDING	0.0Kmph	0.0%	79 bpm <td>B.P. 114/78 <td>80ms PostJ</td> </td>	B.P. 114/78 <td>80ms PostJ</td>	80ms PostJ
STAGE 1	2:59	2.7Kmph	126 bpm <td>B.P. 120/82 <td>80ms PostJ</td> </td>	B.P. 120/82 <td>80ms PostJ</td>	80ms PostJ
STAGE 2	3:59	4.0Kmph	146 bpm <td>B.P. 138/88 <td>80ms PostJ</td> </td>	B.P. 138/88 <td>80ms PostJ</td>	80ms PostJ
PEAK EXERCISE	7:58	5.4Kmph	158 bpm <td>B.P. 150/88 <td>80ms PostJ</td> </td>	B.P. 150/88 <td>80ms PostJ</td>	80ms PostJ
RECOVERY	2:59	0.0Kmph	75 bpm <td>B.P. 120/80 <td>80ms PostJ</td> </td>	B.P. 120/80 <td>80ms PostJ</td>	80ms PostJ



ONEPLUS ULTRASOUND LAB
 47, Haren Vihar, Pitam Pura,
 Delhi-110034
 Ph. 011-2480101, 9599913051
 E-mail: oneplusul@sthal.com

CardiCom, INDIA Ph.:091-731-2620740, Telefax:091-731-2431214

ONEPLUS ULTRASOUND LAB

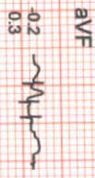
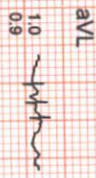


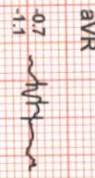
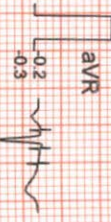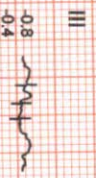
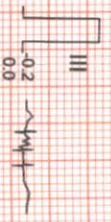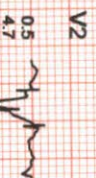
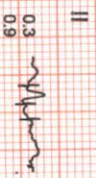
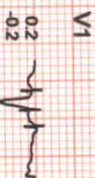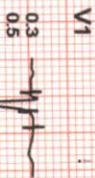
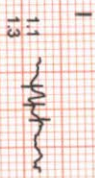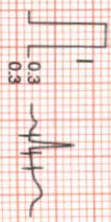
COMPARISON REPORT

STANDING
 0.0kmph
 0.0%
 79 bpm
 B.P. 114/78
 80ms PostJ

PEAK EXERCISE
 7:58
 1:58
 5.4kmph
 14.0%
 158 bpm
 B.P. 150/88
 80ms PostJ

STANDING
 0.0kmph
 0.0%
 79 bpm
 B.P. 114/78
 80ms PostJ

PEAK EXERCISE
 7:58
 1:58
 5.4kmph
 14.0%
 158 bpm
 B.P. 150/88
 80ms PostJ



ONEPLUS ULTRASOUND LAB
 47 Mersah Vilas, Pitam Pura,
 Jhansi-140034
 Ph. 011-92480101, 9599913051
 Email onepiusul@gmail.com




भारतीय विशिष्ट पहचान प्राधिकरण

Unique Identification Authority of India



AADHAAR

Address: Bhuvan Aggarwal, 5C-62, New
Rohtak Road, Karol Bagh, Central Delhi,
Delhi, 110005



Print Date: 18/12/2021

6848 2657 1769



1947



help@uidai.gov.in



www.uidai.gov.in

Please Turn off
Mobile Phones

Ultrasound Lab

Delhi-34 Phone: 011-42480101

गर्भ या लड़कणी की पहचान नहीं की जाती।
सुरक्षित है।

करना पीसी और पीएनडीटी
दंडनीय अपराध है

Identification and disclosure of sex
of foetus is not done.
Offendable under law.

THE SEX OF CHILD IS
NOT DONE UNDER PC & PNDT ACT

Under PC & PNDT Act Contact:

Delhi District
District Magistrate, GNCT of Delhi, Kanjhawala, Delhi-84
(011) 26113000

Delhi District
North West, Sector-13, Rohini, Delhi-85
(011) 26113000

USG ROOM
NO. 1

ULTRASOUND

No Admission
Without Permission

Dr. Pooja Garg
Radiologist

MBBS (MAMC) DMRD (MAMC)
Imaging Expert in Fetal And Maternal Medicine,
University of Barcelona, Spain
Fetal Medicine Foundation (FMF) Accreditation
REG No. DMC/R/03398

NOTICE
ALL PATIENTS MUST BE ACCOMPANIED BY AN
ADULT AT ALL TIMES. NO PATIENTS UNDER
18 YEARS OF AGE WILL BE ADMITTED WITHOUT
THE PRESENTATION OF A WRITTEN CONSENT FROM
THEIR LEGAL GUARDIAN(S). PATIENTS MUST
PRESENT AN IDENTIFICATION CARD AT ALL TIMES.
PLEASE DO NOT SMOKE OR DRINK ALCOHOLIC BEVERAGES
BEFORE YOUR APPOINTMENT. THANK YOU FOR
YOUR UNDERSTANDING.

FACILITIES

Ultrasound

3D/4D/5D

Ultrasound

Color Doppler

ECHO

Digital X-Ray

Special Tests

Barium

es, HSG

Lab Tests

tones

AC

Pathology

MT, ECG

Qual/Triple

Quadruple

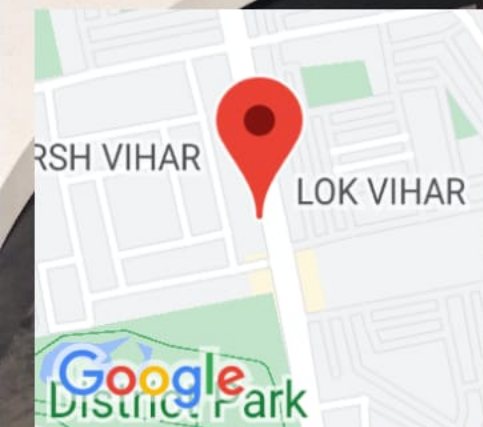
Marker Tests

Timings

10:00 am to

8:00 pm

Days Open



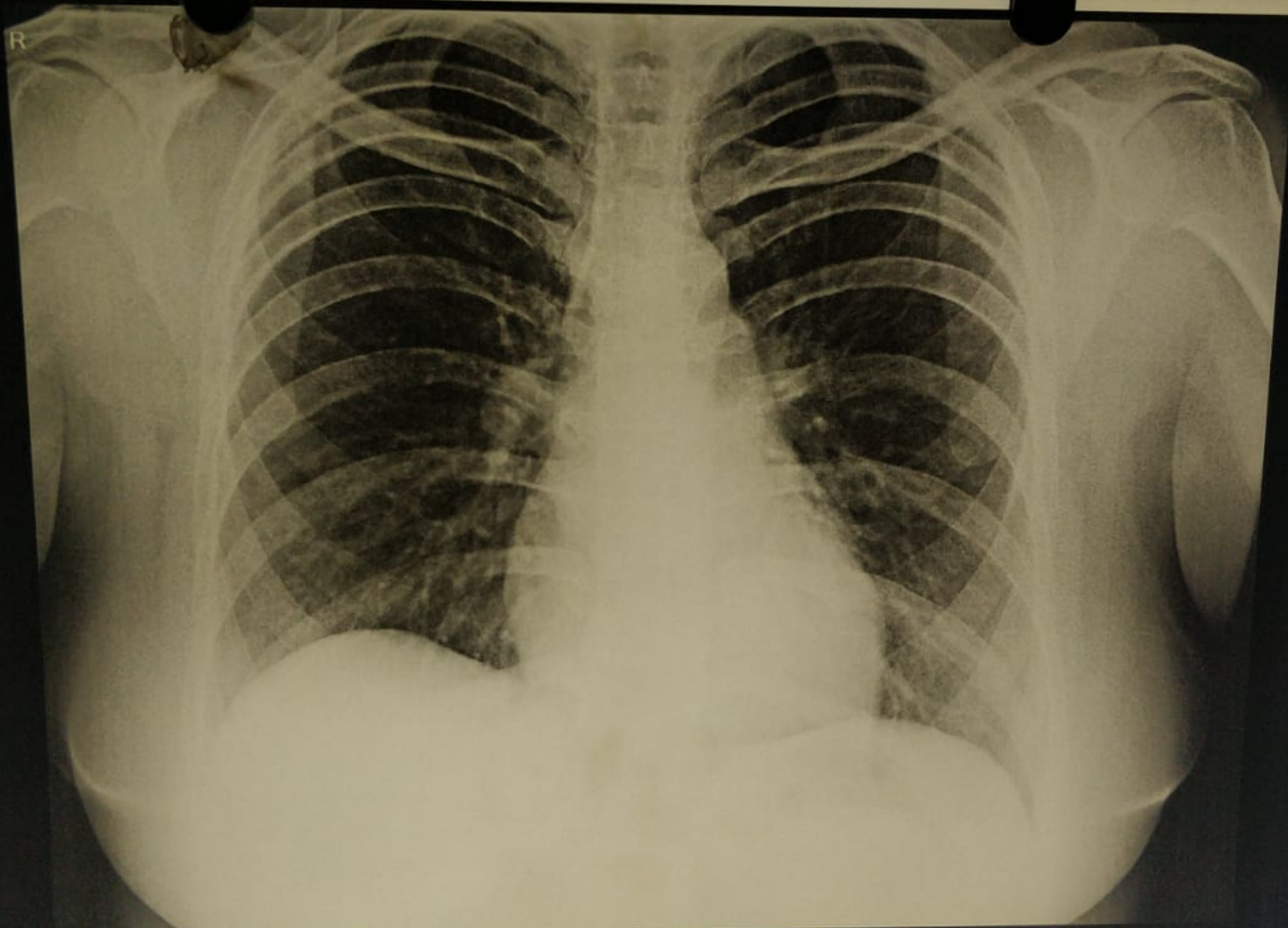
47, Mahatma Hansraj Marg, Harsh
Vihar, Pitampura, Delhi, 110034, India

Lat : 28.6935766

Long : 77.134779

20/04/2024 10:01:01

R



MRS NAMITA 38YRS 20/04/2024 CHEST PA VIEW 4/20/2024
ONEPLUS ULTRASOUND LAB,47-HARSH VIHAR,PITAMPURA