



DEPARTMENT OF LABORATORY

NAVI MUMBAI

Patient Name : Mrs. BULBUL KUMARI	Age / Gender : 34 Y(s)/Female
Bill No/ UMR No : NMBC68051/NMU0051829	Referred By : Dr. DMO
Received Dt : 27-Apr-24 10:07 am	Report Date : 27-Apr-24 03:15 pm

FINAL REPORT

<u>Parameters</u>	<u>Specimen</u>	<u>Result</u>	<u>Biological Reference Intervals</u>	<u>Method</u>
CUE(COMPLETE URINE EXAMINATION)				
<u>PHYSICAL EXAMINATION</u>				
VOLUME	Urine	30ML		
COLOUR		PALE YELLOW	PALE YELLOW	
APPEARANCE		CLEAR	CLEAR	
DEPOSIT		ABSENT	ABSENT	
<u>CHEMICAL EXAMINATION</u>				
SPECIFIC GRAVITY	Urine	1.030	1.000 - 1.030	Dipstick
PH		5.0	5.0 - 8.0	Dipstick
PROTEIN		NEGATIVE	NEGATIVE	Dipstick/Heat coagulation test
GLUCOSE		ABSENT	ABSENT	Dipstick/Benedict's test
UROBILINOGEN		NORMAL	NORMAL	Dipstick
KETONE		NEGATIVE	NEGATIVE	Dipstick/Rothera's Nitroprusside test.
BILIRUBIN		NEGATIVE	NEGATIVE	Dipstick/Fouchet's test
BILE SALT		NEGATIVE	NEGATIVE	Hay's sulphur powder test
BILE PIGMENT		NEGATIVE	NEGATIVE	Fouchet test
NITRITE		NEGATIVE	NEGATIVE	Dipstick
LEUCOCYTE ESTERASE		NEGATIVE	NEGATIVE	
<u>MICROSCOPIC EXAMINATION</u>				
PUS CELLS	Urine	2-3	0 - 5 /hpf	MICROSCOPIC EXAMINATION
RBC		NIL	0 - 5 /hpf	MICROSCOPIC EXAMINATION
EPITHELIAL CELLS		OCCASIONAL	0 - 5 /hpf	MICROSCOPIC EXAMINATION
CRYSTALS		NIL	NIL	MICROSCOPIC EXAMINATION
CASTS		NIL	NIL	MICROSCOPIC EXAMINATION
BACTERIA		ABSENT		MICROSCOPIC EXAMINATION
YEAST		ABSENT		MICROSCOPIC EXAMINATION
AMORPHOUS DEPOSITS		ABSENT		MICROSCOPIC EXAMINATION
SPERMATOZOA				MICROSCOPIC EXAMINATION
MUCUS THREAD		ABSENT		MICROSCOPIC EXAMINATION

NOTE

Microscopic examination of urine is carried out on centrifuged urinary sediment.





MEDICOVER
HOSPITALS

DEPARTMENT OF LABORATORY

NAVI MUMBAI

Patient Name : Mrs. BULBUL KUMARI	Age / Gender : 34 Y(s)/Female
Bill No/ UMR No : NMBC68051/NMU0051829	Referred By : Dr. DMO
Received Dt : 27-Apr-24 10:07 am	Report Date : 27-Apr-24 03:15 pm

Parameters **Specimen** **Result** **Biological Reference In Method**

*** End Of Report ***





DEPARTMENT OF LABORATORY

NAVI MUMBAI

Patient Name : Mrs. BULBUL KUMARI	Age / Gender : 34 Y(s)/Female
Bill No/ UMR No : NMBC68051/NMU0051829	Referred By : Dr. DMO
Received Dt : 27-Apr-24 10:07 am	Report Date : 27-Apr-24 01:36 pm

FINAL REPORT

<u>Parameter</u>	<u>Specimen</u>	<u>Result Values</u>	<u>Biological Reference</u>	<u>Method</u>
COMPLETE BLOOD COUNT				
<u>RBC</u>				
R B C COUNT	Blood	3.66	3.8 - 4.8 $10^6/\mu\text{L}$	
HEMOGLOBIN		11.3	12.0 - 15.0 g/dl	
PCV/HCT		34.3	40 - 50 % 36 - 46 %	
MCV		94	83 - 101 fl 83 - 101 fl	
MCH		30.7	27 - 32 pg	
MCHC		32.8	31.5 - 34.5 g/dL	
RDW(cv)		12.8	11.6 - 14.0 %	
<u>PLATELETS</u>				
PLATELET COUNT	Blood	103	150 - 400 $10^3/\mu\text{L}$	
MPV		11.9	7.5 - 11.5 fl	
<u>WBC</u>				
TC (TOTAL LEUCOCYTE COUNT)	Blood	5.3	4.0 - 11.0 $10^3/\mu\text{l}$	
<u>DIFFERENTIAL COUNT</u>				
NEUTROPHILS	Blood	59	40 - 80 %	
LYMPHOCYTES		31	20 - 40 %	
MONOCYTES		08	02 - 10 %	
EOSINOPHILS		02	00 - 06 %	
BASOPHILS		00	00 - 01 %	
PERIPHERAL SMEAR EXAMINATION		:		
RBC			Mild anisopoikilocytosis. Predominantly normocytic normochromic with ovalocytes.	
WBC			Normal morphology.	
PLATELETS			Mildly reduced in smear. Macroplatelets are also seen.	
ESR	CITRATED BLOOD	75	0 - 20 mm/1st hour	WESTERGREN'S METHOD

*** End Of Report ***





MEDICOVER
HOSPITALS

DEPARTMENT OF LABORATORY

NAVI MUMBAI

Patient Name : Mrs. BULBUL KUMARI	Age / Gender : 34 Y(s)/Female
Bill No/ UMR No : NMBC68051/NMU0051829	Referred By : Dr. DMO
Received Dt : 27-Apr-24 10:07 am	Report Date : 27-Apr-24 12:41 pm

<u>Parameters</u>	<u>Specimen</u>	<u>Result</u>	<u>Biological Reference In Method</u>
-------------------	-----------------	---------------	---------------------------------------





DEPARTMENT OF LABORATORY

NAVI MUMBAI

Patient Name : Mrs. BULBUL KUMARI	Age / Gender : 34 Y(s)/Female
Bill No/ UMR No : NMBC68051/NMU0051829	Referred By : Dr. DMO
Received Dt : 27-Apr-24 10:07 am	Report Date : 27-Apr-24 12:20 pm

FINAL REPORT

<u>Parameters</u>	<u>Specimen</u>	<u>Result</u>	<u>Biological Reference Intervals</u>	<u>Method</u>
SERUM ELECTROLYTES				
SERUM SODIUM		140	136 - 145 mmol/L	ISE INDIRECT
SERUM POTASSIUM		4.0	3.5 - 5.1 mmol/L	ISE INDIRECT
SERUM CHLORIDES		104	98 - 107 mmol/L	ISE INDIRECT
HBA1C (GLYCOSYLATED HAEMOGLOBIN)				
HBA1C		4.9	< 5.7 Normal Prediabetic 5.7 - 6.4 & \geq 6.5 Diabetic %	TINIA
MPG(Mean Plasma Glucose)		93	Excellent Control : 90 - 120 mg/dL Good Control : 121 - 150 mg/dL	
SERUM CREATININE				
CREATININE		0.50	0.6 - 1.2 mg/dl	Method : jaffe
BUN / CREATININE RATIO				
BUN (Blood Urea Nitrogen.)		14	7.0 - 21.0 mg/dL	Calculated
SERUM CREATININE		0.50	0.6 - 1.2 mg/dL	
BUN / CREATININE RATIO		28	10 - 20	
LFT(LIVER FUNCTION TEST)				
TOTAL BILIRUBIN		0.3	< 1.2 mg/dL	Method : Diazo Method
DIRECT BILIRUBIN		0.2	\leq 0.20 mg/dL	Method: Diazo Method
INDIRECT BILIRUBIN		0.1	\leq 1.0 mg/dL	
SGPT (ALT)		18	\leq 33 U/L	Method : UV without P5P
SGOT (AST)		23	\leq 32 U/L	Method : UV without P5P
ALKALINE PHOSPHATASE (ALP)		103	40 - 129 U/L 35 - 105 U/L	Method : PNPP, AMP Buffer - IFCC Ref.
TOTAL PROTEINS		7.3	6.0 - 8.0 g/dL	Method : Biuret method
SERUM ALBUMIN		4.4	3.5 - 5.2 g/dL	Method : Bromcresol Green (BCG)
GLOBULINS		2.9	2.5 - 3.5 g/dL	
A/G RATIO		1.52	1.2 - 2.5	
GAMMA GLUTAMYL TRANSFERASE(GGT)		26	6 - 42 U/L	Method : G-glutamyl-carboxy-nitroanilide - IFCC Ref.
BUN(BLOOD UREA NITROGEN)				
BUN (Blood Urea Nitrogen.)		14	7.0 - 21.0 mg/dL	Calculated





DEPARTMENT OF LABORATORY

NAVI MUMBAI

Patient Name : Mrs. BULBUL KUMARI	Age / Gender : 34 Y(s)/Female
Bill No/ UMR No : NMBC68051/NMU0051829	Referred By : Dr. DMO
Received Dt : 27-Apr-24 10:07 am	Report Date : 27-Apr-24 12:52 pm

<u>Parameter</u>	<u>Specimen</u>	<u>Result Values</u>	<u>Biological Reference</u>	<u>Method</u>
TOTAL PROTEIN				
TOTAL PROTEINS		7.3	6.0 - 8.0 g/dL	Method : Biuret method
LIPID PROFILE				
TOTAL CHOLESTEROL		124	Desirable : : < 200 mg/dL Borderline High : : 200 - 239 mg/dL High risk : > 240 mg/dL	METHOD : Enzymatic colorimetric
HDL CHOLESTEROL		45	Low : : < 40 mg/dL High : : > 60 mg/dL	Homogeneous enzymatic colorimetric
LDL CHOLESTEROL		69	Optimal : - < 100 mg/dL Near Optimal : 100 - 129 mg/dL Borderline High : 130 - 159 mg/dL High : 160 - 189 mg/dL Very High : - > 190 mg/dL	Direct-Enzymatic colorimetric
VLDL		14		
SERUM TRYGLYCERIDES		68	< 150 mg/dL Borderline High : 150 - 199 mg/dL High : 200 - 499 mg/dL	METHOD: Enzymatic colorimetric
CHO/HDL RATIO		2.76	Normal : - < 3.5 High Risk : - > 5.0	
LDL/HDL RATIO		1.53		
SERUM URIC ACID		3.4	2.4 - 5.7 mg/dL	uricase
FBS (FASTING BLOOD GLUCOSE WITH URINE GLUCOSE)				
FASTING BLOOD GLUCOSE		87	Normal Range : 70 - 99 mg/dL	Hexokinase
FASTING URINE SUGAR		Absent		
PLBS (POST LUNCH BLOOD SUGAR WITH URINE SUGAR)				
PLBS (POST LUNCH BLOOD GLUCOSE)		98	110 - 180 mg/dL	Hexokinase
URINE SUGAR		Nil		Dipstick
T3,T4 AND TSH				
T3		128.2	70 - 204 ng/dL	Method : ECLIA
T4		9.61	5.1 - 14.1 ug/dL	Method : ECLIA
TSH(THYROID STIMULATING HORMONE)		0.761	0.270 - 4.20 uIU/mL	Method : ECLIA

*** End Of Report ***





MEDICOVER
HOSPITALS

DEPARTMENT OF LABORATORY

NAVI MUMBAI

Patient Name : Mrs. BULBUL KUMARI	Age / Gender : 34 Y(s)/Female
Bill No/ UMR No : NMBC68051/NMU0051829	Referred By : Dr. DMO
Received Dt : 27-Apr-24 10:08 am	Report Date : 27-Apr-24 04:32 pm

<u>Parameters</u>	<u>Specimen</u>	<u>Result</u>	<u>Biological Reference In Method</u>
-------------------	-----------------	---------------	---------------------------------------

Lab Incharge

Dr. VISHAL MEHROTRA, MD Pathology
Head of Laboratory Services

Verified By : : 026979

Test results related only to the item tested.

No part of the report can be reproduced without written permission of the laboratory.



Patient ID:	NMU0051829	Patient Name:	BULBUL KUMARI
Age:	34 Years	Sex:	F
Accession Number:	NMBC68051	Modality:	US
Referring Physician:	DR.DMO	Study:	USG ABDOMEN WHOLE
Study Date:	27-Apr-2024		

ULTRASOUND EXAMINATION OF ABDOMEN & PELVIS

The Liver is normal in size and shows a normal parenchymal reflectivity. Multiple calcified granulomas are seen in segment VI of right lobe of liver measuring 20 mm and 8.4 mm. The Hepatic veins appear normal. There is no evidence of any dilated IHBR. The portal vein appears normal.

The gall bladder is physiologically distended with normal wall thickness. There is no evidence of gallstones. C.B.D. is of normal caliber.

The Pancreas is normal in size and shows homogeneous reflectivity. There is no evidence of any calcification or ductal dilatation.

The spleen is normal in size and shows a homogeneous echotexture. It measures 10 cm in long axis. There is no evidence of any focal lesion.

Both kidneys are normal in position and size. They show normal cortical reflectivity and cortico-medullary distinction.

The Right Kidney measures 9.8 x 4.0 cm.

The Left Kidney measures 10.6 x 4.1 cm.

There is no evidence of renal calculi, hydronephrosis, or mass noted.

There is no evidence of ascites or para aortic lymphadenopathy.

The Urinary bladder is adequately distended and shows normal wall thickness. No evidence of any intraluminal mass or calculi.

The uterus is Anteverted.

It measures 7.9 x 5.2 x 3.9 cm.

The uterine myometrial echotexture is homogeneous. No focal lesion is seen.

The Endometrial thickness is 6 mm. LSCS scar is seen in lower uterine segment.

Both ovaries are well visualized and appear normal in size and reflectivity.

The Right ovary measures 2.9 x 1.9 cm.

The Left ovary measures 2.5 x 1.8 cm.


There is no evidence of any ovarian or adnexal mass lesion.

No evidence of any fluid collection in the pelvis.

Patient ID:	NMU0051829	Patient Name:	BULBUL KUMARI
Age:	34 Years	Sex:	F
Accession Number:	NMBC68051	Modality:	US
Referring Physician:	DR.DMO	Study:	USG ABDOMEN WHOLE
Study Date:	27-Apr-2024		

IMPRESSION:

- No significant abnormality is seen.



DR JAMILA FANI
Consultant Radiologist
MBBS, MD

Date: 27-Apr-2024 14:30:23

Patient ID:	NMU0051829	Patient Name:	BULBUL KUMARI
Age:	34 Years	Sex:	F
Accession Number:	NMBC68051	Modality:	DX
Referring Physician:	DR.DMO	Study:	CHEST
Study Date:	27-Apr-2024		

X RAY CHEST PA VIEW

Both lungs are clear.

The frontal cardiac dimensions are normal.

The pleural spaces are clear.


Both hilar shadows are normal in position and density.

No diaphragmatic abnormality is seen.

The soft tissues and bony thorax are normal.

Impression:

- **No significant abnormality is seen.**



DR JAMILA FANI
Consultant Radiologist
MBBS, MD

Date: 27-Apr-2024 14:08:01

Patient ID:	NMU0051829	Patient Name:	BULBUL KUMARI
Age:	34 Years	Sex:	F
Accession Number:	NMBC68051	Modality:	US
Referring Physician:	DR.DMO	Study:	USG ABDOMEN WHOLE
Study Date:	27-Apr-2024		

ULTRASOUND EXAMINATION OF THE BREAST

Real -Time Sonography of both the Breasts was done with a high resolution linear transducer.

Normal glandular breast parenchyma is seen in both breasts.

There is no evidence of any solid or cystic mass lesion noted.

There is no evidence of any ductal dilatation seen in the retro-areolar region.

Small reactive lymph nodes with maintained fatty hilum are seen in both axilla.


IMPRESSION:

- **No significant abnormality is seen.**

BIRADS Category I (Negative)

Suggest a routine screening sonomammography after one year.

(BIRADS CATEGORY : BIRADS 0 - Requires additional evaluation, I - Negative, II - Benign findings, III - Probably benign findings, IV - Suspicious abnormality, V-Highly suggestive of malignancy, VI – Known biopsy proven malignancy.)



DR JAMILA FANI
Consultant Radiologist
MBBS, MD

Date: 27-Apr-2024 14:30:53

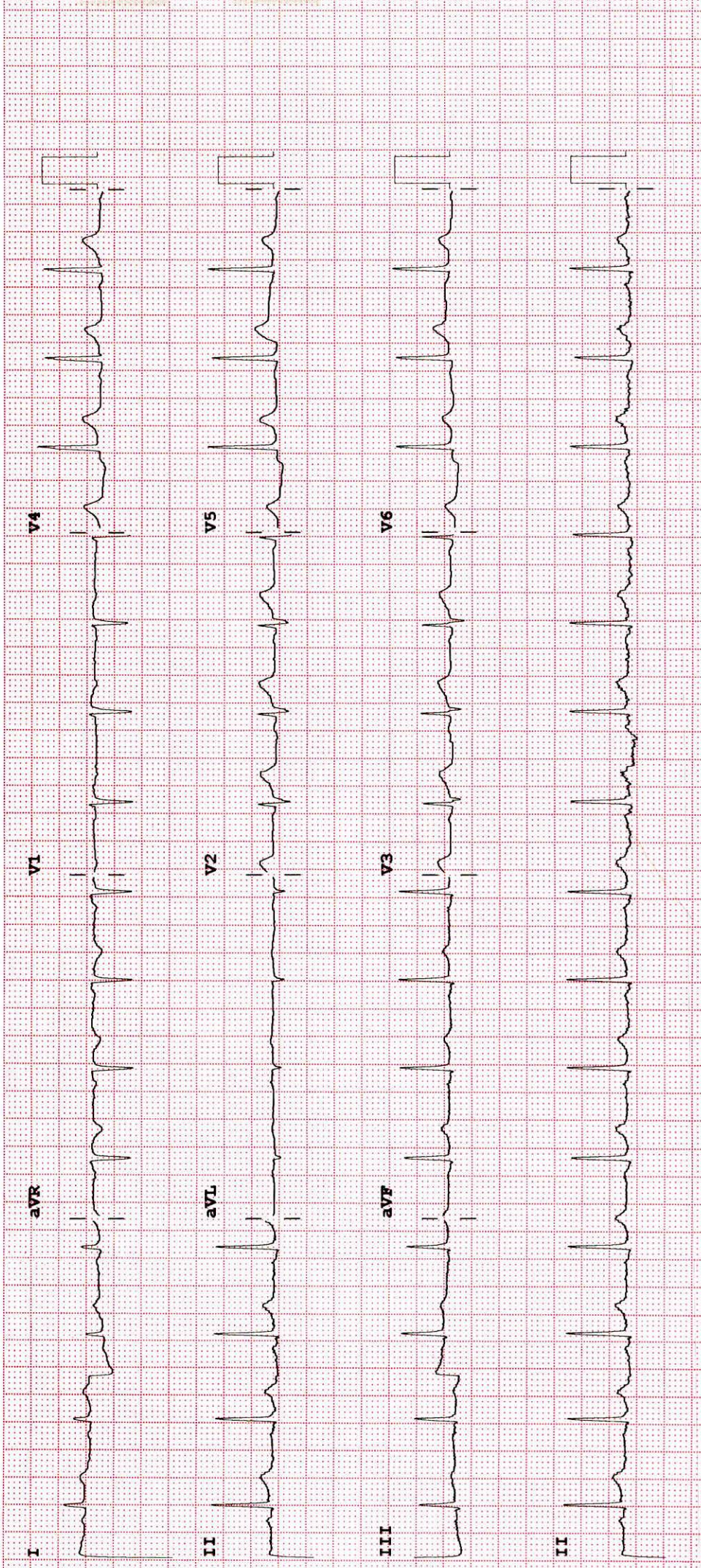
Normal

Rate 93 . Sinus rhythm.....normal P axis, V-rate 50- 99
PR 119 . Borderline short PR interval.....PR int <120ms
QRS 75 . Baseline wander in lead(s) I,II,aVR,aVL

--AXIS--
P 65
QRS 68
T 30
- OTHERWISE NORMAL ECG -

Unconfirmed Diagnosis

12 Lead; Standard Placement





MEDICOVER
HOSPITALS

NAVI MUMBAI

2D ECHO CARDIOGRAPHY WITH COLOR DOPPLER

Name : Mrs. Bulbul Kumari

Date:-27/04/2024

Age / Sex : 34 Yrs / Female

UMR No. 0051829

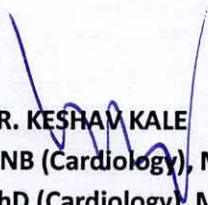
Referred By : Health Check Up

FINDINGS:

- No left ventricle regional wall motion abnormality.
- Normal left ventricle systolic function. LVEF = 60%.
- No left ventricle diastolic dysfunction.
- No mitral regurgitation.
- No aortic regurgitation. No aortic stenosis.
- Trivial tricuspid regurgitation. No pulmonary hypertension.
PASP = 20 mm Hg.
- No left ventricle clot / vegetation/pericardial effusion.
- Intact IAS and IVS.
- Normal left atrium and left ventricle dimensions.
- Normal right atrium and right ventricle dimensions.
- Normal right ventricle systolic function. No hepatic congestion.

IMP:

- No RWMA.
- Trivial TR. No PH.
- Normal LV and RV systolic function.


DR. KESHAV KALE
DNB (Cardiology), MD (Medicine), MBBS
PhD (Cardiology), MNAMS, LL.B (Law)
FSCAI (USA), AFACC (USA), FESC (EU)
Consultant & Interventional Cardiologist





MEDICOVER
HOSPITALS

NAVI MUMBAI

M-MODE MEASUREMENTS:

LA	33	mm
AO root	28	mm
AO CUSP SEP	17	mm
LVID(s)	30	mm
LVID(d)	42	mm
IVS(d)	10	mm
LVPW(d)	10	mm
RVID(d)	29	mm
RA	31	mm
LVEF	60	%

	PEAK	MEAN	Vmax	Gradient of Regurgitation
MITRAL	N			Nil
AORTIC	8			Nil
TRICUSPID	20			Trivial
PULMONERY	4.4			Nil

