



Shubham Imaging & ALC Diagnostic Center

ISO 9001:2015 Certified Center

(A Unit of P. K. Arogyam Health & Wellness Center)

E-95, P.C. Colony, Near Sai Netryalaya Transformer, Kankarbagh, Patna - 20

✉ : alcdiagnostics@gmail.com

🌐 : www.pkarogayamhealthcheckup.com

☎ : 7050037694, 9153988577

OPINION MUST BE CORRELATES WITH CLINICALLY & OTHER INVESTIGATION FOR FINAL DIAGNOSIS. NOT FOR MEDICO LEGAL PURPOSE

PATIENT NAME : Mr. RAHUL KUMAR PATIENT ID : 1023
COL DATE : 24/08/2024 REPORTING DATE: 24/08/2024 AGE SEX : 30 YRS/M
REF.BY : DR. / MEDIWHEEL

TEST NAME	RESULT	Unit	REF.RANGE
-----------	--------	------	-----------

BLOOD SUGAR (F)	94.0 mg/dl		70 - 110 mg/dl
-------------------	------------	--	----------------

LIPID PROFILE:-

TOTAL CHOLESTROL	221.6 mg/dl		130 -250 mg/dl
TRIGLYCERIDE	204.7 mg/dl		50 -160 mg/dl
HDL CHOLESTROL	46.0 mg/dl		30 - 60 mg/dl
LDL CHOLESTROL	131.7 mg/dl		80 -130 mg/dl
VLDL CHOLESTROL	40.9 mg/dl		15 - 40 mg/dl
T.CH./HDL RATIO	4.5 : 1		Upto 5 : 1
LDL /HDL RATIO	2.6 : 1		2 - 4 : 1

AK
24/08/24
Consultant Radiologist

BY:-

Dr. P. K. Tiwari
MD, (Pat)
Consultant Pathologist

Dr. S. Kumar
MD, (Pat)
Consultant Pathologist

Dr. Abhishek Kumar
MBBS, MD
Consultant Neuropathology Specialist

Dr. Kumari Suman
MBBS, DGO, MD
Consultant (TVS & HSG Specialist)

Dr. A. K. Singh
MBBS, PGDMCH
Consultant Radiologist & Sonologist

IMMEDIATELY / यहाँ जन्म से पहले ध्रुण का लिंग जांच नहीं



Shubham Imaging & ALC Diagnostic Center

ISO 9001:2015 Certified Center
(A Unit of P. K. Arogyam Health & Wellness Center)

E-95, P.C. Colony, Near Sai Netryalaya Transformer, Kankarbagh, Patna - 20

✉ : alcdiagnostics@gmail.com

🌐 : www.pkarogayamhealthcheckup.com

☎ : 7050037694, 9153988577

OPINION MUST BE CORRELATES WITH CLINICALLY & OTHER INVESTIGATION FOR FINAL DIAGNOSIS. NOT FOR MEDICO LEGAL PURPOSE

PATIENT NAME : Mr. RAHUL KUMAR
COL DATE : 24/08/2024 REPORTING DATE: 24/08/2024 AGE SEX:- 30 YRS/M
REF. BY : DR. / MEDIWHEEL .

PATIENT ID : 1023

TEST NAME	RESULT	Unit	REF.RANGE
-----------	--------	------	-----------

LFT:-

SGPT	41.0	IU/L	5 - 40 IU/L
SGOT	32.2	IU/L	5 - 40 IU/L
ALKALINE PHOSPHATASE	121.4	IU/L	M - 53 - 165 IU/L F - 42 - 136 IU/L
TOTAL PROTIN	7.8	g/dl	6.0 - 8.7 g/dl
SERUM ALBUMIN	4.7	g/dl	3.5 - 5.4 g/dl
SERIUM GLUBLINE	3.1	g/dl	2.3 - 3.6 g/dl
AG RATIO	1.5: 1		1.0 - 2.3 g/dl
BILIRUBIN			
TOTAL	0.79	mg/dl	0.1 - 1.1 mg/dl
DIRECT	0.31	mg/dl	0.0 - 0.32 mg/dl
INDIRECT	0.48	mg/dl	0.0 - 0.78 mg/dl

GGTP(GGT) 23.2 iu/L 8 - 38 iu/L

KFT/RFT

URIC ACID	6.8	mg/dl	3.2 - 7.0 mg/dl
SERUM CREATNINE	0.9	mg/dl	0.6 - 1.5 mg/dl
BLOOD URIA	31.1	mg/dl	5 - 45 mg/dl
BLOOD URIA NITROZEN(BUN).	14.5	mg/dl	5 - 23 mg/dl

(Signature)
24/08/24

Consultant Radiologist

BY:-

P. K. Tiwari
M.Sc (Radio Imaging)
Mf Nuclear Medicine)
ant Imagonologist

Dr. S. Kumar
MD, (Pat)
Consultant Pathologist

Dr. Abhishek Kumar
MBBS, MD
Consultant Neuropatho Physiologist

Dr. Kumari Suman
MBBS, DGO, MD
Consultant (TVS & HSG Specialist)

Dr. A. K. Singh
MBBS, PGDMCH
Consultant Radiologist & Sonologist

NG MISTAKE SHOULD BE REPORTED BACK IMMEDIATELY / यहाँ जन्म से पहले धुण का लिंग जाँच नहीं होता है



Shubham Imaging & ALC Diagnostic Center

ISO 9001:2015 Certified Center

(A Unit of P. K. Arogyam Health & Wellness Center)

E-95, P.C. Colony, Near Sai Netryalaya Transformer, Kankarbagh, Patna - 20

✉ : alcdiagnostics@gmail.com

🌐 : www.pkarogyamhealthcheckup.com

☎ : 7050037694, 9153988577

OPINION MUST BE CORRELATES WITH CLINICALLY & OTHER INVESTIGATION FOR FINAL DIAGNOSIS. NOT FOR MEDICO-LEGAL PURPOSE

PATIENT NAME : Mr. RAHUL KUMAR

PATIENT ID : 10235

COL DATE : 24/08/2024 REPORTING DATE: 24/08/2024

AGE SEX : 30 YRS/M

REF.BY : DR./MEDIWHEEL

GLYCOSYLATED HEMOGLOBIN

TEST NAME	RESULT	Unit	REF.RANGE
HbA1c	4.1 %		Below 5.7 % : Normal 5.7 - 6.4 % : Prediabetic > = 6.5 % : Diabetic
AVERAGE PLASMA GLUCOSE	109.0 mg/dl		90 - 120 mg/dl : Good Control 121 - 150 mg/dl : Fair Control 151 - 180 mg/dl : Unsatisfactory Control >180 mg/dl : Poor Control

ESTB BY:-

Dr. P. K. Tiwari
MD, M.Sc (Radio Imaging)
Ph.D (Art Nuclear Medicine)
Consultant Imagiologist

Dr. S. Kumar
MD, (Pat)
Consultant Pathologist

Dr. Abhishek Kumar
MBBS, MD
Consultant Neuropatho Physiologist

Dr. Kumari Suman
MBBS, DGO, MD
Consultant (TVS & HSG Specialist)

Dr. A. K. Singh
MBBS, PGDICH
Consultant Radiologist

REPORT TO BE REPORTED BACK IMMEDIATELY / यहाँ जन्म से पहले भ्रूण का लिंग जांच



Shubham Imaging & ALC Diagnostic Center

ISO 9001:2015 Certified Center

(A Unit of P. K. Arogyam Health & Wellness Center)

E-95, P.C. Colony, Near Sai Netryalaya Transformer, Kankarbagh, Patna - 20

☎ : 7050037694, 9153988577

✉ : alcdiagnostics@gmail.com

🌐 : www.pkarogyamhealthcheckup.com

OPINION MUST BE CORRELATES WITH CLINICALLY & OTHER INVESTIGATION FOR FINAL DIAGNOSIS. NOT FOR MEDICO LEGAL PURPOSE

PATIENT NAME : Mr. RAHUL KUMAR

COL DATE

: 24/08/2024

REPORTING DATE: 24/08/2024

PATIENT ID: 1023

REF.BY

: DR. / MEDIWHEEL .

AGE SEX:- 30 YRS/M

TEST NAME	RESULT	Unit	REF.RANGE
ESR	14 mm/hr		<20 mm/hr
CBC			
Total W.B.C. Count	7,500 /cumm		4,000 - 11,000 /cumm
R B C COUNT	4.74 Million/ CUmm		4 - 7 Million/ CUmm
Platelets count	1.82 Lakh/ cumm		1.5 - 5.0 Lakh/ cumm
Differential Count of W.B.C.			
Neutrophils	62 %		40 -70%
Lymphocytes	34 %		25 - 40%
Eosinophils	03 %		01 - 05%
Mnonocytes	01 %		00 - 02%
Basophiles	00 %		00 - 0%
HAEMOGLOBIN	14.2 gm/dl (97.2 %)		14.6 gm/dl = 100%
PCV	41.2 %		35 - 47 %
MCV	87.1 fl		76 - 96 fl
MCH	30.0 pg		29 - 35 pg
MCHC	34.4 %		30 - 38 %

1

24/08/24
Consultant Radiologist

ESTB BY:-

Dr. P. K. Tiwari
MD, M.Sc (Radio Imaging)
Ph.D (Alt Nuclear Medicine)
Consultant Imagiologist

Dr. S. Kumar
MD, (Pat)
Consultant Pathologist

Dr. Abhishek Kumar
MBBS, MD
Consultant Neuropatho Physiologist

Dr. Kumari Suman
MBBS, DGO, MD
Consultant (TVS & HSG Specialist)

Dr. A. K. Singh
MBBS, PGDMCH
Consultant Radiologist & Sonologist

PRINTING MISTAKE SHOULD BE REPORTED BACK IMMEDIATELY / यहाँ जन्म से पहले भ्रुण का लिंग जाँच नहीं होता है

Shubham Imaging & ALC Diagnostic Center

ISO 9001:2015 Certified Center

(A Unit of P. K. Arogyam Health & Wellness Center)

F-95, P.C. Colony, Near Sai Netryalaya Transformer, Kankarbagh, Patna - 20

✉ akdiagnostics@gmail.com

🌐 www.pkrogyamhealthcheckup.com

☎ 7050037694, 9153988577

DISPENSE MUST BE CORRELATES WITH CLINICALLY & OTHER INVESTIGATION FOR FINAL DIAGNOSIS. NOT FOR MEDICAL LEGAL PURPOSE

PATIENT NAME : Mr. RAHUL KUMAR

PATIENT ID: 1023

COL DATE : 24/08/2024


REPORTING DATE: 24/08/2024

AGE SEX: 30 YRS/M

REF. BY : DR. / MEDIWHEEL.

TEST NAME	RESULT	Unit	REF. RANGE
BLOOD GROUP	: ' B '		
Rh Typing	: POSITIVE		

Note: Do always cross - matching before blood transfusion


Dr. A. K. Singh
MBBS, PGDIPACI
Consultant Radiologist & Sonologist

TEST BY:-

Dr. P. K. Tiwari
M.Sc. (Radio Imaging)
D (All Nuclear Medicine)
Consultant Imaging Radiologist

Dr. S. Kumar
MD, (Pat)
Consultant Pathologist

Dr. Abhishek Kumar
MBBS, MD
Consultant Neurospinal Physiologist

Dr. Kumari Suman
MBBS, DGO, MD
Consultant (IVS & HSG) Specialist

Dr. A. K. Singh
MBBS, PGDIPACI
Consultant Radiologist & Sonologist

REPORTING MISTAKE SHOULD BE REPORTED BACK IMMEDIATELY / यहाँ जग से पहले पूरा का लिए जांच नहीं होता है।

Cash Memo
ADVANCE IMAGING DIAGNOSTICS
P.C. Colony, Near Sai Natralaya Transformer, K.Bagh, Patna

Date 24/08/24

Shubham Imaging & ALC Diagnostic Center

ISO 9001:2015 Certified Center

(A Unit of P. K. Arogyam Health & Wellness Center)

E-95, P.C. Colony, Near Sai Natralaya Transformer, Kankarbagh, Patna - 20

alcdiagnostics@gmail.com

www.pkarogayamhealthcheckup.com

7050037694, 9153988577

OPINION MUST BE CORRELATES WITH CLINICALLY & OTHER INVESTIGATION FOR FINAL DIAGNOSIS, NOT FOR MEDICAL LEGAL PURPOSE

PATIENT NAME : Mr. RAHUL KUMAR

PATIENT ID: 2218

COL DATE : 26/08/2024

REPORTING DATE: 26/08/2024

AGE SEX : 30 YRS/M

REF. BY : DR. / ALC POLY CLINIC.

Investigation	Result	Normal Range
Total Triiodothyronin T3	1.51 μ ng/dl	0.80 - 2.00 μ ng/dl
Total Thyroxin T4	8.27 μ ug/dl	5.10-14.10 μ ug/dl
Serum TSH	1.67 μ U/ml	0.27-4.20 μ U/ml


THYROID DISORDER (>: Increase: < Decrease: n Normal

1. T3(n) T4(n) TSH(n) : EUTHYROID STATE:
2. T3(>) T4(>) TSH(<): HYPERTHYROIDISM:
3. T3(<) T4(<) TSH(>): HYPOTHYROIDISM:
4. T3(n) T4(n) TSH(>) : SUB-CLINICAL HYPO-THYROIDISM:
5. T3(n) T4(n) TSH(<): SUB-CLINICAL HYPER-THYROIDISM:
6. T3(>) T4(n) TSH(<): T3 THYROTOXICOSIS:

Total T3/T4 level is dependent on Level:

So determination of free T3/T4 is a better MARKER of Thyroid Function.

*FREE T3/T4 ESTIMATION FACILITY IS AVAILABALE ON REQUEST.:


26/08/24
Consultant Radiologist

Dr. S. Kumar

Dr. Abhishek Kumar
MBBS, MD

Dr. Kumar Suman
MBBS, DGO, MD
Consultant (TVS & HSG Specialist)

Dr. A. K. Singh
MBBS, PGDMCH
Consultant Radiologist & Sonologist



Shubham Imaging & ALC Diagnostic Center

ISO 9001:2015 Certified Center

(A Unit of P. K. Arogyam Health & Wellness Center)

E-95, P.C. Colony, Near Sai Netryalaya Transformer, Kankarbagh, Patna - 20

Email: alcdiagnostics@gmail.com

Website: www.pkarogyanthealthcheckup.com

Phone: 7050037694, 9153988577

OPINION MUST BE CORRELATES WITH CLINICALLY & OTHER INVESTIGATION FOR FINAL DIAGNOSIS, NOT FOR MEDICO LEGAL PURPOSE

Pt. Name :- RAHUL KUMAR
Ref. By :- DR./MEDIWHEEL

Date:- 24-Aug-24
Age / Sex -33 Yrs. M.

REAL TIME U.S.G. OF WHOLE ABDOMEN

Thanks for your kind referral

(Report.)

- LIVER** :- Measures 15.81 cm. Mild Enlarged in shape, size and echo texture fatty change seen in liver parenchyma. I.H.B.R. are not dilated. Hepatic veins are normal. No SOL seen.
- G.BL. :- Lumen is echo free. Wall thickness appears normal.
- C.B.D. :- Measures 3.5 mm in diameter with echo free lumen. No calculi or mass seen.
- P.V. :- Measures 7.7 mm in diameter. Appears normal. No thrombus seen.
- PANCREAS :- Normal in shape, size and echo texture. No calcification mass seen.
- SPLEEN :- Measures 11.37 cm. Normal in shape, size and echo texture. No SOL seen.
- KIDNEY :- Both kidney shows normal shape, size & echotexture. C.M.D intact. P.C.S.is not dilated. No calculi, cyst or hydronephrosis seen on either side.
Right Kidney :- Measures 9.27 x 4.20 cm.
Left Kidney :- Measures 10.25 x 4.50 cm.
- URETER :- Not dilated. No apparent calculi seen.
- U.BLADDER:- Shows normal in outline with echo free lumen. No calculi or mass seen.
Pre void - ml. Post void - is in significant
- PROSTATE :- Normal in size, shape, and echo texture. No calcification, mass, growth seen. capsule is intact.
- R.I.F. :- No son graphically no appendicular mass or collection seen.
- OTHERS :- No Ascites. no Lymph Adenopathy. No pleural effusion seen on either side.

IMPRESSION

- *Mild Hepatomegaly With fatty liver G-I.*
➤ *Adv:- Further work up/ other investigation.*
Otherwise son graphically normal scan. of rest organs

ESTB BY:-

Dr. P. K. Tiwari
MD, M.Sc (Radio Imaging)
Medicine

Dr. S. Kumar
MD, (Pat)
Consultant Pathologist

Dr. Abhishek Kumar
MBBS, MD
Consultant Neuropatho Physiologist

Dr. Kumari Suman
MBBS, DGO, MD
Consultant (TVS & HSG Specialist)

Dr. A. K. Singh
MBBS, PGDMCH
Consultant Radiologist &

गहाँ जन्म से पहले भ्रूण का लिंग जांच

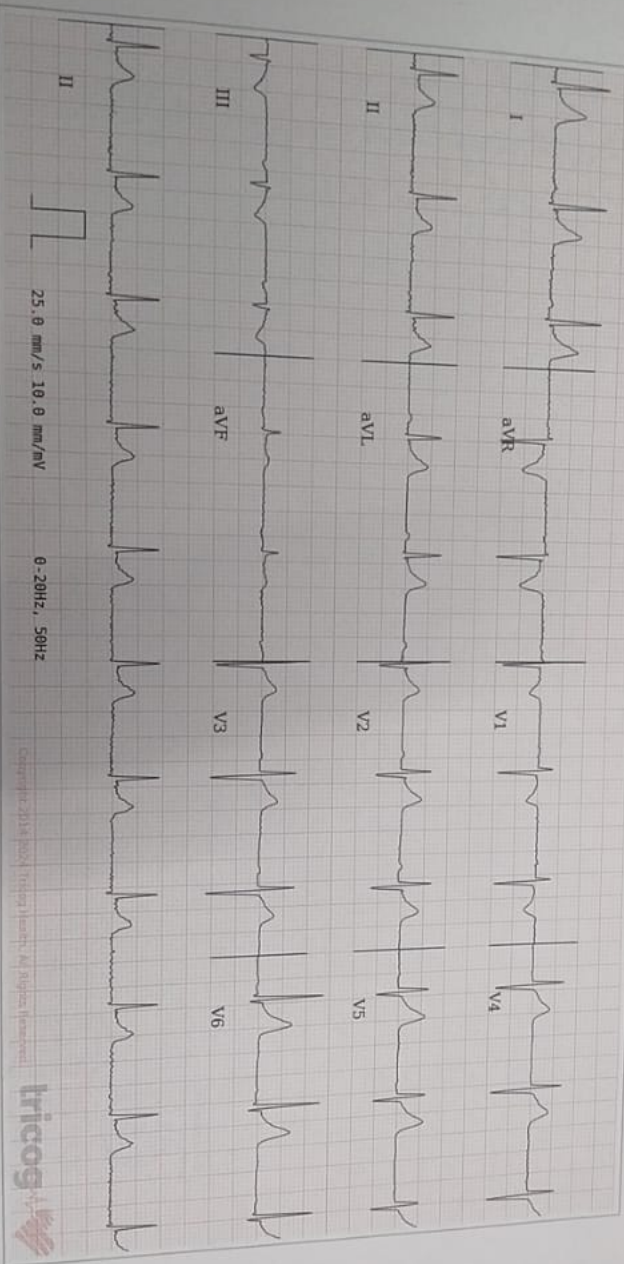
Consultant Radiologist



P. K AROGYAM

Date and Time: 24th Aug 24 11:33 AM


Age / Gender: 33 / Male
Patient ID: 1023
Patient Name: Rahul kumar



AR: 66bpm VR: 65bpm ORSD: 80ms QT: 360ms QTcB: 374.7ms PRI: 162ms P-R-T: -23° 21° 12°

25.0 mm/s 10.0 mm/mV 0.20Hz, 50Hz

Copyright © 2018 Philips Medical Systems. All Rights Reserved.



ECG Within Normal Limits: Limb Lead Reversal Suspected, Sinus Rhythm. Possible LA-LI interchange. Please correlate clinically.

