



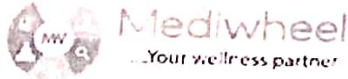Corporate Head <shreeramhospital.corphead@gmail.com>

Health Check up Booking Confirmed Request(22E31491),Package Code-PKG10000366, Beneficiary Code-319416

1 message

Mediwheel <wellness@mediwheel.in>
To: shreeramhospital.corphead@gmail.com
Cc: customercare@mediwheel.in

Wed, Aug 21, 2024 at 11:55 AM



011-41195959

Hi **Shree Ram multispeciality Hospital,**

The following booking has been confirmed. It is requested to honor the said booking & provide priority services to our client

Hospital Package Name : Mediwheel Full Body Annual Plus

Patient Package Name : Mediwheel Full Body Health Checkup Male Below 40

Hospital Address : Gate No.1, Basant Vihar, near Railway Under Bridge, Gondwara Chowk, Gudhiyari, Raipur, Chhattisgarh- 492001

Contact Details : 8895818525

Appointment Date : 24-08-2024

Confirmation Status : Booking Confirmed

Preferred Time : 8:30am

Member Information		
Booked Member Name	Age	Gender
MR. SA BISHNU PRASAD	34 year	Male

We request you to facilitate the employee on priority.

Thanks,
Mediwheel Team

Please Download Mediwheel App



You have received this mail because your e-mail ID is registered with **Arcofemi Healthcare Limited** This is a system-generated e-mail please don't reply to this message.

Please visit to our [Terms & Conditions](#) for more informaion. [Click here to unsubscribe.](#)



ଭାରତର ଏକମାତ୍ର ସମ୍ପୂର୍ଣ୍ଣ
Unique Identification Authority of India

ଠିକଣା, ବିଜି, ଗଡ଼ରାମାଲ, ନିଜା
ମୁମ୍ବାଇ, ଓଡ଼ିଶା, 766108

Address: NILAJI
Gadaramal, Nuapada, Nilaji,
Odisha, 766108

5241 1170 1696

1947
1800 300 1947

help@uidai.gov.in

www.uidai.gov.in



ଭାରତ ସରକାର
Government of India



ବିଶ୍ଵ ପ୍ରସାଦ ସା
BISHNU PRASAD SA
ପିତା ଲୋକନାଥ ସା
Father: LOKANATH SA

ଜନ୍ମ ତାରିଖ / DOB 05/06/1990
ଲିଙ୍ଗ / Male



5241 1170 1696

ଆଧାର - ସାଧାରଣ ଲୋକର ଅଧିକାର



Shree Ram Multispeciality Hospital (SRMH)

L o k a h S a m a s t a S u k h i n o B h a v a n t u

EXAMINATION OF EYES:- (BY OPHTHALMOLOGIST)


Patient Name Prashant P. So

Date 24/8/24

Sex/ Age 34/M

UHID.....

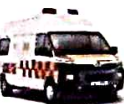EXTERNAL EXAMINATION				
SQUINT		NIO		
NYSTAGMUS				
COLOUR VISION		NORMAL		
FUNDUS : (RE):-		WNL	(LE):-	WNL
INDIVIDUAL COLOUR IDENTIFICATION		Good		
DISTANT VISION:(RE):-		6/6	(LE):-	6/6
NEAR VISION:(RE):-		N/G	(LE):-	N/G
NIGHT BLINDNESS				
	SPH	CYL	AXIS	ADD
RIGHT				
LEFT				
REMARKS:-				



📍 Near Railway Under Bridge, Basant Vihar Gate No. 1, Gondwara Chowk, Gudhiyari, Raipur (Chhattisgarh)

☎ 0771-43 43 161, 0771-43 40 162, 📞 8404 8404 79

✉ shreeramhospital.op@gmail.com 🌐 www.srmhraipur.com





Shree Ram Multispeciality Hospital (SRMH)

Shree Ram Multispeciality Hospital (SRMH)

Lokah Samasta Sukhino Bhavantu

OPD - ID : 02024-2025-0000001

PT. TYPE : NEW REGISTRATION

UHI-ID : SRMH-2408881

PRINT DATE : 24/08-2024 / 01:15

TOKEN NO. : 4

PATIENT NAME	: MR. BISHNU PRASAD SA	DEPARTMENT	: ENT
AGE / SEX	: 34 -Y 0-M 0-D / MALE	DOB	: none
CONSULT-DATE	: 24-AUG-2024 - 11:24 AM		
MOB-NO	: 8895818552	COMPANY NAME	: MEDIWHEEL
GUARDIAN NAME	: LOKHNATH	OPD PAID FEE	: 0.00
ADDRESS	: NILAJI GASARAMAL NUAPADA NILAJI		

Weight : Temp : B.P. : Pulse : SPO2 :

Please indicate whether you are presently suffering from anyone of the following symptoms:

Yes No

Ears, Nose, Mouth, Throat

Ear pain	0	✓
Ear itch	0	✓
Ear drainage	0	✓
Dizziness/ Loss of balance	0	✓
Loss of Hearing	0	✓
Popping Noise	0	✓
Tinnitus	0	✓
Nosebleeds	0	✓
Post-nasal Drip	0	✓
Sinus pain	0	✓
Sinus pressure	0	✓
Nasal congestion	0	✓
Loss of smell/taste	0	✓
Hoarseness	0	✓
Sore Throat	0	✓
Throat tickle	0	✓
Dry Mouth / Throat	0	✓
Throat clearing	0	✓
Snoring	0	✓

Present chief complaints:- No further complaints

Dr. Signature

FOLLOW-UP DATE : ADVICE

FOR ADMISSION

YES	NO
-----	----



Near Railway Under Bridge, Basant Vihar Gate No. 1, Gondwara Chowk, Gudhiyari, Raipur (Chhattisgarh)

0771-43 43 161, 0771-43 40 162, 8404 8404 79

shreeramhospital.op@gmail.com www.srmhraiipur.com





Shree Ram Multispeciality Hospital (SRMH)

Lokah Samasta Sukhino Bhavantu

OPD - ID : 02024 - 2025-0000001
UH-ID : SRMH-2408881

PT. TYPE : FREE OPD
PRINT DATE : 24-08-2024 / 12:50:26



6873041

PATIENT NAME	: MR. BISHNU PRASAD SA	OPD-DATE	: 24-Aug-2024 - 12:50 PM
AGE / SEX	: 34-Y 2-M 22-D / MALE	DEPARTMENT	: GENERAL MEDICINE
DOB	:	CONSULTANT	: DR. AJIT KUMAR
MOB-NO	: 8895818525	COMPANY NAME	: MEDIWHEEL
GUARDIAN NAME	: S/o LOKAANATH SA	OPD PAID FEE	: 0.00
ADDRESS	: NILAJI GASARAMAL NUAPADA NILAJI, RAIPUR, C.G.		

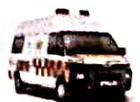Weight : 88.2kg Height : Temp : 91.8°F B.P. : 130/80 Pulse : 117bpm SPO2 : 99%.



📍 Near Railway Under Bridge, Basant Vihar Gate No. 1, Gondwara Chowk, Gudhiyari, Raipur (Chhattisgarh)

☎ 0771-43 43 161, 0771-43 40 162, 📞 8404 8404 79

✉ shreeramhospital.op@gmail.com 🌐 www.srmhraipur.com



📍 Near Railway Under Bridge, Basant Vihar Gate No. 1, Gondwara Chowk, Gudhiyari, Raipur (Chhattisgarh)

☎ 0771-43 43 161, 0771-43 40 162, 📞 8404 8404 79

✉ shreeramhospital.op@gmail.com 🌐 www.srmhraipur.com





Shree Ram Multispeciality Hospital (SRMH)

L o k a h S a m a s t a S u k h i n o B h a v a n t u

PT. NAME : MR. BISHNU PRASAD SA
MOBILE NO : 8895818525 TEST NO 622
DOCTOR : DR. AJIT KUMAR
REFERRED BY : SELF

AGE / SEX : 34Y 2M 22D/MALE
UH ID NO. : SRMH-2408881
COLLECTION : 24-08-2024
REPORTING : 24-Aug-2024

HAEMATOLOGY

TEST NAME	RESULT	UNIT	NORMAL VALUES
CBC (COMPLETE BLOOD COUNT)			
HAEMOGLOBIN (Hb)	13.7	gm%	13.5 - 17.5
TOTAL RBC COUNT	5.28	Million/cumm	4.5 - 5.9
HAEMATOCRIT (PCV)	41.2	%	41.5 - 50.4
RBC INDICES			
MCV	78.4	fl	78 - 96
MCH	27.5	pg	27 - 32
MCHC	32.6	%	33 - 37
RDW	12.1	%	11 - 16
TOTAL WBC COUNT (TLC)	9500	/cumm	4000 - 11000
DIFFERENTIAL COUNT			
NEUTROPHILS	67	%	40 - 70
LYMPHOCYTES	26	%	22 - 48
EOSINOPHILS	03	%	0 - 6
MONOCYTES	04	%	2 - 10
BASOPHILS	00	%	-
PLATELET COUNT	2.82	/cumm	1.50 - 4.50
PCT	0.17	%	0.10 - 0.28
MPV(MEAN PLATELET VOLUME)	10.2	µm ³	8 - 11
PDW	14.8	%	11 - 18


ESR

ESR	10	mm /hr	0 - 15
-----	----	--------	--------

-- End Of Report --

LAB TECHNICIAN

Note : This Report is not for medicolegal purpose


Dr. Dhananjay Prasad
MBBS, MD (Pathologist)

📍 Near Railway Under Bridge, Basant Vihar Gate No. 1, Gondwara Chowk, Gudhiyari, Raipur (Chhattisgarh)

☎ 0771-43 43 161, 0771-43 40 162, 📞 8404 8404 79

✉ shreeramhospital.op@gmail.com 🌐 www.srmh.org





Shree Ram Multispeciality Hospital (SRMH)

Lokah Samasta Sukhino Bhavantu

PT. NAME : MR. BISHNU PRASAD SA
MOBILE NO : 8895818525 TEST NO 622
DOCTOR : DR. AJIT KUMAR
REFERRED BY : SELF

AGE / SEX : 34Y 2M 22D/MALE
UH ID NO. : SRMH-2408881
COLLECTION : 24-08-2024
REPORTING : 24-Aug-2024

HAEMATOLOGY

TEST NAME	RESULT	UNIT	NORMAL VALUES
BLOOD GROUPING AND RH TYPING			
BLOOD GROUP	"O"		-
RH FACTOR	NEGATIVE		-

-- End Of Report --

LAB TECHNICIAN

Note : This Report is not for medicolegal purpose



Dr. Dhananjay Prasad
MBBS, MD (Pathologist)

📍 Near Railway Under Bridge, Basant Vihar Gate No. 1, Gondwara Chowk,
Gudhiyari, Raipur (Chhattisgarh)

☎ 0771-43 43 161, 0771-43 40 162, 📞 8404 8404 79

✉ shreeramhospital.op@gmail.com 🌐 www.srmhraipur.com





Shree Ram Multispeciality Hospital (SRMH)

L o k a h S a m a s t a S u k h i n o B h a v a n t u

PT NAME : MR. BISHNU PRASAD SA
MOBILE NO : 8895818525 TEST NO 622
DOCTOR : DR AJIT KUMAR
REFERRED BY : SELF

AGE / SEX : 34Y 2M 22D/MALE
UH ID NO : SRMH-2408881
COLLECTION : 24-08-2024
REPORTING : 24-Aug-2024

BIOCHEMISTRY

TEST NAME	RESULT	UNIT	NORMAL VALUES
CREATININE			
CREATININE	0.87	mg / dl	0.6 - 1.2
URIC ACID			
URIC ACID	4.91	mg/dL	3.6 - 7.7

-- End Of Report --

LAB TECHNICIAN

Note : This Report is not for medicolegal purpose

Dr. Dhananjay Prasad
MBBS, MD (Pathologist)

Near Railway Under Bridge, Basant Vihar Gate No. 1, Gondwara Chowk,
Gudhiyari, Raipur (Chhattisgarh)

☎ 0771-43 43 161, 0771-43 40 162, 📞 8404 8404 79
✉ shreeramhospital.op@gmail.com 🌐 www.srmhraiipur.com

24/7
Emergency





Shree Ram Multispeciality Hospital (SRMH)

L o k a h S a m a s t a S u k h i n o B h a v a n t u

PT. NAME : MR. BISHNU PRASAD SA
MOBILE NO : 8895818525 TEST NO 622
DOCTOR : DR. AJIT KUMAR
REFERRED BY : SELF

AGE / SEX : 34Y 2M 22D/MALE
UH ID NO. : SRMH-2408881
COLLECTION : 24-08-2024
REPORTING : 24-Aug-2024

BIOCHEMISTRY

TEST NAME	RESULT	UNIT	NORMAL VALUES
LIVER FUNCTION TEST (LFT)			
BILIRUBIN TOTAL	0.51	mg/dL	0.2 - 1
BILIRUBIN DIRECT	0.22	mg / dl	0.1 - 0.6
BILIRUBIN INDIRECT	0.29	mg / dl	0.1 - 0.4
SGOT	28.6	U / L	0 - 46
SGPT	25.3	U / L	0 - 40
ALKALINE PHOSPHATASE	189.5	U / L	0 - 240
TOTAL PROTEIN	6.43	g / dl	6 - 8
ALBUMIN	3.85	g/dl	3.5 - 5.0
GLOBULIN	2.58	g / dl	2 - 3.5
A/G RATIO	1.49		1 - 2.5

Clinical Significance

Alanine transaminase (ALT)

ALT is an enzyme found in the liver that helps your body metabolize protein. When the liver is damaged, ALT is released into the bloodstream and levels increase.

Aspartate transaminase (AST)

AST is an enzyme that helps metabolize alanine, an amino acid. Like ALT, AST is normally present in blood at low levels. An increase in AST levels may indicate liver damage or disease or muscle damage.

Alkaline phosphatase (ALP)

ALP is an enzyme in the liver, bile ducts and bone. Higher-than-normal levels of ALP may indicate liver damage or disease, such as a blocked bile duct, or certain bone diseases.

Albumin and total protein

Albumin is one of several proteins made in the liver. Your body needs these proteins to fight infections and to perform other functions. Lower-than-normal levels of albumin and total protein might indicate liver damage or disease.

Bilirubin.

Bilirubin is a substance produced during the normal breakdown of red blood cells. Bilirubin passes through the liver and is excreted in stool. Elevated levels of bilirubin (jaundice) might indicate liver damage or disease or certain types of anemia.

-- End Of Report --

LAB TECHNICIAN

Note : This Report is not for medicolegal purpose

Dr. Dhananjay Prasad
MBBS, MD (Pathologist)

☉ Near Railway Under Bridge, Basant Vihar Gate No. 1, Gondwara Chowk, Gudhiyari, Raipur (Chhattisgarh)

☎ 0771-43 43 161, 0771-43 40 162, 📞 8404 8404 79

✉ shreeramhospital.op@gmail.com 🌐 www.srmhraipur.com





Shree Ram Multispeciality Hospital (SRMH)

Lokah Samasta Sukhino Bhavantu

PT. NAME : MR. BISHNU PRASAD SA
MOBILE NO : 8895818525 TEST NO 622
DOCTOR : DR. AJIT KUMAR
REFERRED BY : SELF

AGE / SEX : 34Y 2M 22D/MALE
UH ID NO : SRMH-2408881
COLLECTION : 24-08-2024
REPORTING : 24-Aug-2024

BIOCHEMISTRY

TEST NAME	RESULT	UNIT	NORMAL VALUES
LIPID PROFILE			
CHOLESTEROL	204.5	mg / dl	150 - 220
SERUM TRYGLYCERIDE	119.6	mg / dl	60 - 165
HDL	35.3	mg / dl	35 - 80
LDL	169.2	mg/dL	90 - 160
VLDL	23.92	mg/dL	20 - 50
CHOLESTEROL / HDL RATIO	5.79	mg/dL	3.5 - 5.5
LDL/HDL Ratio	4.79	mg / dl	2.5 - 3.5
TRIGLYCERIDES / HDL RATIO	3.38	mg / dl	2.0 - 4.0

-- End Of Report --

LAB TECHNICIAN

Dr. Dhananjay Prasad
MBBS, MD (Pathologist)

Note : This Report is not for medicolegal purpose

Near Railway Under Bridge, Basant Vihar Gate No. 1, Gondwara Chowk,
Gudhiyari, Raipur (Chhattisgarh)

☎ 0771-43 43 161, 0771-43 40 162, 📞 8404 8404 79

✉ shreeramhospital.op@gmail.com 🌐 www.srmhraipur.com

24/7
Emergency
Services





Shree Ram Multispeciality Hospital (SRMH)

L o k a h S a m a s t a S u k h i n o B h a v a n t u

PT. NAME : MR. BISHNU PRASAD SA
MOBILE NO : 8895818525 TEST NO 622
DOCTOR : DR. AJIT KUMAR
REFERRED BY : SELF

AGE / SEX : 34Y 2M 22D/MALE
UH ID NO. : SRMH-2408881
COLLECTION : 24-08-2024
REPORTING : 24-Aug-2024

BIOCHEMISTRY

TEST NAME	RESULT	UNIT	NORMAL VALUES
BLOOD SUGAR - FASTING AND PP			
BLOOD SUGAR FASTING	94.2	mg/dL	70 - 120
BLOOD SUGAR PP	125.3	mg/dL	80 - 140

CLINICAL PATHOLOGY

TEST NAME	RESULT	UNIT	NORMAL VALUES
URINE SUGAR FASTING AND PP			
URINE SUGAR FASTING	Absent		Absent -
URINE SUGAR PP	Absent		Absent -

-- End Of Report --

LAB TECHNICIAN

Note : This Report is not for medicolegal purpose

Dr. Dhananjay Prasad
MBBS, MD (Pathologist)

📍 Near Railway Under Bridge, Basant Vihar Gate No. 1, Gondwara Chowk,
Gudhiyari, Raipur (Chhattisgarh)

☎ 0771-43 43 161, 0771-43 40 162, 📞 8404 8404 79

✉ shreeramhospital.op@gmail.com 🌐 www.srmhraipur.com





Shree Ram Multispeciality Hospital (SRMH)

L o k a h S a m a s t a S u k h i n o B h a v a n t u

Mr BISHNU PRASAD SA
Age: 34 Years Sex: Male

Sample Collected At:
Ref. By: Dr. AJIT KUMAR (MD)
UH ID NO. - SRMH - 2408881

Registered: 24 Aug, 24 01:27 PM
Collected: 24 Aug, 24 01:16 PM
Reported: 24 Aug, 24 07:05 PM

BUN / Creatinine Ratio PANAL

Investigation	Observed Value	Unit	Biological Reference Interval
BUN			
BUN	13.6	mg/dL	7.00 - 20.00
Serum Creatinine	0.87	mg/dL	0.55 - 1.20
BUN / Creatinine Ratio	15.63		10:1 - 20:1

Blood urea nitrogen (BUN) is a waste product produced when the liver breaks down protein. The kidneys then filter it out of the blood and eliminate it through urine. Creatinine is a waste product created by the breakdown of phosphocreatine, a molecule stored in muscle tissue. The kidneys filter creatinine from the blood, and its levels in the body reflect the efficiency of the kidney's excretory function. therefore, BUN and creatinine are useful markers in assessing kidney health because they help doctors evaluate the kidney's filtration rate.



Dr. D. Prasad
M.D. (Pathologist)

END OF REPORT
Near Railway Under Bridge, Basant Vihar Gate No. 1, Gondwara Chowk,
Gudhiyari, Raipur (Chhattisgarh)

☎ 0771-43 43 161, 0771-43 40 162, 📞 8404 8404 79

✉ shreeramhospital.op@gmail.com 🌐 www.srmhraipur.com

24/7
Emergency
Services





Shree Ram Multispeciality Hospital (SRMH)

L o k a h S a m a s t a S u k h i n o B h a v a n t u

Mr BISHNU PRASAD SA
Age: 34 Years Sex: Male

Sample Collected At:
Ref. By: Dr. AJIT KUMAR (MD)
UH ID NO. – SRMH - 2408881

Registered: 24 Aug, 24 01:27 PM
Collected: 24 Aug, 24 01:16 PM
Reported: 24 Aug, 24 07:05 PM

TFT

Thyroid Function Test (TFT)

Investigation	Observed Value	Unit	Biological Reference Interval
THYROID SERUM HORMONS			
Serum Triiodothyronine (T3)	0.95	ng/mL	0.89 - 1.87
Serum thyroxine (T4)	10.12	ug/dL	5.1 - 14.28
Thyroid Stimulating Hormone (TSH)	1.22	μIU/mL	0.66 - 5.67

Comments:-

- (i) Ethnicity, iodine intake, gender, age, body mass index and Exercise influences the reference range of Thyroid hormones and serum TSH concentrations.
- (ii) Changes in Thyroid Hormones (especially T3) and TSH may be seen as early as 24 hours after the onset of non-thyroid illness. (Poor nutrition/starvation, sepsis, burns, malignancy, myocardial infarction, post-surgery, and with chronic liver and renal disease)
- (iii) Serum total T4 and T3 concentrations increase to approximately 150% of non-pregnant values – this occurs during the first half of pregnancy and is maintained thereafter until parturition. Free T4 concentrations also change during pregnancy: in the first trimester a transient rise is often observed.
- (iv) Measurement of FT4 and FT3 is best avoided in patients receiving heparin therapy. (When indicated, blood sample should be taken 10 hours after the last injection of heparin, and analyzing it without delay, can reduce the risk of artifactual hyperthyroxinaemia.)
- (v) Phenytoin, carbamazepine and furosemide cause artifactual increase in free T4 (FT4) and decrease in total T4.



Dr. D. Prasad
M.D. (Pathologist)

END OF REPORT
Near Railway Under Bridge, Basant Vihar Gate No. 1, Gondwara Chowk,
Gudhiyari, Raipur (Chhattisgarh)

☎ 0771-43 43 161, 0771-43 40 162, 📞 8404 8404 79

✉ shreeramhospital.op@gmail.com 🌐 www.srmhraipur.com





Shree Ram Multispeciality Hospital (SRMH)

L o k a h S a m a s t a S u k h i n o B h a v a n t u

Mr. BISHNU PRASAD SA

Sample Collected At :

Registered : 24 Aug,24 02:22PM

Age: 34 Years

Ref By : Dr.AJIT KUMAR

Collected : 24 Aug,24 02.:10PM

Sex:-Male

UH ID NO. – SRMH -2408881

Reported : 25 Aug,24 12:11PM

GAMAMA GLUTAMYL TRANSFERASE (GGT)

INVESTIGATION	RESULT	REFERENCE VALUE	UNIT
GAMMA – GLUTAMYL TRANSFERASE (GGT) , SERUM	15.9	12.00-18.00	U/L


GENDER - NORMAL RANGE(U/L)

MALE - 12.00-18.00

FEMALE - 6.00-29.00

COMMENTS:-

Gamma – Glutamyl Transferase (Ggt) Is An Enzyme That Is Found In Many Organs Throughtout The Body , With The Highest Concentrations Found In The Liver .Ggt Is Elevated In The Blood In Most Diseases That Cause Damage To The Liver Or Bile Ducts ,This Test Measures The Level Of Ggt In A Blood Samle.


 DR. DHANANJAY PRASAD
 (MD Pathology)

Near Railway Under Bridge, Basant Vihar Gate No. 1, Gondwara Chowk, Gudhiyari, Raipur (Chhattisgarh)

☎ 0771-43 43 161, 0771-43 40 162, 📞 8404 8404 79

✉ shreeramhospital.op@gmail.com 🌐 www.srmhraipur.com

24/7
Emergency
Services





Shree Ram Multispeciality Hospital (SRMH)

Lokah Samasta Sukhino Bhavantu

PT. NAME : MR. BISHNU PRASAD SA
 MOBILE NO : 8895818525 TEST NO 622
 DOCTOR : DR. AJIT KUMAR
 REFERED BY : SELF

AGE / SEX : 34Y 2M 22D/MALE
 UH ID NO. : SRMH-2408881
 COLLECTION : 24-08-2024
 REPORTING : 24-Aug-2024

CLINICAL PATHOLOGY

TEST NAME	RESULT	UNIT	NORMAL VALUES
URINE ROUTINE AND MICROSCOPY			
PHYSICAL EXAMINATION			
QUANTITY	20	ml	-
COLOUR	Yellow		Pale Yellow -
APPEARANCE	Clear		Clear -
REACTION	Acitic		Acitic -
CHEMICAL EXAMINATION			
ALBUMIN	Absent		Absent -
SUGAR	Absent		Absent -
KETONE	Absent		Absent -
BILE SALT	Absent		Absent -
BILE PIGMENT	Absent		Absent -
MICROSCOPIC EXAMINATION			
PUS CELLS	2-3	/hpf	2 - 5
EPITHELIAL CELLS	1-2	/hpf	1 - 5
RBC	Nil	/hpf	0 - 3
CAST	Nil	/lpf	Nil -
YEAST	Nil		Nil -
CRYSTAL	Nil	/lpf	Nil -
BACTERIA	Nil		Nil -
OTHERS	-		-

-- End Of Report --

LAB TECHNICIAN

Note : This Report is not for medicolegal purpose



Dr. Dhananjay Prasad
 MBBS, MD (Pathologist)

📍 Near Railway Under Bridge, Basant Vihar Gate No. 1, Gondwara Chowk,
 Gudhiyari, Raipur (Chhattisgarh)

☎ 0771-43 43 161, 0771-43 40 162, 📞 8404 8404 79

✉ shreeramhospital.op@gmail.com 🌐 www.srmhraipur.com





Shree Ram Multispeciality Hospital (SRMH)

L o k a h S a m a s t a S u k h i n o B h a v a n t u

PT. NAME : MR. BISHNU PRASAD SA
MOBILE NO : 8895818525 TEST NO 622
DOCTOR : DR. AJIT KUMAR
REFERRED BY : SELF

AGE / SEX : 34Y 2M 22D/MALE
UH ID NO. : SRMH-2408881
COLLECTION : 24-08-2024
REPORTING : 24-Aug-2024

BIOCHEMISTRY

TEST NAME	RESULT	UNIT	NORMAL VALUES
HbA1c -Glycosylated hemoglobin			
HbA1c -Glycosylated hemoglobin	4.98	%	Normal Range : <6% Good Control : 6-7% fair Control : 7-8% Unsatisfactory Control : 8-10% Poor Control : >10% -
Estimated average plasma glucose	99.98	mg/dl	80 - 120

-- End Of Report --

LABORATORY TECHNICIAN

Note: This Report is not for medicolegal purpose

Dr. Dhananjay Prasad
MBBS, MD (Pathologist)

Near Railway Under Bridge, Basant Vihar Gate No. 1, Gondwara Chowk,
Gudhiyari, Raipur (Chhattisgarh)

☎ 0771-43 43 161, 0771-43 40 162, 📞 8404 8404 79

24x7



SHREE RAM MULTI SPECIALITY HOSPITAL

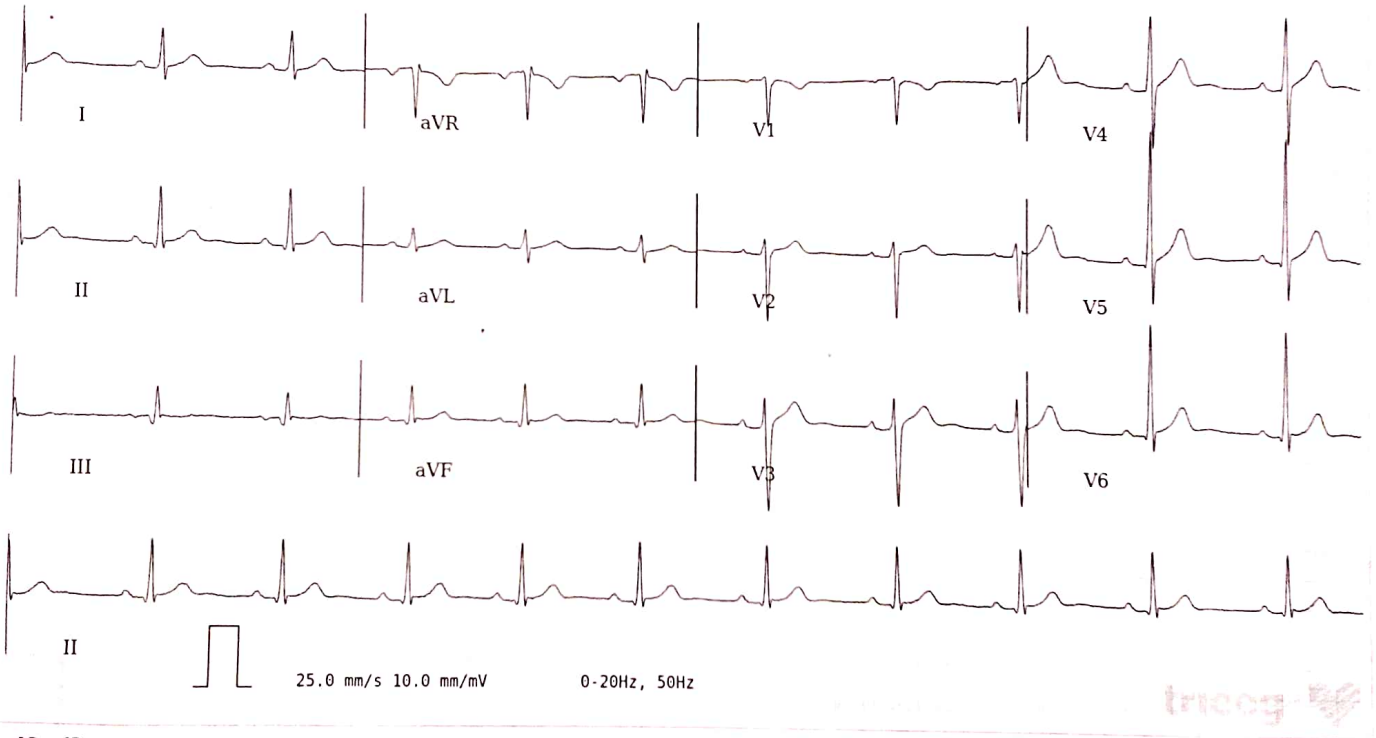


Age / Gender: 34/Male

Date and Time: 24th Aug 24 2:12 PM

Patient ID: 2408881

Patient Name: Mr bishnu prasad sa



AR: 67bpm

VR: 67bpm


QRSD: 92ms

QT: 358ms

QTcB: 378ms

PRI: 170ms

P-R-T: 30° 50° 34°



Disclaimer: Analysis in this report is based on ECG alone and should only be used as an adjunct to clinical history, symptoms and results of other invasive and non-invasive tests and must be interpreted by a qualified physician



Shree Ram Multispeciality Hospital (SRMH)

L o k a h S a m a s t a S u k h i n o B h a v a n t u

ECHOCARDIOGRAPHY REPORT

Name	Mr. Bishnu Prasad Sa	Age / Sex	34 years / Male
Date	24-08-2024	UHID no	2408881

PULMOANRY VELOCITY ; 0.66 m/s

AORTIC VELOCITY : 0.96 m/s

TRICUSPID VELOCITY : 1.56 m/s

PASP : 15 mmHg + RAP


M-Measurement Value

Aorta	2.6	LVEDD	4.4
LA	3.5	IVSD	0.9
LVEF	>60%	LVPWD	0.9

FINAL IMPRESSION

- Normal Cardiac Chambers & Dimension
- No RWMA
- Normal LV Systolic Function
- LVEF >60%
- Trace TR / MR, PASP 15 mmHg + RAP
- No Clot/PE / Vegetation

Dr. Nikhil Motiramani
(MBBS, MD,DM Card)


Dr. Ajay Halbai.
(MBBS, MD)

📍 Near Railway Under Bridge, Basant Vihar Gate No. 1, Gondwara Chowk,
Gudhiyari, Raipur (Chhattisgarh)

☎ 0771-43 43 161, 0771-43 40 162, 📞 8404 8404 79

✉ shreeramhospital@gmail.com





A Unit of Diagnostic Care with Trust

श्री साई इमेजिंग एंड डायग्नोस्टिक सेंटर

हर जीवन अमूल्य है



0771-4023900



MRI | CT Scan | 4D Color USG | Digital X-Ray | Advance Pathology | 2D Echo/E.C.G./TMT | E.E.G/OPG/SPIRO

DATE- 24-Aug-24

PATIENT NAME MR. BISHNU SA
AGE/SEX 34 YEAR / MALE
REF. BY SHREE RAM MULTISPECIALTY HOSPITAL

SONOGRAPHY OF THE ABDOMEN

PROCEDURE DONE BY ULTRASOUND MACHINE Canon Apilo a450 (4D COLOR DOPPLER)

LIVER : The liver is normal in size, shape & contour with raised echotexture. No evidence of any Focal lesion or mass seen. The intrahepatic biliary ducts are normal. The CBD is normal in course, caliber & contour. Hepatic & portal vein appear normal in morphology.

GALL BLADDER : Well distended & shows normal wall thickness. No obvious intraluminal calculus.

PANCREAS : It is normal echogenicities and size, shape. Pancreatic duct is normal.

SPLEEN : Spleen is normal size, shape and position. No focal lesion seen.

KIDNEY : Right kidney measures 10.1 x 3.8 cm.
Left kidney measures 9.1 x 3.9 cm.
Both Kidneys are normal size, shape and position.
Renal parenchymal echogenicities are normal.
No evidence of any calculus or pelvicalyceal dilation.

URINARY BLADDER: UB is well distended with normal wall thickness. No evidence of mass /calculus.

PROSTATE : It is normal in size, shape & smooth outlines.


RETRO PERITONEUM : No evidence of lymphadenopathy / mass.

FREE FLUID : No free fluid seen in abdomen & peritoneal cavity.

IMPRESSION:

- Fatty liver Grade- I
- Rest no significant abnormality detected

Needs clinical correlation & other investigations.


DR. Yatendra Nath Singh
DMRD, DNB, EDiR
Consultant Radiologist

Investigations have their limitation, solitary radiological / pathological and other investigations never confirm the final diagnosis of disease. They only help in diagnosing the disease in correlation to symptom and other related test please interpret accordingly.

Kindly Note:-

- The report and films are not valid for medico – legal purpose.
- Please Intimate us if any typing mistakes and send the report for correction within 7 days.
- कृपया अगली बार जांच के लिए आने पर पुराना रिपोर्ट साथ में लावे ।

पुराना धमतरी रोड, सब्जी बाजार के सामने, संतोषी नगर, रायपुर (छ.ग.)

सही जाँच ही सही ईलाज का आधार है...

Email : shrisaiimaging@gmail.com, Website : www.shrisaidiagnostic.com



Shree Ram Multispeciality Hospital (SRMH)

L o k a h S a m a s t a S u k h i n o B h a v a n t u

Department of Radiology

NAME -; Mr. Bishnu Prasad Sa	AGE - 34 YEAR /M
REF.BY -; SHREE RAM MULTI SPECIALITY HOSPITAL	DATE - 24/08/2024

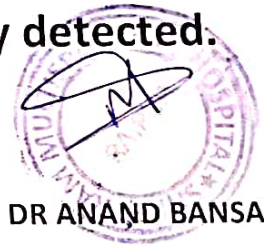
X – RAY CHEST PA VIEW.

FINDINGS:

- Bilateral lung parenchyma is clear.
- Both apices free.
- Trachea in mid line.
- C T ratio within normal limits.
- Both hila are normal.
- Both costo & cardiophrenic angles are clear.
- Bony cage normal.
- Soft tissue appears normal.

IMPRESSION :

No significant abnormality detected.



DR ANAND BANSAL

MD DNB RADIODIAGNOSIS

CONSULTANT RADIOLOGIST

CGMC 2015/6359

📍 Near Railway Under Bridge, Basant Vihar Gate No. 1, Gondwara Chowk,
Gudhiyari, Raipur (Chhattisgarh)

☎ 0771-43 43 161, 0771-43 40 162, 📞 8404 8404 79

✉ shreeramhospital.op@gmail.com 🌐 www.srmhraipur.com



HRI SAI ADVANCE IMAGING & DAIGNOSTIC CENTER, SANTOSHI NAGA R

24 Aug 2024 Study : Abdomen
Name : BISHNU 34M

