

# SENTINI HOSPITALS

D.No:54-15-5, B&C, Beside Vinayaka Theatre,  
Ring Road, Vijayawada - 520 008.Ph:0866-6677869

## DEPARTMENT OF BIOCHEMISTRY

Name	: Mrs. MONICA CLARA .MANDADI	Age /Sex	: 33 Y(s)/Female
Bill Date	: 24-Aug-2024 08:58 AM	UMR No.	: UMR2410856
Rept. Dt	: 24-Aug-2024 11:51 AM	Bill No.	: BIL24017263
Ref By	: Dr.GENERAL HEALTH CHECK UP	Result No	: 0 / RES24016654

<u>Parameter</u>	<u>Result</u>	<u>Normal Values</u>
Fasting Blood Sugar	: 102 mg/dl	70 - 110 mg/dl
HB A1C	: 5.0 %	Non Diabetic : < 6.0 % Good Control : 6.0 - 7.5 % Fair control : 7.5 - 8.5 % Poor Control : > 8.5 %
Post Prandial Blood Sugar	: 125 mg/dl	80 - 199 mg/dl
RFT (RENAL FUNCTION TEST)		
BLOOD UREA	: 27 mg/dl	13 - 45 mg/dl
Serum Creatinine	: 0.7 mg/dl	0.7 - 1.4 mg/dl
TFT (THYROID FUNCTION TEST)		
T3 (TRI IODO THYRONINE)	: 149 ng/dl	80 - 200 ng/dl
T4 (THYROXINE)	: 8.6 ug/dl	5.1 - 14.1 ug/dl
TSH (THYROID STIMULATING HORMONE)	: 0.8 mIU/l	0.3 - 4.2 mIU/l
LIPID PROFILE		
Fasting Blood Sugar	: 102 mg/dl	70 - 110 mg/dl
Total Cholesterol	: 160 mg/dl	150 - 240 mg/dl
Triglycerides	: 91 mg/dl	50 - 200 mg/dl
HDL Cholesterol	: 39 mg/dl	
LDL Cholesterol	: 103 mg/dl	80 - 160 mg/dl
VLDL	: 18 mg/dl	10 - 50 mg/dl
Cholesterol / HDL ratio	: 4.1	< 6
LDL / HDL	: 2.6	< 4
LFT(LIVER FUNCTION TEST)		
Total Bilirubin	: 0.4 mg/dl	0.1 - 1.2 mg/dl
Direct Bilirubin	: 0.1 mg/dl	0.0 - 0.3 mg/dl
Indirect Bilirubin	: 0.3 mg/dl	
SGOT	: 27 IU/L	5 - 55 IU/L
SGPT	: 18 IU/L	5 - 55 IU/L
Alkaline Phosphatase	: 84 IU/L	Adult : 35 - 125 IU/L Children : 125 - 330 IU/L
Total Protein	: 7.8 gm/dl	6.0 - 8.3 gm/dl
Albumin	: 4.5 gm/dl	3.2 - 5.0 gm/dl
Globulin	: * 3.3 gm/dl	2.5 - 3.0 gm/dl

# SENTINI HOSPITALS

D.No:54-15-5, B&C, Beside Vinayaka Theatre,  
Ring Road, Vijayawada - 520 008.Ph:0866-6677869

## DEPARTMENT OF BIOCHEMISTRY

Name	: Mrs. MONICA CLARA .MANDADI	Age /Sex	: 33 Y(s)/Female
Bill Date	: 24-Aug-2024 08:58 AM	UMR No.	: UMR2410856
Rept. Dt	: 24-Aug-2024 11:51 AM	Bill No.	: BIL24017263
Ref By	: Dr.GENERAL HEALTH CHECK UP	Result No	: 0 / RES24016654

<u>Parameter</u>	<u>Result</u>	<u>Normal Values</u>
A / G RATIO	: * 1.3	1.51 - 1.81

\*\*\* End Of Report \*\*\*

Lab Tech.

Bio-Chemist

Lab In-Charge

Consultant Pathologist

Correlate Clinically

We use only sterilised disposable syringes & needles.

This report is to help you for better management of patient and not valid for medicolegal purpose.  
Discrepancies due to technical or typing errors should be reported within 3 days for correction.

# SENTINI HOSPITALS

D.No: 54-15-5, B&C, Beside Vinayaka Theatre,  
Ring Road, Vijayawada - 520 008.Ph:0866-6677869

## DEPARTMENT OF HAEMATOLOGY

Name	: Mrs. MONICA CLARA .MANDADI	Age /Sex	: 33 Y(s)/Female
Bill Date	: 24-Aug-2024 08:58 AM	UMR No.	: UMR2410856
Rept. Dt	: 24-Aug-2024 11:51 AM	Bill No.	: BIL24017263
Ref By	: Dr.GENERAL HEALTH CHECK UP	Result No	: 0 / RES24016654

<u>Parameter</u>	<u>Results</u>	<u>Normal Values</u>
ESR	: 30 mm/1hour	0 - 15 mm/1hour
CBC (COMPLETE BLOOD COUNT)		
HAEMOGLOBIN	: 13.7 g/dl	11.5 - 16.0 g/dl
Total WBC Count	: 7,800 cells/cumm	4000 - 11000 cells/cumm
DC COUNT		
Neutrophils	: 59 %	50 - 70 %
Lymphocytes	: 37 %	15 - 40 %
Eosinophils	: 02 %	0 - 7 %
Monocytes	: 02 %	0 - 4 %
Basophils	: 00 %	0 - 1 %
RBC COUNT	: 4.8 millions/cumm	4.5 - 6.5 millions/cumm
PLATELET COUNT	: 3.0 lakhscells/cumm	1.5 - 4.0 lakhscells/cumm

\*\*\* End Of Report \*\*\*

Lab Tech.

Bio-Chemist

Lab In-Charge

Consultant Pathologist

Correlate Clinically, We use only sterilised disposable syringes & needles.

Discrepancies due to technical or typing errors should be reported within 3 days for correction.

This report is to help you for better management of patient and not valid for medicolegal purpose.

# SENTINI HOSPITALS

D.No: 54-15-5, B&C, Beside Vinayaka Theatre,  
Ring Road, Vijayawada - 520 008.Ph:0866-6677869

## DEPARTMENT OF PATHOLOGY

Name	: Mrs. MONICA CLARA .MANDADI	Age /Sex	: 33 Y(s)/Female
Bill Date	: 24-Aug-2024 08:58 AM	UMR No.	: UMR2410856
Rept. Dt	: 24-Aug-2024 11:51 AM	Bill No.	: BIL24017263
Ref By	: Dr.GENERAL HEALTH CHECK UP	Result No	: 0 / RES24016654

<u>Parameter</u>	<u>Result</u>	<u>Normal Values</u>
URINE ROUTINE EXAMINATION		
Sugar	: Nil	
Albumin	: Nil	
Microscopic Examination		
Pus cells	: 2-4 /HPF	
Epithelial cells	: 6-8 /HPF	
RBC	: Absent /HPF	

\*\*\* End Of Report \*\*\*

Lab Tech.

Bio-Chemist

Lab In-Charge

Dr. K.MADHAVI, MD PATHOI  
CONSULTANT PATHOLOGIS

Correlate Clinically, We use only sterilised disposable syringes & needles.

Discrepancies due to technical or typing errors should be reported within 3 days for correction.

This report is to help you for better management of patient and not valid for medicolegal purpose.

# SENTINI HOSPITALS

D.No: 54-15-5, B&C, Beside Vinayaka Theatre,  
Ring Road, Vijayawada - 520 008.Ph:0866-6677869

## DEPARTMENT OF SEROLOGY

Name	: Mrs. MONICA CLARA .MANDADI	Age /Sex	: 33 Y(s)/Female
Bill Date	: 24-Aug-2024 08:58 AM	UMR No.	: UMR2410856
Rept. Dt	: 24-Aug-2024 11:51 AM	Bill No.	: BIL24017263
Ref By	: Dr.GENERAL HEALTH CHECK UP	Result No	: 0 / RES24016654

Blood Grouping & Rh Typing : "O" POSITIVE

\*\*\* End Of Report \*\*\*

Lab Tech.

Bio-Chemist

Lab In-Charge

Consultant Pathologist



MONICA CLARA MANDADI

Date:24/08/2024

UMR : 2410856

Age/Sex: 33Y/F

Ref : GENERAL

**REAL TIME ULTRASONOGRAPHY OF THE ABDOMEN**

- LIVER:** Normal in size, shape and outline. Parenchymal echotexture normal. No focal cystic or solid mass lesion. No intrahepatic biliary dilatation. Intrahepatic portion of IVC is normal.  
Portal vein is normal. Porta hepatis is normal.
- G. B:** Partially distended. No obvious calculus to the visualized extent, advised review scan with fasting if detailed evaluation required.
- C.B.D:** Not dilated.
- PANCREAS:** Parenchymal echotexture normal. No ductal dilatation. No calculi.
- SPLEEN:** Normal in size & echotexture.
- KIDNEYS:** **Right kidney** measures 9.0 x 4.2cm .  
Normal in size, shape and outline. Parenchymal echotexture normal.  
Corticomedullary differentiation is well made out and is normal.  
No evidence of calculi/ Hydronephrosis.
- Left kidney** measures 9.5 x 4.3cm  
Normal in size, shape and outline. Parenchymal echotexture normal.  
Corticomedullary differentiation is well made out and is normal.  
No evidence of calculi / Hydronephrosis.
- URINARY BLADDER :** Normal wall thickness; No calculus /mass.
- UTERUS** : **Retroverted.** Normal in size & echotexture.  
No focal lesions in myometrium.  
Endometrial thickness: normal
- OVARIES** : Normal in size and echotexture. No Adnexal cysts noted.  
\* No evidence of free fluid / lymphadenopathy.

**IMPRESSION:**

- **NO SIGNIFICANT ABNORMALITY.**

- For clinical correlation & follow up.

**[Consultant Radiologist]**

SENTINI HOSPITAL, VIJAYAWADA

2024 08 18 22:37

Name:

Sex:

Section: Cardiology I I I I

Room ID:

Bed ID:

ID:

Operator:

Custom1:

Custom2:

Custom3:

Age:

33 years

Microalbuminuria

Data for reference only:

HR bpm : 98

PR Interval ms : 155

P Duration ms : 96

QRS Duration ms : 63

T Duration ms : 203

QT/QTc ms : 316/403

P/QRS/T Axis deg : 53.6/0.4/26.8

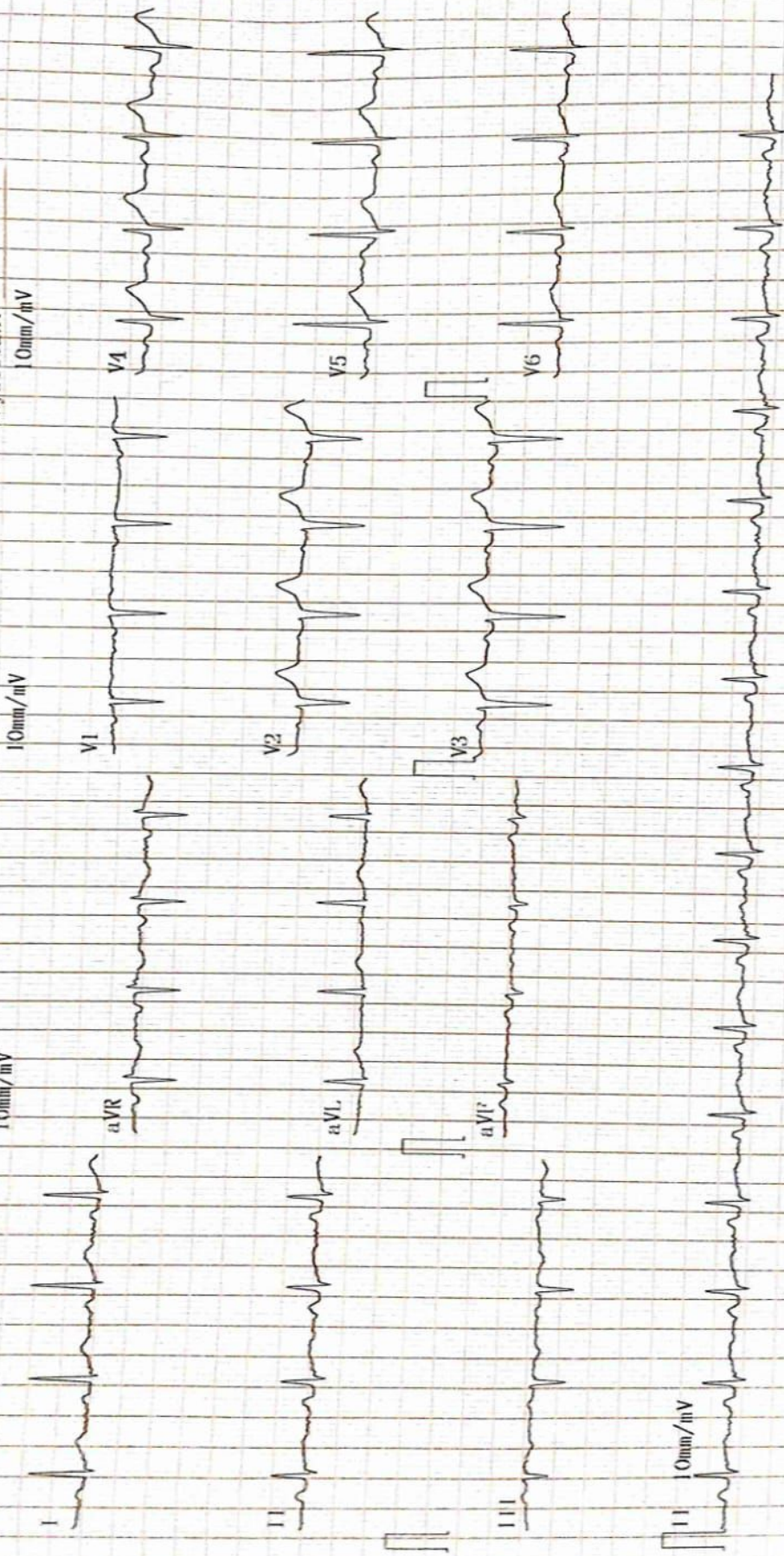
R(V5)/S(V1) mV : 1.14/0.85

R(V5) S(V1) mV : 1.99

AUTO 10mm/mV

10mm/mV

Physician: 10mm/mV



<< Conclusions >>

Normal Sinus Rhythm  
Longitudinal Left axis deviation.

\*\*Report need physician confirm\*\*



# Sentini Hospitals (P) Limited

Cardiology Department

## ECHOCARDIOGRAM REPORTS

Name : M. Monica Clara	UMR/OP/IP No	: 2410856
Age : 33 Years	Sex	: Female
Date : 24/08/2024	Echo No	: 592
Technician: Praveen		

MITRAL VALVE : Normal  
AORTIC VALVE : Normal  
TRICUSPID VALVE : Normal  
PULMONARY VALVE : Normal  
AORTA : 28 mm  
LEFT ATRIUM : 29 mm  
LEFT VENTRICLE : Normal  
RWMA : No LV RWMA  
IVS : 12 mm LV IDd : 40 mm  
PW : 12 mm LVIDs : 26 mm  
LV EF : 60 %  
RIGHT ATRIUM : Normal  
RIGHT VENTRICLE : Normal  
PULMONARY ARTERY : Normal  
PULMONARY VEINS : Normal  
IAS : Intact  
IVS : Intact  
PERICARDIUM : Normal  
PERICARDIAL EFFUSION : No Effusion

### DOPPLER STUDY

MITRAL FLOW : E>A  
TRICUSPID FLOW : TRJV- m/s TR Gr : mmHg RVSP: mmHg  
AORTIC JET VELOCITY : 1.1 m/s AV Gr: mmHg  
PULMONARY JET VELOCITY : 0.9 m/s  
COLOUR DOPPLER : MR TR AR No PR  
IVC : Normal  
SVC : Normal  
OTHERS :  
CONCLUSION :

**Normal Sized cardiac Chambers**  
**No LV RWMA**  
**No MR/AR/TR/No PAH**  
**Normal LV systolic function**  
**No PE /No Clot**

DR RAGHURAM MD.DM  
SENIOR INTERVENTIONAL CARDIOLOGIST

DR K. KRISHNA CHAND MD.DNB  
SENIOR INTERVENTIONAL CARDIOLOGIST