



Patient Name : Mr. VIRENDRA RAOKHANDE

Age/Gender : 42 Y/M

UHID/MR No. : CKHA.0000072653

OP Visit No : CKHAOPV111258

Sample Collected on :

Reported on : 25-03-2024 14:46

LRN# : RAD2279268

Specimen :

Ref Doctor : SELF

Emp/Auth/TPA ID : bobE14758

DEPARTMENT OF RADIOLOGY

ULTRASOUND - WHOLE ABDOMEN

Dr. HARSHAD JAGTAP
MBBS,DMRD,DNB
Radiology


CERTIFICATE OF MEDICAL FITNESS

This is to certify that I have conducted the clinical examination

of virendra Raskhande on 25/03/24

After reviewing the medical history and on clinical examination it has been found that he/she is

	Tick
<ul style="list-style-type: none"> Medically Fit 	✓
<ul style="list-style-type: none"> Fit with restrictions/recommendations <p>Though following restrictions have been revealed, in my opinion, these are not impediments to the job.</p> <p>1. Glucose Fasting - 204 ↑ PP ↑ (319) Glucosuria.</p> <p>2. Dyslipidemia</p> <p>3. vit. D ↓ vit B12 ↓</p> <p>Grade - 2 Fatty liver.</p> <p>However the employee should follow the advice/medication that has been communicated to him/her.</p> <p>Review after _____</p>	
<ul style="list-style-type: none"> Currently Unfit. <p>Review after: _____ recommended</p>	
<ul style="list-style-type: none"> Unfit 	


Dr. Zuha Khan
 Dr. MBBS General Physician
 Medical Officer: 2020/03/1804
 Apollo Clinic, Kharadi

This certificate is not meant for medico-legal purposes

Apollo Health and Lifestyle Limited

(CIN - U85110TG2000PLC115819)

Regd. Office: 1-10-60/62, Ashoka Raghupathi Chambers, 5th Floor, Begumpet, Hyderabad, Telangana - 500 016.

Ph No: 040-4904 7777, Fax No: 4904 7744 | Email ID: enquiry@apollohl.com | www.apollohl.com

APOLLO CLINICS NETWORK MAHARASHTRA

Pune (Aundh | Kharadi | Nigdi Pradhikaran | Viman Nagar | Wanowrie)

Online appointments: www.apolloclinic.com

TO BOOK AN APPOINTMENT

 **1860 500 7788**

Date : 23-03-2024
 MR NO : CKHA.0000072653
 Name : Mr. VIRENDRA RAO KHANDE
 Age/ Gender : 42 Y / Male
 Department : GENERAL
 Doctor :
 Registration No :
 Qualification :

Consultation Timing: 10:45	Weight: 85.1	BMI: 29	Waist Circum: 102
Height: 168	Pulse: 82	Resp: 20	B.P: 124/83
Temp: 97.5 F			

General Examination / Allergies History

Clinical Diagnosis & Management Plan

Present complains - Nil complains
 Comorbidity - K/C/O - DM - Not compliant
 Allergies - } NO.
 Surgical H/O }
 Family H/O - Uncle / Father - DM
 Addiction - NO
 OE
 CVS- }
 CNS- }
 P/A- } NAD
 Chest- }
 H/O covid infection - Yes - 2021
 Vaccinated with - 2 vaccine + 1 Booster.

Follow up date:

Phan
 Doctor Signature

POWER PRESCRIPTION

NAME: *Mrs Viswendra Raokhande* GENDER: *M/F* DATE: *23-3-24*
 AGE: *42* UHID: *72653*

RIGHT EYE

LEFT EYE

	SPH	CYL	AXIS	VISION
DISTANCE	<i>-0.50</i>	<i>.</i>	<i>.</i>	<i>6/6</i>
NEAR				

	SPH	CYL	AXIS	VISION
DISTANCE	<i>-0.50</i>	<i>.</i>	<i>.</i>	<i>6/6</i>
NEAR				

INSTRUCTIONS:

SIGNATURE 

ID: 72653

virendra raokhande

Male 42Years

kg / mmHg

Req. No. : 72653

23-03-2024 16:45:13

HR : 89 bpm

P : 114 ms

PR : 142 ms

QRS : 96 ms

QT/QTcBz : 362/441 ms

P/QRS/T : 51/26/45 °

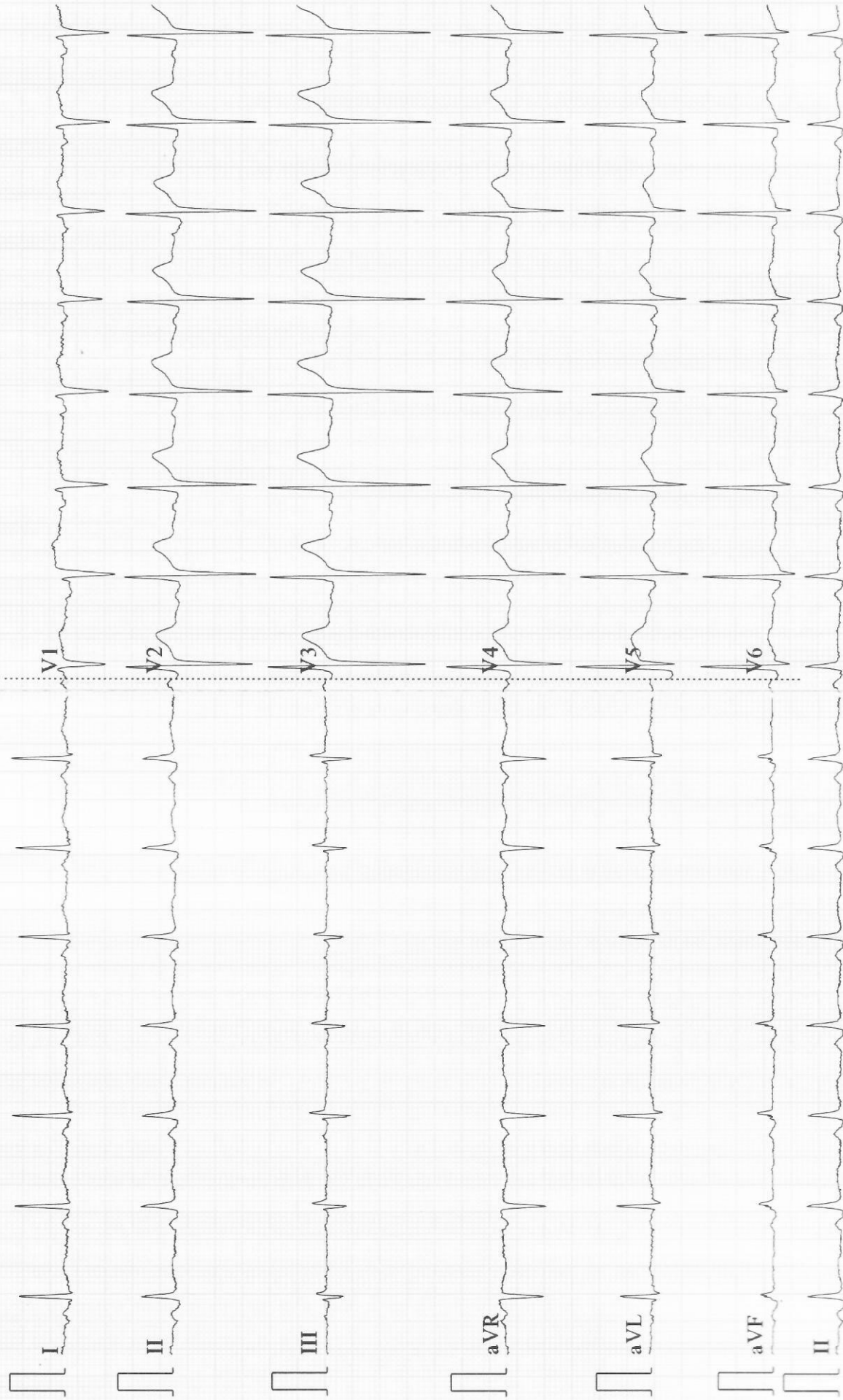
RV5/SV1 : 1.322/0.809 mV

Diagnosis Information:

Sinus rhythm

Normal ECG

Report Confirmed by:



Patient Name : Mr. VIRENDRA RAOKHANDE Age : 42 Y M
UHID : CKHA.0000072653 OP Visit No : CKHAOPV111258
Reported on : 24-03-2024 09:41 Printed on : 24-03-2024 09:51
Adm/Consult Doctor : Ref Doctor : SELF

DEPARTMENT OF RADIOLOGY

X-RAY CHEST PA

Both lung fields and hila are normal .

No obvious active pleuro-parenchymal lesion seen .

Both costophrenic and cardiophrenic angles are clear .

Both diaphragms are normal in position and contour .

Thoracic wall and soft tissues appear normal.

CONCLUSION :

No obvious abnormality seen

Printed on:24-03-2024 09:41

---End of the Report---



Dr. SANKET KASLIWAL
MBBS DMRE
Radiology

Patient Name : VIRENDRA RAO KHANDE.

Date : 23/03/2024

Referred By : Apollo Clinics.

Age : 42 yrs. Sex : M.

USG – Abdomen & pelvis

Clinical Profile : Routine check up.

Findings:

Liver appears normal in size, shape and **shows grade II fatty changes**. No focal mass lesions seen. Intrahepatic biliary radicals and veins are normal.

GB is well distended and appears normal. No calculi are noted. Gall bladder wall is normal. CBD and PV are normal.

Pancreas is normal in size, shape and echotexture. No focal mass lesion seen. Pancreatic duct is normal.

Spleen is normal in size, shape and echotexture. No focal mass lesion seen.

Right kidney is normal in size, shape and echotexture. It measures 12.4 x 4.9 cm in size. No evidence of calculus / hydronephrosis is seen. Cortical thickness is normal. CMD is well maintained.

Left kidney is normal in size, shape and echotexture. It measures 12.0 x 5.8 cm in size. No evidence of calculus / hydronephrosis is seen. Cortical thickness is normal. CMD is well maintained.

No ascites. No para-aortic lymphadenopathy.

Bladder is well distended and normal in outline. Bladder wall is normal.

Prostate appears normal in size and texture.

Impression:

> **Grade II fatty liver.**


> Rest of the USG of the abdomen and pelvis does not reveal any significant abnormality. Suggest- Clinico- Lab correlation.

This report is a professional opinion based on real time imaging findings and not a diagnosis by itself. Its has to correlated and interpreted with clinical and other investigations findings. Kindly bring the previous sonography reports for reference.

Dr. Harshad V. Jagtap
DMRD, DNB (Radiodiagnosis)

Thanks for the referral

Bank of Baroda

 **बैंक ऑफ बड़ोदा**
Bank of Baroda

नाम
Name: **Virendra G Raokhande**

ए.सी. नंबर
E.C.No.: **97352**

अधिकारी अधिकृत
Residing Authority
Chief Manager (अधीन)
Rural Zone






होल्डर का हस्ताक्षर
Signature of Holder

SUGGESTIVE LIST OF MEDICAL TESTS
LETTER OF APPROVAL / RECOMMENDATION

To,

The Coordinator,
Mediwheel (Arcofemi Healthcare Limited)
Helpline number: 011- 41195959

Dear Sir / Madam,

Sub: Annual Health Checkup for the employees of Bank of Baroda

This is to inform you that the following employee wishes to avail the facility of Cashless Annual Health Checkup provided by you in terms of our agreement.

PARTICULARS	EMPLOYEE DETAILS
NAME	MR. RAOKHANDE VIRENDRA GOKULDAS
EC NO.	97352
DESIGNATION	LEGAL
PLACE OF WORK	MUMBAI, SAMB
BIRTHDATE	18-12-1982
PROPOSED DATE OF HEALTH CHECKUP	23-03-2024
BOOKING REFERENCE NO.	23M97352100098946E

This letter of approval / recommendation is valid if submitted along with copy of the Bank of Baroda employee id card. This approval is valid from **11-03-2024** till **31-03-2024**. The list of medical tests to be conducted is provided in the annexure to this letter. Please note that the said health checkup is a **cashless facility** as per our tie up arrangement. We request you to attend to the health checkup requirement of our employee and accord your top priority and best resources in this regard. The EC Number and the booking reference number as given in the above table shall be mentioned in the invoice, invariably.

We solicit your co-operation in this regard.

Yours faithfully,

Sd/-

Chief General Manager
HRM Department
Bank of Baroda

Patient Name : Mr. VIRENDRA RAOKHANDE

Age/Gender : 42 Y/M

UHID/MR No. : CKHA.0000072653

OP Visit No : CKHAOPV111258

Sample Collected on :

Reported on : 24-03-2024 09:41

LRN# : RAD2279268

Specimen :

Ref Doctor : SELF

Emp/Auth/TPA ID : bobE14758

DEPARTMENT OF RADIOLOGY

X-RAY CHEST PA

Both lung fields and hila are normal .

No obvious active pleuro-parenchymal lesion seen .


Both costophrenic and cardiophrenic angles are clear .

Both diaphragms are normal in position and contour .

Thoracic wall and soft tissues appear normal.

CONCLUSION :

No obvious abnormality seen



Dr. SANKET KASLIWAL
MBBS DMRE
Radiology