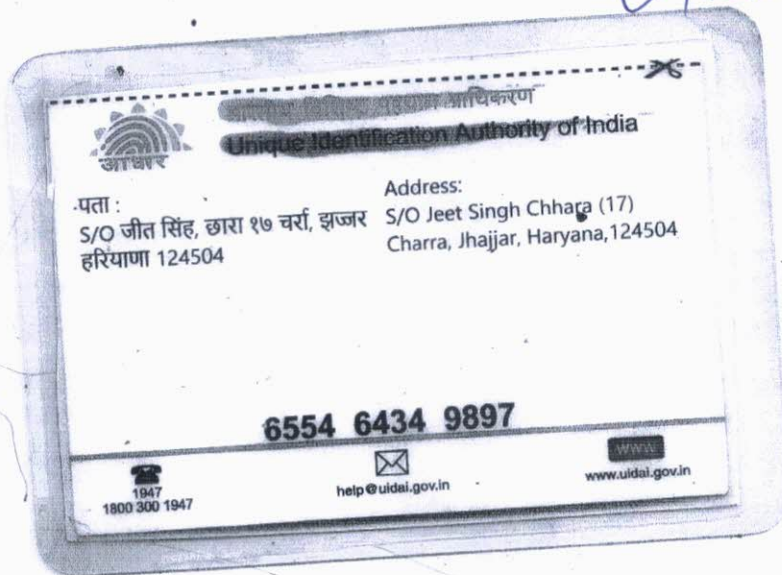







Dr. NITIN AGARWAL
MBBS, MD
Regn. No. DMC-R-1436

SACHIN
5/4/24
for one plus
ultrasound



ONEPLUS ULTRASOUND LAB
47 Harsh Vihar, Pitam Pura,
Delhi-110034
Ph. 011-42480101, 9599913051
E-mail oneplusul@gmail.com




DR. NITIN AGARWAL
 MBBS, MD
 Regn. No. DMC-R-1496

SA CH W
 5/4/24
 for One Plus
 ultrasound

ONEPLUS ULTRASOUND LAB
 47 Harsh Vihar, Pitam Pura,
 Delhi-110034
 Ph. 011-42480101, 9599913051
 E-mail onenplusul@gmail.com

ONEPLUS ULTRASOUND LAB

47, HARSH VIHAR, PITAMPURA, DELHI- 110034

Mr. SACHIN KUMAR
 Age : 40M
 Ref. by : MED/WH/EEI
 Indication 1 :
 Medication 2 :
 Indications 3 :
 COMMENTS :

ID : 2545
 H/Wt : 175/83
 Recorded : 5-4-2024 10:31
 Medication 1 :
 Medication 2 :
 Medication 3 :

BP : 86
 BP : 130/84
 P Axis : 76 deg
 QRS Axis : 72 deg
 T Axis : 72 deg

P duration : 100 msec
 PR duration : 143 msec
 QRS duration : 96 msec
 QT interval : 320 msec
 QTc interval : 365 msec

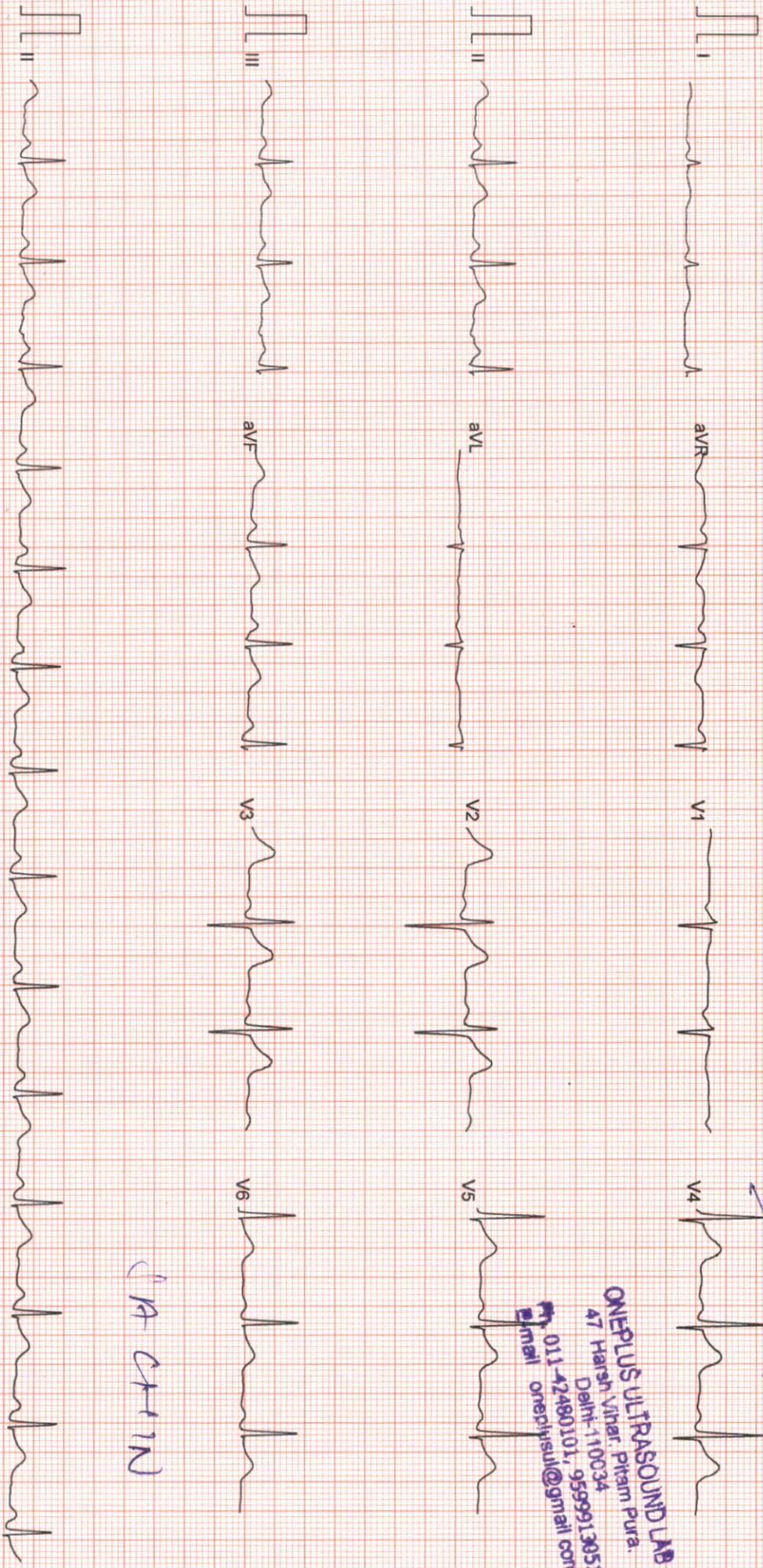
Unconfirmed Report Reviewed By:

Cardiologist

Dr. P. K. Gupta
 MBBS, MD
 Regd. No-1071

ONEPLUS ULTRASOUND LAB
 47 Harsh Vihar, Pitam Pura,
 Delhi-110034
 Phone: 011-42460101, 9599913051
 Email: oneplusul@gmail.com

Dr. CHIN



Filtered

25mm/sec 10mm/mV

CardiCom, INDIA

ONEPLUS ULTRASOUND LAB

47, HARSH VIHAR PITAMPURA DELHI 110034

Mr. SACHIN KUMAR
 Age/Sex : 40/M
 Ref. by : MEDIWHEEL
 Indication1 :
 Indication2 :
 Indication3 :

ID : 983
 H/Wt : 175/83
 Recorded : 5-4-2024 10:34

TREADMILL TEST SUMMARY REPORT
 Protocol: BRUCE
 History:

Medication1 :
 Medication2 :
 Medication3 :

PHASE	PHASE TIME	STAGE TIME	SPEED (Km./Hr.)	GRADE (%)	H.R. (BPM)	B.P. (mmHg)	RPP IX100	II	ST LEVEL (mm) V2	V5 f	METS
SUPINE											
STANDING											
HYPERVENT	0:03	0:03			80	130/84	104	1.2	2.4	1.7	
					81	130/84	105	1.4	2.4	1.7	
					93	130/84	120	1.4	2.1	1.7	
STAGE 1	2:59	2:59	2.70	10.00	103	130/84	133	1.1	2.5	1.6	4.80
STAGE 2	5:59	2:59	4.00	12.00	115	140/88	161	0.9	2.3	2.0	7.10
STAGE 3	8:59	2:59	5.40	14.00	139	140/88	194	1.0	2.8	1.7	10.00
STAGE 4	9:59	0:59	6.70	16.00	164	150/90	246	0.7	3.3	1.3	11.32
PEAK EXER	10:00	1:00			165	150/90	247	0.7	3.3	1.3	
RECOVERY	2:59	2:59	0.00	0.00	111	132/84	146	1.5	3.2	1.8	11.34

RESULTS

Exercise Duration : 10:00 Minutes
 Max Heart Rate : 165 bpm 91% of target heart rate 180 bpm
 Max Blood Pressure : 150/90 mmHg
 Max Work Load : 11.34 METS
 Reason of Termination :
 IMPRESSIONS :

Major for idable work

Dr. P.K. GUPTA
 MBBS, MD
 Reg. Cardiologist

ONEPLUS ULTRASOUND LAB
 47 Harsh Vihar Pitam Pure
 Delhi-110034
 Ph. 011-42480101, 9599913051
 E-mail oneplusuk@gmail.com

SACHIN
5/4/24

ONEPLUS ULTRASOUND LAB

SUPINE
PRETEST

ST @ 10mm/mV
80ms PostJ

MR. SACHIN KUMAR

I.D. : 983

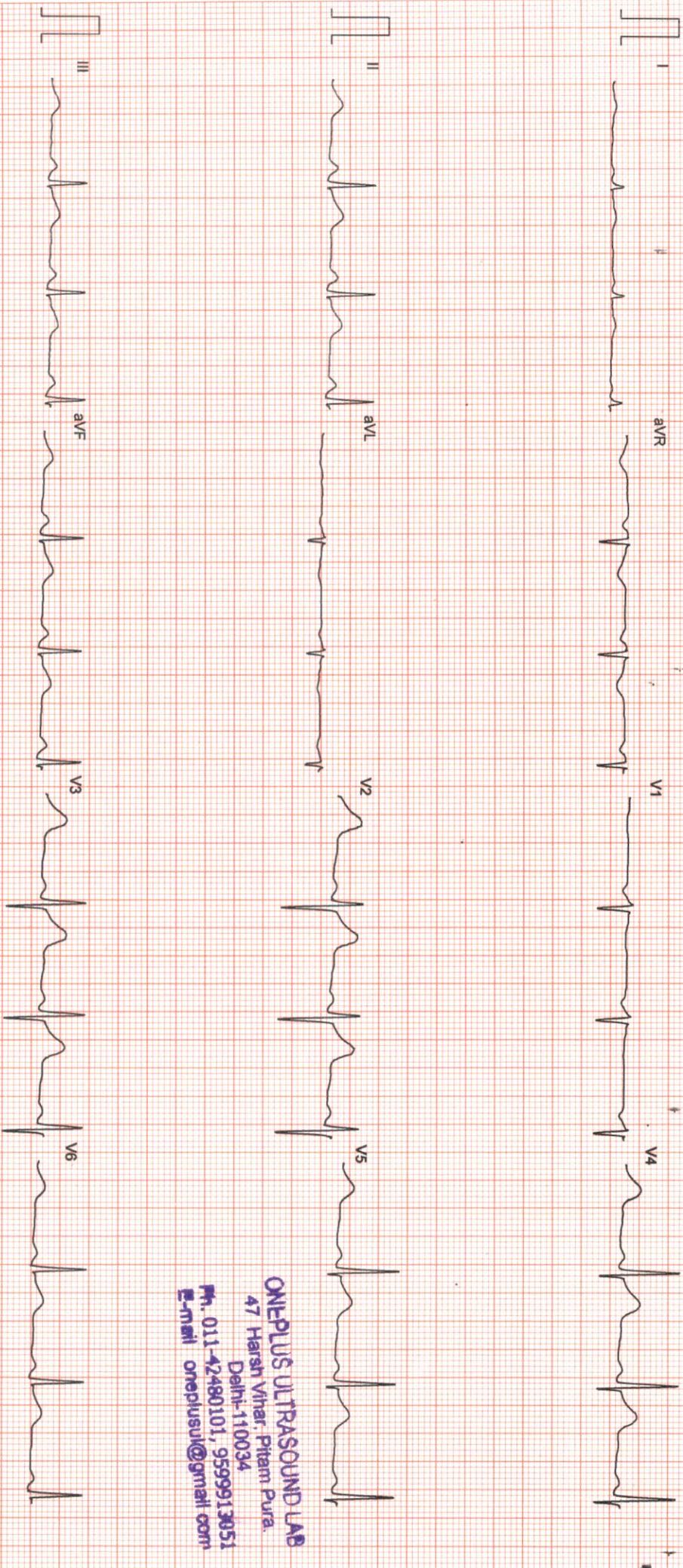
AGE/SEX : 40/M

RATE : 80 BPM

RECORDED : 5-4-2024 10:34

B.P. : 130/84 mmHg

RAW E.C.G.



ONEPLUS ULTRASOUND LAB
47 Harsh Vihar, Pitam Pura,
Delhi-110034
Ph. 011-42480101, 9599913051
E-mail onepiusul@gmail.com

8

Filtered

25mm/sec 10mm/mV

CardiCom, INDIA Ph.:091-731-2620740, TeleFax:091-731-2431214

ONEPLUS ULTRASOUND LAB

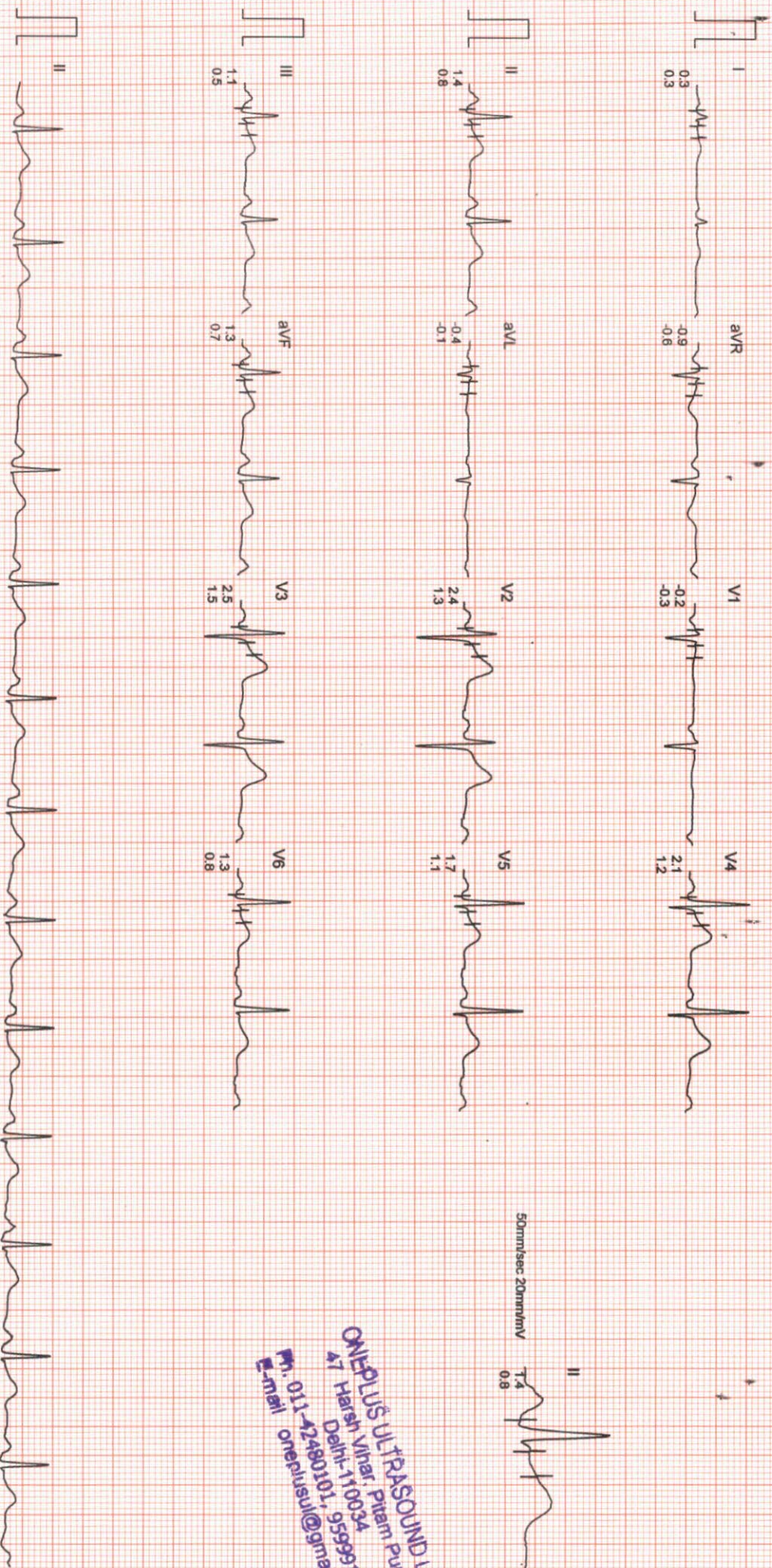
STANDING
PRETEST

ST @ 10mm/mV
80ms PostJ

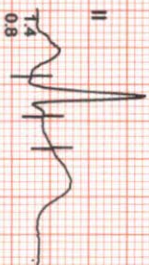
Mr. SACHIN KUMAR
I.D. : 983
AGE/SEX : 40/M
RECORDED : 5-4-2024 10:34

RATE : 81 BPM
B.P. : 130/84 mmHg

LINKED MEDIAN



50mm/sec 20mm/mV



ONEPLUS ULTRASOUND LAB
47 Harsh Vihar, Pitam Pura,
Delhi-110034
Ph. 011-2248010, 9555599613/3051
E-mail: oneplusul@gmail.com

Filtered

Computer Corrected Baseline

25mm/sec 10mm/mV

CardiCom, INDIA Ph.:091-731-2620740, TeleFax:091-731-2431214

ONEPLUS ULTRASOUND LAB

MR. SACHIN KUMAR
I.D. : 983

AGE/SEX : 40/M
RECORDED : 5-4-2024 10:34

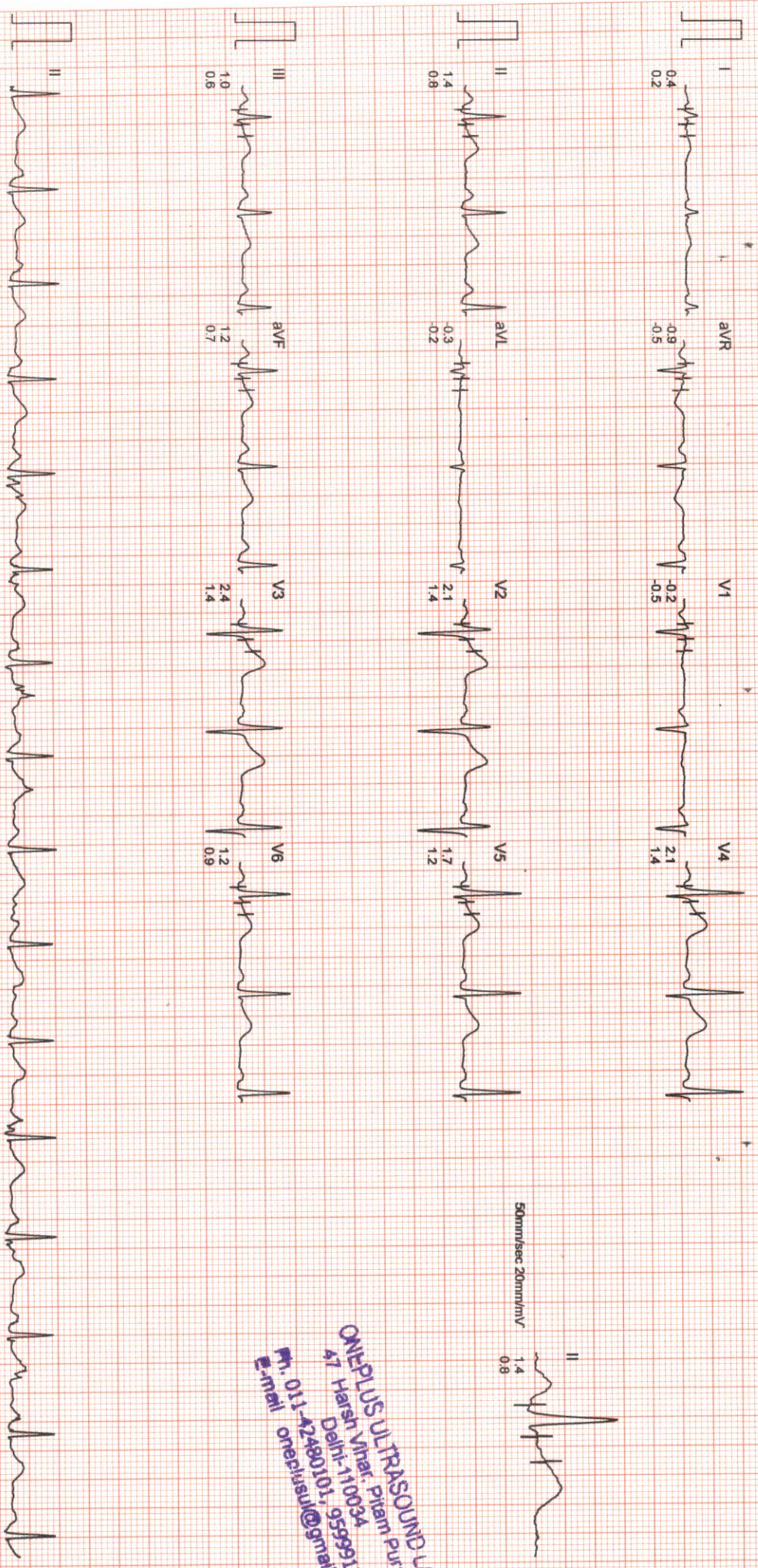
RATE : 93 BPM
B.P. : 130/84 mmHg

STAGE TIME : 0:03

HYPERVENTILATION
PRETEST

ST @ 10mm/mV
80ms PostJ

LINKED MEDIAN



ONEPLUS ULTRASOUND LAB
47 Harsit Vihar, Piam Pura,
Delhi-110024
Ph. 011-42480101, 95599913051
E-mail: oneplusul@5mail.com

ONEPLUS ULTRASOUND LAB

Mr. SACHIN KUMAR

ID : 983

AGE/SEX : 40M

RECORDED : 5-4-2024 10:34

RATE : 103 BPM
B.P. : 130/84 mmHg

BRUCE

EXERCISE 1

PHASE TIME : 2:59

STAGE TIME : 2:59

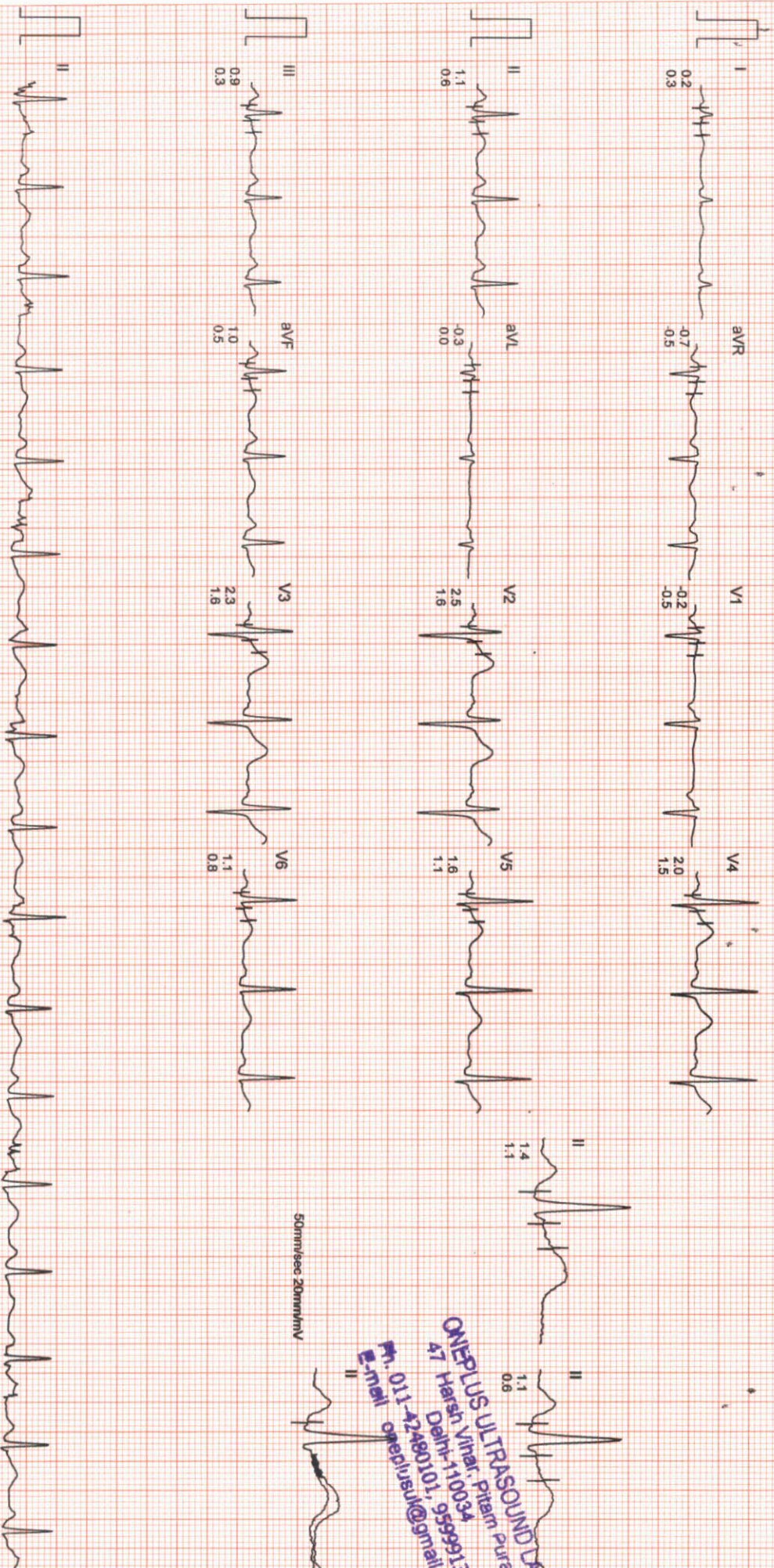
ST @ 10mm/mV

80ms PostJ

SPEED : 2.7 Km./Hr.

GRADE : 10.0 %

LINKED MEDIAN



ONEPLUS ULTRASOUND LAB
47 Harsh Vihar, Pitam Pura,
Delhi-110034
Ph. 011-22480101, 9559913851
E-mail onepplus@gmail.com

Filtered

Computer Corrected Baseline

25mm/sec 10mm/mV

CardiCom, INDIA Ph.:091-731-2620740, TeleFax:091-731-2431214

ONEPLUS ULTRASOUND LAB

MR. SACHIN KUMAR

I.D. : 983

AGE/SEX : 40/M

RECORDED : 5-4-2024 10:34

RATE : 115 BPM

B.P. : 140/88 mmHg

BRUCE
EXERCISE 2

PHASE TIME : 5:59

STAGE TIME : 2:59

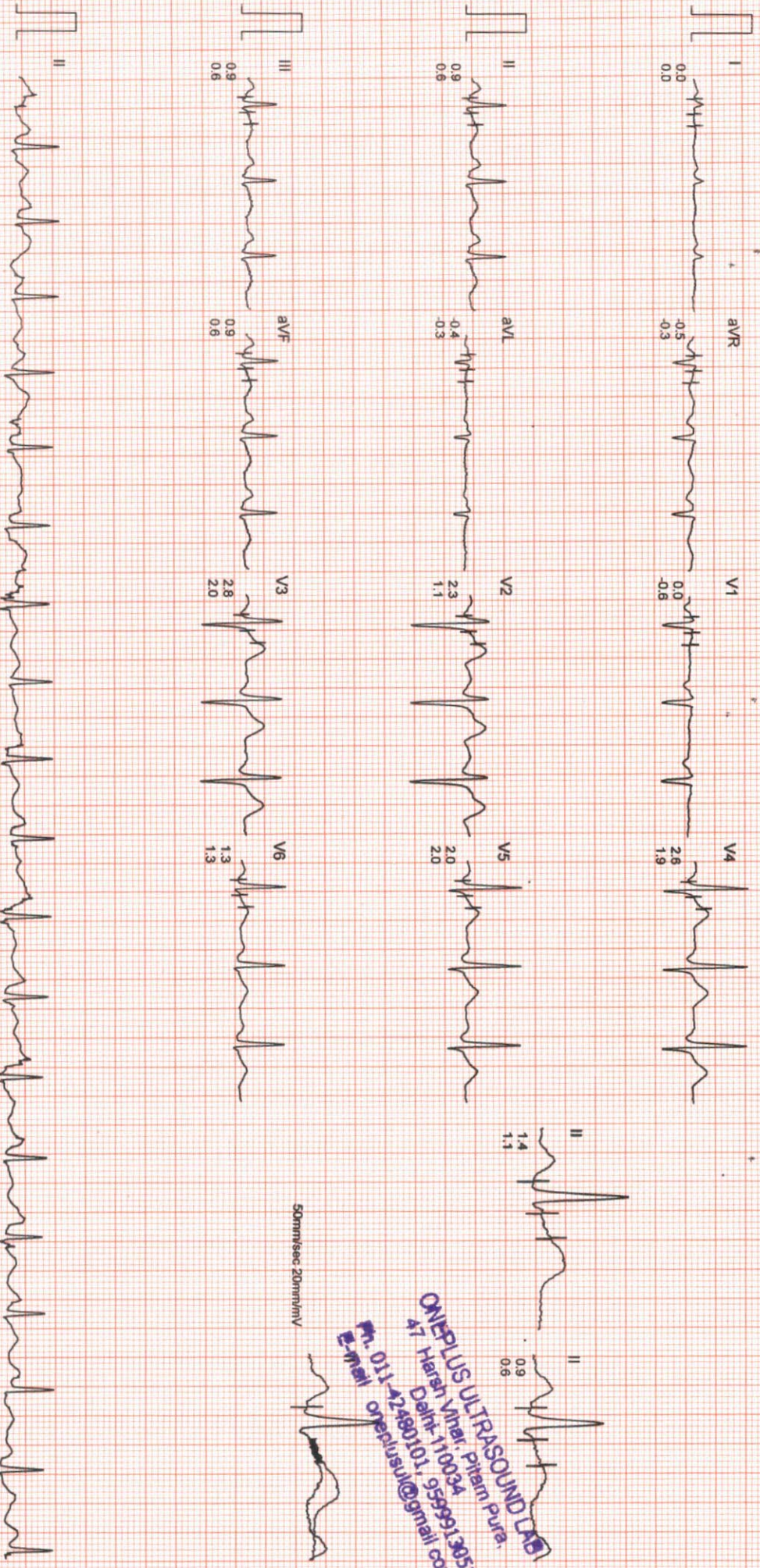
ST @ 10mm/mV

80ms PostJ

SPEED : 4.0 Km./Hr.

GRADE : 12.0 %

LINKED MEDIAN



50mm/Sec 20mm/mV

ONEPLUS ULTRASOUND LAB
47 Hariy Vihar, Pitam Pura,
Delhi-110034
Ph. 011-42480101, 9999913051
E-mail oneplusul@gmail.com

ONEPLUS ULTRASOUND LAB

Mr. SACHIN KUMAR

I.D. : 983

AGE/SEX : 40M

RECORDED : 5-4-2024 10:34

RATE : 139 BPM

B.P. : 140/88 mmHg

BRUCE

EXERCISE 3

PHASE TIME : 8:59

STAGE TIME : 2:59

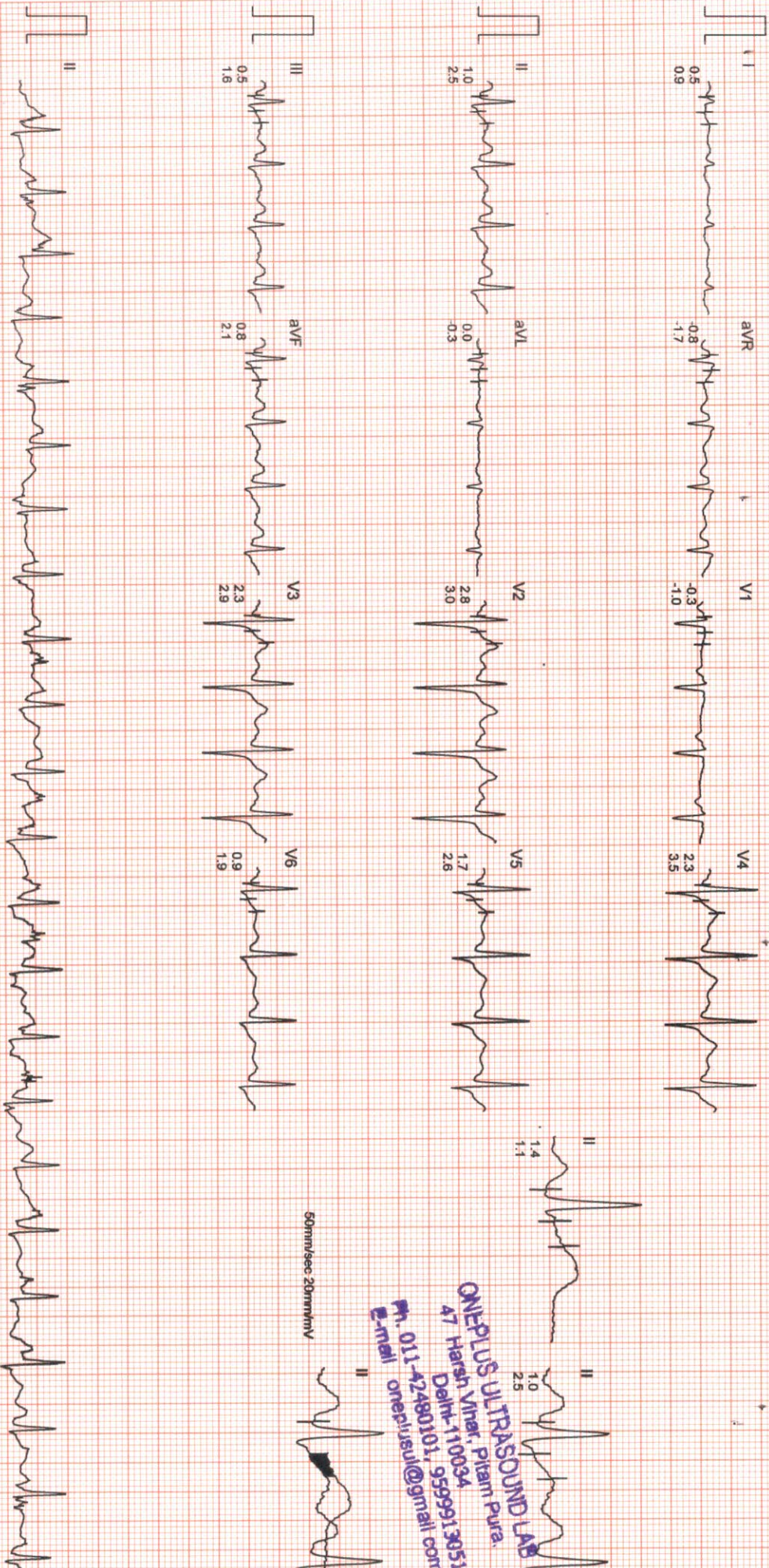
ST @ 10mm/mV

80ms PostJ

SPEED : 5.4 Km./Hr.

GRADE : 14.0 %

LINKED MEDIAN



ONEPLUS ULTRASOUND LAB
47 Harsh Vihar, Pitam Pura,
Delhi-110034
Ph. 011-42480101, 9599913051
E-mail oneplusul@gmail.com

ONEPLUS ULTRASOUND LAB

Mr. SACHIN KUMAR

I.D : 983

AGE/SEX : 40/M

RECORDED : 5-4-2024 10:34

RATE : 165 BPM

B.P : 150/90 mmHg

BRUCE
PEAK EXER

PHASE TIME : 10:00

STAGE TIME : 1:00

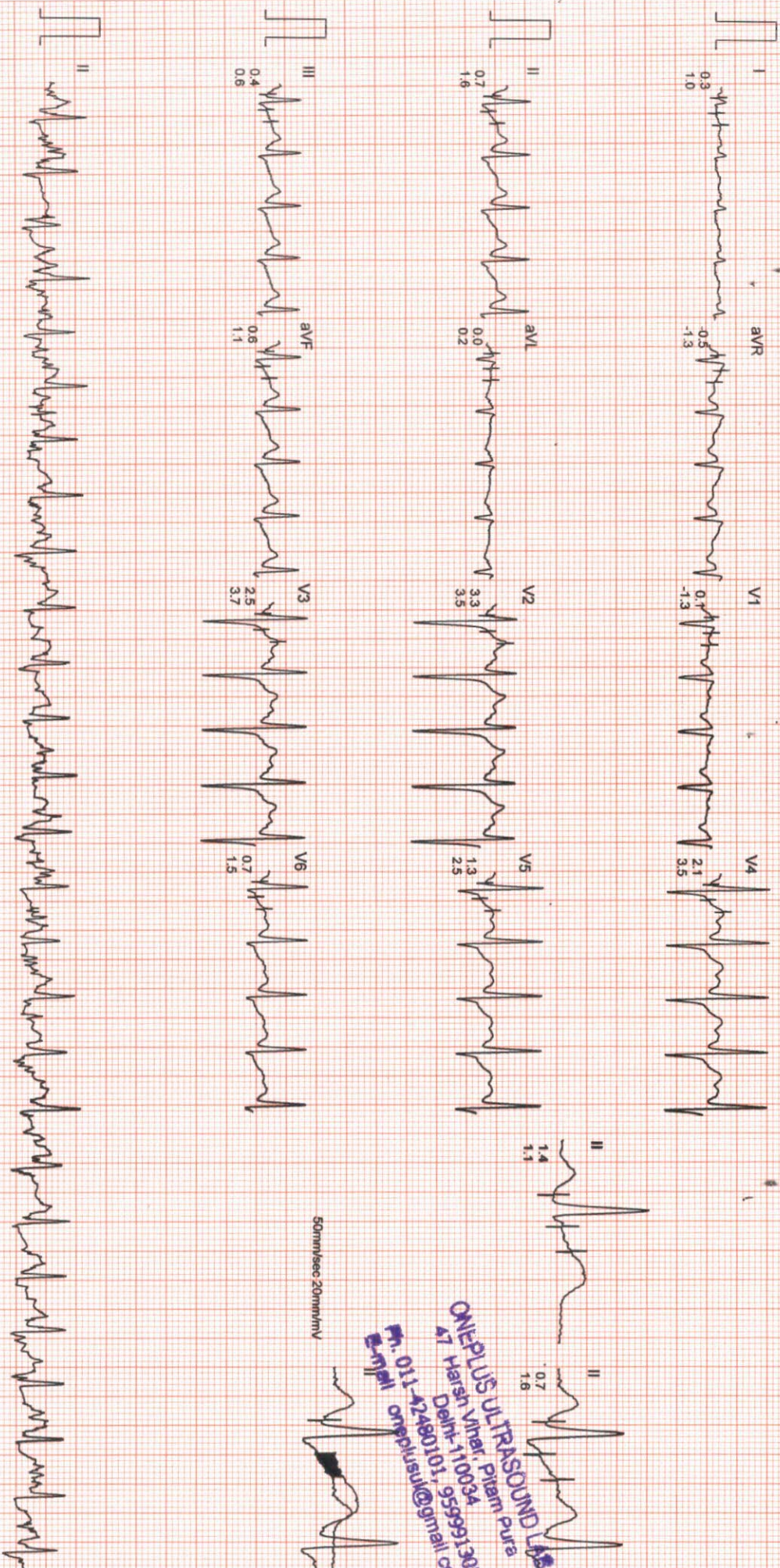
ST @ 10mm/mV

80ms PostJ

SPEED : 6.7 Km./Hr.

GRADE : 16.0 %

LINKED MEDIAN



ONEPLUS ULTRASOUND LAB
7 Harsh Vihar, Pitam Pura
Delhi-110034
Ph. 011-2480101, 99599913051
oneplusul@gmail.com

Filtered

Computer Corrected Baseline

25mm/sec 10mm/mV

CardiCom, INDIA Ph.:091-731-2620740, TeleFax:091-731-2431214

ONEPLUS ULTRASOUND LAB

Mr. SACHIN KUMAR

I.D. : 983

AGE/SEX : 40/M

RECORDED : 5-4-2024 10:34

RATE : 111 BPM
B.P : 132/84 mmHg

BRUCE

RECOVERY

PHASE TIME : 2:59

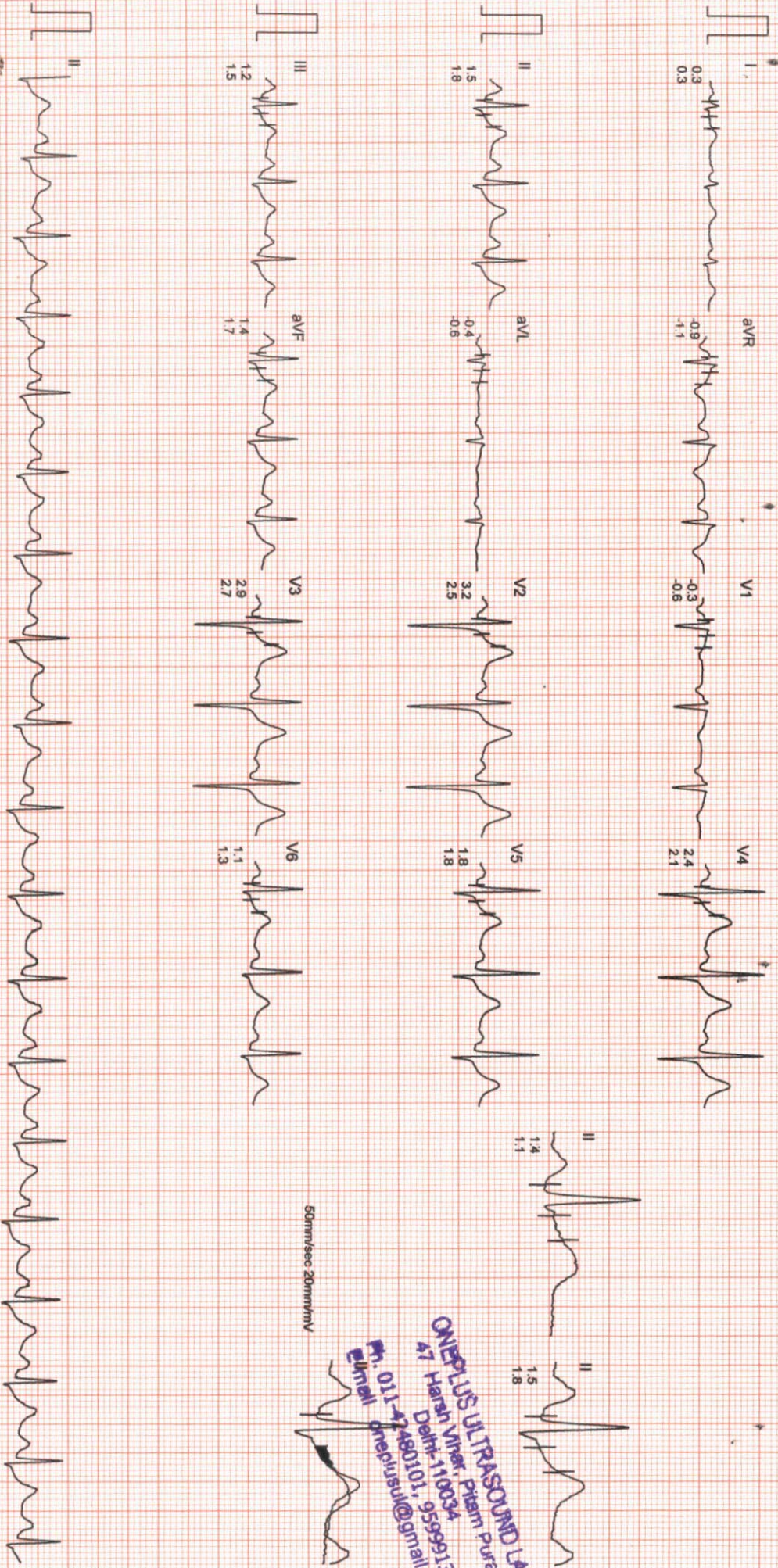
ST @ 10mm/mV

80ms PostJ

SPEED : 0.0 Km./Hr.

GRADE : 0.0 %

LINKED MEDIAN



50mm/sec 20mm/mV

ONEPLUS ULTRASOUND LAB
57 H Harsh Vihar, Pitam Pura
Delhi-110034
Ph. 011-2480101, 95599613051
Email: oneplusul@gmail.com

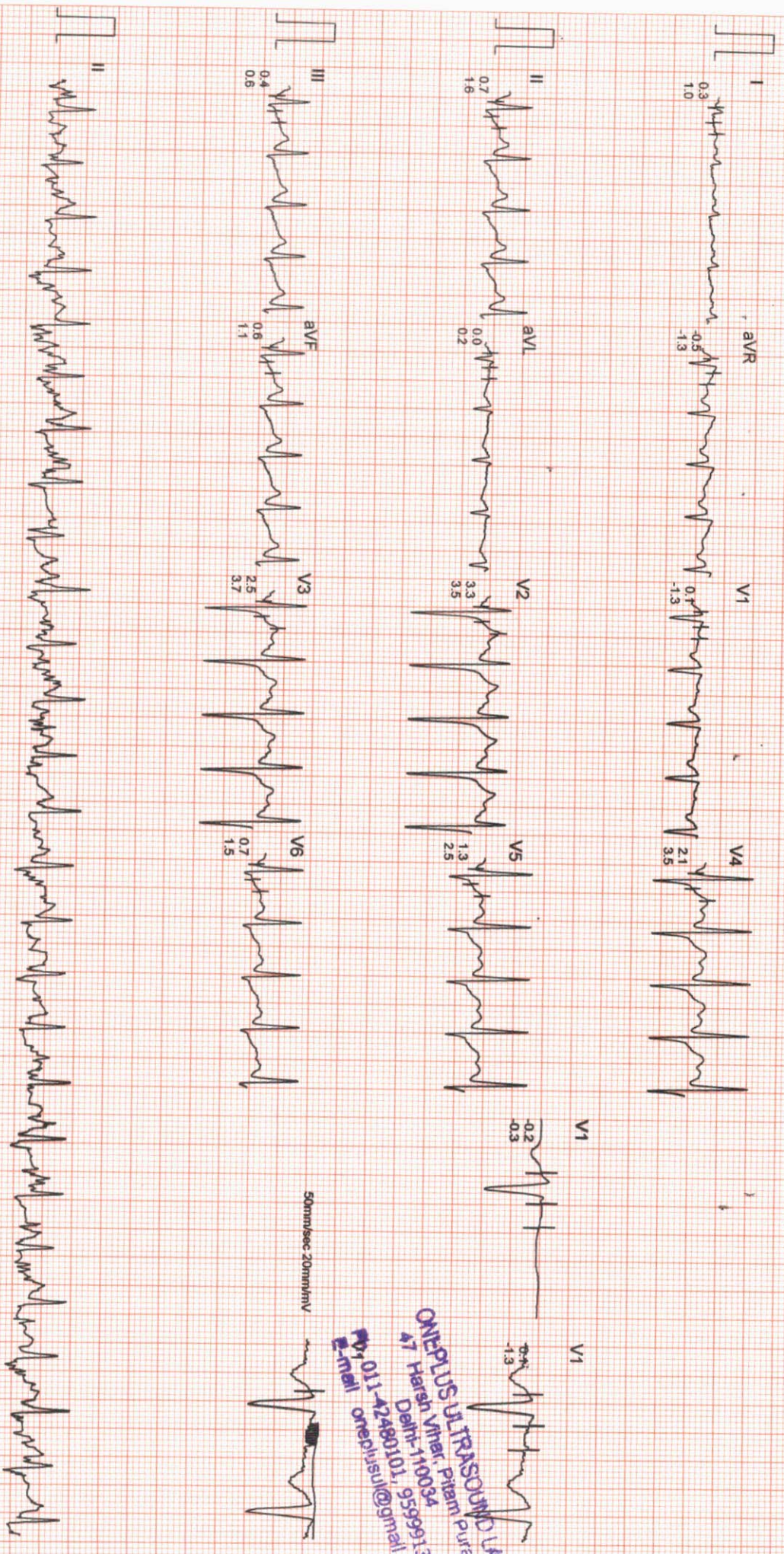
ONEPLUS ULTRASOUND LAB

Mr. SACHIN KUMAR
I.D. : 983
AGE/SEX : 40M
RECORDED : 5-4-2024 10:34

RATE : 164 BPM
B.P. : 150/90 mmHg

BRUCE
EXERCISE 4
PHASE TIME : 9:59
STAGE TIME : 0:59

ST @ 10mm/mV
80ms PostJ
SPEED : 6.7 Km./Hr.
GRADE : 16.0 %
LINKED MEDIAN



Filtered Computer Corrected Baseline

25mm/sec 10mm/mV

50mm/sec 20mm/mV

ONEPLUS ULTRASOUND LAB
47, Harsuh Vihar, Pitam Pur, Gurgaon
Delhi-110084
9556956130351
10111-24880101
Email: onepplusul@ gmail.com

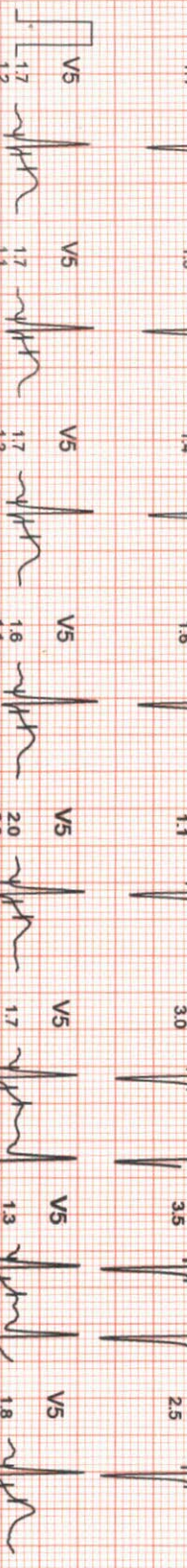
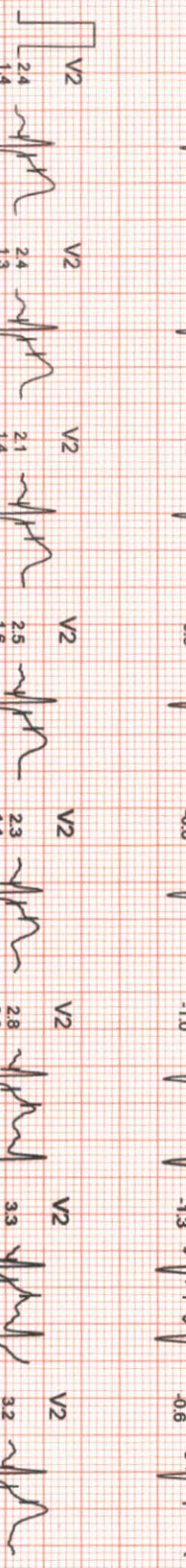
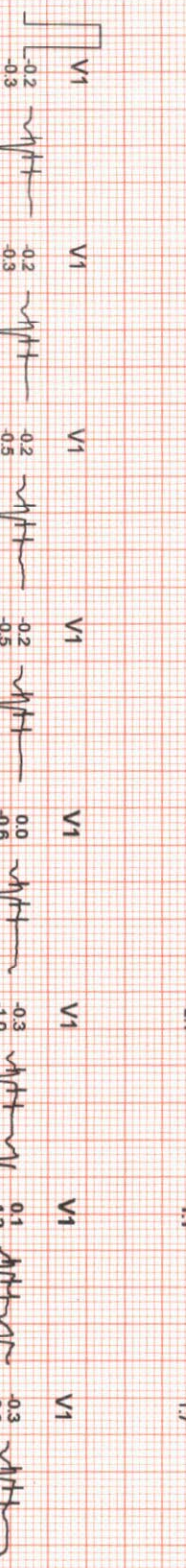
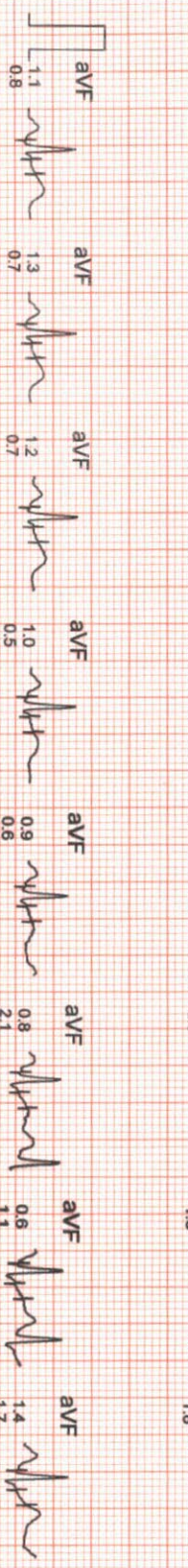
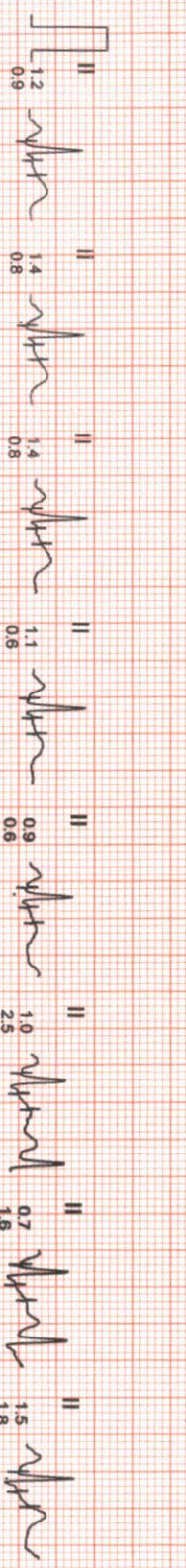
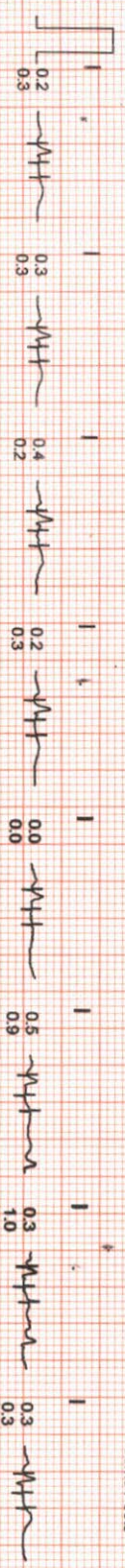
ONEPLUS ULTRASOUND LAB

AGE/SEX : 40/M

RECORDED : 5-4-2024 10:34

AVG E.C.G.

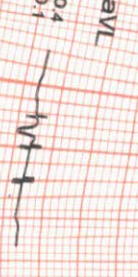
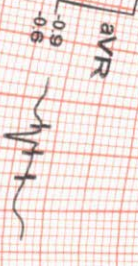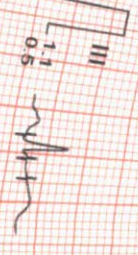
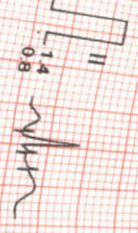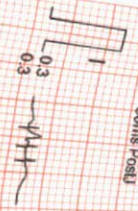STAGE	VELOCITY	HR	B.P.
SUPINE	0.0Kmph	80 bpm	B.P. 130/84
STANDING	0.0Kmph	81 bpm	B.P. 130/84
HYPERVENT	0.03	83 bpm	B.P. 130/84
STAGE 1	2.59	103 bpm	B.P. 130/84
STAGE 2	5.59	116 bpm	B.P. 140/88
STAGE 3	8.59	139 bpm	B.P. 140/88
PEAK EXERCISE	10.00	165 bpm	B.P. 150/90
RECOVERY	2.99	111 bpm	B.P. 132/84



ONEPLUS ULTRASOUND LAB
 47 Harsn Vihar, Pitam Pura,
 Delhi-110034
 Ph. 011-2480101, 99599913051
 E-mail: oneplusul@gmail.com

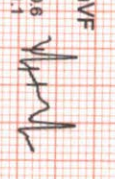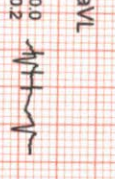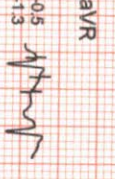

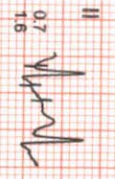
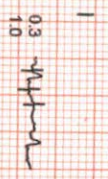
STANDING

0.0Km/h
0.0%
81 bpm
B.P. 130/84
80ms Postu



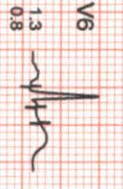


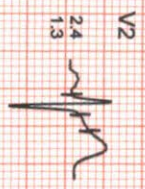
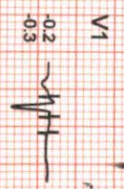
PEAK EXERCISE

1000
1:00
0.0Km/h
6.7Km/h
16.0%
165 bpm
B.P. 150/90
80ms Postu



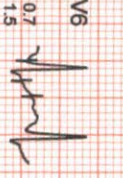
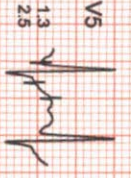
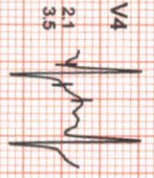
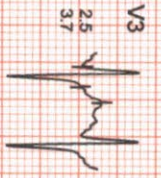
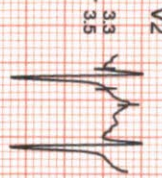
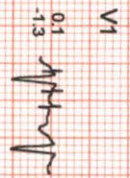
STANDING

0.0Km/h
0.0%
81 bpm
B.P. 130/84
80ms Postu



PEAK EXERCISE

1000
1:00
0.0Km/h
6.7Km/h
16.0%
165 bpm
B.P. 150/90
80ms Postu



COMPARISON REPORT

ONEPLUS ULTRASOUND LAB
#7 Harsh Vihar, Pitam Pura,
Delhi-110034
Ph. 011-42480101, 9599913051
E-mail onechrisul@gmail.com

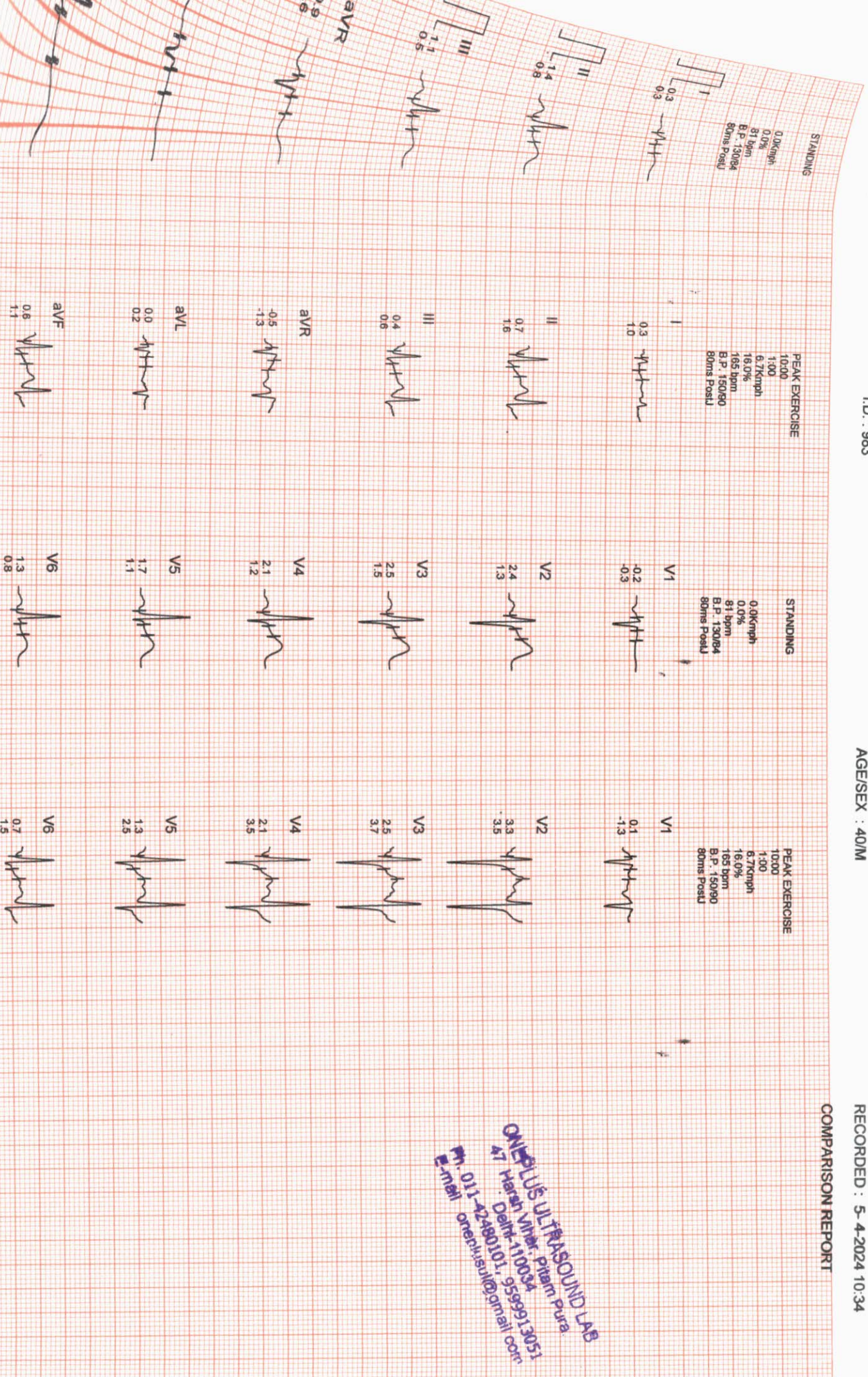


STANDING
0.0kmph
0.0%
81 bpm
B.P. 130/84
80ms Postu

PEAK EXERCISE
10:00
1:00
6.7kmph
16.0%
165 bpm
B.P. 150/90
80ms Postu

STANDING
0.0kmph
0.0%
81 bpm
B.P. 130/84
80ms Postu

PEAK EXERCISE
10:00
1:00
6.7kmph
16.0%
165 bpm
B.P. 150/90
80ms Postu



ONEPLUS ULTRASOUND LAB
 47 Harsh Vihar, Pitam Pura,
 Delhi-110034
 Ph. 011-42480101, 9599913051
 E-mail oneplusul@gmail.com



OnePLUS
Ultrasound Lab
— QUALITY FIRST... ALWAYS! —

Dr. Nitin Agarwal

Pathologist & Director
MBBS, MD, FAGE
Ex. Chief of Lab
Dr. Lal Path labs.

Dr. Pooja (Garg) Agarwal

Radiologist & Director
MBBS (MAMC) DMRD (MAMC)
Imaging Expert In Fetal And Maternal Medicine,
University of Barcelona, Spain
Fetal Medicine Foundation (UK) Accreditation

Name	: Mr. SACHIN KUMAR	Age/Sex	: 40 YRS/Male
Ref. By	: Dr. MEDIWHEEL	Lab No	: 012404050016
Date	: 05-Apr-2024	Patient ID	: LSHHI133397

X-ray-Chest PA view

Bony cage and soft tissues are normal.

Cardiothoracic ratio is normal.

Mediastinum is normal.


Both hila are normal.

Both costophrenic angles are clear.

Both domes of diaphragm are normal.

Lung fields are clear. No parenchymal lesion seen.

IMPRESSION: Normal Study.


DR. POOJA GARG
RADIOLOGIST
REG NO- DMC/R/03398

Dr. POOJA GARG
M.B.B.S., D.M.R.D
Reg No DMC/R/03398
Radiologist

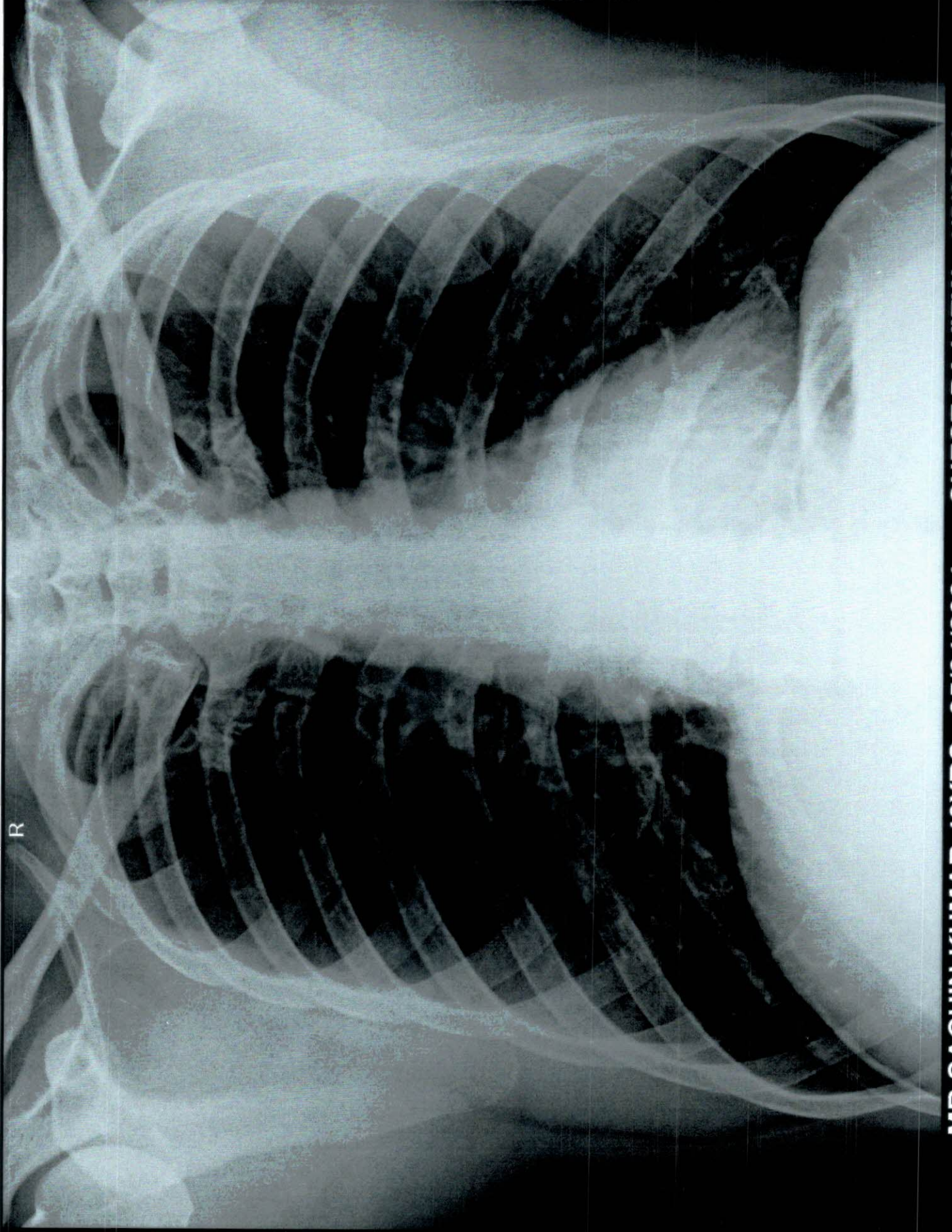
Type By : darshita

47, Harsh Vihar, Pitampura, Delhi-34 ☎ 011-4248 0101, 9599913051

✉ Email: oneplusul@gmail.com 🌐 www.oneplusul.in

- Clinical correlation is essential for final diagnosis. • If test results are unsatisfactory please contact personally or on phone.
- This report is for perusal of doctors only. • All disputes are subject to Delhi jurisdiction only. • Not for medico legal case.
- All congenital anomalies in a foetus may not be diagnosed in routine obstetric ultrasound.

R



MR SACHIN KUMAR 40YRS 05/04/2024 CHEST PA VIEW 4/5/2024
ONEPI US UI TRASOUND I AR 47-HARSH VIHAR PITAMPIRA

Name	: Mr. SACHIN KUMAR	Age/Sex	: 40 YRS/Male
Ref. By	: Dr. MEDIWHEEL	Lab No	: 012404050016
Date	: 05-Apr-2024	Patient ID	: LSHHI133397

ULTRASOUND EXAMINATION---WHOLE ABDOMEN

Liver is normal in size (13.6 cm) and outline with altered echopattern. Diffuse increase in echogenicity of liver parenchyma is noted, suggestive of fatty infiltration (grade I). No abscess or mass lesion seen. Hepatic veins, portal vein, IVC and aorta are normal. Intrahepatic biliary radicles are not dilated. CBD is normal in caliber (3.5 mm).

Gall bladder is well distended. Few calculi are seen in the gallbladder lumen, largest measuring upto 4.7 mm. Gallbladder walls are not thickened. Local tenderness over gallbladder is absent.

Both kidneys are normal in size, shape, position, outline and echopattern. Corticomedullary differentiation is maintained. No pelvicalyceal dilation or calculus or mass lesion is seen.

Renal measurements are --

Rt. Kidney – 10.5 x 4.8 cm.

Lt. kidney – 10.4 x 4.5 cm.

Spleen is normal in size and echotexture. No mass lesion seen.

Pancreas is normal in size, outline and echotexture.

Urinary bladder is normal in shape and position. No evidence of intravesical stone or mass seen.

Prostate is normal in size, shape and echopattern.

Prostate measures 4.0 x 3.5 x 3.0 cm. **Weight of prostate is 22.6 grams.**

No abnormal bowel wall thickening seen in right iliac fossa.

No free fluid seen anywhere in abdomen.

IMPRESSION:

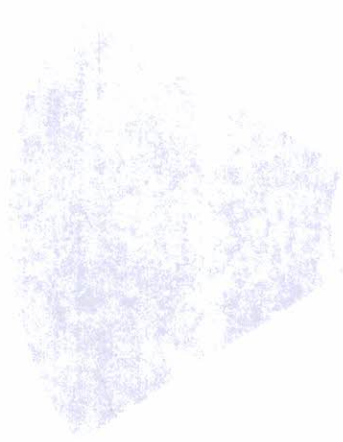


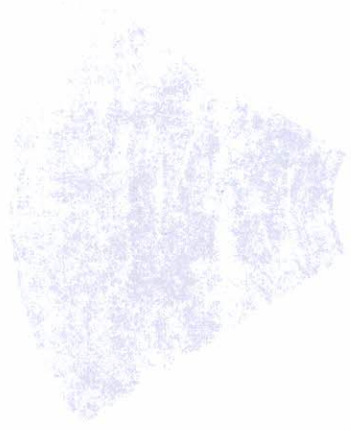
- Fatty infiltration of liver (grade I) with no hepatomegaly.
- Cholelithiasis.


DR. RASHMI BANSAL
RADIOLOGIST
REG NO- DMC/R/10067

Dr. RASHMI BANSAL
Radiologist
Reg. No. DMC/R/10067

47, Harsh Vihar, Pitampura, Delhi-34 ☎ 011-4248 0101, 9599913051

✉ Email: oneplusul@gmail.com 🌐 www.oneplusul.in



RESEARCH CENTER FOR THE STUDY OF EARLY MAN

WISNIA MR SACHIN 40 M MI 14 05-04-2024
OnePlus Ultrasound Lab CA-7A / Abdomen / FR 25Hz Th 0.1 11:32:43 AM
20 G60 DR135 FAS P90 Frq Gen. 16 Dcm
D1 3.04 cm
D2 4.91 cm



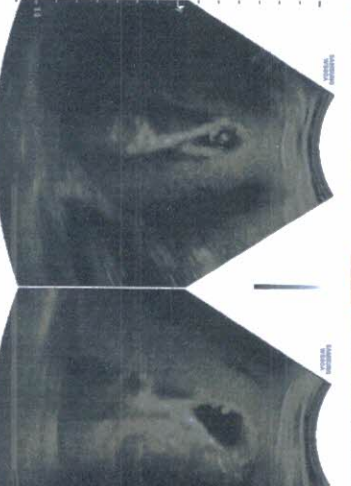
RT KIDNEY

WISNIA MR SACHIN 40 M MI 14 05-04-2024
OnePlus Ultrasound Lab CA-7A / Abdomen / FR 25Hz Th 0.1 11:32:54 AM
20 G60 DR135 FAS P90 Frq Gen. 16 Dcm
D1 3.39 cm



SPLEEN

WISNIA MR SACHIN 40 M MI 14 05-04-2024
OnePlus Ultrasound Lab CA-7A / Abdomen / FR 25Hz Th 0.1 11:34:03 AM
20 G60 DR135 FAS P90 Frq Gen. 16 Dcm
D1 0.47 cm




LT KIDNEY

WISNIA MR SACHIN 40 M MI 14 05-04-2024
OnePlus Ultrasound Lab CA-7A / Abdomen / FR 25Hz Th 0.1 11:32:38 AM
20 G60 DR135 FAS P90 Frq Gen. 16 Dcm
D1 3.80 cm
D2 4.80 cm



RT KIDNEY

WISNIA MR SACHIN 40 M MI 14 05-04-2024
OnePlus Ultrasound Lab CA-7A / Abdomen / FR 25Hz Th 0.1 11:32:13 AM
20 G60 DR135 FAS P90 Frq Gen. 16 Dcm
D1 8.85 cm



SPLEEN

WISNIA MR SACHIN 40 M MI 14 05-04-2024
OnePlus Ultrasound Lab CA-7A / Abdomen / FR 25Hz Th 0.1 11:37:49 AM
20 G60 DR135 FAS P90 Frq Gen. 16 Dcm
D1 3.49 cm
D2 3.08 cm
D3 4.01 cm
D4 28.50 ml




LT KIDNEY

WISNIA MR SACHIN 40 M MI 14 05-04-2024
OnePlus Ultrasound Lab CA-7A / Abdomen / FR 25Hz Th 0.1 11:32:31 AM
20 G60 DR135 FAS P90 Frq Gen. 16 Dcm
D1 3.04 cm
D2 4.91 cm



LT KIDNEY

WISNIA MR SACHIN 40 M MI 14 05-04-2024
OnePlus Ultrasound Lab CA-7A / Abdomen / FR 25Hz Th 0.1 11:32:39 AM
20 G60 DR135 FAS P90 Frq Gen. 16 Dcm
D1 0.38 cm



SPLEEN

WISNIA MR SACHIN 40 M MI 14 05-04-2024
OnePlus Ultrasound Lab CA-7A / Abdomen / FR 25Hz Th 0.1 11:37:59 AM
20 G60 DR135 FAS P90 Frq Gen. 16 Dcm



LT KIDNEY



NAME	:Mr. SACHIN KUMAR	Barcode No	:10168867
AGE/GENDER	:40 YRS/Male	SPECIMEN DATE	:05/Apr/2024 09:21AM
PATIENT ID	:133397	SPECIMEN RECEIVED	:05/Apr/2024 11:00AM
REFERRED BY	:Dr. MEDIWHEEL	REPORT DATE	:05/Apr/2024 03:19PM
CENTRE NAME	:ONEPLUS ULTRASOUND LAB	LAB NO.	:012404050016

Test Name	Result	Unit	Ref. Range
-----------	--------	------	------------

HAEMATOLOGY

MediWheel Health Checkup >40 Male

Sample Type:EDTA Blood

Glycosylated Hemoglobin (HbA1c) HPLC	5.5	%	Non Diabetic adults <5.7 Prediabetic (at risk) 5.7-6.4 Diabetes >6.4
--	-----	---	--

Estimated average blood glucose (eag) CALCULATED	111		
--	-----	--	--

Reference range (mg/dl):

90 - 120:Excellent control, 121 - 150:Good Control, 151 - 180:Average Control, 181 - 210:Action Suggested

>211:Panic value

Checked By.

Dr. NITIN AGARWAL
MBBS, MD
Regn. No. DMC-R-1436


DR. NITIN AGARWAL
MBBS,MD(PATHOLOGIST)

47, Harsh Vihar, Pitampura, Delhi-34 ☎ 011-4248 0101, 9599913051

✉ Email: oneplusul@gmail.com 🌐 www.oneplusul.in

- Clinical correlation is essential for final diagnosis. • If test results are unsatisfactory please contact personally or on phone.
- This report is for perusal of doctors only. • All disputes are subject to Delhi jurisdiction only. • Not for medico legal case.
- All congenital anomalies in a foetus may not be diagnosed in routine obstetric ultrasound.



OnePLUS Ultrasound Lab

— QUALITY FIRST... ALWAYS! —

Dr. Nitin Agarwal

Pathologist & Director
MBBS, MD, FAGE
Ex. Chief of Lab
Dr. Lal Path labs.

Dr. Pooja (Garg) Agarwal

Radiologist & Director
MBBS (MAMC) DMRD (MAMC)
Imaging Expert In Fetal And Maternal Medicine,
University of Barcelona, Spain
Fetal Medicine Foundation (UK) Accreditation



NAME	:Mr. SACHIN KUMAR	Barcode No	:10168867
AGE/GENDER	:40 YRS/Male	SPECIMEN DATE	:05/Apr/2024 09:21AM
PATIENT ID	:133397	SPECIMEN RECEIVED	:05/Apr/2024 11:00AM
REFERRED BY	:Dr. MEDIWHEEL	REPORT DATE	:05/Apr/2024 03:19PM
CENTRE NAME	:ONEPLUS ULTRASOUND LAB	LAB NO.	:012404050016

Test Name	Result	Unit	Ref. Range
-----------	--------	------	------------

HAEMATOLOGY

BLOOD GROUP (ABO)

Forward and Reverse grouping (Slide & Tube)

O

Rh typing


POSITIVE

NOTE :

- * Apart from major A,B,H antigens which are used for ABO grouping and Rh typing, many minor blood group antigens exist. Agglutination may also vary according to titre of antigen and antibody.
- * So before transfusion, reconfirmation of blood group as well as cross-matching is needed.
- * Presence of maternal antibodies in newborns, may interfere with blood grouping.
- * Auto agglutination (due to cold antibody, falciparum malaria, sepsis, internal malignancy etc.) may also cause erroneous result.

Checked By.

Dr. NITIN AGARWAL
MBBS, MD
Regn. No. DMC-R-1436


DR. NITIN AGARWAL
MBBS,MD(PATHOLOGIST)

47, Harsh Vihar, Pitampura, Delhi-34 ☎ 011-4248 0101, 9599913051

✉ Email: oneplusul@gmail.com 🌐 www.oneplusul.in

- Clinical correlation is essential for final diagnosis. • If test results are unsatisfactory please contact personally on phone.
- This report is for perusal of doctors only. • All disputes are subject to Delhi jurisdiction only. • Not for medico legal case.
- All congenital anomalies in a foetus may not be diagnosed in routine obstetric ultrasound.



OnePLUS
Ultrasound Lab

— QUALITY FIRST... ALWAYS! —



NABL
MC - 6036

Dr. Nitin Agarwal

Pathologist & Director
MBBS, MD, FAGE
Ex. Chief of Lab
Dr. Lal Path labs.

Dr. Pooja (Garg) Agarwal

Radiologist & Director
MBBS (MAMC) DMRD (MAMC)
Imaging Expert In Fetal And Maternal Medicine,
University of Barcelona, Spain
Fetal Medicine Foundation (UK) Accreditation



NAME	:Mr. SACHIN KUMAR	Barcode No	:10168867
AGE/GENDER	:40 YRS/Male	SPECIMEN DATE	:05/Apr/2024 09:21AM
PATIENT ID	:133397	SPECIMEN RECEIVED	:05/Apr/2024 11:00AM
REFERRED BY	:Dr. MEDIWHEEL	REPORT DATE	:05/Apr/2024 03:19PM
CENTRE NAME	:ONEPLUS ULTRASOUND LAB	LAB NO.	:012404050016

Test Name	Result	Unit	Ref. Range
HAEMATOLOGY			
CBC			
Haemoglobin Non cyanide Hb analysis	14.7	g/dl	13.0-17.0
Total Leucocyte Count Electrical Impedance	7900	/cumm	4000-10000
Differential leucocyte count			
Neutrophils Electrical Impedance & Microscopic	65.1	%	40-80
Lymphocyte Electrical Impedance & Microscopic	30.70	%	20-40
Monocytes Electrical Impedance & Microscopic	2.00	%	2-10
Eosinophils Electrical Impedance & Microscopic	2.0	%	1-6
Basophils Electrical Impedance & Microscopic	0.2	%	0-2
RBC Count Electrical Impedance	5.00	million/cumm	4.5 - 5.5
Hematocrit(PCV) Flow Cytometry	43.6	%	40-50
MCV Calculated	86.5	fl	83-101
MCH Calculated	29.1	pg	27-32
MCHC Calculated	33.6	g/dL	31.5-34.5
RDW-CV Calculated	13.5	%	11.4-14.0
Platelet count Electrical Impedance	287000	/cumm	150000-410000

BIOCHEMISTRY

Sample Type:Fluoride F

Blood sugar fasting
GOD-POD

92 mg/dl 70-100 mg/dl

Checked By.

DR. NITIN AGARWAL
MBBS,MD(PATHOLOGIST)
Regn. No. DMC-R-1436

47, Harsh Vihar, Pitampura, Delhi-34 ☎ 011-4248 0101, 9599913051

✉ Email: oneplusul@gmail.com 🌐 www.oneplusul.in

- Clinical correlation is essential for final diagnosis. • If test results are unsatisfactory please contact personally or on phone.
- This report is for perusal of doctors only. • All disputes are subject to Delhi jurisdiction only. • Not for medico legal case.
- All congenital anomalies in a foetus may not be diagnosed in routine obstetric ultrasound.



OnePLUS

Ultrasound Lab

— QUALITY FIRST... ALWAYS! —



NABL
MC - 6036

Dr. Nitin Agarwal

Pathologist & Director
MBBS, MD, FAGE
Ex. Chief of Lab
Dr. Lal Path labs.

Dr. Pooja (Garg) Agarwal

Radiologist & Director
MBBS (MAMC) DMRD (MAMC)
Imaging Expert In Fetal And Maternal Medicine,
University of Barcelona, Spain
Fetal Medicine Foundation (UK) Accreditation



NAME	:Mr. SACHIN KUMAR	Barcode No	:10168867
AGE/GENDER	:40 YRS/Male	SPECIMEN DATE	:05/Apr/2024 09:21AM
PATIENT ID	:133397	SPECIMEN RECEIVED	:05/Apr/2024 11:00AM
REFERRED BY	:Dr. MEDIWHEEL	REPORT DATE	:05/Apr/2024 03:19PM
CENTRE NAME	:ONEPLUS ULTRASOUND LAB	LAB NO.	:012404050016

Test Name	Result	Unit	Ref. Range
-----------	--------	------	------------

Sample Type:Serum

Bun (blood urea nitrogen) Calculated	12.10	mg/dl	8.9-21.6
Uric Acid, serum Uricase- PAP	4.6	mg/dl	3.5-7.2
Creatinine, serum Enzymatic	0.9	mg/dl	0.71-1.16

LFT(LIVER FUNCTION TEST)

Bilirubin Total Modified tab	0.56	mg/dl	0.2-1.1
Bilirubin Conjugated Diazotied sulfanilic acid	0.24	mg/dL	0.11-0.42
Bilirubin Unconjugated Calculated	0.32	mg/dl	up to 0.7
SGOT (AST) Tris buffer	20	U/L	0-46
SGPT (ALT) Tris buffer	52	U/L	0-49
Alkaline phosphatase Amp buffer	95	U/L	40-129
GAMMA GT Szasz Method	28	U/L	10-45
Total Protein Biuret	6.9	gm/dl	6.60 - 8.70
Albumin serum BCG	3.7	g/dL	3.0-5.2
Globulin Calculated	3.20	gm/dl	1.8-3.4
Albumin/Globulin Ratio Calculated	1.16		1.10 - 2.50

LIPID PROFILE

Cholesterol CHOD-PAP	221	mg/dl	50-200
Triglycerides GPO-PAP	139	mg/dL	25-150
HDL Cholesterol Selective Inhibition	46	mg/dL	40 - 60

Checked By.

DR. NITIN AGARWAL
MBBS, MD (PATHOLOGIST)
Page 4 of 8

47, Harsh Vihar, Pitampura, Delhi-34 ☎ 011-4248 0101, 9899913051

✉ Email: oneplusul@gmail.com 🌐 www.oneplusul.in

- Clinical correlation is essential for final diagnosis. • If test results are unsatisfactory please contact personally on phone.
- This report is for perusal of doctors only. • All disputes are subject to Delhi jurisdiction only. • Not for medico legal case.
- All congenital anomalies in a foetus may not be diagnosed in routine obstetric ultrasound.



OnePLUS

Ultrasound Lab

QUALITY FIRST... ALWAYS!



NABL
MC - 6036

Dr. Nitin Agarwal

Pathologist & Director
MBBS, MD, FAGE
Ex. Chief of Lab
Dr. Lal Path labs.

Dr. Pooja (Garg) Agarwal

Radiologist & Director
MBBS (MAMC) DMRD (MAMC)
Imaging Expert In Fetal And Maternal Medicine,
University of Barcelona, Spain
Fetal Medicine Foundation (UK) Accreditation



NAME	:Mr. SACHIN KUMAR	Barcode No	:10168867
AGE/GENDER	:40 YRS/Male	SPECIMEN DATE	:05/Apr/2024 09:21AM
PATIENT ID	:133397	SPECIMEN RECEIVED	:05/Apr/2024 11:00AM
REFERRED BY	:Dr. MEDIWHEEL	REPORT DATE	:05/Apr/2024 03:19PM
CENTRE NAME	:ONEPLUS ULTRASOUND LAB	LAB NO.	:012404050016

Test Name	Result	Unit	Ref. Range
LDL cholesterol Calculated	147	mg/dL	<100
VLDL cholesterol Calculated	27.8	mg/dL	5-40
Cholesterol/HDL Ratio Calculated	4.8		Low Risk 3.3-4.97 Average Risk 4.4-7.1 Moderate Risk 7.1-11.0 High Risk >11.0
LDL/HDL Ratio Calculated	3.2		0 - 3.55

LDL Cholesterol	Total Cholesterol	HDL Cholesterol
<100 Optimal	<200 Desirable	<40 Low
100-129 Near optimal	200-239 Borderline high	>60 High
130-159 Borderline high	>240 High	
160-189 High		
>190 Very high		

According to NCEP, ATP-III Guidelines

BUN/Creatinine ratio

UREA UREASE-GLDH	26.00	mg/dl	15-45
Bun (blood urea nitrogen) Calculated	12.15	mg/dl	8.9-21.6
CREATININE ENZYMATIC	0.90	mg/dl	0.30-1.10
Bun/Creatinine Ratio Calculated	13.50		10.0 - 20.0

Checked By.

Dr. NITIN AGARWAL
MBBS, MD
No. DMC-R-1436
DR. NITIN AGARWAL
MBBS, MD (PATHOLOGIST)

47, Harsh Vihar, Pitampura, Delhi-34 ☎ 011-4248 0101, 9599913051

✉ Email: oneplusul@gmail.com 🌐 www.oneplusul.in

- Clinical correlation is essential for final diagnosis. • If test results are unsatisfactory please contact personally based on phone.
- This report is for perusal of doctors only. • All disputes are subject to Delhi jurisdiction only. • Not for medico legal case.
- All congenital anomalies in a foetus may not be diagnosed in routine obstetric ultrasound.



OnePLUS
Ultrasound Lab
— QUALITY FIRST... ALWAYS! —

Dr. Nitin Agarwal

Pathologist & Director
MBBS, MD, FAGE
Ex. Chief of Lab
Dr. Lal Path labs.

Dr. Pooja (Garg) Agarwal

Radiologist & Director
MBBS (MAMC) DMRD (MAMC)
Imaging Expert In Fetal And Maternal Medicine,
University of Barcelona, Spain
Fetal Medicine Foundation (UK) Accreditation



NAME	:Mr. SACHIN KUMAR	Barcode No	:10168867
AGE/GENDER	:40 YRS/Male	SPECIMEN DATE	:05/Apr/2024 09:21AM
PATIENT ID	:133397	SPECIMEN RECEIVED	:05/Apr/2024 11:00AM
REFERRED BY	:Dr. MEDIWHEEL	REPORT DATE	:05/Apr/2024 03:19PM
CENTRE NAME	:ONEPLUS ULTRASOUND LAB	LAB NO.	:012404050016

Test Name	Result	Unit	Ref. Range
-----------	--------	------	------------

ENDOCRINOLOGY

PSA TOTAL

Prostatic specific antigen, Total 1.24 ng/ml <4.0

< 40 years	0.21 to 1.72 ng/ml
40 - 49	0.27 to 2.19 ng/ml
50 - 59	0.27 to 3.42 ng/ml
60 - 69	0.22 to 6.16 ng/ml
> 69	0.21 to 6.77 ng/ml

Notes:

PSA is principally produced by the glandular epithelium of the prostate, and is secreted in the seminal fluid. PSA is also present in urine and blood. PSA acts on seminal fluid to fluidify and increase sperm mobility. PSA levels rise in prostatic pathologies such as benign prostatic hyperplasia (BPH) or prostate cancer.

THYROID PROFILE(T3,T4,TSH)

Triiodothyronine total [t3] ECLIA	0.85	ng/dl	0.52-1.9
Thyroxine total [t4] ECLIA	6.50	µg/dl	4.4 - 10.8
TSH (Thyroid Stimulating Hormone) Enzyme linked fluorescent assay	1.40	µIU/ml	0.25-5.0

AGE WISE VARIATION IN TSH

AGE	TSH(µIU/ml)	AGE	TSH(µIU/ml)
1-4 weeks	1.00 - 19.0	16-20 yrs	0.25 - 5.0
1-12 mths	1.70 - 9.1	21 - 80 yrs	0.25 - 5.0
1-5 yrs	0.80 - 8.2	I st trimester	0.25 - 5.0
6-10 yrs	0.25 - 5.0	II nd trimester	0.50 - 5.0
11-15 yrs	0.25 - 5.0	II rd trimester	0.4 - 6.0

Reference ranges - Interpretation of Diagnostic tests - (Jacques Wallach)

Checked By.

DR. NITIN AGARWAL
MBBS,MD(PATHOLOGIST)

Dr. NITIN AGARWAL
MBBS, MD
Regn. No. DMC-R-1436

47, Harsh Vihar, Pitampura, Delhi-34 ☎ 011-4248 0101, 9599913051

✉ Email: oneplusul@gmail.com 🌐 www.oneplusul.in

- Clinical correlation is essential for final diagnosis. • If test results are unsatisfactory please contact personally on 011-4248 0101.
- This report is for perusal of doctors only. • All disputes are subject to Delhi jurisdiction only. • Not for medico legal case.
- All congenital anomalies in a foetus may not be diagnosed in routine obstetric ultrasound.



OnePLUS

Ultrasound Lab

— QUALITY FIRST... ALWAYS! —

Dr. Nitin Agarwal

Pathologist & Director
MBBS, MD, FAGE
Ex. Chief of Lab
Dr. Lal Path labs.

Dr. Pooja (Garg) Agarwal

Radiologist & Director
MBBS (MAMC) DMRD (MAMC)
Imaging Expert In Fetal And Maternal Medicine,
University of Barcelona, Spain
Fetal Medicine Foundation (UK) Accreditation



NAME	:Mr. SACHIN KUMAR	Barcode No	:10168867
AGE/GENDER	:40 YRS/Male	SPECIMEN DATE	:05/Apr/2024 09:21AM
PATIENT ID	:133397	SPECIMEN RECEIVED	:05/Apr/2024 11:00AM
REFERRED BY	:Dr. MEDIWHEEL	REPORT DATE	:05/Apr/2024 03:19PM
CENTRE NAME	:ONEPLUS ULTRASOUND LAB	LAB NO.	:012404050016

Test Name	Result	Unit	Ref. Range
-----------	--------	------	------------

1. Primary hypothyroidism is accompanied by depressed serum T3 and T4 values and elevated serum TSH level.
2. Primary hyperthyroidism is accompanied by elevated serum T3 and T4 levels along with depressed TSH values.
3. Slightly elevated T3 levels may be found in pregnancy and estrogen therapy, while depressed levels may be encountered in severe illness, renal failure and during therapy with drugs like propranolol and propyl thiouracil.
4. Although elevated TSH levels are nearly always indicative of primary hypothyroidism, and may be seen in secondary thyrotoxicosis

Checked By.

Dr. NITIN AGARWAL
MBBS, MD
Regn. No. DMC-k-1436


DR. NITIN AGARWAL
MBBS,MD(PATHOLOGIST)

47, Harsh Vihar, Pitampura, Delhi-34 ☎ 011-4248 0101, 9599913051

✉ Email: oneplusul@gmail.com 🌐 www.oneplusul.in

- Clinical correlation is essential for final diagnosis. • If test results are unsatisfactory please contact personally on phone.
- This report is for perusal of doctors only. • All disputes are subject to Delhi jurisdiction only. • Not for medico legal case.
- All congenital anomalies in a foetus may not be diagnosed in routine obstetric ultrasound.



OnePLUS
Ultrasound Lab
— QUALITY FIRST... ALWAYS! —



NABL
MC - 6036

Dr. Nitin Agarwal

Pathologist & Director
MBBS, MD, FAGE
Ex. Chief of Lab
Dr. Lal Path labs.

Dr. Pooja (Garg) Agarwal

Radiologist & Director
MBBS (MAMC) DMRD (MAMC)
Imaging Expert In Fetal And Maternal Medicine
University of Barcelona, Spain
Fetal Medicine Foundation (UK) Accredited



NAME	:Mr. SACHIN KUMAR	Barcode No	:10168867
AGE/GENDER	:40 YRS/Male	SPECIMEN DATE	:05/Apr/2024 09:21AM
PATIENT ID	:133397	SPECIMEN RECEIVED	:05/Apr/2024 11:00AM
REFERRED BY	:Dr. MEDIWHEEL	REPORT DATE	:05/Apr/2024 03:19PM
CENTRE NAME	:ONEPLUS ULTRASOUND LAB	LAB NO.	:012404050016

Test Name	Result	Unit	Ref. Range
-----------	--------	------	------------

CLINICAL PATHOLOGY

URINE ROUTINE (Strip/microscopy)

Sample Type:Urine

Physical examination

Colour	PALE YELLOW		PALE YELLOW
Transparency	CLEAR		CLEAR
Sp.gravity BROMOTHYMOL BLUE	1.015		1.005-1.030
pH Double Indicators Test	6.00		5.0-8.0
Reaction	ACIDIC		ACIDIC

Chemical examination

Urine protein Protein Ionization	NIL		NIL
Urine sugar Oxidation Reaction	NIL		NIL
Bilirubin, urine	NEGATIVE		NEGATIVE
Urobilinogen P-Aminobenzoic Acid and Phenazopyridine Reaction	NORMAL		NORMAL
Ketones Acetoacetate and Dichlorobenzene Reaction	NEGATIVE		NEGATIVE

Microscopic examination

Pus cells. Microscopy	2-3	/HPF	0-2
Epithelial cells Microscopy	1-2	/HPF	NIL
R.B.C. Microscopy	NIL	/HPF	NIL
Casts Microscopy	NIL	/HPF	NIL
Crystals Microscopy	NIL	/HPF	NIL
Bacteria Microscopy	NIL	/HPF	NIL

Checked By.

Dr. NITIN AGARWAL
MBBS, MD
Regn. No. DMC - 436

DR. NITIN AGARWAL
MBBS,MD(PATHOLOGIST)

47, Harsh Vihar, Pitampura, Delhi-34 ☎ 011-4248 0101, 9599913051

✉ Email: oneplusul@gmail.com 🌐 www.oneplusul.in

• Clinical correlation is essential for final diagnosis. • If test results are unsatisfactory please contact personally or on phone.
• This report is for perusal of doctors only. • All disputes are subject to Delhi jurisdiction only. • Not for medico legal case.
• All congenital anomalies in a foetus may not be diagnosed in routine obstetric ultrasound.



OnePLUS Ultrasound Lab

QUALITY FIRST... ALWAYS!



NABL
MC - 6036

Dr. Nitin Agarwal

Pathologist & Director
MBBS, MD, FAGE
Ex. Chief of Lab
Dr. Lal Path labs.

Dr. Pooja (Garg) Agarwal

Radiologist & Director
MBBS (MAMC) DMRD (MAMC)
Imaging Expert In Fetal And Maternal Medicine,
University of Barcelona, Spain
Fetal Medicine Foundation (UK) Accreditation



NAME	:Mr. SACHIN KUMAR	Barcode No	:10168867
AGE/GENDER	:40 YRS/Male	SPECIMEN DATE	:05/Apr/2024 09:21AM
PATIENT ID	:133397	SPECIMEN RECEIVED	:05/Apr/2024 11:00AM
REFERRED BY	:Dr. MEDIWHEEL	REPORT DATE	:05/Apr/2024 03:19PM
CENTRE NAME	:ONEPLUS ULTRASOUND LAB	LAB NO.	:012404050016

Test Name	Result	Unit	Ref. Range
Others.	NIL	NIL	NIL

*** End Of Report ***

Checked By.

Dr. NITIN AGARWAL
MBBS, MD
Regn. No. DMC/R-1436

DR. NITIN AGARWAL
MBBS, MD (PATHOLOGIST)

47, Harsh Vihar, Pitampura, Delhi-34 ☎ 011-4248 0101, 9599913051

✉ Email: oneplusul@gmail.com 🌐 www.oneplusul.in

- Clinical correlation is essential for final diagnosis. • If test results are unsatisfactory please contact personally or on phone.
- This report is for perusal of doctors only. • All disputes are subject to Delhi jurisdiction only. • Not for medico legal case.
- All congenital anomalies in a foetus may not be diagnosed in routine obstetric ultrasound.