

ID: Name: ms. asha b m

Birth date: / mmHg

Sex: F cm kg

36 years 1100 Sinus rhythm
4068 Nonspecific T wave abnormality [flat T or negative T (V₄), V₄]
9130 ** borderline ECG **

Indication: 81 bpm
Symptoms: 132 ms
History: 78 ms

Heart rate: 81 bpm
RS dur: 362/400 ms
T/QTc(E) int: 73/81/60 ms

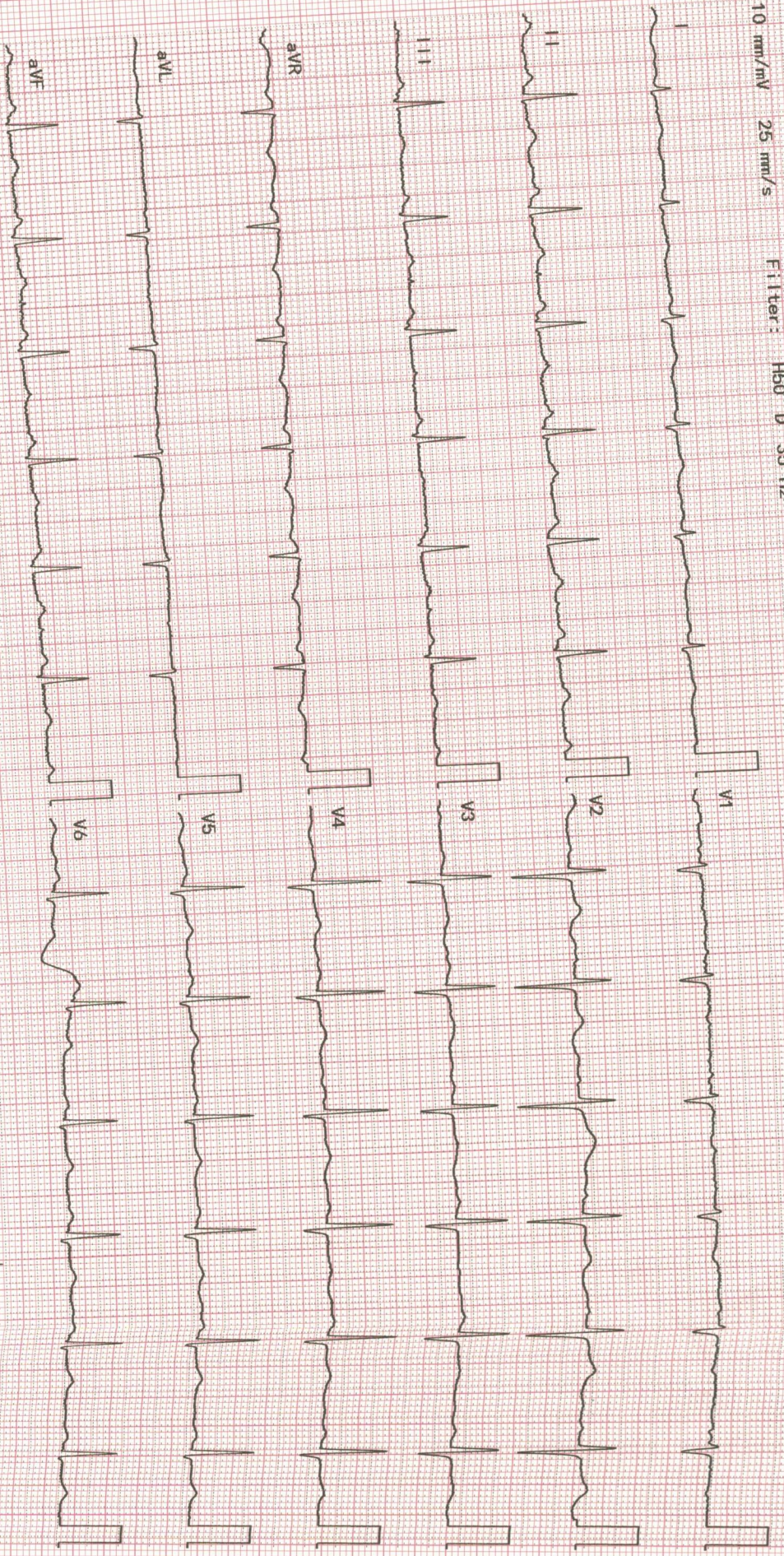
VQRS/T axis: 1.07/0.40 mV
M5/SV1 amp: 1.48 mV
M5+SV1 amp: 1.48 mV

Filter: H50 D 35 Hz

10 mm/mV 25 mm/s

10 mm/mV

Unconfirmed Report
Reviewed by:





DEPARTMENT OF RADIODIAGNOSIS

Name	Asha B M	Date	06/04/24
Age	36 years	Hospital ID	UHJA24000264
Sex	Female	Ref.	Health check

ULTRASOUND ABDOMEN AND PELVIS

FINDINGS:

Liver is normal in size and echopattern. No intra or extra hepatic biliary duct dilatation. No focal lesions. **Portal vein** is normal in caliber. **CBD** is not dilated.

Gall bladder shows a small polyp measuring 2.2 mm in the body region. There is no evidence of calculi, wall thickening or pericholecystic fluid.

Pancreas - Visualized part of the pancreatic head and body appears normal in size, contour and echogenicity. Rest of the pancreas is obscured by bowel gas.

Spleen is normal in size, shape, contour and echopattern. No evidence of mass or focal lesions.

Right Kidney is normal in size (10.8 x 3.5 cms), position, shape and echopattern. Corticomedullary differentiation is maintained. No evidence of calculi or hydronephrosis.

Left Kidney is normal in size (10.7 x 4.4 cms), position, shape and echopattern. Corticomedullary differentiation is maintained. No evidence of calculi or hydronephrosis.

Retroperitoneum- Visualized aorta appeared normal. No obvious enlarged para-aortic nodes.

Urinary Bladder is distended, normal in contour and wall thickness. No evidence of calculi.

Uterus is anteverted and normal in size, measures 8.7 x 3.5 x 4.6 cms. Myometrial and endometrial echoes are normal. Endometrium measures 6 mm.

Right ovary could not be visualized - likely by bowel gas.

Left ovary is normal in size and echopattern, measures 6.3 cc.

Both adnexa: Normal. No mass is seen.

There is no ascites or pleural effusion. Appendix could not be localized. No RIF probe tenderness.

IMPRESSION:

- Small gall bladder polyp.
- No other definite sonological abnormality detected.

Dr. Elluru Santosh Kumar
Consultant Radiologist



NABH



NABL



No.1



HOSPITAL
Care Par Excellence
Jayanagar, Bangalore

DEPARTMENT OF RADIODIAGNOSIS

Name	Asha B M	Date	06/04/24
Age	36 years	Hospital ID	UHJA24000264
Sex	Female	Ref.	Health check

RADIOGRAPH OF THE CHEST (PA - VIEW)

FINDINGS:

Bilateral lung fields are normal.

Bilateral costo-phrenic angles are normal.

Cardia and mediastinal contours are normal.

The bony thorax is grossly normal.

IMPRESSION:

- No radiographic abnormality.

Dr. Elluru Santosh Kumar
Consultant Radiologist

UNITED HOSPITAL (A Unit of United Brothers Healthcare Services Private Limited)



NABH



NABL



No.1

**UNITED HOSPITAL**Care Par Excellence
Jayanagar, Bangalore

Patient name :	Mrs. ASHA B M	Date :	06/04/24
Age :	36 years GENDER: FEMALE	Patient ID :	24000264
Ref by :	DR. CMO	OP/ IP :	HEALTH CHECKUP

2D- ECHOCARDIOGRAPHY
M - MODE AND DOPPLER MEASUREMENTS

(c.m)	(c.m)	(cm/sec)		
AO : 2.5 (2.5-3.7)	LVIDD : 4.2 (3.5-5.5)	MV EV : 70.3	AV : 63.1	MR : NORMAL
LA : 2.6 (1.9-4.0)	LVIDS : 2.7 (2.4-4.2)	AV : 130		AR : NORMAL
RA : 2.2 (<4.4)	IVSD : 0.8 (0.6-1.1)	PV : 107		PR : NORMAL
RV : 2.1 (<3.5)	IVSS : 1.0 (0.9-1.2)	TV EV : ----	AV : ----	TR : NORMAL
TAPSE: 1.8 (>1.6)	LVPWD : 1.1 (0.6-1.1)	Diastolic Function : NO LVDD		
	LVPWS : 1.2 (0.9-1.2)			
	EF : 60%			

DESCRIPTIVE FINDINGS

Left Ventricle	: NORMAL
Right Ventricle	: NORMAL
Left Atrium	: NORMAL
Right Atrium	: NORMAL
Wall motion analysis	: NO RWMA
Mitral Valve	: NORMAL
Aortic Valve	: NORMAL
Tricuspid Valve	: NORMAL
Pulmonary Valve	: NORMAL
IAS	: INTACT
IVS	: INTACT
Pericardium	: NORMAL
Other Findings	: IVC NORMAL AND COLLAPSING

IMPRESSION:

NORMAL CHAMBER DIMENSIONS
 NORMAL LV SYSTOLIC FUNCTION EF : 60%
 NORMAL LV DIASTOLIC FUNCTION
 NO PULMONARTERY HYPERTENSION
 NO REGIONAL WALL MOTION ABNORMALITIES
 NO CLOTS/ PERICARDIAL EFFUSION /VEGETATION

DR. RAHUL S PATIL
CONSULTANT CARDIOLOGIST

UNITED HOSPITAL (A Unit of United Brothers Healthcare Services Private Limited)

United Hospital

No.110 (30), Madhavan Park Circle, 10th Main Rd,
 3rd Block Jayanagar, Bangalore - 560 011

T: 080 4566 6666

E: appointments@unitedhospital.in

W: www.unitedhospitals.com



NABH



NABL



No.1



UNITED HOSPITAL

Care Par Excellence
Jayanagar, Bangalore

Out Patient Record

Patient Name : Mrs.ASHA B.M **UHID** : UHJA24000264
Age / Sex : 36 Years / Female **OP NO/Reg Dt** : 06-04-2024 09:09 AM
Spouse / Father Name : R RAGHAVENDRA B **Department** :
Address : , , Bengaluru Urban, Karnataka, INDIA, **Referred By** : *optical*
Consultant : Dr.Preventive Health Check Up
KMC No. :

Complaints / Findings / Observations :

Investigations:

Vn $\left\{ \begin{array}{l} 6/60 \text{ PR } 6/6 \\ 6/18 \text{ PR } 6/6 \end{array} \right\}$ *as* *nil optical*

Treatment / Care of Plan / Provisional Diagnosis :


As OU need

Fundis OU CD 0.3:1, (HFF)

Follow Up Advice :

RE: - 3.25 DS / - 1.00 DC X 60 6/6
LE: - 1.25 DS / - 1.00 DC X 105 6/6

Adv: Dilated fundis examination


Signature of the Doctor
Dr. Shub