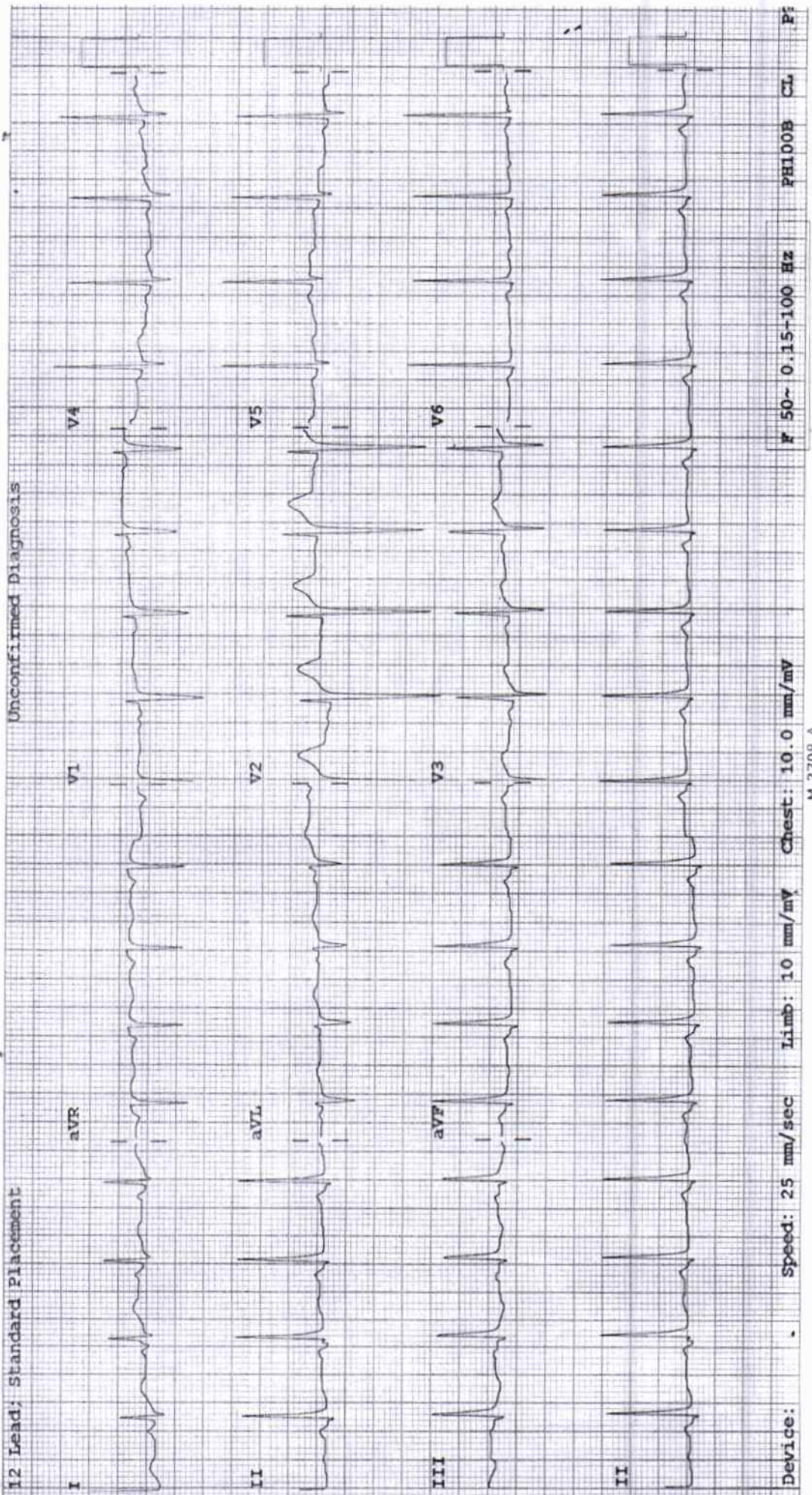


Rate 105 . Age not entered, assumed to be 50 years old for purpose of ECG interpretation
 . Sinus tachycardia.....rate> 99
 PR 132 . Consider left ventricular hypertrophy..... (S V1/V2+R V5/V6) >3.50mV
 QRSD 82 . Borderline T abnormalities, inferior leads.....T flat/neg, II III aVF
 QT 322
 QTc 426

--AXIS--
 P 50
 QRS 75
 T -18
 - ABNORMAL ECG -



2D ECHOCARDIOGRAPHY & COLOUR DOPPLER STUDY

Name : Mr. Prashant Ghawghawe

Age / Sex : 35 Yrs. / Male

Done By : Dr. Nitin Tiwari

Date : March 23, 2024

OPD

UHID : 353692

Comments :

Sector echo done in plax, psax, apical 4 & 5 chambers, subcostal view shows:

Normal morphology of mitral, aortic, tricuspid and pulmonary valves.

The left atrium, left ventricle, right atrium and right ventricle are normal in dimension and morphology. There is no regional wall motion abnormality of left ventricle at rest. The left ventricular systolic function is **good**. The global left ventricular ejection fraction is 60 %

The IAS and IVS are intact.

The pericardium is normal. There is no pericardial effusion

There is no clot or vegetation seen.

CW, PW and Colour Doppler: Transmitral flow is suggestive of normal left ventricular diastolic function present. The flow pattern across other cardiac valves is normal. There is no evidence of pulmonary hypertension.

Impression:

Normal cardiac valves and chamber dimensions

No regional wall motion abnormality of left ventricle at rest

Good left ventricular systolic function. LVEF – 60 %

Normal LV diastolic function

No pulmonary hypertension

Dr. Nitin Tiwari
MD, DNB (Med.), DM, DNB (Card.),
MNAMS, MAPSIC
Sr. Interventional Cardiologist



DEPARTMENT OF LABORATORY MEDICINE

BIOCHEMISTRY

Final Report

Patient Name : MR. PRASHANT GHAWGHAWE	Order Date : 23/03/2024 10:41 AM
Age / Sex : 35 Years / Male	Sample Collection : 23/03/2024 10:48 AM
UHID : WHN2.0000353692	Receiving Date Time : 23/03/2024 10:49 AM
Approval Date Time : 23/03/2024 01:53 PM	Report Date : 23/03/2024 01:52 PM
Primary Consultant : DR. WOCKHARDT DOCTOR	Specimen : Serum
Order No. : 54992	
Bill No. : OCR3/24/0007245	

PARAMETER	METHOD	RESULT	UNIT	B.R.I
Serum Urea	Urease-GLDH	13.7	mg/dL	1-50
Blood Urea Nitrogen	Calculated	6.40	mg/dL	6-20
Creatinine- Serum				
Creatinine	Enzymatic colorimetric	0.94	mg/dL	0.67-1.17
Plasma Glucose				
Random Sugar		87.69	mg/dl	70-150
Uric Acid- Serum				
Uric Acid	Enzymatic colorimetric	6.9	mg/dL	3.4-7
Lipid Profile				
Cholesterol	Colorimetric - Cholesterol Oxidase	216.86	mg/dL	0-200
Triglycerides	Enzymatic colorimetric	180.3	mg/dL	0-150
HDL Cholesterol - Direct	Direct Homogenous Enzymatic Colorimetric	32.2		1. No Risk: >65 2. Moderate Risk: 45-65 3. High Risk: <45
LDL-Cholesterol -Direct	Direct Homogenous Enzymatic Colorimetric	148.60	mg/dL	0-100
VLDL Cholesterol	Calculated	36.06	mg/dL	10-35
Chol/HDL Ratio		6.73		1.Low Risk: 3.3-4.4 2.Average Risk: 4.4-7.1 3.Moderate Risk: 7.1-11.0 4.High Risk: >11.0
Remark:		Test done on random sample at the patients/consultants request		
Liver Function Test (L.F.T.)				
Alkaline Phosphatase	Colorimetric IFCC	78.9	U/L	40-129
S.G.O.T (AST)	IFCC Without Pyridoxal 5 Phosphate	26.9	U/L	0-40
S.G.P.T (ALT)	IFCC Without Pyridoxal 5 Phosphate	35.3	U/L	0-50
Total Protein (Serum)	Colorimetric - Biuret Method	7.44	g/dL	6.4-8.3
Albumin, BCG	Colorimetric - Bromo-Cresol Green	4.43	g/dL	3.5-5.2
Globulin	Calculated	3.01	g/dL	1.9-3.5
Albumin/Globulin Ratio	Calculated	1.47		0.9-2
Serum Total Bilirubin	Colorimetric Diazo	0.35	mg/dL	0-1.2
Serum Direct Bilirubin	Colorimetric Diazo	0.15	mg/dL	0-0.4
Serum Indirect Bilirubin	Calculated	0.20	mg/dL	0-1

--- END OF REPORT ---

JAMILUDDIN SIDDIQUI
Verified By


 Dr. LAXMI LOKESH
 Consultant Pathologist

DEPARTMENT OF LABORATORY MEDICINE

HEMATOLOGY

Final Report

Patient Name :	MR. PRASHANT GHAWGHAWE	Order Date :	23/03/2024 10:41 AM
Age / Sex :	35 Years / Male	Sample Collection :	23/03/2024 10:48 AM
UHID :	WHN2.0000353692	Receiving Date Time :	23/03/2024 10:49 AM
Approval Date Time :	23/03/2024 11:58 AM	Report Date :	23/03/2024 11:51 AM
Primary Consultant :	DR. WOCKHARDT DOCTOR	Specimen :	EDTA Blood
Order No. :	54992		
Bill No. :	OCR3/24/0007245		

PARAMETER	METHOD	RESULT	UNIT	B.R.I
Complete Blood Count (With ESR)- EDTA Blood				
Haemoglobin	SLS Method	13.3	g%	11-15
Haematocrit	RBC Pulse Height Detection	45.0	%	40-50
MCV	Calculated	73.2	fl	83-101
MCH	Calculated	21.6	pg	27-32
MCHC	Calculated	29.6	g/dl	32-35
RBC Count	DC Detection	6.15	Million/ul	4.5-5.5
RDW-CV	Calculated	17.3	%	12-14
WBC Total Count (TLC)	Electrical Impedance	8800	Cells/cumm	4000 - 10000
Neutrophils	Hydrodynamic Focussing And Microscopy	58	%	40-80
Lymphocytes	Hydrodynamic Focussing And Microscopy	30	%	20-40
Monocytes	Hydrodynamic Focussing And Microscopy	08	%	2-10
Eosinophils	Hydrodynamic Focussing And Microscopy	04	%	0-6
Basophils	Hydrodynamic Focussing And Microscopy	00	%	0-2
Platelet Count	Hydrodynamic Focussing DC	302	Thou/Cumm	150-450
PDW	Calculated	7.8	fl	9.0-17
MPV	Calculated	7.9	fl	9.4-12.3
P-LCR	Calculated	11.1	%	13.0-43.0
PCT	Calculated	0.24	%	0.17-0.35
Blood ESR	Westergren Method	15	mm/hr	0-15

--- END OF REPORT ---

JAMILUDDIN SIDDIQUI
Verified By


 Dr. LAXMI LOKESH
 Consultant Pathologist
 MDPATH

Partial Reproduction of Report not permitted This Report Relates to Sample received by Laboratory
 * B.R.I - BIOLOGICAL REFERENCE INTERVAL ** Test not in Scope of Accreditation

DEPARTMENT OF LABORATORY MEDICINE

BIOCHEMISTRY


Final Report

Patient Name	: MR. PRASHANT GHAW/GHAWE	Order Date	: 23/03/2024 10:41 AM
Age / Sex	: 35 Years / Male	Sample Collection	: 23/03/2024 10:48 AM
UHID	: WHN2.0000353692	Receiving Date Time	: 23/03/2024 10:49 AM
Approval Date Time	: 23/03/2024 12:03 PM	Report Date	: 23/03/2024 11:56 AM
Primary Consultant	: DR. WOCKHARDT DOCTOR	Specimen	: EDTA Blood
Order No.	: 54992		
Bill No.	: OCR3/24/0007245		

PARAMETER	METHOD	RESULT	UNIT	B.R.I
Glycosylated Haemoglobin- EDTA Blood				
Glycosylated Haemoglobin	HPLC	5.9	%	Action required: 7.0-8.0% Good control: 6.5-7.0% Normal control: 4.6-6.4% Poor control: >8.0%
Estimated Mean glucose	Calculated	132.74	mg/dL	

--- END OF REPORT ---

JAMILUDDIN SIDDIQUI
Verified By


 Dr. LAXMI LOKESH
 Consultant Pathologist
 MDPATH

Partial Reproduction of Report not permitted. This Report Relates to Sample received by Laboratory
 * B.R.I : BIOLOGICAL REFERENCE INTERVAL ** Test not in Scope of Accreditation

DEPARTMENT OF LABORATORY MEDICINE

BIOCHEMISTRY


Final Report

Patient Name	: MR. PRASHANT GHAWGHAWE	Order Date	: 23/03/2024 10:41 AM
Age / Sex	: 35 Years / Male	Sample Collection	: 23/03/2024 01:08 PM
UHID	: WHN2.0000353692	Receiving Date Time	: 23/03/2024 01:08 PM
Approval Date Time	: 23/03/2024 02:53 PM	Report Date	: 23/03/2024 02:46 PM
Primary Consultant	: DR. WOCKHARDT DOCTOR	Specimen	: Plasma
Order No.	: 54992		
Bill No.	: OCR3/24/0007245		

<u>PARAMETER</u>	<u>METHOD</u>	<u>RESULT</u>	<u>UNIT</u>	<u>B.R.I</u>
Plasma Glucose Post Prandial	Enzymatic Hexokinase	106.94	mg/dl	70-140
Urine Sugar Post Prandial	Double Sequential Enzyme Reaction - GOD/ POD	NA		

--- END OF REPORT ---

SONAL BHAIARE
Verified By


Dr. LAXMI LOKESH
 Consultant Pathologist
 MDPATH

Partial Reproduction of Report not permitted. This Report Relates to Sample received by Laboratory
 * B.R.I : BIOLOGICAL REFERENCE INTERVAL ** Test not in Scope of Accreditation

DEPARTMENT OF LABORATORY MEDICINE

IMMUNOLOGY


Final Report

Patient Name	: MR. PRASHANT GHAWGHAWE	Order Date	: 23/03/2024 10:41 AM
Age / Sex	: 35 Years / Male	Sample Collection	: 23/03/2024 10:48 AM
UHID	: WHN2.0000353692	Receiving Date Time	: 23/03/2024 10:49 AM
Approval Date Time	: 23/03/2024 01:25 PM	Report Date	: 23/03/2024 12:48 PM
Primary Consultant	: DR. WOCKHARDT DOCTOR	Specimen	: Serum
Order No.	: 54992		
Bill No.	: OCR3/24/0007245		

PARAMETER	METHOD	RESULT	UNIT	B.R.I
T3 T4 TSH- Serum				
TOTAL T3	ECLIA	106.6	ng/dl	80-200
TOTAL T4	ECLIA	9.39	ug/dl	4.5-11.7
TSH	ECLIA	0.842	μIU/mL	0.27-4.2

--- END OF REPORT ---

JAMILUDDIN SIDDIQUI
Verified By


 Dr. LAXMI LOKESH
 Consultant Pathologist
 MDPATH

Partial Reproduction of Report not permitted This Report Relates to Sample received by Laboratory
 * B.R.I : BIOLOGICAL REFERENCE INTERVAL ** Test not in Scope of Accreditation

DEPARTMENT OF LABORATORY MEDICINE

CLINICAL PATHOLOGY

Final Report

Patient Name :	MR. PRASHANT GHAWGHAWE	Order Date :	23/03/2024 10:41 AM
Age / Sex :	35 Years / Male	Sample Collection :	23/03/2024 10:48 AM
UHID :	WHN2.0000353692	Receiving Date Time :	23/03/2024 10:49 AM
Approval Date Time :	23/03/2024 12:36 PM	Report Date :	23/03/2024 12:35 PM
Primary Consultant :	DR. WOCKHARDT DOCTOR	Specimen :	Urine
Order No. :	54992		
Bill No. :	OCR3/24/0007245		

PARAMETER	METHOD	RESULT	UNIT	B.R.I
Urine Routine				
Physical Examination				
Colour		Yellow		
Appearance		Clear		
Urinalyser (Roche UriSys 1100)				
Specific Gravity		1.030		1.003 - 1.035
Reaction (pH)		6		
Leukocytes, microscopy		02	/hpf	
Erythrocytes, microscopy		02	/hpf	
Nitrite, urinalyser		neg		
Protein, urinalyser		neg		
Glucose, urinalyzer		neg		
Ketone, urinalyser		neg		
Urobilinogen urinalyser		neg		
Billirubin uirnalyser		neg		

--- END OF REPORT ---

PRADIP TAMBE
Verified By


Dr. LAXMI LOKESH
 Consultant Pathologist
 MDPATH

Partial Reproduction of Report not permitted This Report Relates to Sample received by Laboratory
 * B.R.I - BIOLOGICAL REFERENCE INTERVAL ** Test not in Scope of Accreditation

DEPARTMENT OF RADIODIAGNOSTICS

Patient Name : MR. PRASHANT GHAWGHAWE
Age/Sex : 35 Yrs / Male **Order Date** : 23/03/2024 10:41 AM
UHID : WHN2.0000353692 **Referred by** :
Reporting Date : 23/03/2024 02:28 PM **Order No.** : 21247
Bill No. : OCR3/24/0007245

CHEST X-RAY PA VIEW :

Both lung fields are clear.

The costophrenic angles and domes of diaphragm appear normal.


No hilar or mediastinal lesion seen.

Cardiac silhouette is within normal limits.

Visualised bony thorax and soft tissues appear normal.

Impression:

Normal Chest X-Ray.


DR. VISHAL GAJBHIYE
M.B.B.S., M.D.
CONSULTANT - RADIOLOGIST



DEPARTMENT OF RADIODIAGNOSTICS

Patient Name	: MR. PRASHANT GHAWGHAWE	Order Date	: 23/03/2024 10:41 AM
Age/Sex	: 35 Yrs / Male	Referred by	:
UHID	: WHN2.0000353692	Order No.	: 21247
Reporting Date	: 23/03/2024 03:44 PM		
Bill No.	: OCR3/24/0007245		

USG ABDOMEN WITH PELVIS :

Real time sonography of the abdomen and pelvis was performed using the 3.5 MHz transducer.

The liver is normal in size and shows moderate increased echogenicity suggesting fatty infiltration. No focal parenchymal lesion noted.

Intrahepatic biliary tree and venous radicles are normal.

The portal vein and CBD appear normal in course and calibre.

The gall bladder is normal in size with a normal wall thickness and there are no calculi noted within.

The pancreas is normal in size and echotexture. No evidence of focal lesion or calcification or duct dilatation seen.

The spleen is normal in size and echotexture.

Both kidneys are normal in size, position and echogenicity.

Cortical thickness and corticomedullary differentiation are normal.

No hydronephrosis or calculi noted.

The urinary bladder is normal in contour, capacity and wall thickness. No vesical calculi noted.

The prostate is normal in size and homogenous in echotexture.

There is no evidence of ascites.

Impression :

Grade II fatty infiltration of liver.

DR. PREETI CHOUDHARY JAIN
M.B.B.S., D.M.R.E.
RADIOLOGIST