


8912

Name : Mr. ALAPAKA VINAYA KUMAR Address : MYSORE Plan : ARCOFEMI MEDIWHEEL MALE AHC CREDIT PAN INDIA OP AGREEMENT	Age : 33 Y Sex : M	UHID :CMYS.0000060290  OP Number :CMYSOPV123995 Bill No :CMYS-OCR-22877 Date : 29.03.2024 09:04
--	---	---

Sno	Service Type/ServiceName	Department
1	ARCOFEMI - MEDIWHEEL - FULL BODY ANNUAL PLUS MALE - 2D ECHO - PAN INDIA - FY2324	
1	GAMMA GLUTAMYL TRANSFERASE (GGT)	
2	2D ECHO	
3	LIVER FUNCTION TEST (LFT)	
4	GLUCOSE, FASTING	
5	HEMOGRAM + PERIPHERAL SMEAR	
6	DIET CONSULTATION <i>✓</i>	
7	COMPLETE URINE EXAMINATION	
8	URINE GLUCOSE(POST PRANDIAL)	H → 174
9	PERIPHERAL SMEAR	
10	EKG	
11	RENAL PROFILE/RENAL FUNCTION TEST (RFT/KFT)	W → 76.6
12	DENTAL CONSULTATION	
13	GLUCOSE, POST PRANDIAL (PP), 2 HOURS (POST MEAL)	BP → 120/70
14	URINE GLUCOSE(FASTING)	
15	HbA1c, GLYCATED HEMOGLOBIN	
16	X-RAY CHEST PA	
17	ENT CONSULTATION <i>✓</i>	
18	FITNESS BY GENERAL PHYSICIAN <i>✓</i>	
19	BLOOD GROUP ABO AND RH FACTOR	
20	LIPID PROFILE	
21	BODY MASS INDEX (BMI)	
22	OPHTHAL BY GENERAL PHYSICIAN	
23	ULTRASOUND - WHOLE ABDOMEN <i>→ P</i>	
24	THYROID PROFILE (TOTAL T3, TOTAL T4, TSH)	

Date : 29-03-2024
MR NO : CMYS.0000060290

Department : GENERAL
Doctor : ROHITH.H.K

Name : Mr. ALAPAKA VINAYA KUMAR

Registration No :

Age/ Gender : 33 Y / Male

Qualification :

Consultation Timing: 09:03

Height: 174cm	Weight: 76.6 kg	BMI:	Waist Circum:
Temp:	Pulse: 7	Resp:	B.P: 120/70

General Examination/
Allergies History

Cholelithiasis.
Single.

Clinical Diagnosis & Management Plan

Pt came for Annual Health check up
No fresh complaints
No L/O DM, HTN



Follow up date :

Doctor Signature
Apollo Clinic
Apollo Health & Lifestyle Ltd.
1 Floor 23, Kalidasa Road
MYSORE-570 002

Date : 29-03-2024

Department : GENERAL

MR NO : CMYS.0000060290

Doctor :

Name : Mr. ALAPAKA VINAYA KUMAR

Registration No : H Kaveri (CMYS.R

Age/ Gender : 33 Y / Male

Qualification : MS (Genl)

Consultation Timing: 09:03

Height : 174 cm	Weight : 76.6 kg	BMI :	Waist Circum :
Temp :	Pulse : 74	Resp :	B.P : 120/70

General Examination /
Allergies History

Clinical Diagnosis & Management Plan

Cause for muscular weakness unclear

(R) Ear wax (+)

(L) ear wax (+)

nose 17mm (+)

Ad

otology Ear down (+) - 10 days

i.v.v. PL

Follow up date :

Doctor Signature
Apollo Clinic
Apollo Health & Lifestyle Ltd.
1 Floor, 23, Kalidasa Road
MYSORE-570 002

Date : 29-03-2024

Department : GENERAL

MR NO : CMYS.0000060290

Doctor :

Name : Mr. ALAPAKA VINAYA KUMAR

Registration No :

Age/ Gender : 33 Y / Male

Qualification :

Consultation Timing: 09:03

Height :	Weight :	BMI :	Waist Circum :
Temp :	Pulse :	Resp :	B.P :

General Examination /
Allergies History

Clinical Diagnosis & Management Plan


O/E

76 / 67 ^{Initial} DC

ADU GR I

cat, sft

ADU - OP



Follow up date :

Joseph

Doctor Signature
Apollo Clinic
Apollo Health & Lifestyle Ltd.
1 Floor 23 Kalidasa Road
MYSORE-570 002

Date : 29-03-2024 Department : GENERAL (Ophthalmology)
 MR NO : CMYS.0000060290 Doctor :
 Name : Mr. ALAPAKA VINAYA KUMAR Registration No : Sujatha
 Age/ Gender : 33 Y / Male Qualification :

Consultation Timing: 09:03

Height :	Weight :	BMI :	Waist Circum :
Temp : NO	Pulse : 90/min.	Resp : 20/min.	B.P :

General Examination /
Allergies History

NO

Clinical Diagnosis & Management Plan

wearing Spectacle.
 NO fresh complaints.
 NO H/O T4 II DM / HTN.

vision (R) (L)
 Far NG NL
 Near wearing corrected
 colour NAD.

Follow up date :

Doctor Signature

Regular checks

Apollo Clinic
 Apollo Health & Lifestyle Ltd.
 1 Floor, 23, Kalidasa Road
 MYSORE-570 002

Date : 29-03-2024
MR NO : CMYS.0000060290



Department : GENERAL Dietetics
Doctor : Machava. B.P

Name : Mr. ALAPAKA VINAYA KUMAR

Registration No :

Age/ Gender : 33 Y / Male

Qualification : M.Sc Nutrition & Dietetics
PhD

Consultation Timing: 09:03

Height : 174cm	Weight : 76.6 kg	BMI : 25.3 kg/m ²	Waist Circum : 100 - 100
Temp :	Pulse :	Resp :	B.P : 120/70

General Examination /
Allergies History

Total cholesterol - 220
NON HDL - 170
LDL - 144.87

Clinical Diagnosis & Management Plan

dxs - cholelithiasis

⇒ Advised low fat diet with fiber rich foods.

⇒ Dietary guidelines sheet is given.

Follow up date :

Doctor Signature

29/3/2024

Apollo Clinic
23, 1st Floor,
Kalidasa Road, Mysore - 02
Ph : 0821-4006040/41

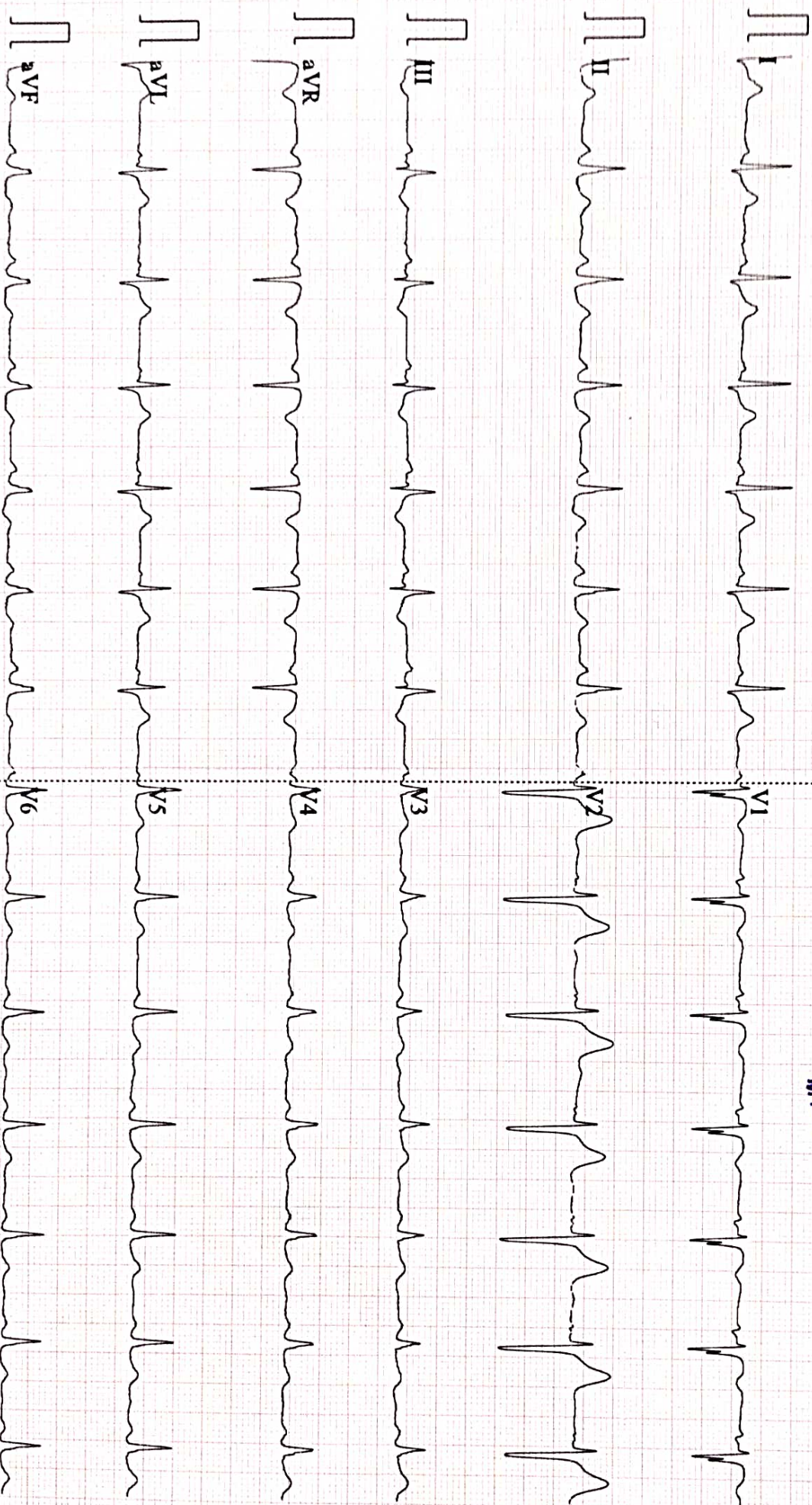
ID: 60290
MR ALAPAKA VINAYA KUMAR
Male 33Years
174cm 76kg 120/70 mmHg

29-03-2024 10:59:10 AM

Diagnosis Information:

Unconfirmed Report.

Apollo Clinic & Lifestyle Ltd.
Apollo Health & Lifestyle Road
1 Floor 23, Kallidasa Road
MYSORE-570 002



Patient Name	: Mr. ALAPAKA VINAYA KUMAR	Age	: 33 Y M
UHID	: CMYS.0000060290	OP Visit No	: CMYSOPV123995
Reported on	: 29-03-2024 15:35	Printed on	: 29-03-2024 15:36
Adm/Consult Doctor	:	Ref Doctor	: SELF

DEPARTMENT OF RADIOLOGY

X-RAY CHEST PA

Both lung fields and hila are normal .
No obvious active pleuro-parenchymal lesion seen .
Both costophrenic and cardiophrenic angles are clear .
Both diaphragms are normal in position and contour .
Thoracic wall and soft tissues appear normal.

IMPRESSION :NORMAL STUDY .

Printed on:29-03-2024 15:35

---End of the Report---



Dr. CHETAN HOLEPPAGOL
MBBS, DNB(RADIO DIAGNOSIS)
Radiology

Apollo Health and Lifestyle Limited

(CIN: U65110TG0000PLC115819)

Regd Office: 110-6/2, Ashoka Raghupathi Chambers, 5th Floor, Begumpet, Hyderabad, Telangana - 500 016

Ph No: (040) 4904 7777 Fax No: 4904 7744 | Email ID: enquiry@apollohl.com | www.apollohl.com

APOLLO CLINICS NETWORK KARNATAKA

Bangalore (Basavanagudi | Bellandur | Electronic City | Fraser Town | HSR Layout | Indira Nagar | JP Nagar | Kundalahalli | Koramangala | Marjapur Road) | Mysore (VV Mohalla)

Online appointments: www.apolloclinic.com

TO BOOK AN APPOINTMENT

 **1860 500 7788**

Patient Name: Mr. ALAPAKA VINAYA KUMAR	Date: 29.03.2024	Referring Doctor: Self
Age / Sex :33yrs /Male	UHID :060290	
ULTRASONOGRAPHY – ABDOMEN & PELVIS		

LIVER: It is normal in size, outline and echotexture. No focal lesions seen. IHBR are not dilated. CBD and Portal vein are normal.

GALL BLADDER: It is distended. A calculus measuring 8.2mm is seen in the GB.

SPLEEN: It is normal in size, outline and echopattern. No e/o focal lesions.

PANCREAS: It is normal in size, outline and echopattern.

RIGHT KIDNEY: It measures 9.6 cm with parenchymal thickness of 1.3 cm. It is normal in size, outline and echotexture. No e/o calculus or hydronephrosis seen.

LEFT KIDNEY: It measures 10 cm with parenchymal thickness of 1.3 cm. It is normal in size, outline and echotexture. No e/o calculus or hydronephrosis seen.

URINARY BLADDER: It is well distended. The UB wall is normal. No e/o calculi.

PROSTATE: It is normal in size, outline and echotexture.

No e/o free fluid in the abdomen.

IMPRESSION: CHOLELITHIASIS.


Dr. Raghuveer Suhas Prasad, DNB
Consultant Radiologist.

Apollo Health and Lifestyle Limited

ICMR: UB5110TG2000PLC1158191
Kings Office: 1, 10, 11 & 12, A. Vinaya Raghupathi Chambers, 5th Floor, Begumpet, Hyderabad, Telangana - 500 016
Ph. No: 044-4604 7777 | Fax No: 4604 7744 | E-mail ID: enquiry@apolloh.com | www.apolloh.com

APOLLO CLINICS NETWORK KARNATAKA

Bangalore: Susevarajugudi | Bellandur | Electronic City | Fraser Town | MSR Layout | Indira Nagar | JP Nagar | Kundalahalli |
Koramangala | Sarjapur Road | Mysore: (VV Mahalle)

Online appointments: www.apolloclinic.com

TO BOOK AN APPOINTMENT

1860 500 7788

Patient's Name : Mr. ALAPAKA VINAYA KUMAR	Age & Sex: 33Yrs /Male
Date : 29.03.2024	UHID No:0060290

2D ECHOCARDIOGRAPHY STUDY

Impression:

- Normal chambers and valves
- No regional wall motion abnormality
- Normal left ventricular systolic function. EF 64 %
- No clots. No pericardial effusion

Findings

Left Ventricle:	No RWMA
Right Ventricle	Normal
Left Atrium	Normal
Right Atrium	Normal
Aorta	Normal
Pulmonary Artery	Normal
IAS	Intact
IVS	Intact
Valves	Normal
Pericardium	Normal
Doppler	Normal

Apollo Health and Lifestyle Limited

10th Floor, LBS Lotus Green Plaza, FSR 19

Regd. Office: 1-10-60-62, Anjuna Rajgopurthi Chambers, 5th Floor, Begumpet, Hyderabad, Telangana - 500 014

Ph. No: 041-4344 7777 Fax No: 4344 7744 | Email: enquiry@apollohd.com | www.apollohd.com

APOLLO CLINICS NETWORK KARNATAKA

Bangalore: Basavanagudi | Bellandur | Electronic City | Fraser Town | HSR Layout | Indira Nagar | JP Nagar | Koradihalli | Koramangala | Sarjapur Road | Mysore (VV Mohalla)

Online appointments: www.apollohd.com

TO BOOK AN APPOINTMENT

 **1860 500 7788**

Patient's Name : Mr. ALAPAKA VINAYA KUMAR	Age & Sex; 33 Yrs / Male
Date : 29.03.2024	UHID No:0060290

Measurements

AO : 3.0 cm
LA : 2.7 cm

RV : 2.5 cm
LVIDd : 4.49 cm
LVIDs : 2.90 cm
IVSd : 0.90 cm
IVSs : 1.36 cm
PWd : 0.90 cm
PWs : 1.31 cm
EF : 64.0 %
FS : 34.0 %

Doppler

	MV		TV		AV		PV	
E	0.82 m/s	E	---	m/s	V max	1.04 m/s	V max	0.91 m/s
A:	0.32 m/s	A	---	m/s				

Dr. GURU PRASAD. B. V, MBBS, PGDCC
CONSULTANT – NON-INVASIVE CARDIOLOGY



Dr. GURU PRASAD. B. V
MBBS, PGDCC (CARDIO)
CCIM, CCF, CCEPM, MACE, CCEBIM
Consultant - Non Invasive Cardiology
EMC No: 69045

Apollo Health and Lifestyle Limited

(CIN: UAS110TG2000PLE115819)

Regd. Office: 1-10-60-62, Ashoka Raghupathi Chambers, 5th Floor, Begumpet, Hyderabad, Telangana - 500 016

Ph: No. (04) 4904 7777 Fax No. 4904 7744 | Email ID: enquiry@apollohl.com | www.apollohl.com

APOLLO CLINICS NETWORK KARNATAKA

Bangalore (Basavanagudi | Bellandur | Electronic City | Fraser Town | HSR Layout | Indira Nagar | JP Nagar | Kundalahalli | Koramangala | Sarajapur Road) | Mysore (VV Mohalla)

Online appointments: www.apolloclinic.com

TO BOOK AN APPOINTMENT

1860 500 7788