


CERTIFICATE OF MEDICAL FITNESS

This is to certify that I have conducted the clinical examination of
Mrs. Upadrashta Dhawan on 23/03/24.....

After reviewing the medical history and on clinical examination it has been found that
he/ she is

	<u>Tick</u>
<ul style="list-style-type: none">• Medically Fit	<input checked="" type="checkbox"/>
<ul style="list-style-type: none">• Fit with Restrictions/ Recommendations <p>Though following restrictions have been revealed in my opinion, these are not impediments to the job.</p> <p>1.</p> <p>2.</p> <p>3.</p> <p>However the candidate should follow the advice medication that has been communicated to him/her.</p> <p>Review after</p>	
<ul style="list-style-type: none">• Currently Unfit. <p>Review after.....recommended.</p>	
<ul style="list-style-type: none">• Unfit	



Dr. K. VAISHNAVI
MBBS
Regd. No. TSMC/12106

Dr. Vaishnavi
Reg No :12106
Consultant physician
Apollo Clinic
A S Rao Nagar

POWER PRESCRIPTION

NAME: *U. Dorani*

GENDER: M/F

DATE: *22/03/24*

AGE: *32*

UHID:

RIGHT EYE

	SPH	CYL	AXIS	VISION
DISTANCE	-	-	-	<i>6/6</i>
NEAR	-	-	-	<i>6/6</i>

LEFT EYE

	SPH	CYL	AXIS	VISION
DISTANCE	-	-	-	<i>6/6</i>
NEAR	-	-	-	<i>6/6</i>

COLOUR VISION : _____

DIAGNOSIS : *normal*

OTHER FINDINGS :

INSTRUCTIONS :

[Signature]
SIGNATURE

Patient Name	: Mrs. UPADRASTA DHARANI	Age/Gender	: 32 Y/F
UHID/MR No.	: CASR.0000186690	OP Visit No	: CASROPV222749
Sample Collected on	:	Reported on	: 27-03-2024 15:15
LRN#	: RAD2275996	Specimen	:
Ref Doctor	: SELF		
Emp/Auth/TPA ID	: bobE16698		

DEPARTMENT OF RADIOLOGY

ULTRASOUND - WHOLE ABDOMEN

Liver appears normal in size and echotexture. No focal lesion is seen. PV and CBD normal. No dilatation of the intrahepatic biliary radicals.

Gall bladder is well distended. No evidence of calculus. Wall thickness appears normal. No evidence of periGB collection. No evidence of focal lesion is seen.

Spleen appears normal. No focal lesion seen. Splenic vein appears normal.

Pancreas appears normal in echopattern. No focal/mass lesion/calcification. No evidence of peripancreatic free fluid or collection. Pancreatic duct appears normal.

Right kidney:100x42 mm **Left kidney:106x44 mm**

Both the kidneys appear normal in size, shape and echopattern. Cortical thickness and CM differentiation are maintained. No calculus / hydronephrosis seen on either side.

Small umbilical wall defect largest measuring **6mm** noted with herniation of omentum and omental fat as its content

Urinary Bladder is well distended and appears normal. No evidence of any wall thickening or abnormality.

Uterus:43x44 mm appears normal in size. It shows normal shape & echo pattern. Endometrial thickness measures **9.6 mm**

Right ovary:26x21 mm **Left kidney:23x24 mm**

Both ovaries appear normal in size, shape and echotexture. No evidence of any adnexal pathology noted.


IMPRESSION:-Thickened Endometrium.

Small Umbilical Hernia

Suggested clinical correlation and further evaluation if necessary.

Patient Name : Mrs. UPADRASTA DHARANI

Age/Gender : 32 Y/F



Dr. PRAVEEN BABU KAJA
Radiology

Patient Name	: Mrs. UPADRASTA DHARANI	Age	: 32 Y/F
UHID	: CASR.0000186690	OP Visit No	: CASROPV222749
Reported By:	: Dr. MRINAL .	Conducted Date	: 25-03-2024 17:08
Referred By	: SELF		

ECG REPORT

Observation :-

1. Normal Sinus Rhythm.
2. Heart rate is 73 beats per minutes.
3. No pathological Q wave or ST-T changes seen.
4. Normal P,QRS,T waves and axis.
5. No evidence of chamber, hypertrophy or enlargement seen.

Impression:

NORMAL RESTING ECG.

----- END OF THE REPORT -----

Dr. MRINAL .



PHYSICAL EXAMINATION FORM

Apollo Clinic

Apollo Clinic
Laxmi Nagar, Connaught Place

Date 22/3/24.

UHID 186698

Name Mrs. V Phani ^Q Age 32 Yr

Height Cms

Weight Kgs

Chest Measurement (in)cm (out)cm


Waist cm HIP

Pulse Bt/Min BMI kgs/cm²

BP mm/Hg SPO2 %

Apollo Clinic, A.S. Rao Nagar.

ORAL EXAMINATION FORM



Date: 28/3/2024

Patient ID: _____ MHC

Patient Name: Ms. Upadista Dhasani Age: 32 Sex: Male Female

Chief Complaint: General Cracking

Medical History:

Drug Allergy:

Medication currently taken by the Guest:

Initial Screenign Findings:

Dental Caries: +

Missing Teeth: -

Impacted Teeth: -

Attrition / Abrasion: -

Bleeding: ++

Pockets / Recession: -

Calculus / Stains: ++

Mobility: -

Restored Teeth: -

Non - restorable Teeth for extraction / Root Stumps: -

Malocclusion:

Others:

Advice:- ① Advised oral prophylaxis & follow up

Doctor ② Advised follow
Name & Signature: D. Mounik

Patient Name : Mrs. UPADRASTA DHARANI Age : 32 Y/F
UHID : CASR.0000186690 OP Visit No : CASROPV222749
Conducted By: : Dr. SHILPI MOHAN Conducted Date : 24-03-2024 13:14
Referred By : SELF

2D-ECHO WITH COLOUR DOPPLER

Dimensions:

Ao (ed) 2.9 CM
LA (es) 2.6 CM
LVID (ed) 4.6 CM
LVID (es) 2.5 CM
IVS (Ed) 1.1 CM
LVPW (Ed) 0.9 CM
EF 68 %
%FD 37 %

MITRAL VALVE : NORMAL
AML NORMAL
PML NORMAL
AORTIC VALVE NORMAL
TRICUSPID VALVE NORMAL
RIGHT VENTRICLE NORMAL
INTER ATRIAL SEPTUM INTACT
INTER VENTRICULAR SEPTUM INTACT
AORTA NORMAL
RIGHT ATRIUM NORMAL
LEFT ATRIUM NORMAL
Pulmonary Valve NORMAL
PERICARDIUM NORMAL

MITRAL: E: 0.8 m/sec A: 1.0 m/sec
AJV:1.3 m/sec
PJV:1.0 m/sec

Patient Name	: Mrs. UPADRASTA DHARANI	Age	: 32 Y/F
UHID	: CASR.0000186690	OP Visit No	: CASROPV222749
Conducted By:	: Dr. SHILPI MOHAN	Conducted Date	: 24-03-2024 13:14
Referred By	: SELF		

IMPRESSION:

NORMAL CHAMBER DIMENSION.

NORMAL VALVES.

NO RWMA.

LVEF:68%.

NO MR/AR/TR/PAH.

GRADE I DIASTOLIC DYSFUNCTION.

NO CLOTS/VEGETATION.

NO PERICARDIAL EFFUSION.



Dr. SHILPI
MOHAN

Patient Name : Mrs. UPADRASTA DHARANI

Age/Gender : 32 Y/F

UHID/MR No. : CASR.0000186690

OP Visit No : CASROPV222749

Sample Collected on :

Reported on : 22-03-2024 20:40

LRN# : RAD2275996

Specimen :

Ref Doctor : SELF

Emp/Auth/TPA ID : bobE16698

DEPARTMENT OF RADIOLOGY

X-RAY CHEST PA

Both lung fields and hila are normal .

No obvious active pleuro-parenchymal lesion seen .


Both costophrenic and cardiophrenic angles are clear .

Both diaphragms are normal in position and contour .

Thoracic wall and soft tissues appear normal.

CONCLUSION :

No obvious abnormality seen



Dr. PRAVEEN BABU KAJA
Radiology

Asraonagar Apolloclinic

From: Upadrasta Dharani <upadrastadharani@gmail.com>
Sent: 22 March 2024 08:12
To: Asraonagar Apolloclinic
Subject: Fwd: Health Check up Booking Confirmed Request(bobE16698),Package Code-PKG10000377, Beneficiary Code-289714

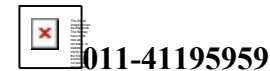
FYI

----- Forwarded message -----

From: Upadrasta Dharani <upadrastadharani@gmail.com>
Date: Fri, 22 Mar 2024, 7:51 am
Subject: Fwd: Health Check up Booking Confirmed Request(bobE16698),Package Code-PKG10000377, Beneficiary Code-289714
To: <asraonagar@apolloclinic.com>

----- Forwarded message -----

From: Mediwheel <wellness@mediwheel.in>
Date: Tue, Mar 19, 2024, 4:55 PM
Subject: Health Check up Booking Confirmed Request(bobE16698),Package Code-PKG10000377, Beneficiary Code-289714
To: <upadrastadharani@gmail.com>
Cc: <customercare@mediwheel.in>



Dear Upadrasta Dharani,

We are pleased to confirm your health checkup booking request with the following details.

Hospital Package Name : Mediwheel Full Body Health Annual Plus Check

Patient Package Name : Mediwheel Full Body Health Checkup Female Above 40

Name of Diagnostic/Hospital : Apollo Clinic - AS Rao Nagar

Address of Diagnostic/Hospital- : A-12, # 1-9-71/A/12/B, Rishabh heights, above vodafone store, beside KFC, A S Rao Nagar, Hyderabad -500062

City : Hyderabad

State :

Pincode : 500062

Appointment Date : 22-03-2024

Confirmation Status : Booking Confirmed

Preferred Time : 09:00 am - 09:30 am

Booking Status : Booking Confirmed

Member Information		
Booked Member Name	Age	Gender
MS. UPADRASTA DHARANI	32 year	Female

Note - Please note to not pay any amount at the center.

Instructions to undergo Health Check:

- Please ensure you are on complete fasting for 10-To-12-Hours prior to check.
- During fasting time do not take any kind of medication, alcohol, cigarettes, tobacco or any other liquids (except Water) in the morning.

- Bring urine sample in a container if possible (containers are available at the Health Check centre).
- Please bring all your medical prescriptions and previous health medical records with you.
- Kindly inform the health check reception in case if you have a history of diabetes and cardiac problems.

For Women:

- Pregnant Women or those suspecting are advised not to undergo any X-Ray test.
- It is advisable not to undergo any Health Check during menstrual cycle.

Request you to reach half an hour before the scheduled time.

In case of further assistance, Please reach out to Team Mediwheel.

Thanks,
Mediwheel Team

Please Download Mediwheel App



You have received this mail because your e-mail ID is registered with **Arcofemi Healthcare Limited** This is a system-generated e-mail please don't reply to this message.

Please visit to our [Terms & Conditions](#) for more informaion. [Click here](#) to unsubscribe.

@ 2024 - 25, Arcofemi Healthcare Pvt Limited.(Mediwheel)



बैंक ऑफ़ बड़ोदा
Bank of Baroda




नाम
Name

Dharani Upadrasta

E.C. No.

109962



जारीकर्ता प्राधिकारी

Issuing Authority

U. Dharani

धारक के हस्ताक्षर

Signature of Notee