


Name : Mr. MAHESH M Address : GUNDLUPET Plan : ARCOFEMI MEDIWHEEL MALE AHC CREDIT PAN INDIA OP AGREEMENT	Age : 47 Y Sex : M	UHID :CMYS.0000060172  * CMYS . 0 0 0 0 0 6 0 1 7 2 * OP Number :CMYSOPV123745 Bill No :CMYS-OCR-22767 Date : 23.03.2024 07:42
---	---	---

Sno	Service Type/ServiceName	Department
1	ARCOFEMI - MEDIWHEEL - FULL BODY ANNUAL PLUS ABOVE 50Y MALE - 2D ECHO - PAN INDIA - FY2324	
1	GAMMA GLUTAMYL TRANSFERASE (GGT)	
2	PROSTATIC SPECIFIC ANTIGEN (PSA TOTAL)	
3	2D ECHO	
4	LIVER FUNCTION TEST (LFT)	
5	GLUCOSE, FASTING	
6	HEMOGRAM + PERIPHERAL SMEAR	
7	DIET CONSULTATION → P	HGT 164
8	COMPLETE URINE EXAMINATION	WGT 63.9
9	URINE GLUCOSE(POST PRANDIAL)	
10	PERIPHERAL SMEAR	
11	ECG	Bp 7 220/120
12	RENAL PROFILE/RENAL FUNCTION TEST (RFT/KFT)	
13	DENTAL CONSULTATION	
14	GLUCOSE, POST PRANDIAL (PP), 2 HOURS (POST MEAL)	
15	URINE GLUCOSE(FASTING)	
16	HbA1c, GLYCATED HEMOGLOBIN	
17	X-RAY CHEST PA	
18	ENT CONSULTATION → P	
19	FITNESS BY GENERAL PHYSICIAN → P	
20	BLOOD GROUP ABO AND RH FACTOR	
21	LIPID PROFILE	
22	BODY MASS INDEX (BMI)	
23	OPHTHAL BY GENERAL PHYSICIAN	
24	ULTRASOUND - WHOLE ABDOMEN	
25	THYROID PROFILE (TOTAL T3, TOTAL T4, TSH)	

Patient Name	: Mr. MAHESH M	Age	: 47 Y M
UHID	: CMYS.0000060172	OP Visit No	: CMYSOPV123745
Reported on	: 23-03-2024 15:00	Printed on	: 23-03-2024 15:01
Adm/Consult Doctor	:	Ref Doctor	: SELF

DEPARTMENT OF RADIOLOGY

X-RAY CHEST PA

Both lung fields and hila are normal .

No obvious active pleuro-parenchymal lesion seen .

Both costophrenic and cardiophrenic angles are clear .


Both diaphragms are normal in position and contour .

Thoracic wall and soft tissues appear normal.

IMPRESSION :NORMAL STUDY .

Printed on:23-03-2024 15:00

---End of the Report---


Dr. CHETAN HOLEPPAGOL
MBBS, DNB(RADIO DIAGNOSIS)
Radiology

Apollo Health and Lifestyle Limited

(CIN: U65110TG2000PLC115819)

Head Office: 1-1D to D2, Ashoka Raghupathi Chambers, 5th Floor, Begumpet, Hyderabad, Telangana - 500 016

Ph. No: 080 4904 7777 Fax No: 4904 7744 | Email ID: enquiry@apolloh.com | www.apolloh.com

APOLLO CLINICS NETWORK KARNATAKA

Bangalore: Basavanagudi | Bellandur | Electronic City | Fraser Town | HSR Layout | Indira Nagar | JP Nagar | Kundalahalli |
Koramangala | Marigutti Road | Mysore (VV Mohalla)

Online appointments: www.apolloclinic.com

TO BOOK AN APPOINTMENT

 **1860 500 7788**

Patient's Name : Mr.Mahesh M	Age & sex :47 Yrs /Male
Date : 23.03.2024	UHID No :60172

2D ECHOCARDIOGRAPHY STUDY

Impression:

- Concentric left ventricular hypertrophy
- Dilated LV with global hypokinesia
- Moderate left ventricular systolic dysfunction. EF 33 %
- Mild eccentric MR
- No clots. No pericardial effusion

Findings

Left Ventricle:	Dilated. Global hypokinesia . Concentric LVH
Right Ventricle	Normal
Left Atrium	Mildly dilated
Right Atrium	Normal
Aorta	Normal
Pulmonary Artery	Normal
IAS	Intact
IVS	Intact
Valves	Normal
Pericardium	Normal
Doppler	Mild eccentric MR



Apollo Health and Lifestyle Limited
Dr. C.B. KESHAVAMURTHY MD, DM, DNB

CONSULTANT CARDIOLOGIST

APOLLO CLINICS NETWORK KARNATAKA
Bangalore | Basavanagudi | Bellandur | Electronic City | Fraser Town | HSR Layout | Indira Nagar | JP Nagar | Kundalahalli |
Koramangala | Marappur Road | Mysore | VV Mohalla |
Online appointments: www.apollohospitals.com

TO BOOK AN APPOINTMENT

 **1860 500 7788**

Patient's Name : Mr. Mubesh M

Age & sex : 47 Yrs / Male

Date : 23.03.2024

UHID No : 40172

Measurements

AO : 2.66 cm
 LA : 3.89 cm

 RV : 1.60 cm
 LVIDd : 5.78 cm
 LVIDs : 4.86 cm
 IVSd : 1.37 cm
 IVSs : 1.46 cm
 PWd : 1.40 cm
 PWs : 1.51 cm
 EF : 83.0 %
 FS : 15.0 %

Doppler

MV	TV	AV	PV
E : 0.83 m/s	E : 0.46 m/s	V max : 1.17 m/s	V max : 0.51 m/s
A : 0.01 m/s	A : 0.54 m/s		
MR 3/4	TR Nil	AR Nil	PR Nil

Dr. C.B. KESHAVAMURTHY MD, DM, DNB
CONSULTANT CARDIOLOGIST

Dr. C.B. Keshavamurthy, MD, DM, DNB, is a Consultant Cardiologist at Apollo Hospitals, Chennai. He has completed his MBBS from Madurai Kamaraj University, Madurai, and his MD, DM, DNB from the Government Medical College, Chennai. He is a member of the Indian Association of Physicians, Indian Association of Cardiovascular Physicians, and Indian Association of Hospital Administrators. He is also a member of the Tamil Nadu State Medical Council. He has been practicing as a Consultant Cardiologist at Apollo Hospitals, Chennai, since 1995. He has a vast experience in the management of various cardiac conditions including Coronary Artery Disease, Heart Failure, Hypertension, and Arrhythmias. He is also involved in teaching and research in the field of Cardiology. He can be contacted at Apollo Hospitals, Chennai, at 044-2669-4000.

1860 500 7885

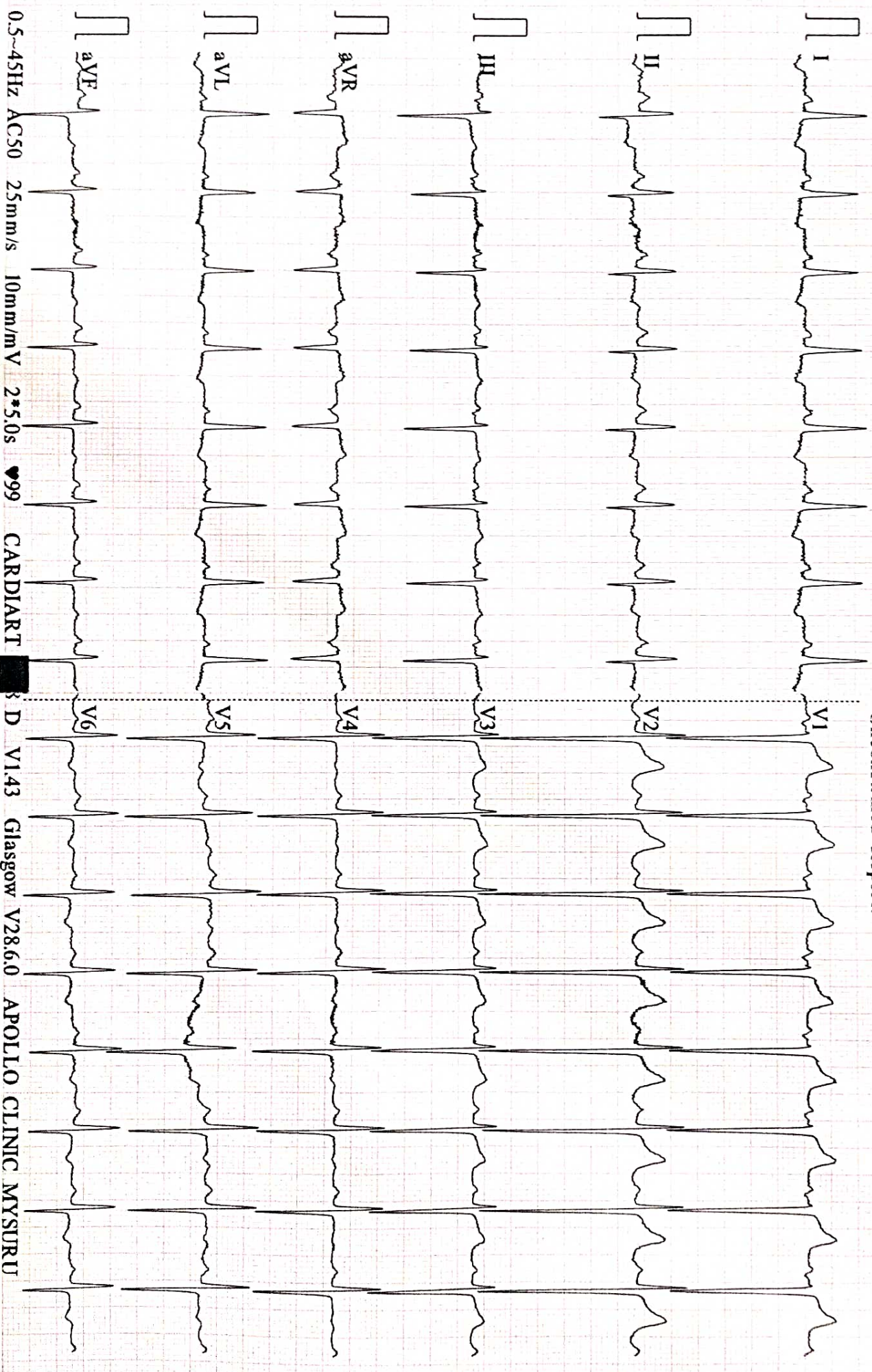ID: 60172
MR MAHESH M
Male 47Years
164cm 63kg 220/120mmHg

23-03-2024 09:36:05 AM

Diagnosis Information:

Apollo Clinic
23, 1st Floor,
Kallidasa Road, Mysore - 02
Ph : 0821-4006040/41

Unconfirmed Report.



0.5-45Hz AC50 25mm/s 10mm/mV 2*5.0s 99 CARDIART