

Patient Name	: Mr. RANGABASHYAM M	Age	: 52 Y/M
UHID	: CANN.0000235113	OP Visit No	: CANNOPV398895
Reported By:	: DR ARULNIDHI	Conducted Date	: 30-03-2024 15:36
Referred By	: SELF		

ECG REPORT

Observation :-

1. Normal Sinus Rhythm.
2. Heart rate is 94 beats per minutes.

Impression:

NORMAL RESTING ECG.

----- END OF THE REPORT -----

DR ARULNIDHI

Patient Name : Mr. RANGABASHYAM M

Age/Gender : 52 Y/M

UHID/MR No. : CANN.0000235113

OP Visit No : CANNOPV398895

Sample Collected on :

Reported on : 29-03-2024 15:29

LRN# : RAD2285625

Specimen :

Ref Doctor : SELF

Emp/Auth/TPA ID : bobE17786

DEPARTMENT OF RADIOLOGY

ULTRASOUND - WHOLE ABDOMEN

Liver is normal in size and show fatty changes.(Grade - I)
Intra and extra hepatic biliary passages are not dilated.

Gall bladder appears normal with no evidence of calculus.
Wall thickness appear normal.

Pancreas and spleen appear normal.
Spleen measures 9.4cms.

Portal and splenic veins appear normal.
No evidence of ascites or lymphadenopathy.

Diaphragmatic movements are satisfactory.
There is no evidence of sub diaphragmatic pathology or pleural effusion.

Right kidney measures 10.4 x 4.6cms.
Left kidney measures 9.6 x 4.7cms.
Both kidneys show normal echopattern with no evidence of calculi or calyceal dilatation.

Prostate measures 3.6 x 2.9 x 2.8cms volume 16cc and shows normal echopattern.
Seminal vesicles appear normal.
Bladder is normal in contour.

IMPRESSION:

***GRADE - I FATTY LIVER.**



Patient Name : Mr. RANGABASHYAM M

Age/Gender : 52 Y/M

DISCLAIMER: THIS ULTRASOUND SCREENING STUDY IS BASED ON SOUND WAVES AND REFLECTION. NOT A DIRECT VISUALISATION OF ORGANS. BASED ON PATIENT HABITUS, BOWEL GAS OBSCURATION AND OTHER FACTORS, MANY CONDITIONS MAY NOT BE PICKED UP BY US STUDY AND SHOULD BE TREATED WITH CLINICAL CORRELATION. NOT AN MLC DOCUMENT. MANY INCIDENTAL FINDINGS OF LOW PRIORITY MIGHT NOT BE MENTIONED AS IT IS NOT A FOCUSED STUDY.

Dr. ASHIQ MOHAMMED JEFFREY

MD

Radiology

Patient Name : Mr. RANGABASHYAM M

Age/Gender : 52 Y/M

UHID/MR No. : CANN.0000235113

OP Visit No : CANNOPV398895

Sample Collected on :

Reported on : 29-03-2024 14:52

LRN# : RAD2285625

Specimen :

Ref Doctor : SELF

Emp/Auth/TPA ID : bobE17786

DEPARTMENT OF RADIOLOGY

X-RAY CHEST PA

Lung fields are clear.

Cardio thoracic ratio is normal.

Apices, costo and cardiophrenic angles are free.

Cardio vascular shadow and hila show no abnormal feature.

Bony thorax shows no significant abnormality.

Domes of diaphragm are well delineated.

IMPRESSION:

***NO SIGNIFICANT ABNORMALITY DETECTED.**


Dr. ASHIQ MOHAMMED JEFFREY

MD

Radiology

CANN-23543

OLR-101736



M.R.



LETTER OF APPROVAL / RECOMMENDATION

To,

The Coordinator,
Mediwheel (Arcofemi Healthcare Limited)
Helpline number: 011- 41195959

Dear Sir / Madam,

Sub: Annual Health Checkup for the employees of Bank of Baroda

This is to inform you that the following employee wishes to avail the facility of Cashless Annual Health Checkup provided by you in terms of our agreement.

PARTICULARS	EMPLOYEE DETAILS
NAME	MR. RANGABASHYAM M
EC NO.	175970
DESIGNATION	SINGLE WINDOW OPERATOR A
PLACE OF WORK	CHENNAI,KILPAUK
BIRTHDATE	19-01-1972
PROPOSED DATE OF HEALTH CHECKUP	29-03-2024
BOOKING REFERENCE NO.	23M175970100104376E

This letter of approval / recommendation is valid if submitted along with copy of the Bank of Baroda employee id card. This approval is valid from **21-03-2024** till **31-03-2024** The list of medical tests to be conducted is provided in the annexure to this letter. Please note that the said health checkup is a **cashless facility** as per our tie up arrangement. We request you to attend to the health checkup requirement of our employee and accord your top priority and best resources in this regard. The EC Number and the booking reference number as given in the above table shall be mentioned in the invoice, invariably.

We solicit your co-operation in this regard.

Yours faithfully,

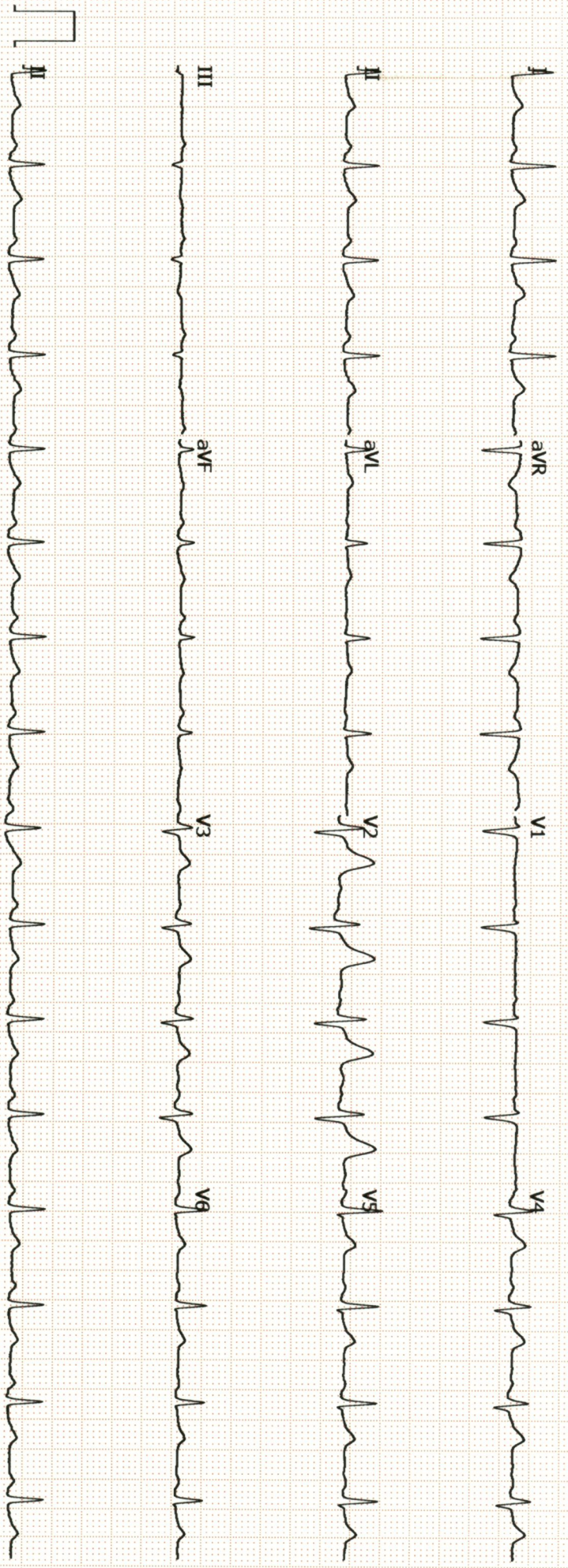
Sd/-

Chief General Manager
HRM Department
Bank of Baroda

(Note: This is a computer generated letter. No Signature required. For any clarification, please contact Mediwheel (Arcofemi Healthcare Limited))

Technician:
Ordering Ph:
Referring Ph:
Attending Ph:

QRS : 82 ms
QT / QTcbaz : 352 / 440 ms
PR : 134 ms
P : 98 ms
RR / PP : 636 / 638 ms
P / QRS / T : 53 / 24 / 28 degrees



ENT check up

Rangabashyam

52/M

29/3/24

Height:	Weight:	BMI:	Waist Circum:
Temp:	Pulse:	Resp:	B.P:

General Examination / Allergies
History

q. freq colds.
q. vertigo

o/e
DSL
rhinitis
Pharyngitis

Imp: DNS ± sinusitis / vertigo

Adv: Audiometry
Tympanometry
VNG
X-ray PNS



Follow up date:

Doctor Signature & Stamp

Convenient & reliable. Complete diagnostic services for the entire family. All under one roof.

Mr. Rangabashyam

52/11

29/3/20

Height:	Weight:	BMI:	Waist Circum:
Temp:	Pulse:	Resp:	B.P:

General Examination / Allergies
History

Re

- Adv RC of crown +7
- Adv crown +7
- Adv replacement +6
- Adv scaling

↓
Dr. G.

Follow up date:

Doctor Signature & Stamp

Convenient & reliable. Complete diagnostic services for the entire family. All under one roof.

Name:.....*Rangabashyam*.....
 Occupation:.....
 Age:.....*52y*..... Sex: Male Female
 Address:.....
Ph:.....

Date:.....*29/3/24*..... Reg. No.:.....*235113*.....
 Ref. Physician:.....
 Copies to:.....

REPORT ON OPHTHALMIC EXAMINATION

History: *Existing glass used past 30 years.*

Present Complaint: *Comfortable with present glasses with glass PE 6/6 NB.*

ON EXAMINATION:

	RE	LE
Ocular Movements :		Full
Anterior Segment :	Full	
Intra-Ocular-Pressure :		
Visual Acuity: D.V. :		N
Without Glass :	N	
With Glass :		6/9 ^P
N.V. :	6/9	
Visual Fields :		
Fundus :	N10	N10
Impression :		Full
Advice :	Full	
Colour Vision :	<i>Reading partial</i>	<i>colours referred evaluation</i>

OPHTHALMOLOGY / OPTOMETRIST

Patient Name : Mr. RANGABASHYAM M Age : 52 Y/M
UHID : CANN.0000235113 OP Visit No : CANNOPV398895
Conducted By: : Dr. RAKESH P GOPAL Conducted Date : 29-03-2024 14:38
Referred By : SELF

2D-ECHO WITH COLOUR DOPPLER

Dimensions:

Ao (ed)	2.4CM
LA (es)	3.3CM
LVID (ed)	4.5CM
LVID (es)	3.0CM
IVS (Ed)	0.8CM
LVPW (Ed)	0.9CM
EF	65%
%FD	35%
MITRAL VALVE :	NORMAL
AML	NORMAL
PML	NORMAL
AORTIC VALVE	NORMAL
TRICUSPID VALVE	NORMAL
PULMONARY VALVE	NORMAL
RIGHT VENTRICLE	NORMAL
INTER ATRIAL SEPTUM	INTACT
INTER VENTRICULAR SEPTUM	INTACT
PULMONARY ARTERY	NORMAL
AORTA	NORMAL
RIGHT ATRIUM	NORMAL
LEFT ATRIUM	NORMAL
LEFT VENTRICLE	NORMAL
PERICARDIUM	NORMAL

Patient Name	: Mr. RANGABASHYAM M	Age	: 52 Y/M
UHID	: CANN.0000235113	OP Visit No	: CANNOPV398895
Conducted By:	: Dr. RAKESH P GOPAL	Conducted Date	: 29-03-2024 14:38
Referred By	: SELF		

DOPPLER STUDIES MITRAL INFLOW :

E : 0.7m/sc A: 1.0 m/sc

Velocity / Gradient Across Pulmonic Valve : 0.5m/sc

Velocity / Gradient Across Aortic Valve 01.3m/sc

IMPRESSION :

NO RWMA

NORMAL LEFT VENTRICULAR FUNCTION(EF - 65%)

NORMAL CARDIAC CHAMBERS & VALVES

GRADE I DIASTOLIC DYSFUNCTION

TRIVIAL TRICUSPID REGURGITATION

NO PAH / CLOT / PE .

Dr.
RAKESH P
GOPAL

Patient Name : Mr. RANGABASHYAM M
UHID : CANN.0000235113
Conducted By: : Dr. RAKESH P GOPAL
Referred By : SELF

Age : 52 Y/M
OP Visit No : CANNOPV398895
Conducted Date : 29-03-2024 14:38
