




Savita

Superspeciality Hospital

(A Unit of Solace Healthcare Pvt. Ltd.)

Parivar Char Rasta, Waghodia-Dabhoi Ring Road, Vadodara-390019
0265-2578844 / 2578849 ✉ mh@savitahospital.com 🌐 savitahospital.com

Patient Name :	Mehulkumar . Solanki	Sample No. :	20240314829 
Patient ID :	20240309249	Visit No. :	OPD20240329442
Age / Sex :	30y/Male	Call. Date :	29/03/2024 10:05
Consultant :	DR SAURABH JAIN	S. Coll. Date :	29/03/2024 13:19
Ward :	-	Report Date :	29/03/2024 16:59

CBC, ESR

Investigation	Result	Normal Value
Hemoglobin :	13.9 gm/dl	13.5 to 18.0 gm/dl
P.C.V. :	42.1 %	42.0 to 52.0 %
M.C.V. :	93.1 fL	78 to 100 fL
M.C.H. :	30.8 pg	27 to 31 pg
M.C.H.C. :	33 g/dl	32 to 36 g/dl
RDW :	12.2 %	11.5 to 14.0 %
RBC Count :	4.52 X 10 ⁶ / cumm [L]	4.7 to 6.0 X 10 ⁶ / cumm
Polymorphs :	63 %	38 to 70 %
Lymphocytes :	33 %	15 to 48 %
Eosinophils :	2 %	0 to 6 %
Monocytes :	2 % [L]	3 to 11 %
Basophils :	0 %	0.0 to 1.0 %
Total :	100	< 100 > 100
WBC Count :	6600 /cmm	4000 to 10000 /cmm
Platelets Count :	269000 /cmm	1,50,000 to 4,50,000 /cmm
ESR - After One Hour :	22 mm/hr [H]	1 to 13 mm/hr



Dr. Mehul Desai
M.B.D.C.P
Reg.No.G-9521



Savita

Superspeciality Hospital
(A Unit of Solace Healthcare Pvt. Ltd.)

Parivar Char Rasta, Waghodia-Dabhoi Ring Road, Vadodara-390019
0265-2578844 / 2578849 ✉ mh@savitahospital.com 🌐 savitahospital.com

Patient Name :	Mehulkumar . Solanki	Sample No. :	20240314829
Patient ID :	20240309249	Visit No. :	OPD20240329442
Age / Sex :	30y/Male	Call. Date :	29/03/2024 10:05
Consultant :	DR SAURABH JAIN	S. Coll. Date :	29/03/2024 13:20
Ward :	-	Report Date :	29/03/2024 16:59

Blood Group


Investigation	Result	Normal Value
BLOOD GROUP :		
ABO	AB	
Rh	Positive	

RENAL FUNCTION TEST

Investigation	Result	Normal Value
Creatinine :	0.8 mg/dl	0.6 - 1.4 mg/dl
Urea :	31 mg/ dl	13 - 45 mg/dl
Uric Acid :	6 mg/dl	3.5 - 7.2 mg/dl
Calcium :	9 mg/dl	8.5 - 10.5

Dr. Mehul Desai
M.B.D.C.P
Reg.No.G-9521



Patient Name :	Mehulkumar . Solanki	Sample No. :	20240314829 
Patient ID :	20240309249	Visit No. :	OPD20240329442
Age / Sex :	30y/Male	Call. Date :	29/03/2024 10:05
Consultant :	DR SAURABH JAIN	S. Coll. Date :	29/03/2024 13:20
Ward :	-	Report Date :	29/03/2024 16:59

Lipid Profile

Investigation	Result	Normal Value
Sample :	Fasting	
Sample Type :	Normal	
Cholesterol (Chol) :	137 mg/dl	Low risk : < 200 Moderate risk : 200 - 239 High risk : > or = 240
Triglyceride :	80 mg/dl	Normal : < 200.0 High : 200 - 499 Very High : > or = 500
HDL Cholesterol :	37 mg/dl [L]	Low risk : >or = 60 mg/dL High risk : Up to 35 mg/dL
LDL :	84 mg/dl [L]	131.0 to 159.0(N) < 130.0(L) > 159.0(H)
VLDL :	16 mg/dl	Up to 0 to 34 mg/dl
LDL/HDL Ratio :	2.27	Low risk : 0.5 to 3.0 Moderate risk : 3.0 to 6.0 Elevted level high > 6.0
Total Chol / HDL Ratio :	3.7	Low Risk : 3.3 to 4.4 Average Risk : 4.4 to 7.1 Moderate Risk : 7.1 to 11.0 High Risk : > 11.0
Total Lipids :	554 mg/dl	400 to 700 mg/dl

Note :- Lipemic samples give high triglyceride value and falsely low LDL value.



Dr.Mehul Desai
M.B.D.C.P
Reg.No.G-9521



Savita

Superspeciality Hospital
(A Unit of Solace Healthcare Pvt. Ltd.)

Parivar Char Rasta, Waghodia-Dabhoi Ring Road, Vadodara-390019
0265-2578844 / 2578849 ✉ mh@savitahospital.com 🌐 savitahospital.com

Patient Name :	Mehulkumar . Solanki	Sample No. :	20240314829
Patient ID :	20240309249	Visit No. :	OPD20240329442
Age / Sex :	30y/Male	Call. Date :	29/03/2024 10:05
Consultant :	DR SAURABH JAIN	S. Coll. Date :	29/03/2024 13:20
Ward :	-	Report Date :	29/03/2024 16:59

LFT (Liver Function Test)

Investigation	Result	Normal Value
Total Bilirubin :	0.6 mg/dl	0.2 to 1.0 mg/dl
Direct Bilirubin :	0.3 mg/dl	0.0 to 0.2 mg/dl
Indirect Bilirubin :	0.3 mg/dl	0.0 to 0.8 mg/dl
AST (SGOT) :	23 U/L	5 to 34 U/L
ALT (SGPT) :	31 U/L	0 to 55 U/L
Total Protein (TP) :	7.2 g/dL	6.4 to 8.3, g/dl
Albumin (ALB) :	4.2 g/dl	3.5 to 5.2 g/dl
Globulin :	3 g/dl	2.3 to 3.5 g/dl
A/G Ratio :	1.4	
Alkaline Phosphatase (ALP) :	77 U/L	40 to 150 U/L
GAMMA GT. :	32 U/L	7 to 35 U/L

Dr.Mehul Desai
M.B.D.C.P
Reg.No.G-9521



Unipath Specialty Laboratory (Baroda) LLP - Platinum Complex, Opp. HDFC Bank, Nr. Radha Krishna char rasta, Akota, Vadodra - 390020
 Unipath Specialty Laboratory (Baroda) LLP - Platinum Complex, Opp. HDFC Bank, Nr. Radha Krishna char rasta, Akota, Vadodra - 390020
 Mobile: 7228800500 / 8155028222 | Email: info.baroda@unipathllp.in
 Home Visit / OPD Reception : 9998724579



TEST REPORT

Reg. No. : 40301017407 Reg. Date : 29-Mar-2024 12:20 Collected On : 29-Mar-2024 12:20
 Name : Mr. MEHULKUMAR SOLANKI Approved On : 29-Mar-2024 14:23
 Age : 30 Years Gender : Male Ref. No. : Dispatch At :
 Ref. By : Tele No. :
 Location : SAVITA SUPERSPECIALTY HOSPITAL @ WAGHODIYA ROAD

Test Name	Results	Units	Bio. Ref. Interval
THYROID FUNCTION TEST			
T3 (triiodothyronine) <i>Method:CLIA</i>	1.39	ng/mL	0.6 - 1.81
T4 (Thyroxine) <i>Method:CLIA</i>	12.40	µg/dL	4.5 - 12.6
TSH (ultra sensitive) <i>Method:CLIA</i>	2.508	µIU/mL	0.55 - 4.78
Sample Type:Serum			

Comments:

Thyroid stimulating hormone (TSH) is synthesized and secreted by the anterior pituitary in response to a negative feedback mechanism involving concentrations of FT3 (free T3) and FT4 (free T4). Additionally, the hypothalamic tripeptide, thyrotropin-releasing hormone (TRH), directly stimulates TSH production. TSH stimulates thyroid cell production and hypertrophy, also stimulate the thyroid gland to synthesize and secrete T3 and T4. Quantification of TSH is significant to differentiate primary (thyroid) from secondary (pituitary) and tertiary (hypothalamus) hypothyroidism. In primary hypothyroidism, TSH levels are significantly elevated, while in secondary and tertiary hypothyroidism, TSH levels are low.

TSH levels During Pregnancy :

- First Trimester : 0.1 to 2.5 µIU/mL
- Second Trimester : 0.2 to 3.0 µIU/mL
- Third trimester : 0.3 to 3.0 µIU/mL

Reference : Carl A.Burtis,Edward R.Ashwood,David E.Bruns. Tietz Textbook of Clinical Chemistry and Molecular Diagnostics. 5th Edition. Philadelphia: WB Saunders.2012:2170

End Of Report

This is an electronically authenticated report.

Test done from collected sample.

Printed On: 29-Mar-2024 14:24

We are open 24 x 7 & 365 days

Dr. Vishal Jhaveri

M.B.B.S, D.C.P

Reg. G-13041

LLP Identification Number: AAN-8932

Page 1 of 1

We are open 24 x 7 & 365 days

LLP Identification Number: AAN-8932



Scanned with OKEN Scanner



Patient Name :	Mehulkumar . Solanki	Sample No. :	20240314829 
Patient ID :	20240309249	Visit No. :	OPD20240329442
Age / Sex :	30y/Male	Call. Date :	29/03/2024 10:05
Consultant :	DR SAURABH JAIN	S. Coll. Date :	29/03/2024 13:20
Ward :	-	Report Date :	29/03/2024 16:59

Urine R/M

Investigation	Result	Normal Value
Quantity - :	20 ml	
Colour - :	Pale Yellow	
Reaction (pH) :	6.0	4.6-8.0
Turbidity :	Clear	
Deposit :	Absent	Absent
Sp.Gravity :	1.025	1.005-1.010
Protein :	Absent	Absent
Glucose :	Absent	Absent
Bile Salts :	Absent	Absent
Bile pigments :	Absent	Absent
Ketones :	Absent	Absent
Urobilinogen :	Absent	
Blood :	Absent	Absent
Pus Cells :	0-1 /hpf	0-5/hpf
Red Blood Cells :	Absent /hpf	Absent
Epithelial Cells :	3-4 /hpf	

Dr.Mehul Desai
M.B.D.C.P
Reg.No.G-9521






Savita

Superspeciality Hospital
(A Unit of Solace Healthcare Pvt. Ltd.)

Parivar Char Rasta, Waghodia-Dabhoi Ring Road, Vadodara-390019
☎ 0265-2578844 / 2578849 ✉ mh@savitahospital.com 🌐 savitahospital.com

Patient Name : Mehulkumar . Solanki	Sample No. : 20240314829 
Patient ID : 20240309249	Visit No. : OPD20240329442
Age / Sex : 30y/Male	Call. Date : 29/03/2024 10:05
Consultant : DR SAURABH JAIN	S. Coll. Date : 29/03/2024 13:20
Ward : -	Report Date : 29/03/2024 17:18

FBS & PPBS

Investigation	Result	Normal Value
Blood Sugar (FBS) :	80 mg/dl	74 - 100 mg/dl
Urine Sugar (FUS) :	Nil	
Blood Sugar (PP2BS) :	92 mg/dl	70 to 120 mg/dl
Urine Sugar (PP2US) :	Nil	

HBA1C

Investigation	Result	Normal Value
Glycosylated Hb :	5.9 %	Near Normal Glycemia : 6 to 7 Excellent Control : 7 to 8 Good Control : 8 to 9 Fair Control : 9 to 10 Poor Control : > 10
Average Plasma Glucose of Last 3 Months :	122.63	



Dr.Mehul Desai
M.B.D.C.P
Reg.No.G-9521



Savita

Superspeciality Hospital
(A Unit of Solace Healthcare Pvt. Ltd.)

Parivar Char Rasta, Waghodia-Dabhoi Ring Road, Vadodara-390019

☎ 0265-2578844 / 2578849 📠 63596 88442

✉ mh@savitahospital.com 🌐 savitahospital.com



PATIENT NAME: MEHUL SOLANKI	
AGE/SEX: 30 YRS/M	DATE: Friday, 29 March 2024

CHEST X-RAY (PA)

Both lung fields appear normal.

Both hila appear normal

Bilateral costo-phrenic angles appear grossly clear

Mediastinum and cardiac shadow appear normal

Bony thorax appears unremarkable

No evidence of free gas under domes of diaphragm

IMPRESSION:

- NO SIGNIFICANT ABNORMALITY NOTED IN LUNG FIELDS
- NORMAL CARDIAC SHADOW


DR SHARAD RUNGTA (MD & DNB)
CONSULTANT RADIOLOGIST

Not all pathologies can be detected on ultrasound in each scan. Further radiographic evaluation is suggested if required.





Savita

Superspeciality Hospital
(A Unit of Solace Healthcare Pvt. Ltd.)

Parivar Char Rasta, Waghodia-Dabhoi Ring Road, Vadodara-390019

☎ 0265-2578844 / 2578849 📞 63596 88442

✉ mh@savitahospital.com 🌐 savitahospital.com



PATIENT NAME: MEHULKUMAR SOLANKI

AGE/SEX: 30 YRS/M

DATE: Friday, 29 March 2024

ULTRASOUND OF ABDOMEN & PELVIS

LIVER appears normal in size and shows raised parenchymal echogenicity. No evidence of focal lesion. No evidence of dilated IHBR or portal vein. CBD appears normal.

GALL BLADDER is distended. No e/o wall thickening, pericholecystic edema or calculus within.

VISUALIZED PART OF PANCREAS appears normal. MPD is WNL.

SPLEEN appears normal in size and shows normal parenchymal echogenicity. No evidence of focal lesion.

BOTH KIDNEYS appear normal in size and position.

Show normal cortical echogenicity. Corticomedullary differentiation is maintained.

No calculus or hydronephrosis on either side.

URINARY BLADDER is full. Mucosal surface appears smooth with no e/o obvious wall thickening or calculus within.

PROSTATE appears normal in size. No evidence of focal lesion noted.

BOWEL LOOPS appear normal and show normal peristalsis

No evidence of LYMPHADENOPATHY noted.

No evidence of ASCITES or PLEURAL EFFUSION noted.

IMPRESSION:

- Grade I Fatty Liver.


DR SHARAD RUNGTA (MD & DNB)
CONSULTANT RADIOLOGIST

Not all pathologies can be detected on ultrasound in each scan. Further radiographic evaluation is suggested if required.



SOLANKI, MEHULKUMAR
Male

29-Mar-24 11:37:21 AM

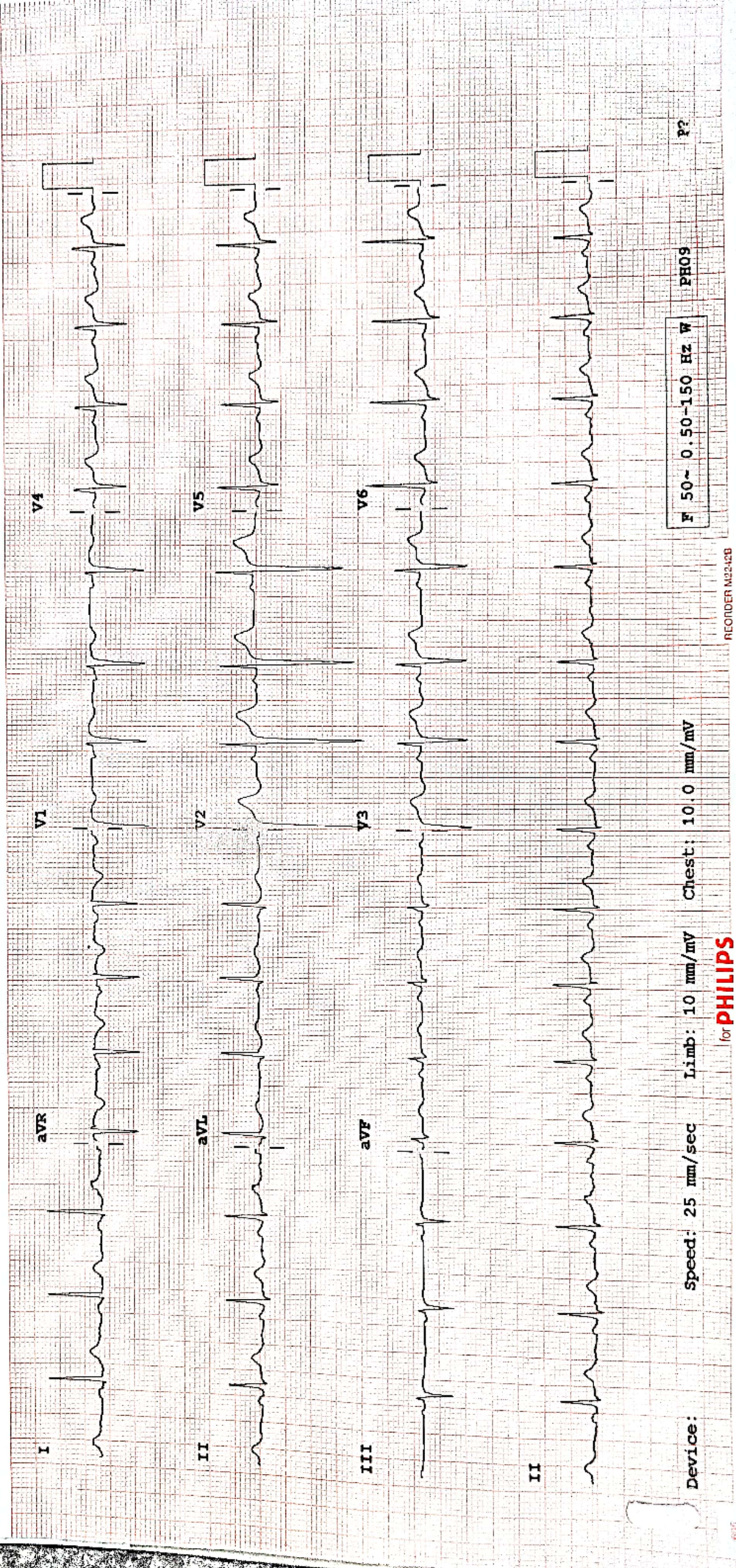
Rate 94

PR 124
QRSD 84
QT 336
QTc 421

--AXIS--

P 35
QRS 12
T 28

12 Lead; Standard Placement



Device:

Speed: 25 mm/sec

Limb: 10 mm/mV

Chest: 10.0 mm/mV

F 50~ 0.50-150 Hz W

PH09

P?

REORDER M3242B

605



2D-ECHOCARDIOGRAPHY AND COLOR DOPPLER REPORT

NAME: MEHULKUMAR SOLANKI

AGE/SEX: 30 YRS/MALE

DATE: 29/03/2024

REF BY: DIRECT

OBSERVATION:

- NORMAL LV SIZE AND NORMAL LV SYSTOLIC FUNCTION. LVEF = 60% (VISUAL).
- NO RWMA AT REST.
- NORMAL LV DIASTOLIC DYSFUNCTION.
- TRIVIAL MR. NO MS.
- NO AR. NO AS.
- TRIVIAL TR. NO PAH.
- NORMAL SIZED LA, RA & RV WITH NORMAL RV SYSTOLIC FUNCTION.
- NORMAL SIZED MPA, RPA & LPA.
- INTACT IAS & IVS.
- NO E/O INTRACARDIAC CLOT/VEGETATION/PE.
- NORMAL IVC.
- NORMAL PERICARDIUM.

LA: 32MM

AO: 32MM

IVS: 09/13MM

LVPW: 10/13MM

LVID: 45/25MM

CONCLUSION:

- NORMAL LV/RV SIZE AND SYSTOLIC FUNCTION.
- NO RWMA AT REST.
- LVEF = 60% (VISUAL).

DR.NIRAV BHALANI
[CARDIOLOGIST]

DR.ARVID SHARMA
[CARDIOLOGIST]



Examination by Ophthalmologist

Name: MEHULKUMAR SOLANKI

Reg. No: 20230309249

Age/ Sex: 30/MALE

DOE: 29/03/2024

Nil

Medical History:

Nil

Examination of Eye:

Right

LEFT

External Examination:

Anti seg Examination:

Schiot Tonometry IOP:

Normal

Fundus:

Without Glass Distant Vision: 6/6 6/6
Near Vision: Ng Ng

With Glass Distant Vision: _____

Near Vision: _____

Colour Vision (With Ishihara Chart): Normal

Impression:

Normal

Advice:

Signature: _____





Examination by Physicia

Name: MEHULKUMAR SOLANKI

Reg. No: 20230309249

Age/ Sex: 30/MALE

DOE: 29/03/2024

Physical Examination

Height: 161 cm Weight: 72 kg BMI: 27.77
Temperature: (N) Pulse: 87 BP: 120/78

SpO2 = 98

Chief Complaints:

No complaints

Past History:

NAD

Examination:

General Examination:

NAD

Systemic Examination:

NAD

Investigation:

RBS _____

ECG _____

Others _____


Advice: _____

Signature





बैंक ऑफ़ बड़ौदा
Bank of Baroda



नाम

मेहुल कुमार सोलंकी


Name

MEHUL KUMAR SOLANKI

कर्मचारी कूट क्र

E.C. No.

199836



जारीकर्ता प्राधिकारी

Issuing Authority

धारक के हस्ताक्षर

Signature Holder's

