

Reg. No. : 24-24-6054956

Date : 13-07-21

Patient's Name : Meha J Poriley Age : 45

Phone No. : _____ Mobile No. : _____

Referred by / Care of : _____

Refraction : _____

Work in daily routine : Driving / Watching TV / Computer / Reading / _____

Complaints : Diminution of Vision / Pain / Watery / Redness / Eyeache / Headache / Itching / Stickiness / Swelling / Irritation / Burning / F. B. Sensation / Photophobia / Diplopia / Squinting / Blackout / Floaters / Flashes / Injury /

Involve : RE / LE / BE Duration : _____

Ocular History : Surgery / Laser / FFA / Oct / Glaucoma / RP / Corneal Opacity / Injury / Amblyopia / Treatment

Surgery : Cataract / Glaucoma / _____ / RE / LE / BE

Systemic History : Glaucoma / RP / DM / _____

MIC : DM / HT / IHD / COPD / PROSTATE / WROID / ALLERGY / SMOKING / ALCOHOL

DETAILS :	RE	LE
With PH	_____	_____
GLASS :	_____	_____
	_____	_____

SS PRESCRIPTION

	R. E. V/A			L. E. V/A		
	SPH.	CYL.	AXIS	SPH.	CYL.	AXIS
Dis						
Nr.						
Comp						

Bifocal / Distant / Near only / Constant / Progressive / Photochromatic

Signature : _____

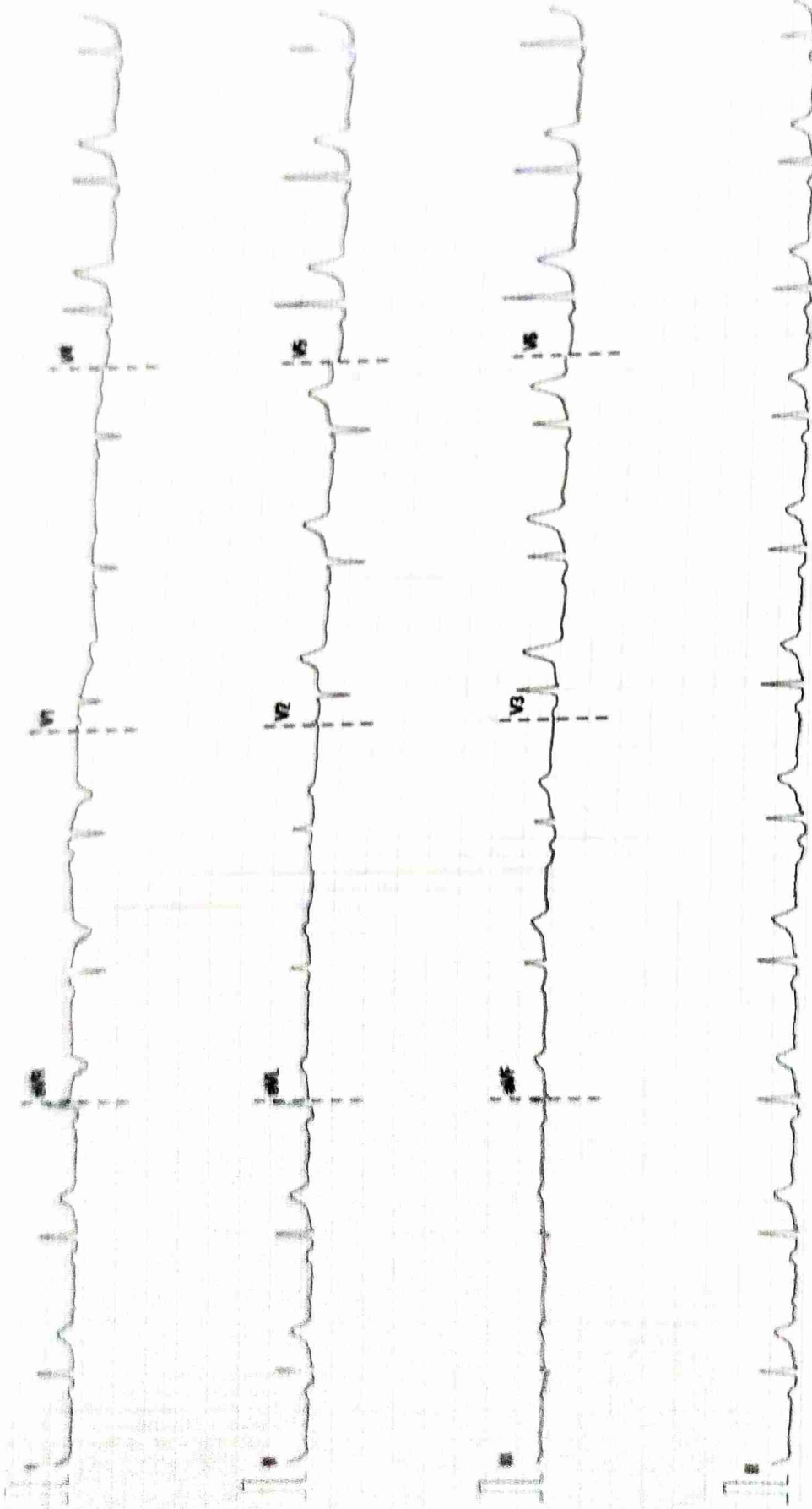
212
822
45.
229
410
08

સિદ્ધાંતરૂપે કહીને અને તમારા આરા સંબંધીઓને સમજૂતી આપેલ છે. મેં ડાક્ટરને મારી શારીરિક સ્થિતિ અંગેની જે સંબંધિત સંજોગોમાં સારવાર અપૂરી છોડીશ કે અનિચ્છિત રહીશ તો તેની નિષ્ફળતાઓ અને તમા સારવારની કિંમતો પર અપાયેલ રકમ મેળાવવા માટે હકકદાર રહીશ નહીં. આ સંજોગો સમજૂતી

સ્થાન: _____
સ્થાન: _____

CONSENT

..... hereby request and authorize Doctor
to perform the required dental treatment. Doctor has informed me and my relatives a



25 mm/s

16 mm/mV

50 Hz

REG 20 Hz

CHARUSAT HOSPITAL

REG 20.000 VOLT 4.1

20.000 VOLT 4.1

+

DATE	PATIENT NAME	AGE IN YEARS	SEX	REF
03-04-2024	NEHA J PARKER	45	F	BOI

USG OF THE ABDOMEN/ PELVIS V

The liver is normal in size and echotexture. The intra hepatic biliary radicles are normal. The gall bladder is well distended with normal wall thickness.

The pancreas reveals a normal echotexture. The spleen reveals a normal size.

Both kidneys are normal in size and echotexture. Medullary differentiation is noted. No hydronephrosis.

No free fluid or lymphadenopathy is seen. The urinary bladder is well distended.

The uterus is antverted, normal size. The endometrium is in the midline. No adnexal masses. The ovaries are normal in size and echotexture.

No adnexal abnormality is seen.

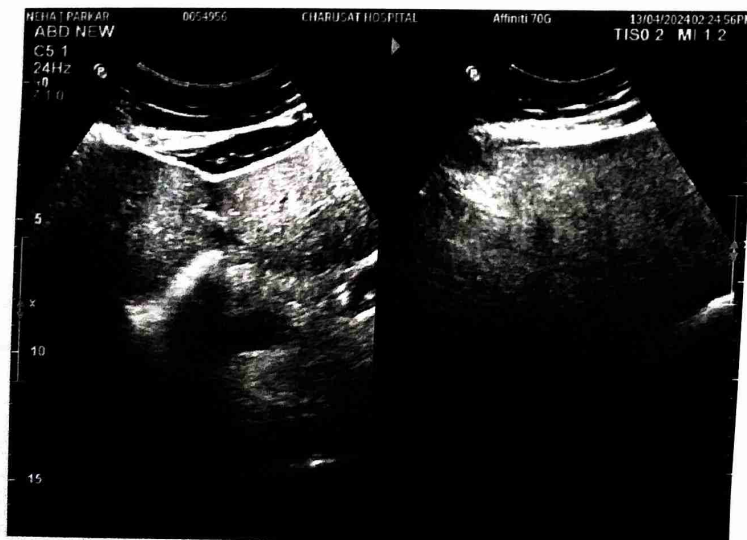
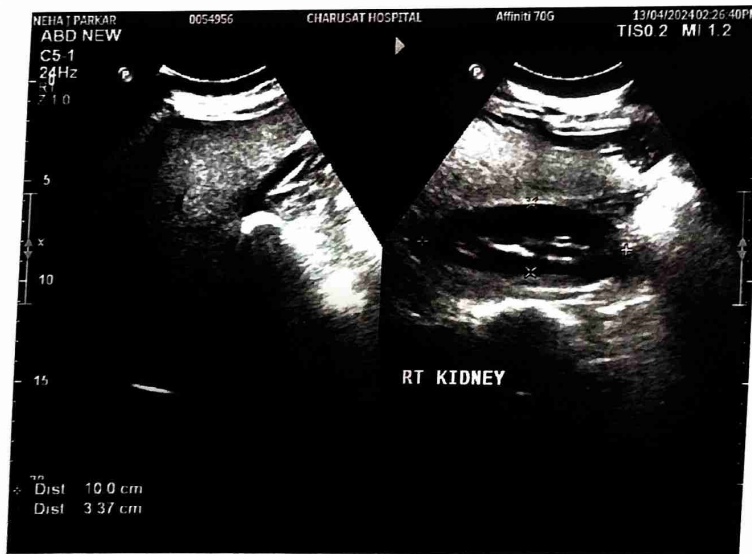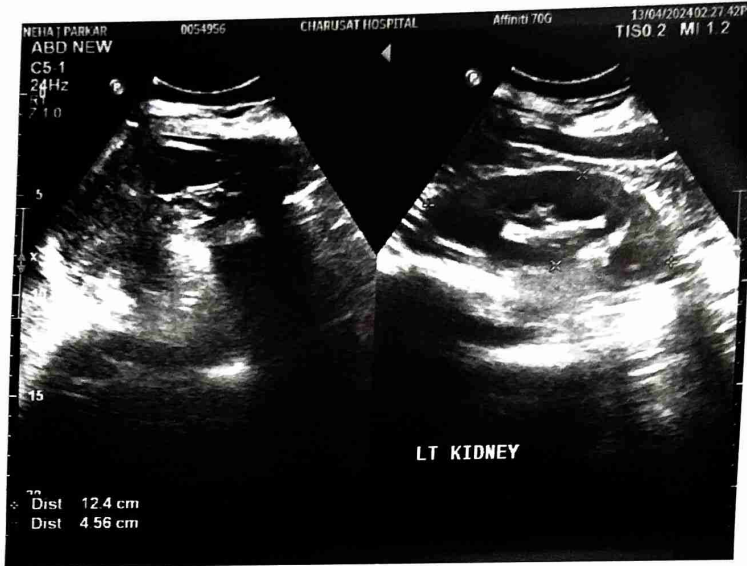
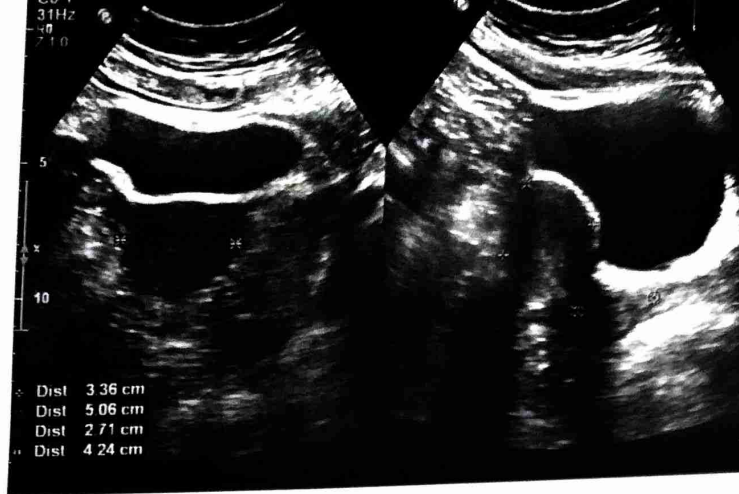
No free fluid is seen in the pouch of Douglas.

IMPRESSION :

NO ABNORMALITY DETECTED.

For reference
R. C. THAKKAR
M.D.M.R.D

Campus, Changa, District Anand 388 421
Web : www.ch-rf.org / www.charusat.org



DATE	PATIENT NAME	AGE IN YEARS	SEX	REFERRED BY DR	INVESTIGATION
13-04-2024	NEHA J PARKER	45	F	BODY PROFILE	UF-TOTAL ABDOMEN USG

USG OF THE ABDOMEN/ PELVIS WAS PERFORMED

The liver is normal in size and echotexture. No focal solid or cystic lesions are seen. The intra hepatic biliary radicles are normal. The portal vein and CBD are normal. The gall bladder is well distended with no calculi or polyp. The wall is not thickened.

The pancreas reveals a normal echopattern, with no focal calcification or a neoplasm. The spleen reveals a normal sonographic features.

Both kidneys are normal in size and echotexture. Evidence of good cortico medullary differentiation is noted. No evidence of any calculi or hydronephrosis.

No free fluid or lymphadenopathy is seen.
The urinary bladder is well distended with no calculi or polyps.

The uterus is antverted, normal size.
The endometrium is in the midline. No focal myoma is seen.
Both the ovaries are normal in size and shape. No focal solid or cystic lesion is seen.

No adnexal abnormality is seen.

No free fluid is seen in the pouch of douglas.

IMPRESSION :

NO ABNORMALITY DETECTED.


I think for reference
DR. KIRTI C THAKKAR
M.B.B.S.D.M.R.D

DATE	PATIENT NAME	AGE IN YEARS	SEX	REFERRED BY DR	INVESTIGATION
04-2024	NEHA J PARKER	45	F	BODY PROFILE	x-ray

X-ray CHEST PA view.

No evidence of consolidation or infiltration seen involving both lungs.

Costophrenic sinuses are clear.

Vascular shadows are normal on both sides.


hilar shadows show evidence of normal size, position & opacity.

Heart & aortic shadows show evidence of normal position & size.

Position of domes of diaphragm is normal. Bony cage show no abnormality.

COMMENTS:

NO EVIDENCE OF ABNORMALITY DETECTED.



Thanks for reference
DR KIRTI C THAKKAR
M.B.B.S, D.M.R.D




Patient Name :	NEHA JETHALAL PARKER	Sample No. :	SAMPLE-0108576
Patient ID :	CH-2024-0054956	Visit No. :	OPD/2024/04/0000629
Sex :	45y/Female	Call. Date :	13-Apr-2024 09:44
Order By :	RIPAL PATEL	S. Coll. Date :	13-Apr-2024 14:41
		Report Date :	13-Apr-2024 14:48

Investigation	Result	Normal Value
Prandial Blood Sugar (2Hrs) :	127.1 mg/dl [NORMAL]	100 - 140

DR. KETAN KAPADIA
 CONSULTANT PATHOLOGIST
 (M.B.B.S.,M.D)


DR. KETAN KAPADIA
 CONSULTANT PATHOLOGIST
 (M.B.B.S.,M.D)

Name :	NEHA JETHALAL PARKER	Sample No. :	SAMPLE-0108566 
ID :	CH-2024-0054956	Visit No. :	OPD/2024/04/0000629
Sex :	45y/Female	Call. Date :	13-Apr-2024 09:44
Ad By :	RIPAL PATEL	S. Coll. Date :	13-Apr-2024 10:25
	-	Report Date :	13-Apr-2024 14:35

Results : Absent -
Investigations : Absent -


DR. KETAN KAPADIA
CONSULTANT PATHOLOGIST
(M.B.B.S, D.C.P)

DR. KETAN KAPADIA
CONSULTANT PATHOLOGIST
(M.B.B.S, M.D)


Patient Name :	NEHA JETHALAL PARKER	Sample No. :	SAMPLE-0108566 
Patient ID :	CH-2024-0054956	Visit No. :	OPD/2024/04/0000629
Sex :	45y/Female	Call. Date :	13-Apr-2024 09:44
Ordered By :	RIPAL PATEL	S. Coll. Date :	13-Apr-2024 10:25
Ref. Id :	-	Report Date :	13-Apr-2024 14:35

serum Cholesterol (Chol) :	146.0 mg/dl	<200 mg/dl Desirable 200-239 mg/dl Boderline High > 240 mg/dl High
serum Triglyceride :	195.6 mg/dl	<150 mg/dl Normal 150-199 mg/dl Boderline High 200-499 mg/dl High
HDL Cholesterol :	33.8 mg/dl	Men : >55, Wo : >65 Standread Risk Level Men : 35-55, Wo : 46-65 Risk Men : <35, Wo : <45
DLC :	83 mg/dl	
LDL :	29.2 mg/dl [NORMAL]	10.0 to 30.0 (mg/dl)
DL/HDL Ratio :	2.46 - [NORMAL]	< 3.5
TC / HDL Ratio :	4.32 - [NORMAL]	4.0 to 6.0
LDL (DIRECT) :	108.4 mg/dl [Near Optimal]	< 100.0 (Optimal), 100.0 to 120.0 (Near Optimal), 130.0 to 159.0 (Border line high), 160.0 to 189.0 (High), > 190.0 (Very high)

LIVER FUNCTION TEST

Investigation	Result	Normal Value
Total Bilirubin :	0.53 mg/dl [NORMAL]	0.0 to 1.2
Direct Bilirubin (DBIL) :	0.17 mg/dl [NORMAL]	0.0 to 0.30
ALT (SGPT) :	25.1 IU/L [NORMAL]	[0.0 - 40]
AST (SGOT) :	12.5 IU/L [NORMAL]	<= 45.0
Alkaline Phosphatase (ALP) :	79.2 IU/L [NORMAL]	15 - 80 - : 37.0 to 147.0



Name :	NEHA JETHALAL PARKER	Sample No. :	SAMPLE-0108566 
ID :	CH-2024-0054956	Visit No. :	OPD/2024/04/0000629
Age :	45y/Female	Call. Date :	13-Apr-2024 09:44
Order By :	RIPAL PATEL	S. Coll. Date :	13-Apr-2024 10:25
	-	Report Date :	13-Apr-2024 14:35

1c 6.9 %

- > 8 : Action Suggested
- 7-8 : Good Control
- < 7 : Goal
- 6-7 : Near Normal Glycemia
- < 6 : Non-diabetic Level

Comments

Hb A1C also known as Glycosylated Haemoglobin is the most important test for the assessment of longterm Blood glucose control (also called glycemic control).
Hb A1C reflects mean glucose concentration over past 69-8 week and provides a much better indication of longterm glycemic control than blood glucose determination.
This Reaction is irreverdible & therefore remains unaffected glucose & Haemoglobin. Long term complications of diabetes such as Retinopathy (Eye-complications), nephropathy(Kidney-complications) & neuropathy(nerve complications) are potentially serious and can lead to blindness, kidney failure etc. Glycemic control as monitored by Hb A1C measurement is considered most important.


SH

Investigation	Result	Normal Value
SH :	4.38 uIU/ml [NORMAL]	0.34 to 4.5 (uIU/ml)

Investigation	Result	Normal Value
T3-Triiodothyronine :	1.52 ng/ml [NORMAL]	0.69 to 2.15 (ng/ml)

Investigation	Result	Normal Value
T4-thyroxine :	67.6 ng/ml [NORMAL]	52.0 to 127.0 (ng/mL)

Investigation	Result	Normal Value
LIPID PROFILE		

Patient Name :	NEHA JETHALAL PARKER	Sample No. :	SAMPLE-0108566 
Patient ID :	CH-2024-0054956	Visit No. :	OPD/2024/04/0000629
Sex :	45y/Female	Call. Date :	13-Apr-2024 09:44
Order By :	RIPAL PATEL	S. Coll. Date :	13-Apr-2024 10:25
Ref. No. :	-	Report Date :	13-Apr-2024 14:35

Investigation	Result	Normal Value
Serum Creatinine	0.71 mg/dl [LOW]	Male : 0.9 to 1.5 mg/dl Female : 0.8 to 1.2 mg/dl

Investigation	Result	Normal Value
Urea Nitrogen (UN)	7 [LOW]	8.0 to 23.0 (mg/dl)

Investigation	Result	Normal Value
Serum Uric Acid	5.17 mg/dl [NORMAL]	Male : 2.5 to 7.0 Female : 1.5 to 6.0

Investigation	Result	Normal Value
Sedimentation Rate (ESR) - After One Hour	10 mm [HIGH]	[M : 3 - 5, F : 4 - 7]

Investigation	Result	Normal Value
Blood Group (ABO)	B	
Rh	Positive	

Investigation	Result	Normal Value
Fasting Blood Sugar	109.7 mg/dl [NORMAL]	70 - 110

Investigation	Result	Normal Value
HbA1C (Mean Blood Glucose)	151.3 mg/dl	



Name :	NEHA JETHALAL PARKER	Sample No. :	SAMPLE-0108566
CH-2024-0054956		Visit No. :	OPD/2024/04/0000629
45y/Female		Call. Date :	13-Apr-2024 09:44
RIPAL PATEL		S. Coll. Date :	13-Apr-2024 10:25
		Report Date :	13-Apr-2024 14:35

Investigation	Result	Normal Value
Hemoglobin (HB)	12.8 gm/dl [NORMAL]	[M : 14-18, F : 12-16]
Hematocrit	4.37 mill./c.mm [NORMAL]	[M : 4.5 - 5.5 , F : 3.8 - 5.2]
WBC Count	9740 /c.mm [NORMAL]	4000 - 10000
Platelet count	3.39 Lakh/cmm [NORMAL]	1.5 - 4.5
WBC Count - Differential		
Neutrophils	65 % [NORMAL]	40 - 70
Lymphocytes	28 % [NORMAL]	20 - 40
Eosinophils	02 % [NORMAL]	1 - 6
Monocytes	05 % [NORMAL]	2 - 10
Basophils	00 % [NORMAL]	0 - 1
BLOOD UREA		
Blood Urea	15.4 mg/dl [NORMAL]	15 - 40
Serum Creatinine		

Investigation/s Advised :

Provisional Diagnosis :

Allergy :

Nutritional Advice :

TREATMENT ADVISED

DATE	DOCTOR'S NOTE	REMARKS
<u>Age-45</u>	<p>SIB. Dr. <u>Aspiter</u> <u>Conne</u></p> <p>C10-N11 - want to conceive</p> <p>LMP - <u>2/4/24</u> → <u>18/3/24</u> →</p> <p>M1H - <u>3-4</u> Regular, mod, <u>28-30</u> Painless</p> <p>PT on to has done IUI - 1 case</p> <p><u>12/10</u> - Hypothyroidism <u>on R</u></p>	<p><u>Adv</u></p> <p><u>IUF</u></p> <p>Tab. Folic acid</p> <p>Oto</p> <p>1 month</p> <p><u>700</u> <u>Tab / caler.</u></p> <p>Vit D3 <u>every week</u></p>

Signature with Stamp

Investigation/s Advised : _____


Provisional Diagnosis : _____

Allergy : _____

Nutritional Advice : _____

TREATMENT ADVISED

DATE	DOCTOR'S NOTE	REMARKS
	<p style="text-align: right;">AHL 2</p> <p>① T. MF (500) 1-0-1</p> <p>② T. Fosyvas (10) 0-0-1</p> <p style="text-align: right;">→ I Month</p>	
11/13 10 July	<p>1/0 on off cervical pain region pain</p> <p>AHL</p> <ul style="list-style-type: none">- Cervical isometric Exercises- T. Fosyvas - MF - FORTE 1 1/1 + ②- D, 60k 1/1/1 + ④	


Signature with Stamp



REGISTRATION FORM (OPD)



Dr. Jinish sir

Date & Time : 13-04-24

Registration No. : CH-24-0054956

Name : Meha J Parke Contact No. : (M) _____

Age : 45 Sex : F (O) _____

Address : _____

BP : 140/80 Pulse : 68 SpO₂ : 98

Height : _____ Weight : _____

OPD-INITIAL ASSESSMENT FORM

Chief Complaints : came for health checkup

CASE ANALYSIS

Past History : _____

N

Present History : _____

SG/E Vitals : _____

Systemic Examination : _____

FAMILY HISTORY :

- Diabetes
- IHD
- Hypertension
- Others (Specify) : _____

PATIENT'S MEDICAL/OTHER HISTORY :

- Hypertension
- Epilepsy
- Food Allergy
- Drug Allergy
- IHD
- Asthma
- AIDS/HIV
- Pregnancy
- T.B.
- Hepatitis B
- Bleeding Disorder
- Jaundice
- Hepatitis C


HABBITTS : Smoking Alcohol Tobacco Others (Specify) : _____



ચારુસેટ હોસ્પિટલ, ચાંગા

વર્લ્ડ ક્લાસ મલ્ટી સ્પેશિયાલિટી હોસ્પિટલ

Body Profile



તારીખ / Date **13/04/2024**

રજીસ્ટ્રેશન નંબર / Registration Number	CH-2024 - 0054956
દર્દીનું નામ / Patient's Name	Heha J Poriker.
સંપર્ક નંબર / Contact Number	

હેલ્થ લાઇન

એમ્બીલેન્સ માટે સંપર્ક
+91-2697-265502/504
+91-95379 27873

૨૪ કલાક ઇમરજન્સી સંપર્ક
+91-2697-265500
+91-75748 38111

નોંધ : ફરી ખતાવવા આવો ત્યારે આ ફાઇલ અચૂક આપો