

YASHFEEN IMAGING & RADIOLOGY DEPARTMENT

MANAGED BY :- YASHFEEN FOUNDATION

VIRAVAL, NAVSARI. 396 445. PHONE : (H) (02637) 235725

Website : www.yashfeenhospital.in E-mail : info@yashfeenhospital.in

Patient's Name:	POOJABEN G. PATEL	Age & Sex:	29Yrs/F
Ref. by Dr.	SELF	Date:	29-03-2024

X RAY CHEST (PA VIEW)

Both lung fields appear normal.
Both hila appear normal.
Both CP angles appear clear.
Cardiac size appears within normal limit.
Both domes of diaphragm appear normal.
Bony thoracic cage appears normal.

IMPRESSION:

- Normal X-ray chest (PA view).

Dr. DHARMESH DESAI
(M.D. Radiology)
Dr. Dharmesh Desai
Reg. No. G-45284
MB
YASHFEEN GROUP OF HOSPITAL



Please contact immediately for any typographical error.

This is only professional opinion, not a final diagnosis. Kindly correlate clinically. Not valid for medicolegal purpose.



YASHFEEN CARDIAC HOSPITAL™

MANAGED BY :- YASHFEEN FOUNDATION

VIRAVAL, NAVSARI. 396 445. PHONE : (H) (02637) 235725

Website : www.yashfeenhospital.in E-mail : info@yashfeenhospital.in

(Regd. No. E / 1390 / Navsari)

(Stationary For Report Only)

2D ECHO CARDIOGRAPHY COLOUR DOPPLER REPORT

Patient Name & No	: POOJABEN GIRISHBHAI PATEL CH23053069	Age/Sex	UHID :	: 5112
Doctor	: Mohil Nagad	29/ F	No :	: 7784
Referred By	:		Date :	: 29/03/2024

M-Mode findings

LVIDd : 42mm
 LVIDs : 29mm
 IVSd : 11mm
 PWd : 11mm
 EF : 60%
 Aorta : 23mm
 LA : 32mm

2D Imaging

Aortic Valve : Trileaflet, Normal
 Mitral Valve : Thin, Pliable, Normal Mobility, Normal function
 Tricuspid Valve : Normal
 Pulmonary Valve : Normal

=> : All cardiac chambers are normal sized.
 => : All cardiac valves are normal.
 => : No regional wall motion abnormality.
 => : Normal LV systolic function.
 => : Normal LV diastolic function.
 => : IAS/IVS intact.
 => : No obvious clots/ vegetations/ or effusion.
 => : IVC Normal size.

Doppler Findings

=> : No MS/MR, No TS/TR, No AS/AR & No PS/PR
 Mitral inflow Pattern : E > A
 Tissue Doppler Findings : E' > A'

Impression : Normal LVEF:60%, No RWMA.



Report Prepared By

Report Checked By
DR. MOHIL NAGAD
 M.D. Medicine, D.M. Cardiology
 M.D. (Phy.) DIB, Cardiology
 Senior Consultant-Interventional Cardiology
 Non Invasive Cardiologist
 Reg. No. G-2285
 YASHFEEN HOSPITAL, NAVSARI

Designed By : Sarita Infotech Pvt. Ltd., Navsari



YASHFEEN CARDIAC HOSPITAL™

At. & Po. Viraval, Navsari. 396 445. Phone (H) (02637) 235725
Website : www.yashfeenhospital.in E-mail : info@yashfeenhospital.in
(For Laboratory Reports Only)



Patient Name : POOJABEN GIRISHBHAI PATEL Age : 29 Years Sex : F
Ref By Dr. : - Area : Navsari Date : 29/03/2024
Sample Time : 29/03/2024 08:45 No : 14 Time : 12:44PM

HAEMOGRAM

Test	Findings	UOM	Normal Range
HAEMOGLOBIN	9.3	gm/dl	M-13.5-17.0 gm/dl F-11.5-15.5 gm/dl
HAEMOGRAM			
RED BLOOD CELL	3.61	10 ⁶ /μL	3.76-5.70
TOTAL LEUCOCYTE COUNT	6400	cells/cumm	4,000-11,000cells/cumm
Differential Count			
Neutrophil	27	%	40-75 %
Lymphocytes	67	%	20-40 %
Eosinophil	2	%	01-06 %
Monocytes	4	%	02-10 %
Basophils	0	%	00-00 %
PLATELET COUNT	553000	lacs/cumm	1.5-5.5 Lacs/cumm
RBC INDICES			
P.C.V.	26.1	%	Male-40-56%, Female-37-47%
M.C.V.	72.3	cu/microns	76.0-94.0
M.C.H.	25.6	Pg	27.0-30.0
M.C.H.C.	35.4	-	30.0-35.0
BLOOD GROUP	" AB "	-	-
RH FACTOR	POSITIVE	-	-
E.S.R.(1 hour)	30	mm/hr.	Male-5-10 mm/hr, Female-5-20 mm/hr

Remarks

Designed By : Sarita Infotech Pvt. Ltd., Navsari

P. Chaudhari
Dr. PIYUSH B. CHAUDHARI

M.D. Medicine

Yashfeen Cardiac Hospital
Regd. No. G-21518

Signature
Signature
Technician

Thanks for Reference



YASHFEEN CARDIAC HOSPITAL™

At. & Po. Viraval, Navsari. 396 445. Phone (H) (02637) 235725

Website : www.yashfeenhospital.in E-mail : info@yashfeenhospital.in
(For Laboratory Reports Only)



Patient Name : POOJABEN GIRISHBHAI PATEL

Ref By Dr. : -

Sample Time : 29/03/2024 08:57 No : 14

Age : 29 Years Sex : F

Area : Navsari

Date : 29/03/2024

Time : 12:44PM

HAEMOGLOBIN A1 C ESTIMATION

Test	Findings	UOM	Normal Range
Hb A1C	5.0	%	>8 : Action Suggested, 7-8 : Good Control, <7 : Goal, 6-7 : Near Normal Glycemia, <6 : Non-diabetic Level
Technique METHOD - HPLC			
Mean Blood Glucose	97.3	mg/dL	



Remarks

Designed By : Sarita Infotech Pvt. Ltd., Navsari

Yashfeen Cardiac Hospital

P. Chaudhari
Dr. PIYUSH B. CHAUDHARI
M.D. Medicine
Reg. No. G-21518

[Signature]
Signature
Technician

Thanks for Reference



YASHFEEN CARDIAC HOSPITAL™

At. & Po. Viraval, Navsari. 396 445. Phone (H) (02637) 235725
Website : www.yashfeenhospital.in E-mail : info@yashfeenhospital.in
(For Laboratory Reports Only)



Patient Name : POOJABEN GIRISHBHAI PATEL
Ref By Dr. : -
Sample Time : 29/03/2024 08:57 No : 14

Age : 29 Years Sex : F
Area : Navsari Date : 29/03/2024
Time : 12:45PM

BLOOD SUGAR TEST REPORT

Test	Findings	UOM	Normal Range
FASTING BLOOD SUGAR	93.5	mg/dL	70-110 mg/dL
FASTING URINE SUGAR	NIL	-	NIL
POSTPANDRIAL BLOOD SUGAR	101.0	mg/dL	70-140 mg/dL
POSTPANDRIAL URINE SUGAR	N.R	-	NIL



f. d. d. e.
Dr. PIYUSH B. CHAUDHARI
M.D. Medicine
Reg. No. G-21518

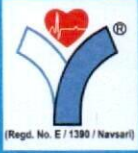Remarks

Designed By : Sarita Infotech Pvt. Ltd., Navsari

Yashfeen Cardiac Hospital

Reth
Signature
Technician

Thanks for Reference



YASHFEEN CARDIAC HOSPITAL™

At. & Po. Viraval, Navsari. 396 445. Phone (H) (02637) 235725
Website : www.yashfeenhospital.in E-mail : info@yashfeenhospital.in
(For Laboratory Reports Only)



Patient Name : POOJABEN GIRISHBHAI PATEL Age : 29 Years Sex : F
Ref By Dr. : - Area : Navsari Date : 29/03/2024
Sample Time : 29/03/2024 08:57 No : 14 Time : 12:45PM

RENAL FUNCTION TEST REPORT

Test	Findings	UOM	Normal Range
S.CREATININE	<u>0.5</u>	mg/dL	Male-0.9-1.4 mg/dL, Female-0.8-1.2 mg/dL
BLOOD UREA NITROGEN	<u>3.4</u>	mg/dL	4.7-23.0 mg/dL
S.URIC ACID	<u>7.6</u>	mg/dL	Male:3.5-7.2 mg/dL, Female:2.6-6.0 mg/dL



P. Chaudhari
Dr. PIYUSH B. CHAUDHARI
M.D. Medicine
Reg. No. G-21518

Remarks

Designed By : Sarita Infotech Pvt. Ltd., Navsari

Yashfeen Cardiac Hospital

Amrisha
Signature
Technician

Thanks for Reference



YASHFEEN CARDIAC HOSPITAL™

At. & Po. Viraval, Navsari. 396 445. Phone (H) (02637) 235725

Website : www.yashfeenhospital.in E-mail : info@yashfeenhospital.in

(For Laboratory Reports Only)



Patient Name : POOJABEN GIRISHBHAI PATEL

Ref By Dr. : -

Sample Time : 29/03/2024 08:58 No : 14

Age : 29 Years Sex : F

Area : Navsari

Date : 29/03/2024

Time : 12:45PM

LIPID PROFILE TEST REPORT

Test	Findings	UOM	Normal Range
S.CHOLESTEROL	117.3	mg/dL	<200:Desirable, 200-239:Borderline High, >=240:High
HDL CHOLESTEROL	28.1	mg/dL	<40:Low(High Risk), >=60:High(Low Risk)
LDL CHOLESTEROL	92.7	mg/dL	<100.0: Optimal, 100.0-129.0: Nearoptimal/ Aboveoptimal, 130.0-159.0:Borderline High, 160.0-189.0:High, >=190.0:Very High
VLDL CHOLESTEROL	23.0	mg/dL	Upto 40.0 mg/dL
S.TRIGLYCERIDES	115.0	mg/dL	<150.0:Normal, 150.0-199.0:Borderline high, 200.0-499.0:High, >=500.0:Very High
CHOL/ HDL RATIO	4.2	mg/dL	LESS THAN 5.0
LDL/ HDL RATIO	3.3	mg/dL	LESS THAN 5.0
REMARK	-	-	



P. Chaudhari
Dr. PIYUSH B. CHAUDHARI
M.D. Medicine
Reg. No. G-21518

Remarks

Designed By : Sarita Infotech Pvt. Ltd., Navsari

Yashfeen Cardiac Hospital

Signature
signature
Technician

Thanks for Reference



YASHFEEN CARDIAC HOSPITAL™

At. & Po. Viraval, Navsari. 396 445. Phone (H) (02637) 235725

Website : www.yashfeenhospital.in E-mail : info@yashfeenhospital.in

(For Laboratory Reports Only)



Patient Name : POOJABEN GIRISHBHAI PATEL

Ref By Dr. : -

Sample Time : 29/03/2024 08:58 No : 14

Age : 29 Years Sex : F

Area : Navsari

Date : 29/03/2024

Time : 12:45PM

LIVER FUNCTION TEST REPORT

Test	Findings	UOM	Normal Range
TOTAL BILIRUBIN	1.1	mg/dL	0-1.0 mg/dL
DIRECT BILIRUBIN	0.4	mg/dL	0-0.8 mg/dL
INDIRECT BILIRUBIN	0.7	mg/dL	0-0.2 mg/dL
SGPT	16.1	U/L	Below 40.0 U/L
S.ALKALINE PHOSPHATASE	65.9	U/L	Child-170.0-515.0 U/L, Adults-37.0-147.0 U/L
TOTAL PROTEIN	7.1	g/dl	6.0-8.0 g/dl
ALBUMIN	4.3	g/dl	3.0-5.0 g/dl
GLOBULIN	2.8	g/dl	3.0-3.5 g/dl
A/G	1.6	g/dl	
SGOT	29.1	U/L	Below 40.0 U/L



P. Chaudhari
Dr. PIYUSH B. CHAUDHARI

M.D. Medicine

Reg. No. G-21518

Remarks

Designed By : Sarita Infotech Pvt. Ltd., Navsari

Yashfeen Cardiac Hospital

Signature
Signature

Technician

Thanks for Reference



YASHFEEN CARDIAC HOSPITAL™

At. & Po. Viraval, Navsari. 396 445. Phone (H) (02637) 235725
Website : www.yashfeenhospital.in E-mail : info@yashfeenhospital.in
(For Laboratory Reports Only)



Patient Name : POOJABEN GIRISHBHAI PATEL Age : 29 Years Sex : F
Ref By Dr. : - Area : Navsari Date : 29/03/2024
Sample Time : 29/03/2024 08:58 No : 14 Time : 12:45PM

GGT TEST REPORT

Test	Findings	UOM	Normal Range
SERUM GGT	18.0	U/L	10.0-71.0 U/L



P. Chaudhari
Dr. PIYUSH B. CHAUDHARI
M. D. Medicine
Reg. No. G-21518

Remarks

Designed By : Sarita Infotech Pvt. Ltd., Navsari

Yashfeen Cardiac Hospital

Abhinav
signature
Technician

Thanks for Reference



YASHFEEN CARDIAC HOSPITAL™

At. & Po. Viraval, Navsari. 396 445. Phone (H) (02637) 235725
Website : www.yashfeenhospital.in E-mail : info@yashfeenhospital.in
(For Laboratory Reports Only)



Patient Name : POOJABEN GIRISHBHAI PATEL Age : 29 Years Sex : F
Ref By Dr. : - Area : Navsari Date : 29/03/2024
Sample Time : 29/03/2024 08:58 No : 14 Time : 12:45PM

THYROID FUNCTION TEST REPORT

Test	Findings	UOM	Normal Range
T3 (TRIODOTHYRONINE)	1.28	ng/ml	Newborns:0.73-2.88, 6 Days-3 Months:0.80-2.75, 4-12Months:0.86-2.65, 1-6 Years:0.92-2.48, 7-11 Years:0.93-2.31, 12-20Years:0.91-2.18, Adults:0.80-2.00
T4(THYROXINE)	5.67	µg/dl	Newborns:5.04-18.5, 6 Days-3 Months:5.41-17.0, 4-12 Months:5.67-16.0, 1-6 Years:5.95-14.7, 7-11 Years:5.99-13.8, 12-20 Years:5.91-13.2, Adults:5.10-14.1
TSH	12.89	µIU/ml	Newborns:0.70-15.2, 6 Days-3 Months:0.72-11.0, 4-12 Months:0.73-8.35, 1-6 Years:0.70-5.97, 7-11 Years:0.60-4.84, 12-20 Years:0.51-4.30, Adults:0.27-4.20

TECHNIQUE
ELECTROCHEMILUMINESCEN
CE



P. Chaudhari
Dr. PIYUSH B. CHAUDHARI
M.D. Medicine
Reg. No. G-21518

Remarks

Designed By : Sarita Infotech Pvt. Ltd., Navsari

Yashfeen Cardiac Hospital

Signature
Signature
Technician

Thanks for Reference



YASHFEEN CARDIAC HOSPITAL™

At. & Po. Viraval, Navsari. 396 445. Phone (H) (02637) 235725

Website : www.yashfeenhospital.in E-mail : info@yashfeenhospital.in

(For Laboratory Reports Only)



Patient Name : POOJABEN GIRISHBHAI PATEL

Age : 29 Years Sex : F

Ref By Dr. : -

Area : Navsari Date : 29/03/2024

Sample Time : 29/03/2024 08:58 No : 14

Time : 12:45PM

ROUTINE URINE ANALYSIS

Test	Findings	UOM	Normal Range
PHYSICAL EXAMINATION			
Quantity	-	-	
Colour	YELLOW	-	
Appearance	CLEAR	-	
Reaction	ACIDIC	-	
Sp. Gravity	1.004	-	
CHEMICAL EXAMINATION			
U.Albumin	NIL	-	
Sugar	NIL	-	
Acetone	NIL	-	
Bile Salt	NIL	-	
Bile Pigment	NIL	-	
Occult Blood	NIL	-	
MICROSCOPIC EXAMINATION			
Pus Cells	3-4	/hpf	
Epithelial cells	5-6	/hpf	
Red cells	ABSENT	/hpf	
Casts	-	/hpf	
Crystals	AMORPHOUS SEEN	/hpf	
Others	BACTERIA {FEW} SEEN	/hpf	



P. Chaudhary
Dr. PIYUSH B. CHAUDHARI
M.D. Medicine
Reg. No. G-21518

Remarks

Designed By : Sarita Infotech Pvt. Ltd., Navsari

Yashfeen Cardiac Hospital

Sarita Infotech
signature
Technician

Thanks for Reference

POOJABEN
ID:
DOB:
29 Years
Female, Unknown
Med.:
Location:
Referring Physician:
Notes:

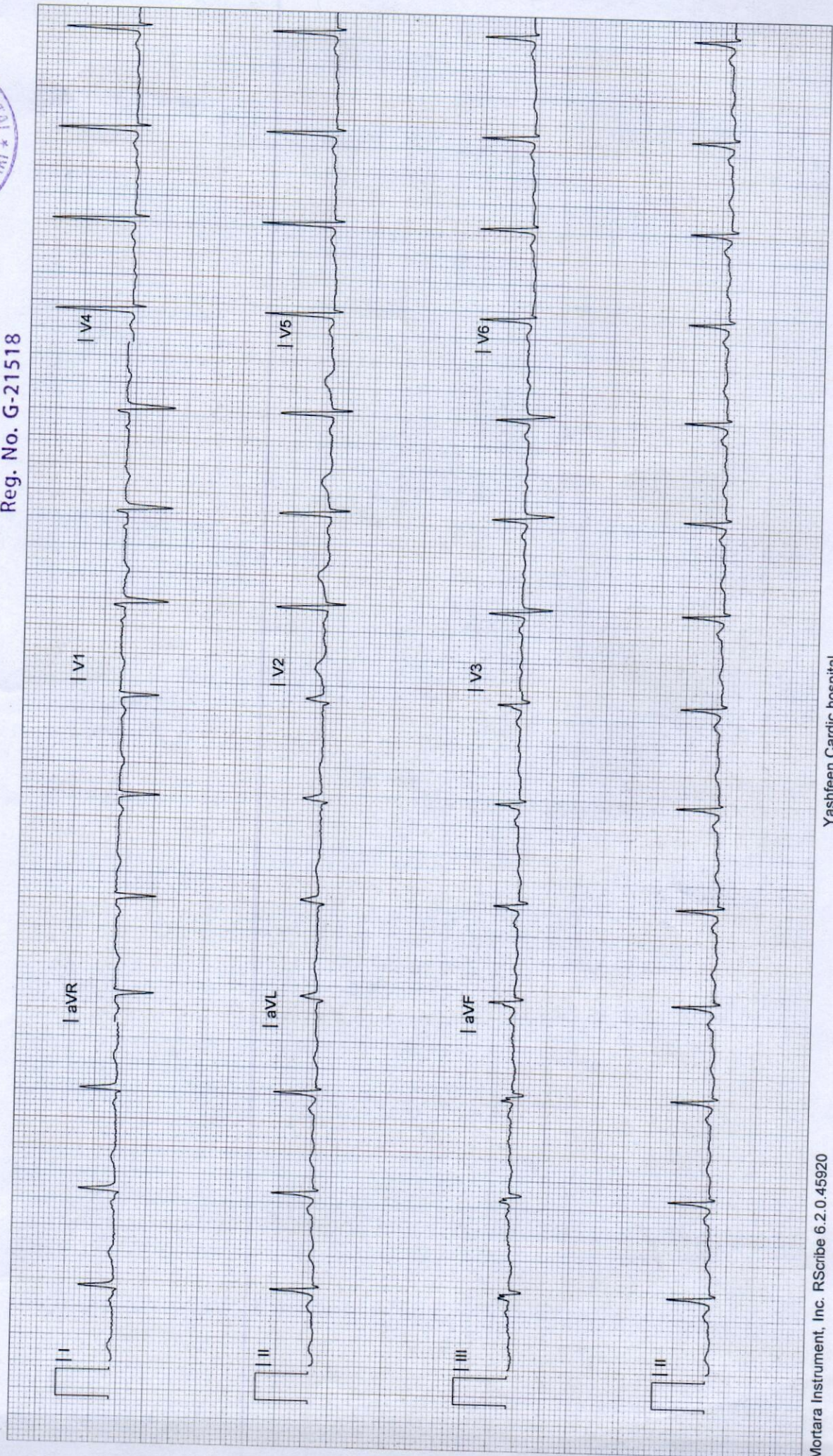
29-03-2024 09:39:21

Vent. Rate: 84 BPM
PR Int: 139 ms
QRS dur: 76 ms
QT/QTc: 367/408 ms
P-R-T axes: 59 37 3
Avg. RR: 711 ms
QTcB: 435 ms
QTcF: 411 ms

SINUS RHYTHM
NONSPECIFIC T-WAVE ABNORMALITY
BORDERLINE ECG

UNCONFIRMED REPORT
Reviewed by:

f. Chaudhari
Dr. PIYUSH B. CHAUDHARI
M.D. Medicine
Reg. No. G-21518



YASHFEEN IMAGING & RADIOLOGY DEPARTMENT

MANAGED BY :- YASHFEEN FOUNDATION

VIRVAL, NAVSARI. 396 445. PHONE : (H) (02637) 235725

Website : www.yashfeenhospital.in E-mail : info@yashfeenhospital.in

Name	POOJABEN G. PATEL	Age	29Y/F
Ref by Dr	SELF	Date	29/03/2024

USG ABDOMEN & PELVIS (SCREENING)(TVS)

Liver appears normal in size & shape with normal echopattern.
No e/o focal or diffuse lesion. IHBR appear normal.
PV and CBD appear normal.

Gall bladder appears distended & normal in shape & size. No e/o calculus or mass seen.
Walls appear normal.

Pancreas appears normal in size and echogenicity. No e/o focal or diffuse lesion.

Spleen could not be visualized.

Both Kidneys appear normal in size and echopattern. CM Differentiation is preserved.
No e/o calculus or hydronephrosis on either side.
Perirenal spaces appear normal on either side.
Suprarenal regions appear normal on either side. No e/o mass lesion.

Bladder is physiologically distended. No e/o calculus or mass. Walls appear normal.

Uterus appears retroverted, normal in size & shows normal echopattern.
Endometrial cavity is empty. ET- 5 mm. No e/o focal or diffuse mass lesion.

Both ovaries appear normal in size & echopattern.
No e/o adnexal mass on either side.

RIF region appears normal.

No e/o ascites.

IMPRESSION:

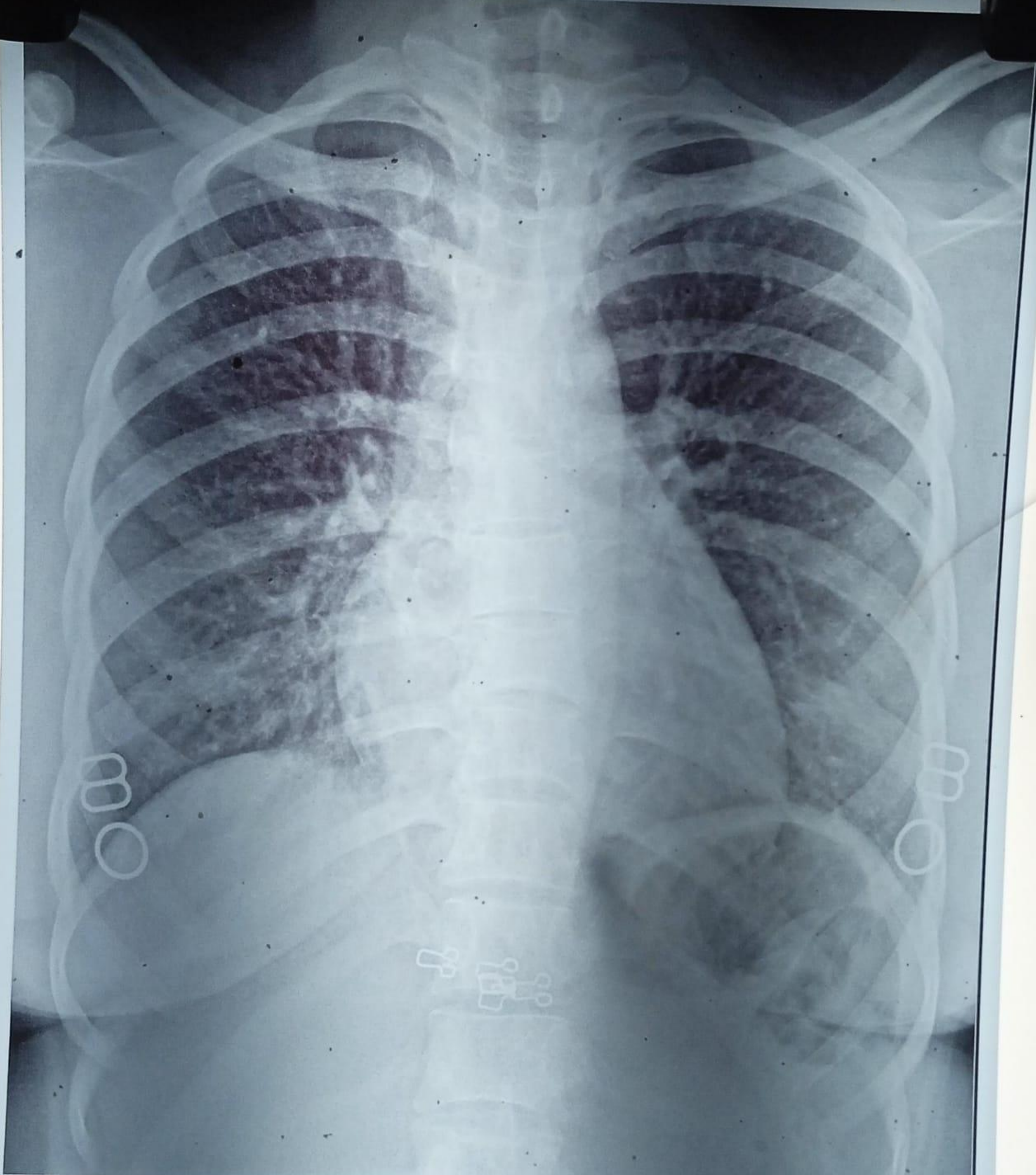
No significant abnormality detected.



Dr. DHARMESH DESAI
(M.D. Radiology)
Reg. No. G-45284
Dr. Dharmesh Desai
YASHFEEN GROUP OF HOSPITAL

Please contact immediately for any typographical error.

This is only professional opinion, not a final diagnosis. Kindly correlate clinically. Not valid for medical/legal purposes.



H23053069 POOJABEN G PATEL 29/Y 290324796 ChestErect PA 29/03/2024
YASHFEEN GROUP OF HOSPITALS NAVSARI PH:9924047789