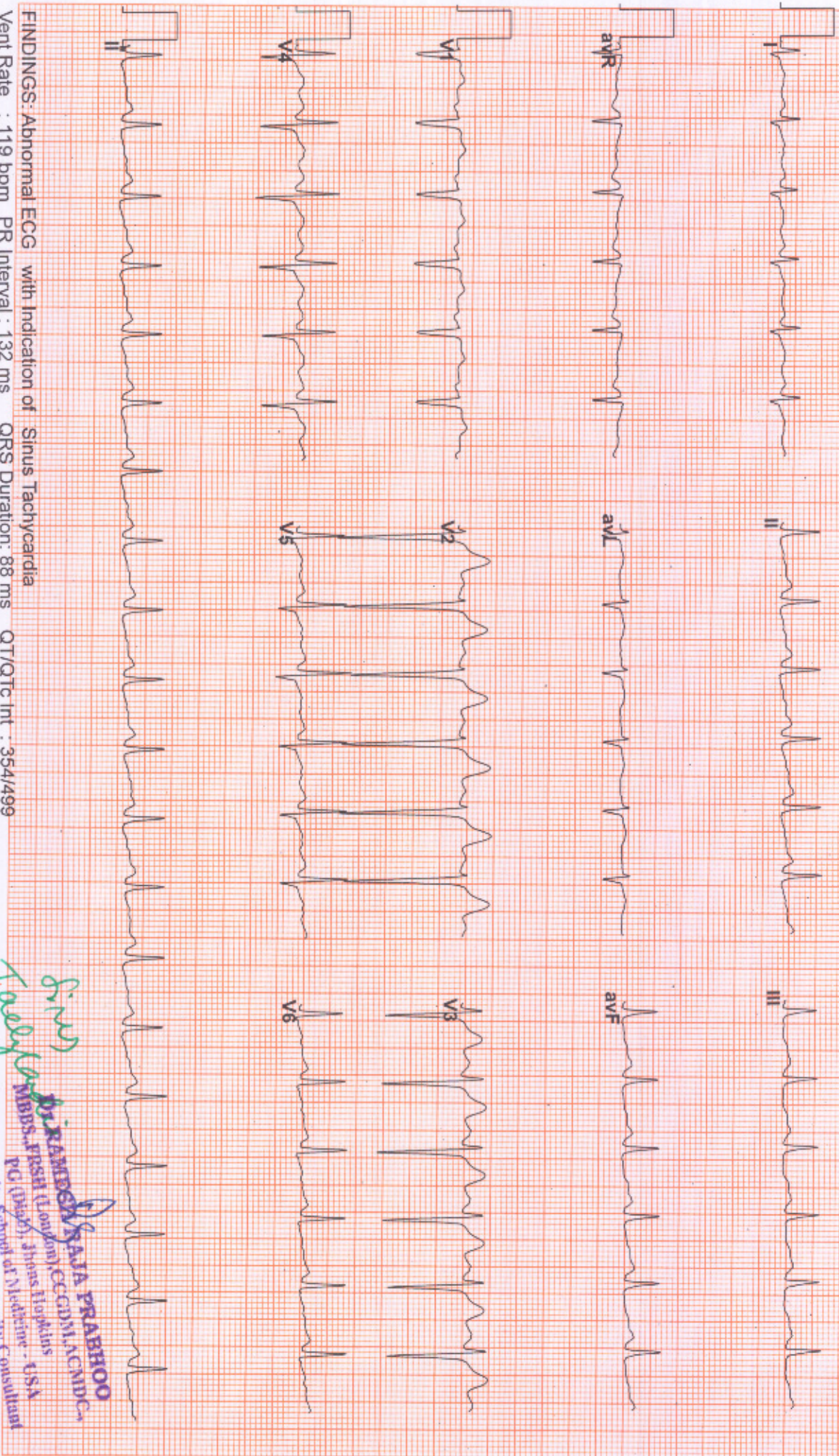

FINDINGS: Abnormal ECG with indication of Sinus Tachycardia

Vent Rate : 119 bpm PR Interval : 132 ms QRS Duration: 88 ms QT/QTc Int : 354/499

P-QRS-T axis: 63° 83° 7° (Deg)

Comments :

Advice:

THE MEDIHUB

CORPORATE WELLNESS CLINIC



ACCREDITED

Cardio-Diabetologist & Obesity Consultant
Regd. No: 72228/20477/15715

Dr. RAMESH RAJA PRAHOO
MBBS, FRCS (London), CC-DIM, ACNIDC
PG (Diab), Johns Hopkins
PG University School of Medicine - USA

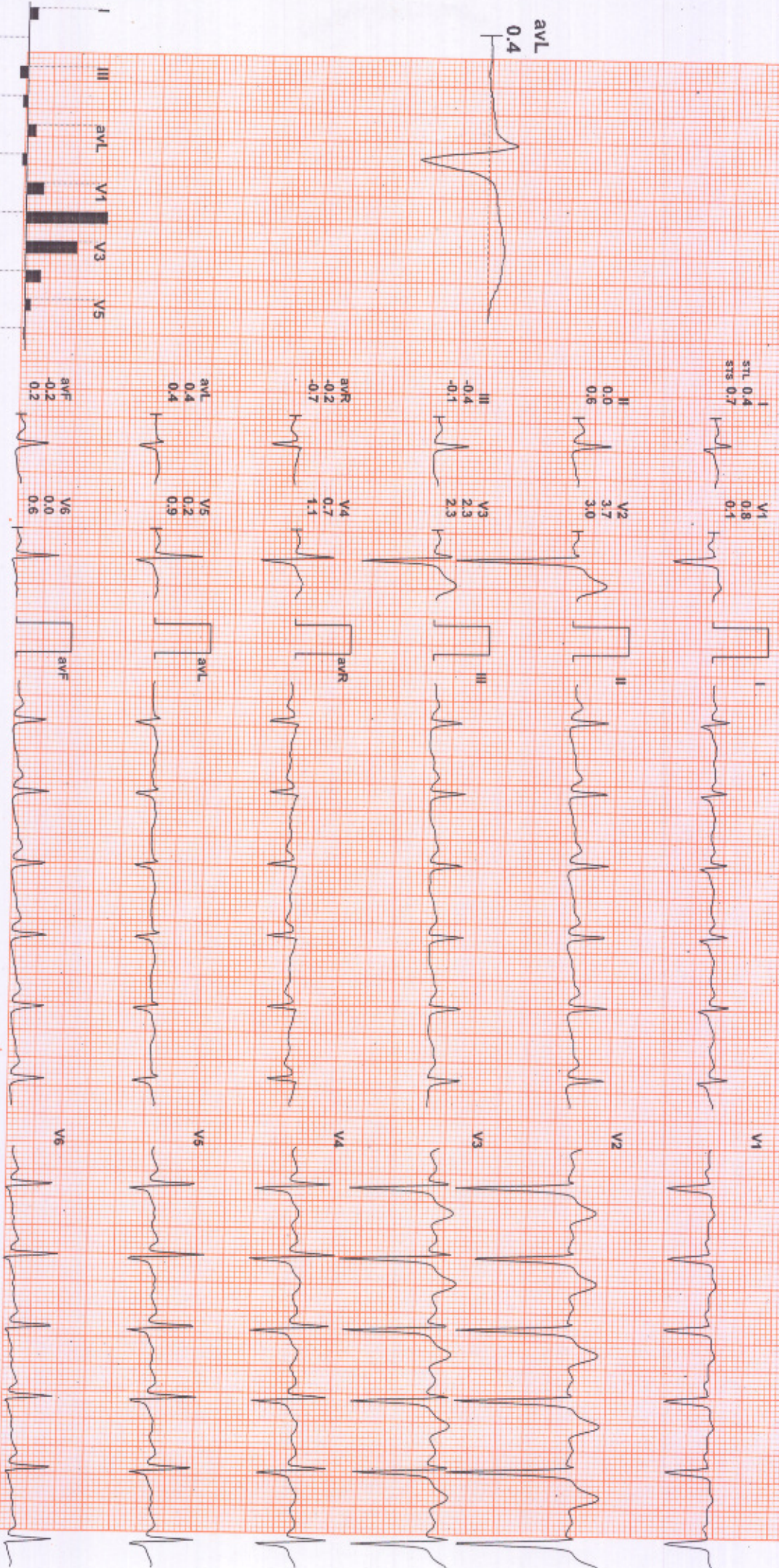
ISO 9001:2015 CERTIFIED COMPANY

12345218 / MR SATHIYA NARAYANAN.P / 43 YRS / M

Date: 23-03-2024 10:52:46 AM
4X
80 ms Post U

METS: 1.0 HR: 118 bpm 66% Trgt BP: 120/80 Raw ECG, BLC, Notch: (0.05-100)Hz

Resting ECG
RMS
ExTime: 00:00 1.1 mph, 0.0%
25 mm/Sec. 1.0 Cm/mv



COMMENTS:

RMS TMT MARK-II(4.0.1)RECORDERS AND MEDICARE SYSTEMS (P) Ltd, CHANDIGARH



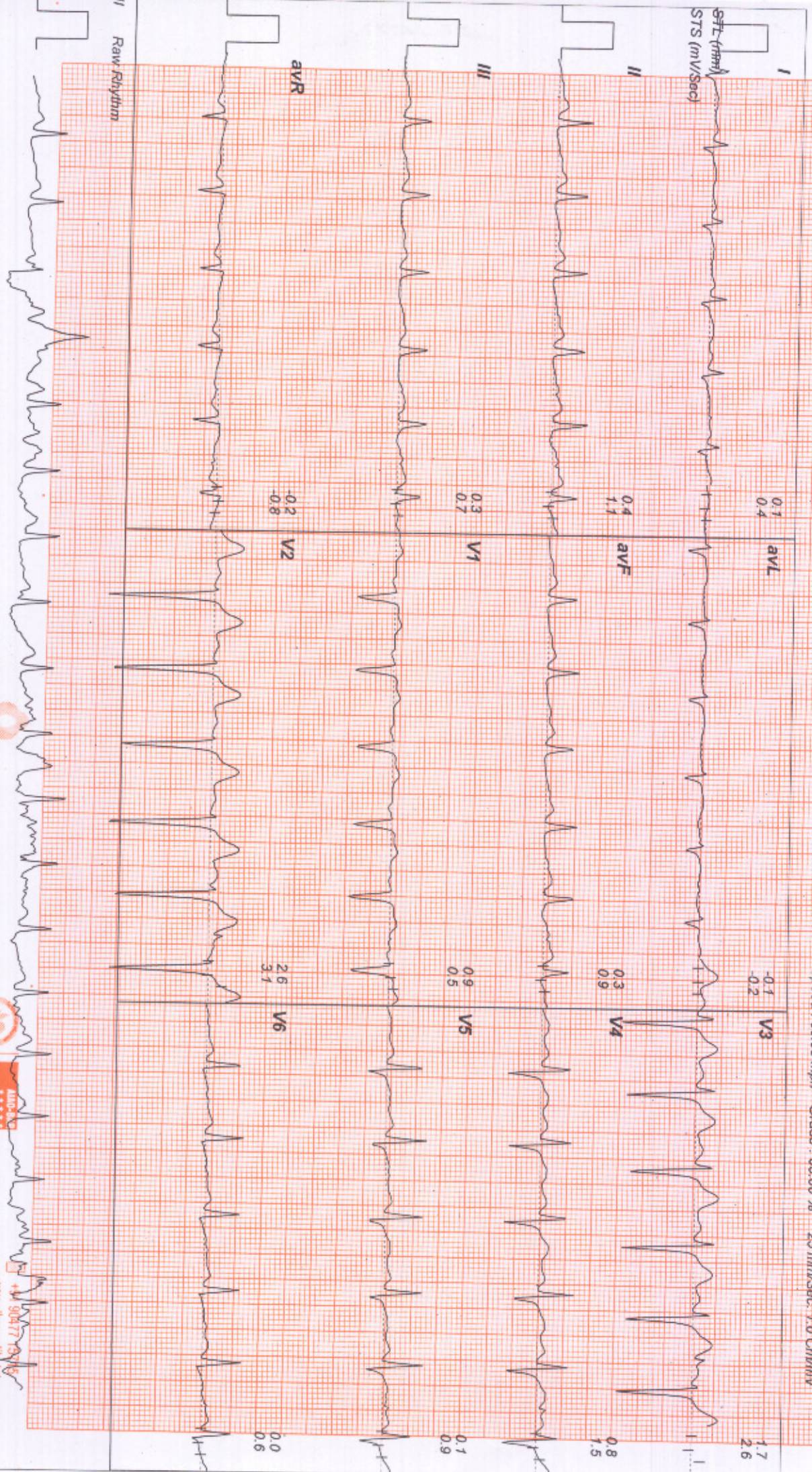
+91 90477 15715
www.themedhub.in

123457218 / MR SATHIYA NARAYANAN / P / 43 Yrs / Male / 0 Kg / 0 Cm / Non Smoker

Date: 23 - 03 - 2024 10:52:46 AM METS: 01:00 HR: 119 Target HR: 67% of 177 BP: 120/80 PostJ @80ms

ExTime: 01:54 Speed: 00:00 mph Grade: 00:00 % 25 mm/Sec: 1.0 Cm/mV

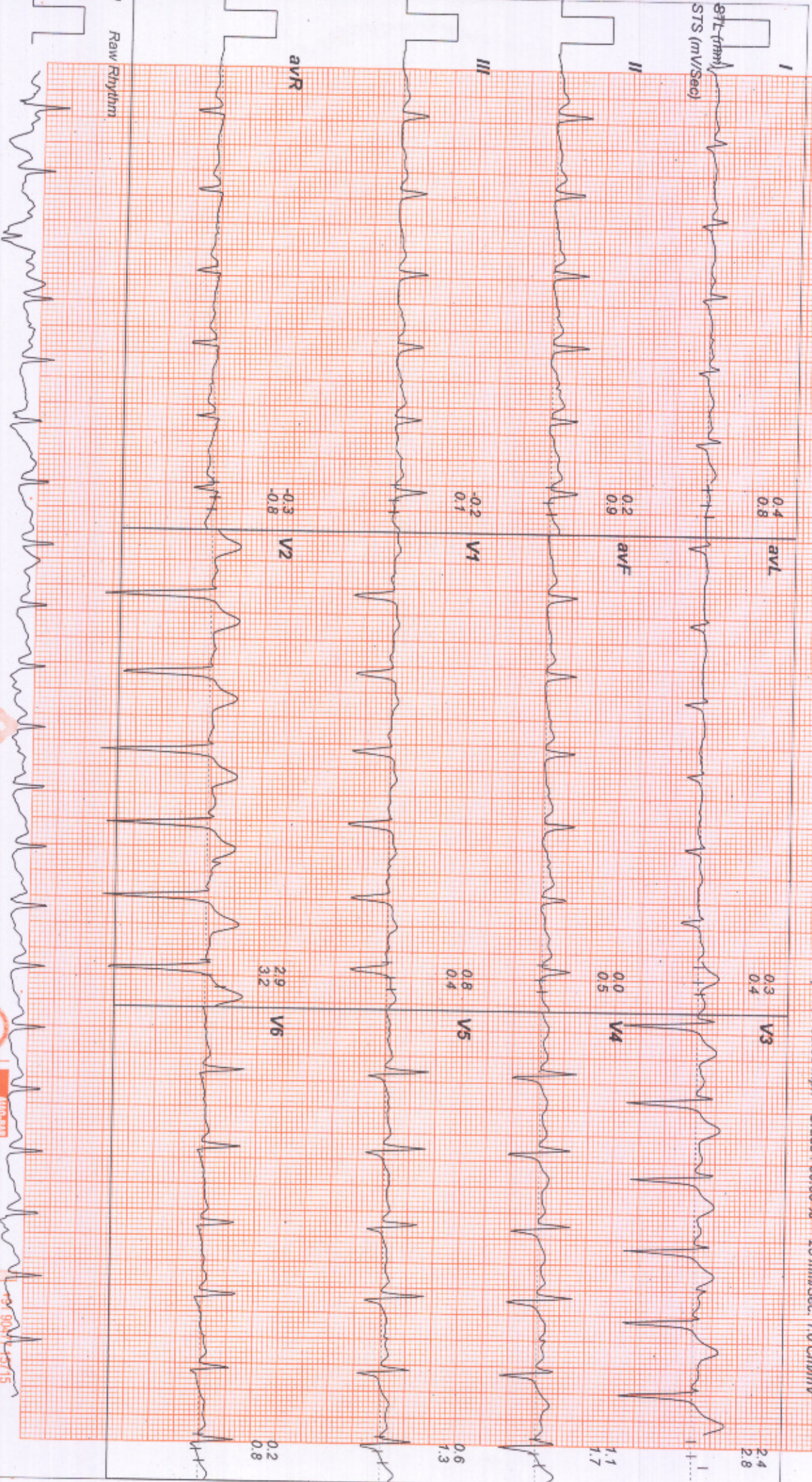
Linked Medians Report
STANDING



123457218 / MR SATHIYA NARAYANAN P / 43 Yrs / Male / 10 Kg / 10 Cm / Non Smoker

Date: 23 - 03 - 2024 10:52:46 AM METs: 01:00 HR: 122 Target HR: 68% of 177 BP: 120/80 Postl @80ms ExTime: 02:04 Speed: 00:00 mph Grade: 00:00 % 25 mm/Sec: 1.0 Cm/mV

Linked Medians Report
HV

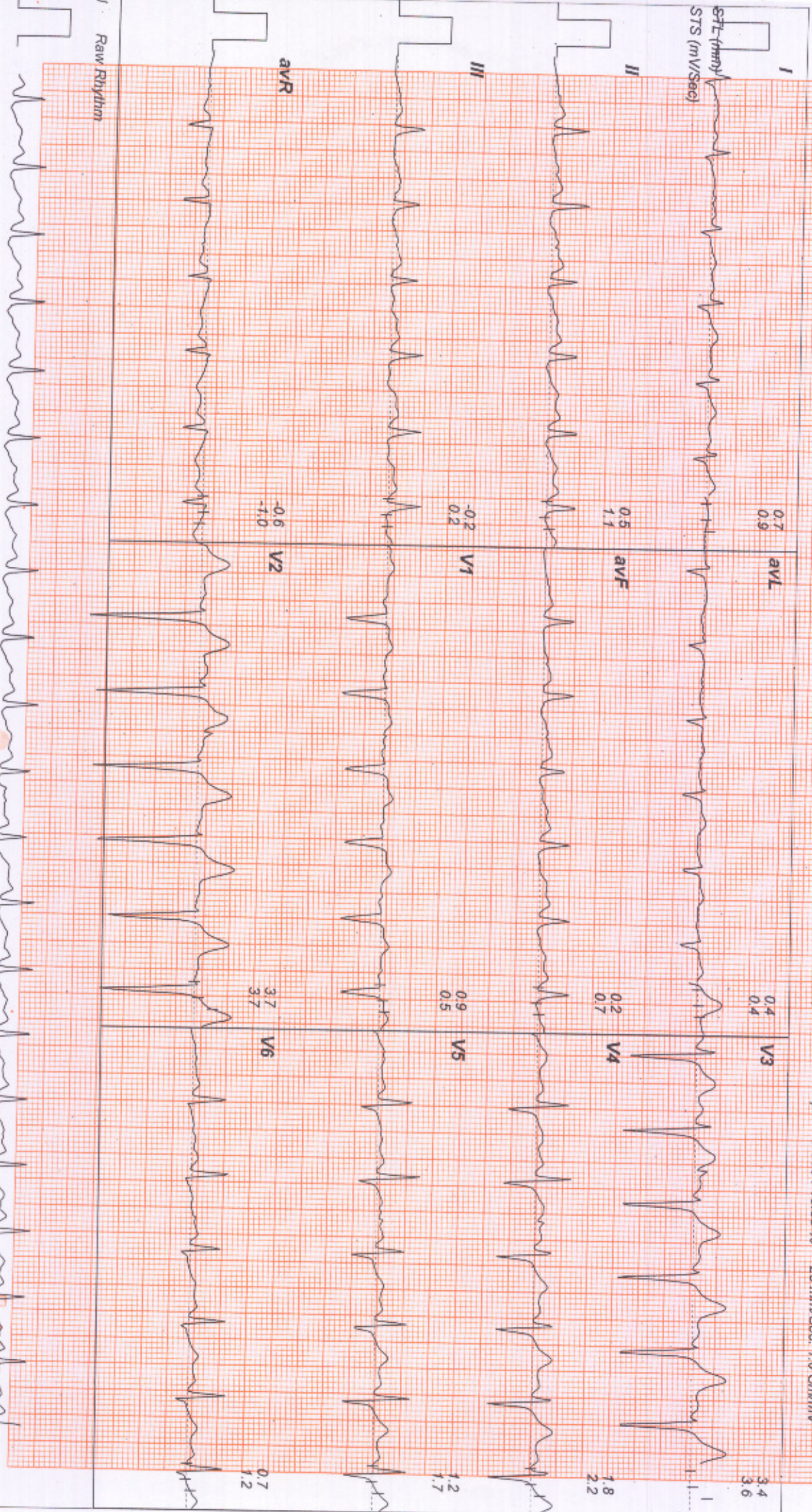


123457218 / MR SATHIYA NARAYANAN, P / 43 Yrs / Male / 0 Kg / 0 Cm / Non Smoker

Date: 23 - 03 - 2024 10:52:46 AM METs : 01.00 HR : 123 Target HR : 69% of 177 BP : 120/80 PostU @80ms

ExTime : 00:00 Speed : 01.70 mph Grade : 10.00 % 25 mm/Sec: 1.0 Cm/mV

Linked Medians Report
ExStt



RMS TMT MARK-II(4.0.1) RECORDERS AND MEDICARE SYSTEMS (P) LTD, CHANDIGARH

THE MEDIHUB
CORPORATE WELLNESS CLINIC

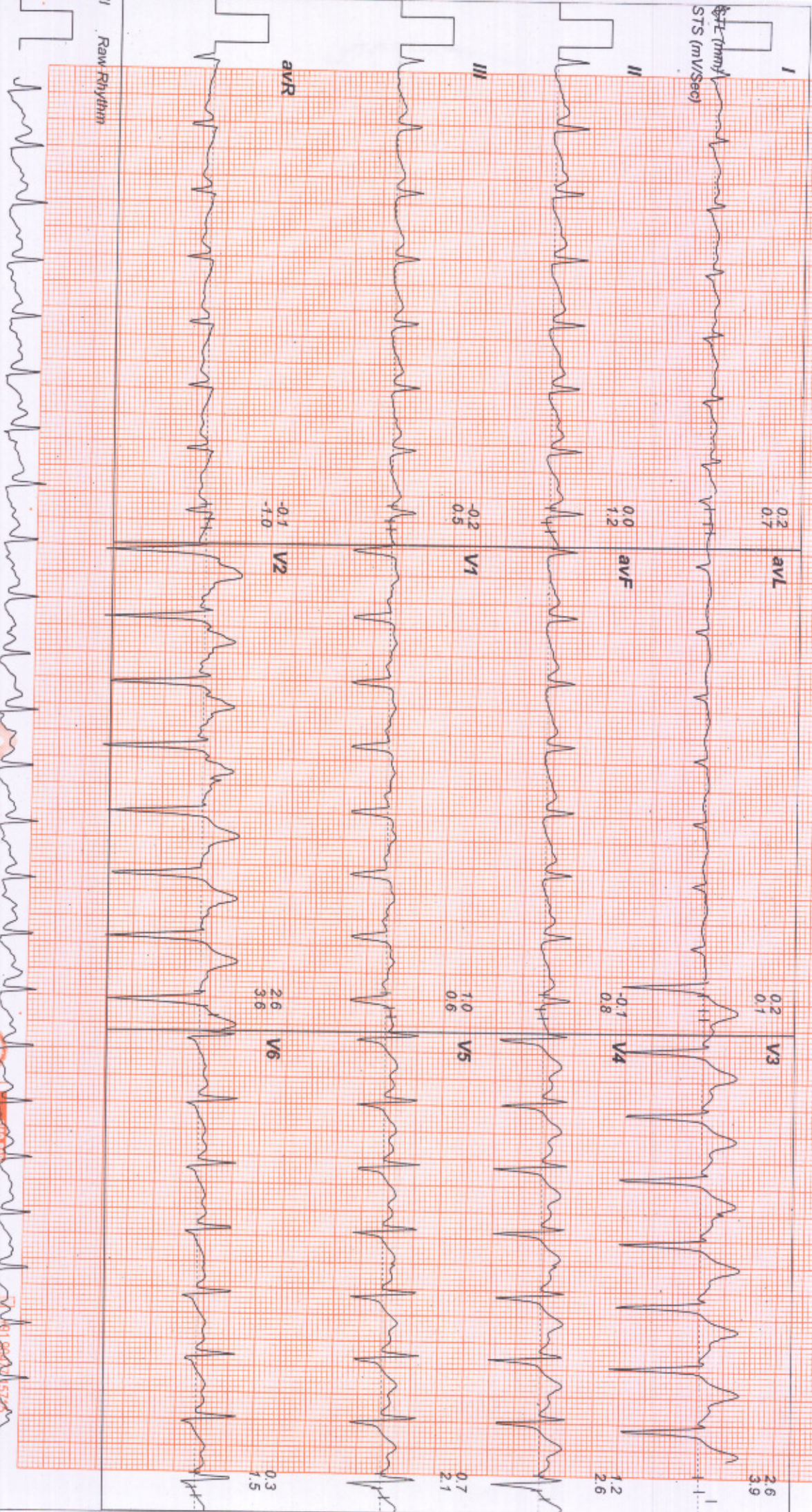


www.themedihub.in

123457218 / MR SATHIYA NARAYANAN.P / 43 Yrs / Male / 70 Kg / 0 Cm / Non Smoker

Date: 23 - 03 - 2024 10:52:46 AM METs: 04.70 HR: 146 Target HR: 82% of 177 BP: 130/90 Postu @ 60ms ExTime: 03:00 Speed: 01.70 mph Grade: 10.00% 25 mm/Sec 1.0 Cm/mV

Linked Medians Report
BRUCE : Stage 1 (03:00)



THE MEDIHUB
CORPORATE WELLNESS CLINIC

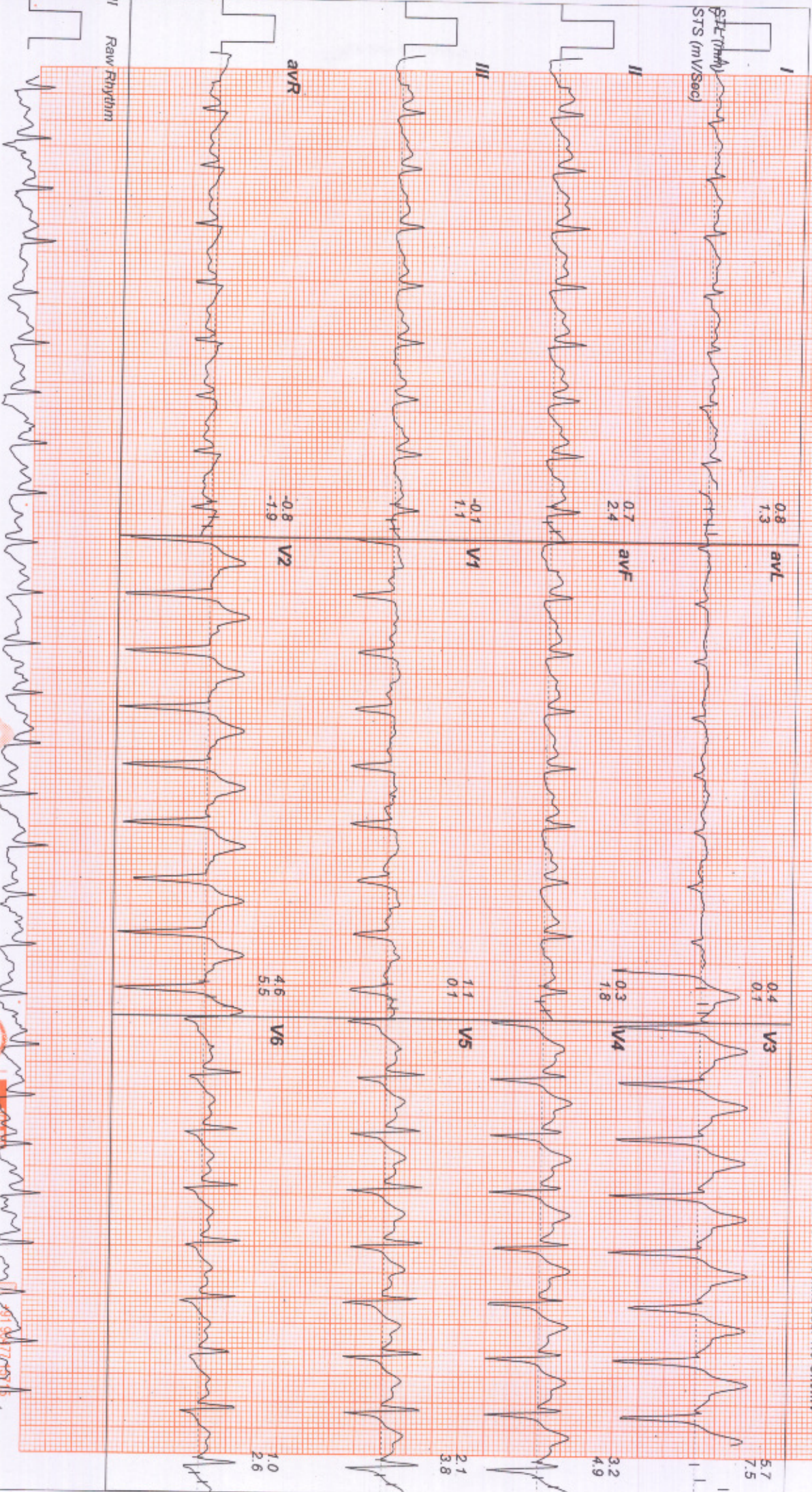


01 9994 1575
www.themedihub.in

123457218 / MR SATHIYA NARAYANAN, P / 43 yrs / Male / 0 Kg / 0 Cm / Non Smoker

Date: 23 - 03 - 2024 10:52:46 AM METs: 07.10 HR: 159 Target HR: 89% of 177 BP: 140/100 PostU @60ms ExTime: 06:00 Speed: 02.50 mph Grade: 12.00% 25 mm/Sec: 1.0 Cm/mV

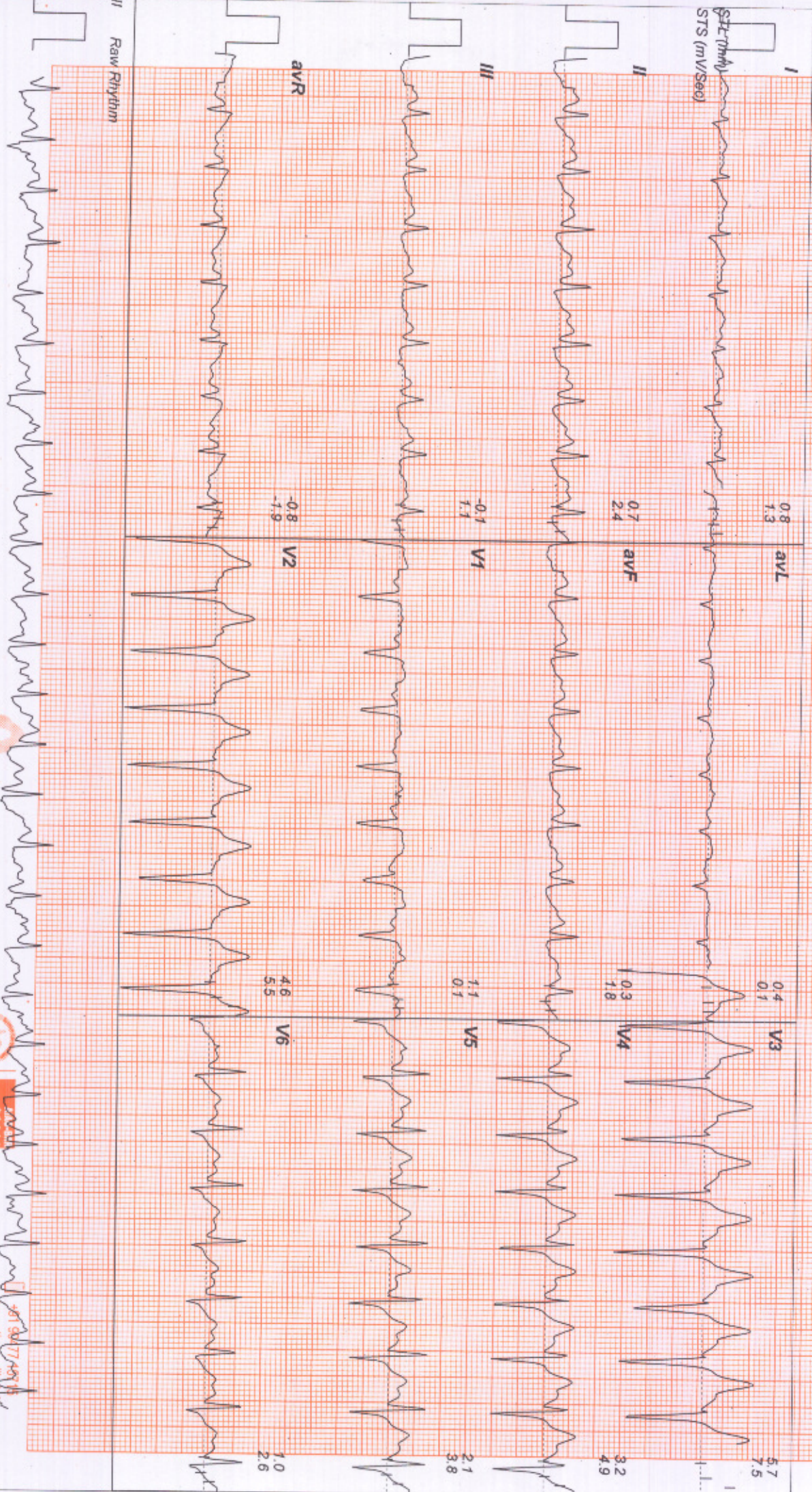
Linked Medians Report
BRUCE : Stage 2 (03:00)



123457218 / MR SATHIYA NARAYANAN P / 43 Yrs / Male / 10 Kg / 10 Cm / Non Smoker

Date: 23-03-2024 10:52:46 AM METs: 07.20 HR: 164 Target HR: 92% of 177 BP: 140/100 Postl @ 60ms ExtTime: 06:03 Speed: 03.40 mph Grade: 14.00% 25 mm/Sec 1.0 Cm/mV

Linked Medians Report
PeakEx

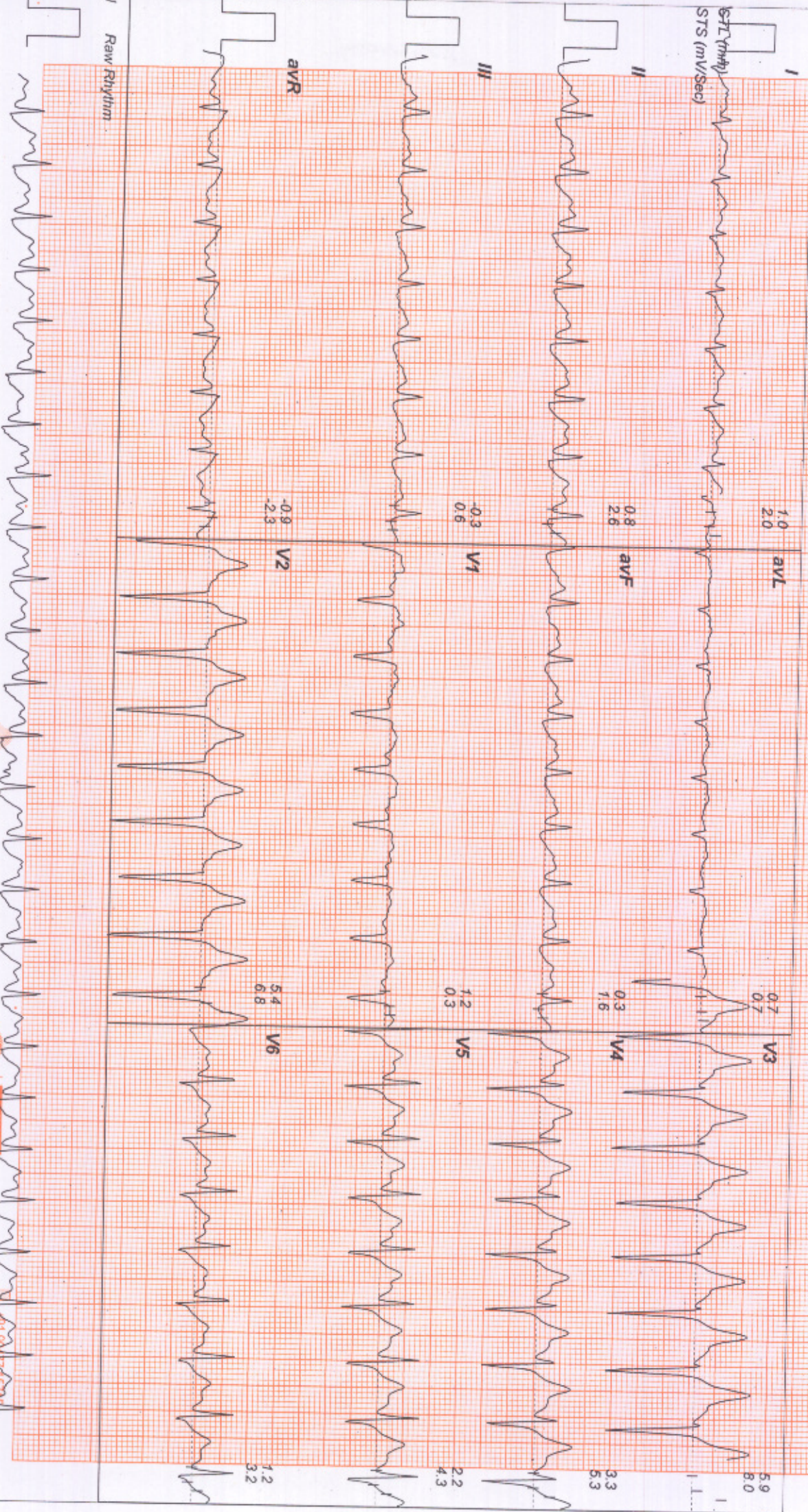


123457218 / MR SATHYA NARAYANAN P / 43 Yrs / Male / 0 Kg / 0 Cm / Non Smoker

Date: 23 - 03 - 2024 10:52:46 AM METs : 01:10 HR : 153 Target HR : 86% of 177 BP : 140/100 Postd @60ms

ExtTime : 06:03 Speed : 01:10 mph Grade : 00.00% 25 mm/Sec 1.0 Cm/mV

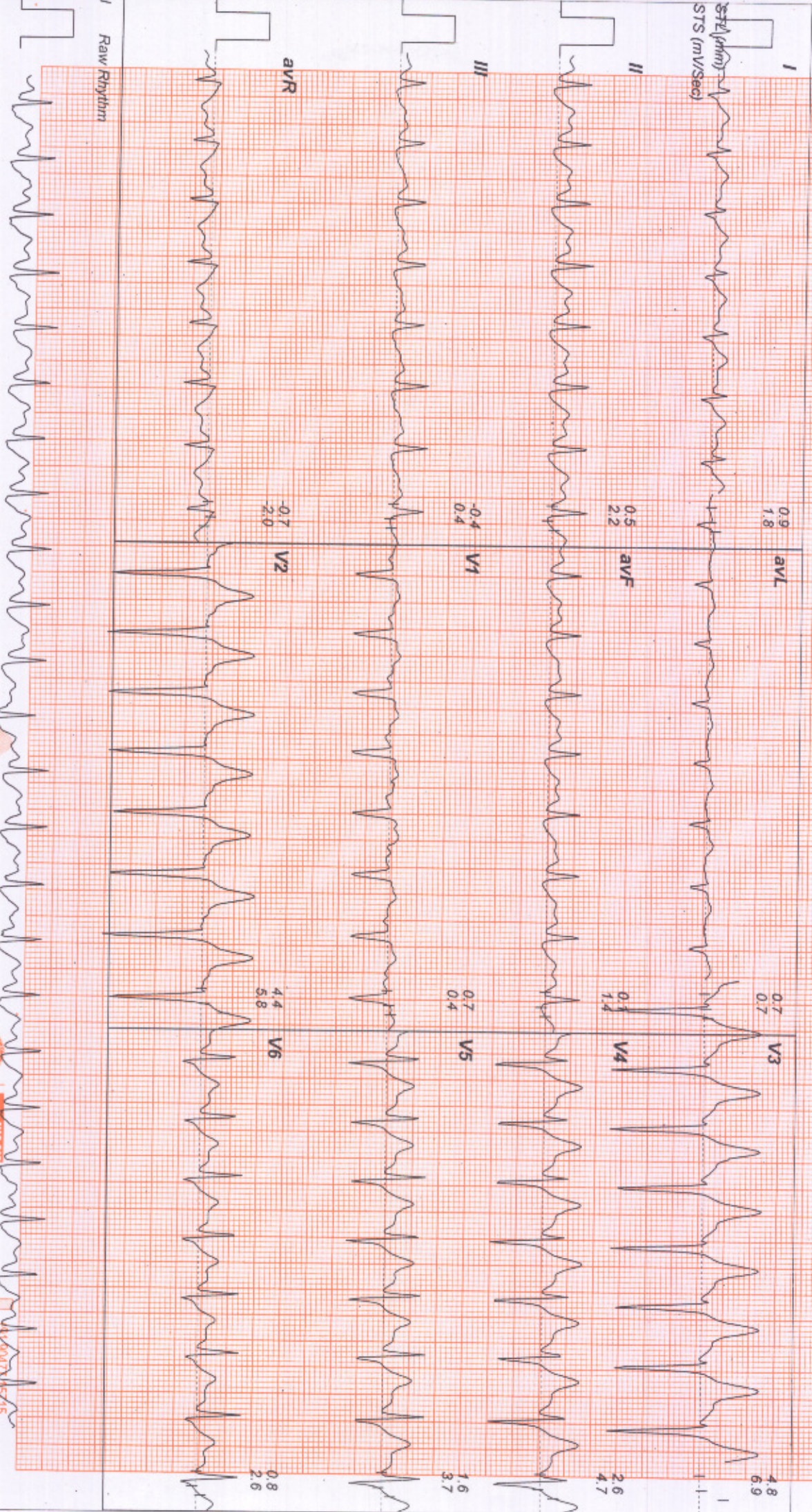
Linked Medians Report
Recovery : (01:00)



123457218 / MR SATHIYA NARAYANAN P / 43 Yrs / Male / 1.0 Kg / 1.0 Cm / Non Smoker

Date: 23 - 03 - 2024 10:52:46 AM METs : 01:00 HR: 143 Target HR: 80% of 177 BP: 130/90 Postl @60ms ExTime : 06:03 Speed : 01:10 mph Grade : 00:00 % 25 min/Sec: 1.0 Cm/min

Linked Medians Report
Recovery : (02:00)



123457218 / MR SATHIYA NARAYANAN.P / 43 Yrs / Male / 0 Kg / 0 Cm / Non Smoker

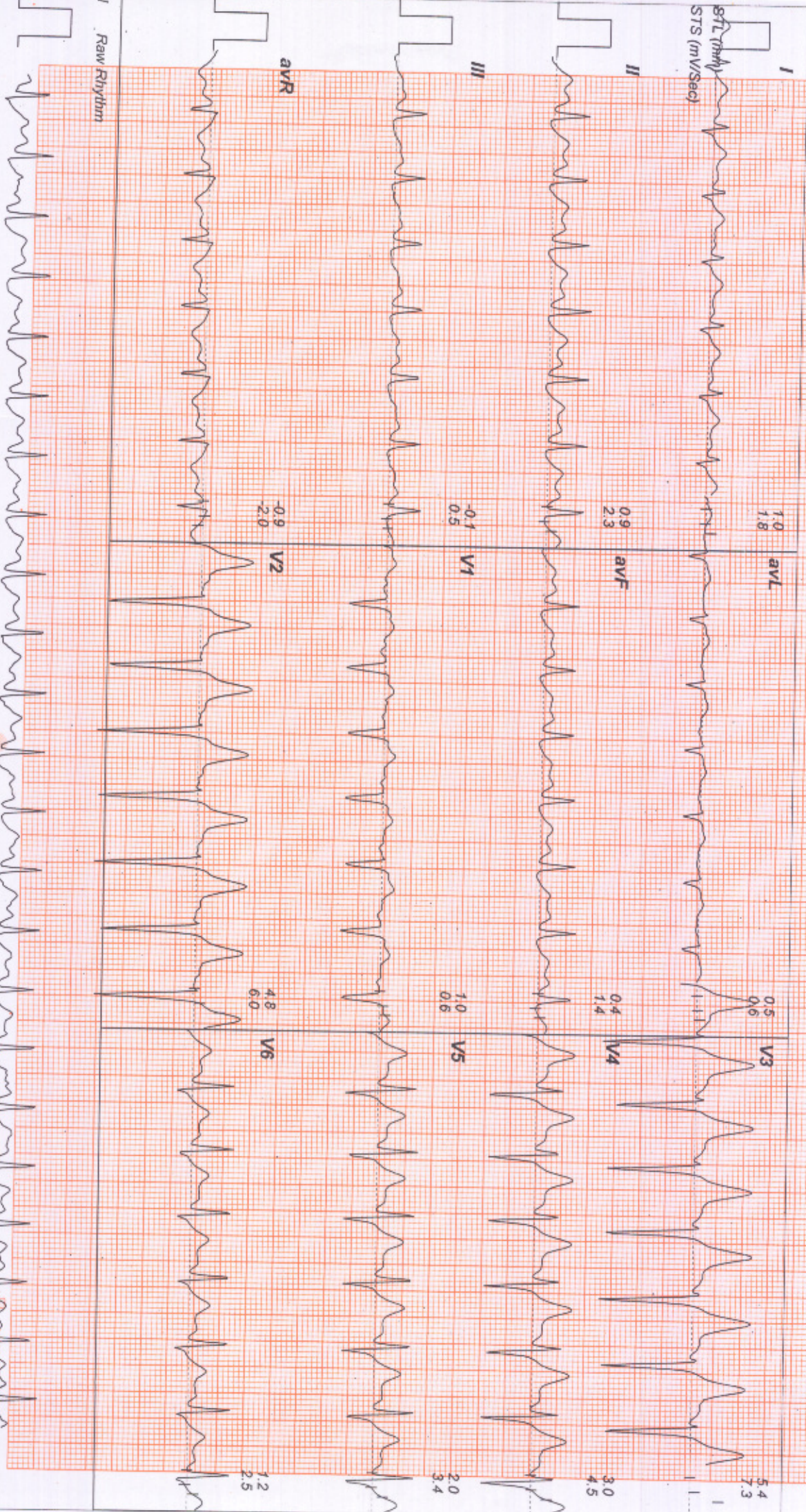
Date: 23 - 03 - 2024 10:52:46 AM METs: 01.00 HR: 135 Target HR: 76% of 177

BP: 120/80 PostU @60ms

ExTime: 06:03

Speed: 01.10 mph Grade: 00.00% 25 mm/Sec: 1.0 Cm/mV

Linked Medians Report Recovery: (03:00)



RMS TMT MARK-II(4.0) RECORDERS AND MEDICARE SYSTEMS (P) LTD, CHANDIGARH



www.themedihub.in



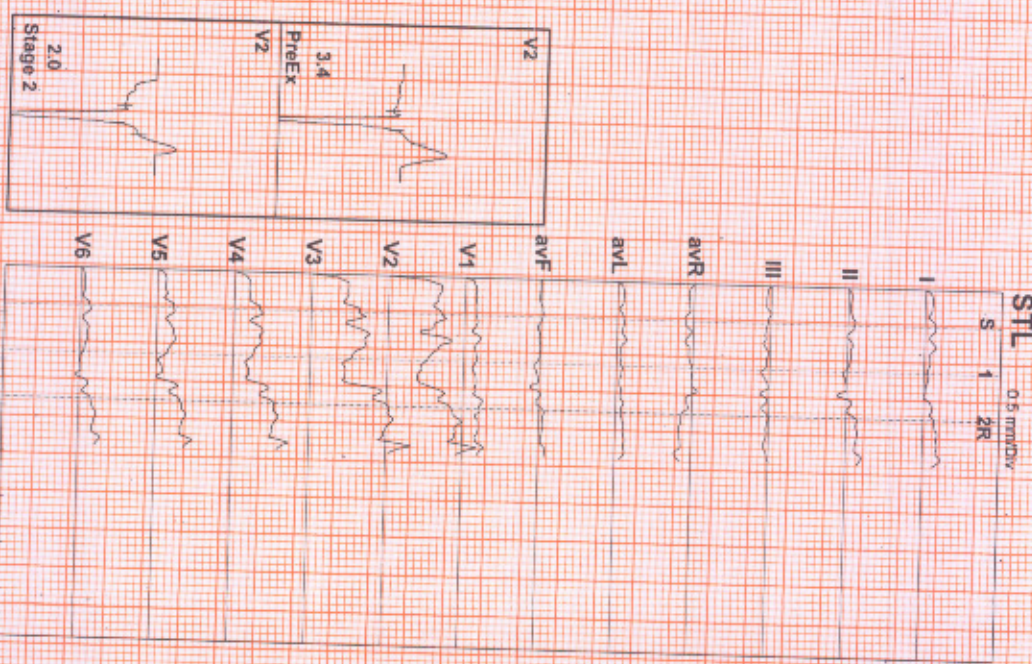
123457218 / MR SATHIYA NARAYANAN P / 43 Yrs / M / 0 Kg / 0 Cms / NonSmoker
 Date: 23-03-2024

Medication : Nil
 Ref. By : SELF
 Protocol : BRUCE
 Objective : FOR TESTING PURPOSE ONLY
 History : Nil

Stage	StageTime (Min:Sec)	Speed (mph)	Grade (%)	METS	H.R. (bpm)	B.P. (mmHg)	R.P.P. x100	PVC	Comments
Supine				1.0	121	120/80	145	-	
Supine				1.0	119	120/80	142	-	
Supine				1.0	120	120/80	144	-	
Standing				1.0	117	120/80	140	-	
HV				1.0	122	120/80	146	-	
ExStart				1.0	125	120/80	150	-	
Stage 1	3:00	1.7	10.0	4.7	146	130/90	189	-	
Stage 2	3:00	2.5	12.0	7.1	159	140/100	222	-	
PeakEx	0:03	3.4	14.0	7.2	161	140/100	225	-	
Recovery	1:00	1.1	0.0	1.2	153	140/100	214	-	
Recovery	2:00	1.1	0.0	1.0	143	130/90	185	-	
Recovery	3:00	1.1	0.0	1.0	135	120/80	162	-	
Recovery	3:03	1.1	0.0	1.0	133	120/80	159	-	

Findings :
 Exercise Time : 06:04
 Max HR Attained : 161 bpm 91% of Target 177
 Max BP : 140/100
 Max Workload attained : 7.2 (Fair Effort Tolerance)

TM Negative for Inducible Ischemia



Advice/Comments:

DR. RAMESH RAJA PRABHU
 MBBS, FRSH (Lop), OCGD, ACCMPC
 PG (Diab), Sports Medicine
 University School of Medicine, USA
 Cardiac-Diabetologist & Obesity Consultant
 Report No: 72228

MEDICAL CENTRE

Name : Mr. Sathiyasagar .

Regn. No : 167991

Age / Gender : 43 | m

Date : 23/3/2024

Height :

Weight :

Temp :

BP :

A/S-16

SIB - DR. Abinaya priya

C/C :- check up.

O/E :- plaque & calculus.

Impacted (partially) $\frac{8}{8}$

Sc $\frac{87}{77}$



THE MEDIHUB

CORPORATE WELLNESS CLINIC



ISO 9001:2015 CERTIFIED COMPANY

OCCUPATIONAL HEALTH | INSURANCE HEALTH | CORPORATE HEALTH
ALLIED PUBLIC HEALTH | INDUSTRIAL SAFETY & HEALTH

Name: MR.SATHIYA NARAYANAN

Age: 43 YRS

ID No: PDF 1317/2024 Sex: Male

Ref By: Dr. RAMESH RAJA PRABHOO M.B.B.S; F.R.S.H.

Date : 23.03.2024

ULTRA SOUND SCAN OF ABDOMEN

Clinical status: Routine clinical examination.

Liver:

Liver: Few small benign granulomatous calcifications are seen in segment 8 largest Measures 6 mm.

Intrahepatic biliary radicles are not dilated.

Portal and hepatic veins are normal.

No focal lesion.

Gallbladder: Gallbladder is normal in size.

No calculi or sludge seen in the gallbladder.

Wall is not thickened.

Spleen: Normal in size and echo pattern.

Pancreas: Head, body and tail of pancreas is normal.

Kidneys:

Right kidney is normal in size with normal echoes.

Left kidney is normal in size with normal echoes.

Corticomedullary differentiation is maintained.

There is no free fluid in peritoneal cavity.

Urinary Bladder: is Normal.

Prostate: is Normal.

IMPRESSION:

SMALL BENIGN GRANULOMATUS CALCIFICATIONS IN RIGHT LOBE OF THE LIVER.



Dr. Rajalakshmi.C

M.B.B.S; D.M.R.D.

Registration No:58990

+91 915 916 0777
+91 9047 715 715

 themedihubcorp@gmail.com
corporatedotsfoundation@gmail.com

 No. 2, 1st Cross, SRP Ponnusamy Nagar
Behind V.V. Vani Vidhyalaya School, Saibaba Colony,
Coimbatore - 641 011 Tamil Nadu, India



THE MEDIHUB
CORPORATE WELLNESS CLINIC



ISO 9001:2015 CERTIFIED COMPANY

OCCUPATIONAL HEALTH | INSURANCE HEALTH | CORPORATE HEALTH
ALLIED PUBLIC HEALTH | INDUSTRIAL SAFETY & HEALTH

Patient Name	MR.SATHIYA NARAYANAN.P	Age / Sex	43 Years/ M
Ref. by	APOLLO	Sample Date	23.03.2024

HAEMATOLOGY

COMPLETE HAEMOGRAM (CBC)

Total WBC Count	8100	cells/cumm	4000 - 11000
Diff.Count			
Polymorphs	65	%	45 - 75
Lymphocytes	30	%	22 - 45
Eosinophil	02	%	00 - 08
Monocytes	02	%	00 - 06
Basophils	01	%	00 - 02
Hemoglobin	12.4	gms %	M:13 - 18, F:12 - 16
ESR-1 hr	14	mm	M-15/1 hr.F-20/1 hr
Hematocrit(PCV)	36.9	%	M:40 - 56, F:36 - 50
Total RBC Count	4.32	million cells/cumm	4.0 - 6.0
Platelet Count	2.81	lakhs/cumm	1.5 - 4.0
MCV	85.4	fL	76 - 96
MCH	26.5	pg/cell	25 - 33
MCHC	31.0	g/dl	30 - 36
Blood Group & Rh Type	" B " Positive		

BIO CHEMISTRY

TEST NAME	RESULTS	UNITS	NORMALRANGE
Fasting Blood Sugar	241.2	mg/dl	70 - 110
PP 2Hrs Sugar	381.7	mg/dl	80 - 130

RENAL FUNCTION TEST

TEST NAME	RESULTS	UNITS	NORMALRANGE
BUN	12.6	mg/dl	5 - 25
Creatinine	0.95	mg/dl	0.5 - 1.5
Uric acid	4.5	mg %	2.6 - 6.0
Urea	25.3	mg/dl	10 - 45
Calcium	9.0	mg/dl	8.0 - 11.0

Dr. SRIDEVI
MD PATHOLOGY
REGD No : 96985
THE MEDIHUB

+91 915 916 0777
+91-9047 715 715

the medihubcorp@gmail.com
corporatedotsfoundation@gmail.com

No. 2, 1st Cross, SRP Ponnusamy Nagar
Behind V.V. Vani Vidhyalaya School, Saibaba Colony,
Chimbatore - 641 011 Tamil Nadu, India



THE MEDIHUB

CORPORATE WELLNESS CLINIC



ISO 9001:2015 CERTIFIED COMPANY

**OCCUPATIONAL HEALTH | INSURANCE HEALTH | CORPORATE HEALTH
ALLIED PUBLIC HEALTH | INDUSTRIAL SAFETY & HEALTH**

Patient Name	MR.SATHIYA NARAYANAN.P	Age / Sex	43 Years/ M
Ref. by	APOLLO	Sample Date	23.03.2024

LIPID PROFILE

TEST NAME	RESULTS	UNITS	NORMALRANGE
Total Cholesterol	230.0	mg/dl	Desirable : Below 200 Borderline : 201 – 240 Undesirable: Above 241
Serum Triglycerides	125.5	mg/dl	Desirable : Below 160 Borderline : 161 – 180 Undesirable: Above 181
HDL Cholesterol	48.8	mg/dl	Desirable : Above 41 Borderline : 35 – 40 Undesirable: Below 34
LDL Cholesterol	156.1	mg/dl	Desirable : Below 140 Borderline : 141 – 160 Undesirable: Above 161
VLDL Cholesterol	25.1	mg/dl	20 - 45

THYROID PROFILE

TEST NAME	RESULTS	UNITS	NORMALRANGE
Total Triiodothyronine (T3)	160.54	ng/dL	58-159
Total Thyroxine (T4)	11.96	ug/dL	4.87-11.72
Thyroid StimulatinHormone(TSH)	5.11	uIU/mL	0.35-4.94

T3 : Competitive Chemi Luminescent Immuno Assay

T4 : Competitive Chemi Luminescent Immuno Assay

TSH :Ultra Sensitive Sandwich Chemi Luminescent Immuno

Dr. SRIDEVI
MD PATHOLOGY
REGD No : 96985
THE MEDIHUB

+91 915 916 0777
+91 9047 715 715

✉ themedihubcorp@gmail.com
corporatedotsfoundation@gmail.com

📍 No. 2, 1st Cross, SRP Ponnusamy Nagar
Behind V.V. Vani Vidhyalaya School, Saibaba Colony,
Coimbatore, 541 011, Tamil Nadu, India



THE MEDIHUB
CORPORATE WELLNESS CLINIC



ISO 9001:2015 CERTIFIED COMPANY

OCCUPATIONAL HEALTH | INSURANCE HEALTH | CORPORATE HEALTH
ALLIED PUBLIC HEALTH | INDUSTRIAL SAFETY & HEALTH

Patient Name	MR.SATHIYA NARAYANAN.P	Age / Sex	43 Years/ M
Ref. by	APOLLO	Sample Date	23.03.2024

LIVER FUNCTION TEST

TEST NAME	RESULTS	UNITS	NORMAL RANGE
Bilirubin Total	0.7	mg/dl	0.2 - 1.2
Bilirubin Direct	0.4	mg/dl	Up to 0.6
Bilirubin Indirect	0.3	mg/dl	Up to 0.8
SGOT (AST)	38.9	U/L	Up to 39
SGPT (ALT)	35.6	U/L	Up to 40
Alkaline Phosphatase	101.2	U/L	50 - 128
Total Protein	7.4	gm/dl	6.0 - 8.0
Albumin	4.8	gm/dl	3.5 - 5.5
Globulin	3.4	gm/dl	2.3 - 3.5
A/G Ratio	1.41:1	gm/dl	1.5 - 2.5
Gamma GT	33.9	U/L	Upto 45
Serum PSA	2.29	ng/ml	Up to 4


Diabetes Screen (Blood)

HbA1c	6.8	%	Below 6.0 – Non-Diabetic 6.1 – 7.4 – Good Control 7.5 – 8.0 – Fair Control 8.1 – 10.0 – Unsatisfactory Control Above 10.0 – Poor Control
-------	-----	---	--

Dr. SRIDEVI
MD PATHOLOGY
REGD No : 96985
THE MEDIHUB

+ 91 915 916 0777
+ 91 9047 715 715

 themedihubcorp@gmail.com
corporatedotsfoundation@gmail.com

 No. 2, 1st Cross, SRP Ponnusamy Nagar
Behind V.V. Vani Vidhyalaya School, Saibaba Colony,
Coimbatore - 641 011. Tamil Nadu, India.



THE MEDIHUB

CORPORATE WELLNESS CLINIC



ISO 9001:2015 CERTIFIED COMPANY



ACCREDITED

OCCUPATIONAL HEALTH | INSURANCE HEALTH | CORPORATE HEALTH
ALLIED PUBLIC HEALTH | INDUSTRIAL SAFETY & HEALTH

Patient Name	MR.SATHIYA NARAYANAN.P	Age / Sex	43 Years/ M
Ref. by	APOLLO	Sample Date	23.03.2024

URINE ROUTINE ANALYSIS

Microscopic Examination

Colour	Pale Yellow
Appearance	Clear
Reaction	Acidic
Albumin	Nil
Sugar	Yellow (++)
Acetone	Negative
Bile Salt	Negative
Bile Pigments	Negative
Urobilinogen	Not Increased
Specific Gravity	1.017

Microscopic Examination

Pus Cells	1-4/ hpf
RBC's	Nil
Epithelial Cells	0-3/ hpf
Casts	Nil
Crystal	Nil
Bacteria	Nil

Body Mass Index:

BMI : 28.0

BMI Categories: Underweight = <18.5

Normal weight = 18.5–24.9

Overweight = 25–29.9

Obesity = BMI of 30 or greater

Dr. SRIDEVI
MD PATHOLOGY
REGD No : 96985
THE MEDIHUB

+91 915 916 0777
+91 9047 715 715

themedihubcorp@gmail.com
corporatedotsfoundation@gmail.com

No. 2, 1st Cross, SRP Ponnusamy Nagar
Behind V.V. Vani Vidhyalaya School, Saibaba Colony,
Coimbatore - 641 011 Tamil Nadu, India



THE MEDIHUB

CORPORATE WELLNESS CLINIC



ISO 9001:2015 CERTIFIED COMPANY



OCCUPATIONAL HEALTH | INSURANCE HEALTH | CORPORATE HEALTH
ALLIED PUBLIC HEALTH | INDUSTRIAL SAFETY & HEALTH

Patient Name	MR.SATHIYA NARAYANAN.P	Age / Sex	43 Years/ M
Ref. by	APOLLO	Sample Date	23.03.2024

PERIPHERAL SMEAR

PERIPHERAL SMEAR REPORT :

RBCs : RBC's are normocytic normochromic. No nucleated Red

CellsAre seen.

Platelets : Adequate.

WBC : Total count and differential count are within normal limits.

DC - (P 65 L 30 M 2 E 2 B 1)

DIAGNOSIS : NORMOCHROMIC NORMOCYTIC BLOOD PICTURE

+91 915 916 0777
+91 9047 715 715

themedihubcorp@gmail.com
corporatedotsfoundation@gmail.com

Dr. SRIDEVI
MD PATHOLOGY
REGD No : 96985

No. 2, 1st Cross, P.M. Nagar
Behind V.V. Vani Vidhyalaya School, Saibaba Colony,
Coimbatore - 641 011 Tamil Nadu, India



THE MEDIHUB

CORPORATE WELLNESS CLINIC



ISO 9001:2015 CERTIFIED COMPANY



ACCREDITED

OCCUPATIONAL HEALTH | INSURANCE HEALTH | CORPORATE HEALTH
ALLIED PUBLIC HEALTH | INDUSTRIAL SAFETY & HEALTH

Name	MR SATHIYA NARAYANAN	Date	23.03.2024
AGE/SEX	43 / M		

CHEST X- RAY (PA VIEW)

- Both the lung fields are clear.
- Hilar shadows are normal.
- CP recesses are free bilaterally.
- Cardiac size and contour within normal limits.
- Diaphragmatic domes are regular bilaterally.

Impression: Normal X-Ray Chest.

Dr. RAMESH SATHIYA PRABHOO
MBBS., FISH (London), CCGDMLACMDC.,
PG (Diab), Johns Hopkins
University School of Medicine - USA
Cardio-Diabetologist & Obesity Consultant
Regd.No: 72228

+91 915 916 0777
+91 9047 715 715

✉ themedihubcorp@gmail.com
corporatedotsfoundation@gmail.com

📍 No. 2, 1st Cross, SRP Ponnusamy Nagar
Behind V.V. Vani Vidhyalaya School, Saibaba Colony,
Coimbatore - 641 011. Tamil Nadu, India.