

ID: 10210350
Name: MR RAJASEKAR
Age: 34 Years
Gender: Male
Race:

2024-04-09 10:00:07 AM

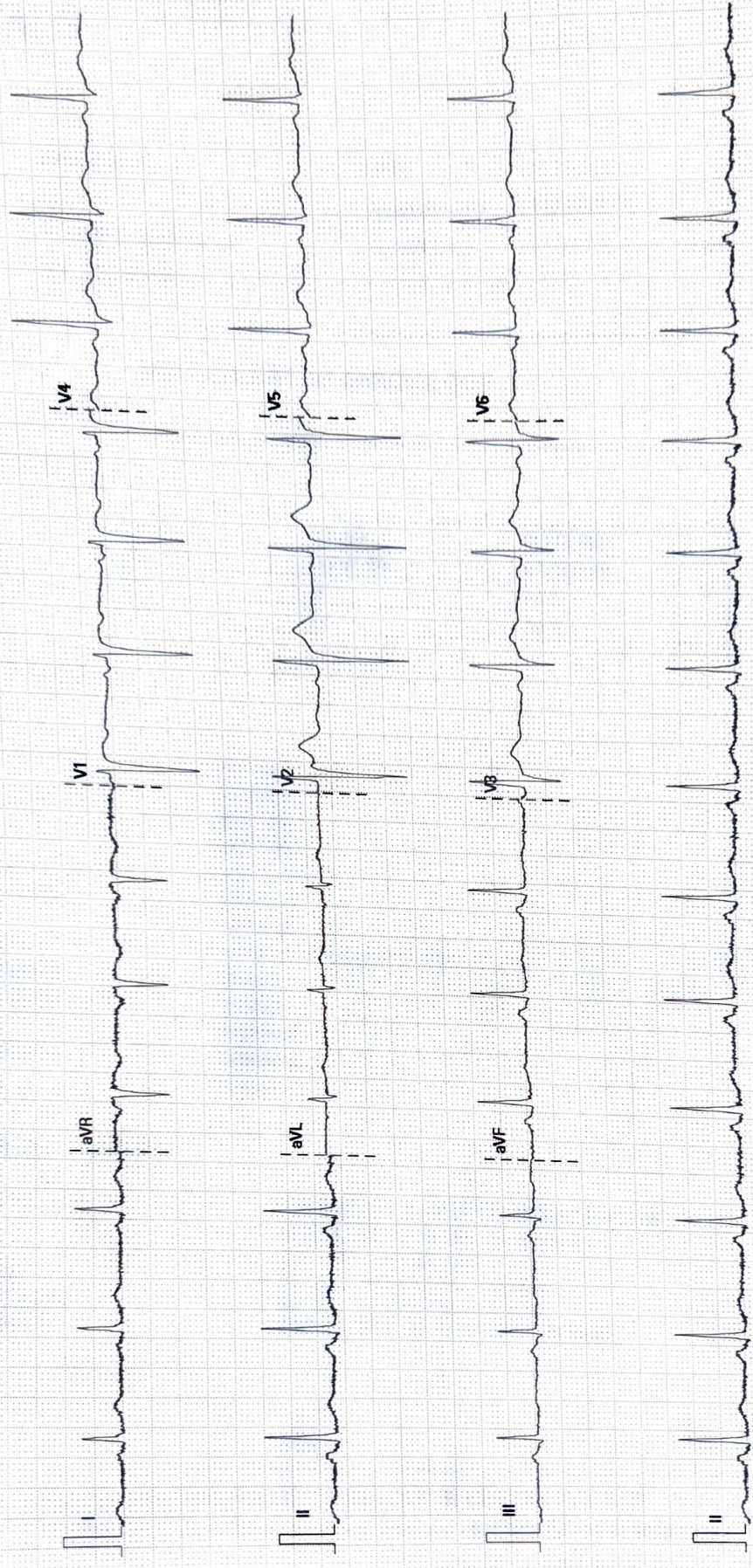
Vent. Rate
PR Interval
QRS Duration
QT/QTc Interval
P/ORS/T Axes
QTc-Hodges

80 bpm
136 ms
96 ms
360/395 ms
67/58/45 deg

Sinus rhythm
Normal ECG

Unconfirmed Diagnosis

Handwritten notes:
①
②





PRASHANTH HOSPITALS

Name	: RAJASEKAR R	UHID	: 10210350
Sex / Age	: M / 34Y	Accession NO	: 9121185175
Study Date	: 9/4/2024, 11:17:00 am	Report Date	: 9/4/2024, 10:47:09 am
Ref Dr.	: DR. GOPALASWAMY G		

DEPARTMENT OF CARDIOLOGY

INVESTIGATION: ECHO

LV MEASUREMENTS

AO	31 mm	IVS d/s	09/12 mm
LA	36 mm	LVPW d/s	07/10 mm
LVID (ED)	46 mm	EF	66 %
LVID (ES)	29 mm	FS	36 %

MORPHOLOGICAL DATA

MITRAL VALVE :

AML	:	NORMAL
PML	:	NORMAL
CHORDAE	:	NORMAL
AORTIC VALVE	:	NORMAL
TRICUSPID VALVE	:	NORMAL
PULMONARY VALVE	:	NORMAL
ATRIA	:	NORMAL
RIGHT VENTRICLE	:	NORMAL FUNCTION (TAPSE : 2.1 cm)
INTER ATRIAL SEPTUM	:	INTACT
INTER VENTRICULAR SEPTUM	:	INTACT
AORTA	:	NORMAL
PULMONARY ARTERY	:	NORMAL
PERICARDIUM	:	NORMAL

DOPPLER DATA :

MITRAL VALVE	:	NORMAL E/A RATIO AT MITRAL INFLOW TRIVIAL MR E : 81 cm/s, A : 66 cm/s E/E' : 11.3 , S' : 10.7 cm/s
AORTIC VALVE	:	NO AR, NO AS, VEL : 114 cm/s
PULMONARY VALVE	:	NO PR, NO PS, VEL : 90 cm/s
TRICUSPID VALVE	:	TRIVIAL TR / NO PAH / TRPG: 20 mmHg

A Unit of PRASHANTH FERTILITY RESEARCH CENTRE PVT. LTD.

No. 36 & 36A, Velachery Main Road, Velachery, Chennai - 600 042. ☎ +91 93 8099 8099

☎ +91 44 4680 5544 / 2243 9494 ✉ info@prashanthhospitals.org 🌐 www.prashanthhospitals.org



PRASHANTH HOSPITALS

Name	: RAJASEKAR R	UHID	: 10210350
Sex / Age	: M / 34Y	Accession NO	: 9121185175
Study Date	: 9/4/2024, 11:17:00 am	Report Date	: 9/4/2024, 10:47:09 am
Ref Dr.	: DR. GOPALASWAMY G		

IMPRESSION

- ◆ NO REGIONAL WALL MOTION ABNORMALITY
- ◆ NORMAL LV SYSTOLIC AND DIASTOLIC FUNCTION (LVEF: 66 %)
- ◆ NORMAL RIGHT VENTRICLE FUNCTION (TAPSE: 2.1 cm)
- ◆ NO PERICARDIAL EFFUSION
- ◆ NO EVIDENCE OF CLOT OR VEGETATION

DONE BY : KARTHIKA. V
SR.ECHO TECHNOLOGIST

Dr. Sivakumar
MBBS.MD.,DNB.,FNB
Sr. Consultant Interventional Cardiologist
Reg. No: 68984

A Unit of PRASHANTH FERTILITY RESEARCH CENTRE PVT. LTD.

No. 36 & 36A, Velachery Main Road, Velachery, Chennai - 600 042. ☎ +91 93 8099 8099

☎ +91 44 4680 5544 / 2243 9494 ✉ info@prashanthhospitals.org 🌐 www.prashanthhospitals.org



PRASHANTH HOSPITALS

Name	: RAJASEKAR R 34 YRS	UHID	: 10210350
Sex / Age	: M / ---	Accession NO	: 180053778
Study Date	: 9/4/2024, 11:06:21 am	Report Date	: 9/4/2024, 3:40:22 pm
Ref Dr.	: DR. G . GOPALASWAMY		

CHEST X-RAY

Trachea and both main bronchi are normal.
Cardiac silhouette and cardiothoracic ratio are normal
Bilateral lung fields are clear. No focal lesion seen.
The cardiophrenic and costophrenic angles are free.
Both hemi diaphragms appear normal.
Bony thorax appears normal.

IMPRESSION:

No significant abnormality detected.


Dr. NARMADHA, MBBS., DMRD
CONSULTANT RADIOLOGIST
REG NO: 93293



PRASHANTH HOSPITALS

Patient Name	Mr. Rajasekar R	Age / Sex	34 Y/ M
Patient ID	10210350	Visit No.	1
Ref. By	Dr. G.Gopalaswamy	Visit Date	09.04.2024

USG Complete Abdomen

Upper Abdomen:

Liver normal in size measures 12.6 cm and filled with homogeneous parenchymal echoes. No abscess or mass lesion in the liver. No dilatation of intrahepatic biliary radicals seen. Gall bladder walls and lumen appeared normal. No calculi seen. Common duct appeared normal. No calculi seen. Portal vein and Pancreas appeared normal. Spleen measured 10.3 cm and appeared normal. No free fluid seen in the hepatorenal pouch.

KUB

RT. Kidney measures 10.0 x 4.4 cm. Cortex appears normal. Cortico medullary differentiation is maintained. Pelvicalyceal system is not dilated. No calculus is seen. Right ureter is not dilated.

LT. Kidney measures 11.2 x 5.1 cm. Cortex appears normal. Cortico medullary differentiation is maintained. Pelvicalyceal system is not dilated. No calculus is seen. Left ureter is not dilated.


Urinary Bladder is normal in contour. No intra luminal echoes are seen. No calculus or diverticulum is seen.

Prostate: Appears normal in size and measures 3.2 x 3.4 x 3.5 cm (Vol = 19.7 cc). It shows homogenous echogenicity. No intravesical extension.

Retroperitoneum: Aorta and IVC appears normal. No obvious para aortic lymphadenopathy. No free fluid in peritoneal cavity. Pleural spaces appeared normal.

Impression:

- No significant abnormality detected in the visualized organs.


Dr. Narmadha, DMRD
Consultant Radiologist
Reg no : 93293

Note: This investigation has its own limitation. Hence sonographic findings should be correlated with clinical features and with further investigations. Not for medico legal purpose.

A Unit of PRASHANTH FERTILITY RESEARCH CENTRE PVT. LTD.

No. 36 & 36A, Velachery Main Road, Velachery, Chennai - 600 042. ☎ +91 93 8099 8099

☎ +91 44 4680 5544 / 2243 9494 ✉ info@prashanthhospitals.org 🌐 www.prashanthhospitals.org



PRASHANTH HOSPITALS

EYE CHECK-UP REPORT

NAME : Mrs. Rajasekar. R

DATE : 09/11/24

AGE / SEX : 34 / M

UHID NUM : 10210350

Chief complaints : Regular eye check up

Past history : —

Systemic Diseases : —

DISTANCE VISION :

WITH OUT GLASS : 6/6, N6 6/6, N6

WITH GLASS : — —

COLOR VISION : NORMAL / ABNORMAL

GLASS PRESCRIPTION :

EYE	SPH	CYL	AXIS	V/A	SPH	CYL	AXIS	V/A
DISTANCE	± Plano	—	—	6/6	± Plano	—	—	6/6
ADD	—	—	—	N6	—	—	—	N6

ANTERIOR SEGMENT :

CORNEA & LENS : BE NONT

REMARK : CONTINUE WITH SAME GLASSE

ROUTINE CHECK UP AFTER 6/12 MONTH ✓

FUNDUSCOPY ONCE A YEAR

OPTOMETRIST

A Unit of PRASHANTH FERTILITY RESEARCH CENTRE PVT. LTD.

No. 36 & 36A, Velachery Main Road, Velachery, Chennai - 600 042. ☎ +91 93 8099 8099

📞 +91 44 4680 5544 / 2243 9494 📧 info@prashanthhospitals.org 🌐 www.prashanthhospitals.org