



Medicover Hospitals
VENKOJIPALAM VISAKHAPATNAM - 530017
ANDHRA PRADESH - INDIA
PHONE NO : 0891-6829999



**MEDICOVER
HOSPITALS**
A UNIT OF SAHRUDAYA HEALTHCARE PVT LTD.

**Dr. RAKESH P
MD
GENERAL PHYSICIAN**

NAME : P. Swarnalatha AGE 32 / F

WT: 74.2 kgs
HT: 148 cm's
BP: 110 / 78
PR 78

Medicover Unit - I
18-1-3, KGH Down, Maharani-peta,
Jagadamba Junction, Visakhapatnam
Andhrapradesh - 530 002.
Ph: +91 96526 69351

Medicover Unit - III
Sry. No.27, Plot No.05, BRTS Road,
Health City, Arilova, Chinnagadhili Mandal,
Visakhapatnam, Andhrapradesh - 530 040.
Ph: +91 0891 6677888

Medicover - MVP
1-1-83, Sector-6, Venkojipalem,
MVP Colony, Visakhapatnam,
Andhrapradesh-530017.
Ph: +91 8886655677



**MEDICOVER
HOSPITALS**

A UNIT OF SAHRUDAYA HEALTHCARE PVT LTD

MEDICOVER HOSPITALS

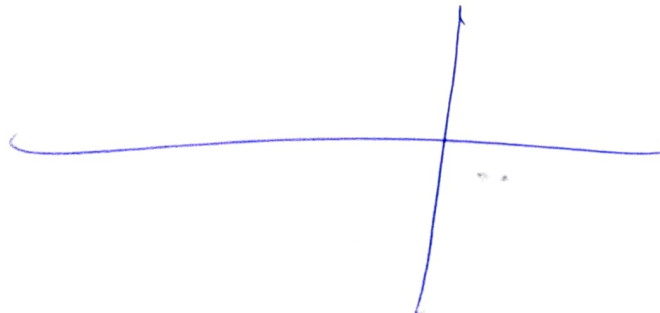
VENKOJIPALEM VISAKHAPATNAM -530017
ANDHRA PRADESH -INDIA
PHOpppNE NO ; 0891-6829999

Dr. DENTAL CONSULTATION CONSULTANT DENTAL

NAME :

AGE :

c/c : Pt has come for a general check
up



stainst
Colabs +

Adv
~~Aspirin~~ Senguel-f - (1)
Tubipaste



Medicover Hospitals

VENKOJIPALAM VISKHAPATNAM -530017

ANDHRA PRADESH -INDIA

PHONO NO : 0891-6829999



MEDICOVER HOSPITALS

A UNIT OF SAHRUDAYA HEALTHCARE PVT LTD.

OPHTHALMOLOGIST CONSULTATION

NAME: _____ AGE: _____

DATE :

m < 6/6
6/6

no tho dr. H5

Als wase

Sp: - normal

low 1 o'dr/m
o'dr/m

ll

Medicover Unit - I

18-1-3, KGH Down, Maharanieta,
Jagadamba Junction, Visakapatnam,
Andhrapradesh - 530 002.
Ph: +91 96526 69351

Medicover Unit - III

Sry. No. 27, Plot No. 05, BRTS Road,
Health City, Arilova, Chinnagadalu Mandal,
Visakhapatnam, Andhrapradesh - 530 040.
Ph: +91 08916677888

Medicover - MVP

1-1-83, Sector -6, Venkojipalem,
MVP Colony, Visakapatnam,
Andhrapradesh-530017.
Ph: +91 8886655677



Medicover Hospitals

VENKOJIPALAM VISAKHAPATNAM - 530017
ANDHRA PRADESH - INDIA
PHONE NO : 0891-6829999



MEDICOVER
HOSPITALS

A UNIT OF SAHRUDAYA HEALTHCARE PVT LTD.

Dr.Tanuja Priyadarsini Velaga

MBBS,DGO,FMAS,FRM

GYNAECOLOGY CONSULTATION

Name

:

Mrs. P. Sumanalatha

Age

:

32

F

UMRNO

:

13/4/24.

MH: S/SO, reg, MF, PL, U.

Dr.

counselled for

HPV vaccination &

Pap Smear

Medicover Unit - I

18-1-3, KGH Down, Maharani-peta,
Jagadamba Junction, Visakhapatnam
Andhrapradesh - 530 002.
Ph: +91 96526 69351

Medicover Unit - III

Sry. No.27, Plot No.05, BRTS Road,
Health City, Arilova, Chinnagadhili Mandal,
Visakhapatnam, Andhrapradesh - 530 040.
Ph: +91 0891 6677888

Medicover - MVP

1-1-83, Sector-6, Venkojipalem,
MVP Colony, Visakhapatnam,
Andhrapradesh-530017.
Ph: +91 8886655677



Medicover Hospitals
VENKOJIPALAM VISAKHAPATNAM - 530017
ANDHRA PRADESH - INDIA



Lab Report

A UNIT OF SAHRUDAYA HEALTHCARE PVT LTD.

Patient Name : **Mrs. PONNADA SWARNALATHA** Age /Gender : **32 Y(s)/Female**
 Bill No/ UMR No : **V4BC224201/V4U180796** Referred By : **Dr. CMO**
 Received Dt : **13-Apr-24 08:45 am** Report Date : **13-Apr-24 09:57 am**
 Lab No : **120000603357**

<u>Parameter</u>	<u>Result Values</u>	<u>Biological Reference</u>
CBC(COMPLETE BLOOD COUNT)		
RBC		
HAEMOGLOBIN	12.8	12.0 - 15.0 g/dl
R B C COUNT	4.8	3.8 - 4.8 10 ⁶ /μL
PCV/HCT	38	36 - 46 %
MCV	* 79	83 - 101 fl
MCH	27	27 - 32 pg
MCHC	34	31.5 - 34.5 g/dL
RDW(cv)	* 14.7	11.6 - 14.0 %
WBC		
TC (TOTAL LEUCOCYTE COUNT)	10800	4000 - 11000 cells/cumm
DIFFERENTIAL COUNT		
NEUTROPHILS	60	40 - 80 %
LYMPHOCYTES	31	20 - 40 %
MONOCYTES	05	02 - 10 %
EOSINOPHILS	04	00 - 06 %
BASOPHILS	00	00 - 01 %
PLATELET COUNT		
PLATELET COUNT	3.40	1.50 - 4.50 Lakhs/cumm
ESR	25	0 - 20 mm/1st hour

*** End Of Report ***

Doctor Incharge

Dr.MUDUGANTI SRINIVAS
MBBS, MD
CONSULTANT PATHOLOGIST

Dr.SRUJANA
MBBS, MD PATHOLOGY
CONSULTANT PATHOLOGIST

Dr.MOHAMMAD SIMI IQBAL
M.B.B.S, M.D
CONSULTANT BIOCHEMIST

Medicover Unit - I
18-1-3, KGH Down, Maharaniapeta,
Jagadamba Junction, Visakapatnam,
Andhrapradesh - 530 002.
Ph: +91 96526 69351

Medicover Unit - III
Sry. No. 27, Plot No. 05, BRTS Road,
Health City, Arilova, Chinnagadalu Mandal,
Visakhapatnam, Andhrapradesh - 530 040.
Ph: +91 08916677888

Medicover - MVP
1-1-83, Sector -6, Venkojipalem,
MVP Colony, Visakapatnam,
Andhrapradesh-530017.
Ph: +91 8886655677



Medicover Hospitals

VENKOJIPALAM VISAKHAPATNAM - 530017
ANDHRA PRADESH - INDIA



MEDICOVER HOSPITALS

A UNIT OF SAHRUDAYA HEALTHCARE PVT LTD.

Lab Report

Patient Name	: Mrs. PONNADA SWARNALATHA	Age /Gender	: 32 Y(s)/Female
Bill No/ UMR No	: V4BC224201/V4U180796	Referred By	: Dr. CMO
Received Dt	: 13-Apr-24 08:45 am	Report Date	: 13-Apr-24 10:23 am
Lab No	: 120000603358		

<u>Parameters</u>	<u>Result</u>	<u>Biological Reference Intervals</u>
LIPID PROFILE		
TOTAL CHOLESTEROL	146	No risk : < 200 mg/dL Moderate risk : 200 - 239 High risk : > 240
HDL CHOLESTEROL	40	<40 Low >60 High
LDL CHOLESTEROL	* 92	Border line : 100 - 130 mg/dL High : > 130 mg/dL Desirable : < 100 mg/dL 100 - 130 mg/dL
VLDL	14	
SERUM TRYGLYCERIDES	72	Very High : > 500 mg/dL High : >= 200 - 499 mg/dL Border line High : >= 150 - 199 mg/dL Normal : < 150 mg/dL Normal : < 4.0 Low risk : 4.0 - 6.0 High risk : > 6.0
CHO/HDL RATIO	* 3.65	
LDL/HDL RATIO	2.3	
FBS (FASTING BLOOD GLUCOSE)		
FASTING BLOOD GLUCOSE	92	Normal : 70-99 mg/dL Impaired : 100-125 mg/dL Diabetic : >= 126 mg/dL
CREATININE	0.7	0.6 - 1.1 mg/dL
LFT(LIVER FUNCTION TEST)		
TOTAL BILIRUBIN	0.5	< 1.2 mg/dL
DIRECT BILIRUBIN	0.1	<= 0.20 mg/dL
INDIRECT BILIRUBIN	0.4	<= 1.0 mg/dL
SGPT (ALT)	10	<= 33 U/L
SGOT (AST)	14	<= 32 U/L
ALKALINE PHOSPHATASE (ALP)	84	35 - 105 U/L
TOTAL PROTEINS	7.8	1-2 years : 5.6-7.5 g/dL > 3 years : 6.0-8.0 g/dL
SERUM ALBUMIN	4.0	Adults : 6.4-8.3 g/dL NewBorn: 0-4 days : 2.8 - 4.4 g/dL Children: 4 days - 14 years : 3.8 - 5.4 g/dL 14-18 years : 3.2 - 4.5 g/dL Adults : 3.5- 5.2 g/dL

Medicover Unit - I

18-1-3, KGH Down, Maharanipecta,
Jagadamba Junction, Visakapatnam,
Andhrapradesh - 530 002.
Ph: +91 96526 69351

Medicover Unit - III

Sry. No. 27, Plot No. 05, BRTS Road,
Health City, Arilova, Chinnagadalu Mandal,
Visakhapatnam, Andhrapradesh - 530 040.
Ph: +91 08916677888

Medicover - MVP

1-1-83, Sector -6, Venkojipalem,
MVP Colony, Visakapatnam,
Andhrapradesh-530017.
Ph: +91 8886655677



Lab Report

Patient Name : **Mrs. PONNADA SWARNALATHA** Age /Gender : **32 Y(s)/Female**
Bill No/ UMR No : **V4BC224201/V4U180796** Referred By : **Dr. CMO**
Received Dt : **13-Apr-24 08:45 am** Report Date : **13-Apr-24 10:23 am**
Lab No : **120000603358**

Parameters	Result	Biological Reference In Method
GLOBULINS	* 3.8	2.5 - 3.5 g/dL
A/G RATIO	* 1.05	1.2 - 2.5
TOTAL PROTEIN		
TOTAL PROTEINS	7.8	1-2 years : 5.6-7.5 g/dL > 3 years : 6.0-8.0 g/dL Adults : 6.4-8.3 g/dL
HBA1C (GLYCOSYLATED HAEMOGLOBIN)		
HBA1C	* 5.7	Non -Diabetic : <= 5.6 % Pre Diabetic : 5.7 - 6.4 % Diabetic : >= 6.5 % %
PLBS (POST LUNCH BLOOD GLUCOSE)		
PLBS (POST LUNCH BLOOD GLUCOSE)	107	Normal : 70- 139 mg/dL Impaired : 140 - 199 mg/dL Diabetic : >= 200 mg/dL
T3,T4 AND TSH		
T3	1.41	0.8 - 2.0 ng/mL
T4	12.54	5.1 - 14.1 ug/dL
TSH(THYROID STIMULATING HORMONE)	* 4.40	0.270 - 4.20 uIU/mL
BUN(BLOOD UREA NITROGEN)	14.01	7.0 - 21.0 mg/dL
GAMMA GT		
GAMMA GLUTAMYL TRANSFERASE(GGT)	9.27	6 - 42 U/L
BUN(BLOOD UREA NITROGEN)	11.21	

*** End Of Report ***

Suggested Clinical Correlation * If necessary, Please discuss

Verified By : : 14561

Test results related only to the item tested.

No part of the report can be reproduced without written permission of the laboratory.

Med. Simi Iqbal

Dr. MOHAMMAD SIMI IQBAL M.B.B.S, M.D

Dr.MUDUGANTI SRINIVAS
MBBS, MD
CONSULTANT PATHOLOGIST

Dr.SRUJANA
MBBS, MD PATHOLOGY
CONSULTANT PATHOLOGIST

Dr.MOHAMMAD SIMI IQBAL
M.B.B.S, M.D
CONSULTANT BIOCHEMIST

Medicover Unit - I

18-1-3, KGH Down, Maharani-peta,
Jagadamba Junction, Visakapatnam,
Andhrapradesh - 530 002.
Ph: +91 96526 69351

Medicover Unit - III

Sry. No. 27, Plot No. 05, BRTS Road,
Health City, Arilova, Chinnagadalu Mandal,
Visakhapatnam, Andhrapradesh - 530 040.
Ph: +91 08916677888

Medicover - MVP

1-1-83, Sector -6, Venkojipalem,
MVP Colony, Visakapatnam,
Andhrapradesh-530017.
Ph: +91 8886655677



Lab Report

Patient Name	: Mrs. PONNADA SWARNALATHA	Age /Gender	: 32 Y(s)/Female
Bill No/ UMR No	: V4BC224201/V4U180796	Referred By	: Dr. CMO
Received Dt	: 13-Apr-24 08:45 am	Report Date	: 13-Apr-24 11:28 am
Lab No	: 240401943		

<u>Parameters</u>	<u>Result</u>	<u>Biological Reference Intervals</u>
-------------------	---------------	---------------------------------------

CUE(COMPLETE URINE EXAMINATION)

CHEMISTRY TEST

UROBILINOGEN	NIL	Negative
BILIRUBIN	Neqative	Negative
KETONE BODIES	Neqative	Negative
BLOOD	Neqative	Negative
PROTEIN	NIL	NIL
NITRITE	Neqative	Negative
LEUCOCYTES	Neqative	
GLUCOSE	NIL	NIL
SPECIFIC GRAVITY	1.010	1.005 - 1.030
PH	6.0	5.0 - 8.0

MICROSCOPY MORPHOLOGY

RBC	NIL	0 - 3 /HPF
WBC (WHITE BLOOD CELL)	2-4	0 - 5 /HPF
SQEP (SQUAMOUS EPITHELIAL CELL)	1-2	0 - 5 /HPF
UNCC (PATHOLOGICAL CAST)	NIL	0 - 0 /HPF
UNCX (UNCLASSIFIED CRYSTALS)	NIL	0 - 5 /HPF

*** End Of Report ***

Doctor Incharge

Dr.MUDUGANTI SRINIVAS
MBBS, MD
CONSULTANT PATHOLOGIST

Dr.SRUJANA
MBBS, MD PATHOLOGY
CONSULTANT PATHOLOGIST

Dr.MOHAMMAD SIMI IQBAL
M.B.B.S, M.D
CONSULTANT BIOCHEMIST



Medicover Hospitals

VENKOJIPALAM VISAKHAPATNAM - 530017
ANDHRA PRADESH - INDIA



MEDICOVER HOSPITALS

A UNIT OF SAHRUDAYA HEALTHCARE PVT LTD.

DEPARTMENT OF RADIOLOGY

Patient Name : Mrs. PONNADA SWARNALATHA	Age / Gender : 32 Y(s)/Female
Bill No/ UMR No : V4BC224201/V4U180796	Referred By : Dr. CMO
Received Dt : 13-Apr-24 08:35 am	Report Date : 13-Apr-24 11:41 am

USG ABDOMEN (FEMALE)

LIVER

Measuring 14.7 cm. Normal in size with normal homogeneous echotexture.
There is no evidence of IHBR/EHBR dilatation seen.
The portal and hepatic vessels are normal. No S.O.L. noted.

GALL BLADDER

Distended. Wall thickness is normal.
No evidence of intraluminal calculi/ masses seen.
Common bile duct appears normal with no intraluminal mass/ calculi.

PANCREAS

Head, Body & Tail are identified with normal echopattern & smooth outlines.
The pancreatic duct system appears normal.
The peri pancreatic fat planes are well preserved.

SPLEEN

Normal in size (8.6 cm) and homogenous echotexture.

RIGHT KIDNEY

Measuring 10.6 x 3.8 cm. Normal in size and echopattern.
Cortico-Medullary differentiation maintained.
No evidence of mass / calculi / hydroureteronephrosis seen.

LEFT KIDNEY

Measuring 10.4 x 4.4 cm. Normal in size and echopattern.
Cortico-Medullary differentiation maintained.
No evidence of mass / calculi / hydroureteronephrosis seen.
No evidence of suprarenal / retroperitoneal mass noted.

URINARY BLADDER

Distended. Wall thickness is normal.
No intraluminal mass / calculi noted.

UTERUS

Measuring 8.3 x 4.7 x 3.0 cm. Normal in size with normal myometrial echoanatomy. The Endometrium measuring 10 mm in thickness with regular outlines and homogenous echopattern.

RIGHT OVARY

Measuring 2.5 x 1.4 cm

Medicover Unit - I

18-1-3, KGH Down, Maharanipeta,
Jagadamba Junction, Visakapatnam,
Andhrapradesh - 530 002.
Ph: +91 96526 69351

Medicover Unit - III

Sry. No. 27, Plot No. 05, BRTS Road,
Health City, Arilova, Chinnagadalu Mandal,
Visakhapatnam, Andhrapradesh - 530 040.
Ph: +91 08916677888

Medicover - MVP

1-1-83, Sector -6, Venkojipalem,
MVP Colony, Visakapatnam,
Andhrapradesh-530017.
Ph: +91 8886655677



Medicover Hospitals

VENKOJIPALAM VISAKHAPATNAM - 530017
ANDHRA PRADESH - INDIA



MEDICOVER
HOSPITALS

A UNIT OF SAHRUDAYA HEALTHCARE PVT LTD.

DEPARTMENT OF RADIOLOGY

Patient Name : Mrs. PONNADA SWARNALATHA	Age / Gender : 32 Y(s)/Female
Bill No/ UMR No : V4BC224201/V4U180796	Referred By : Dr. CMO
Received Dt : 13-Apr-24 08:35 am	Report Date : 13-Apr-24 11:41 am

LEFT OVARY

Measuring 2.9 x 1.9 cm

Both ovaries are normal in size, echopattern.
No evidence of adnexal solid / cystic mass lesion seen.
No evidence of ascites/ pleural effusion seen.
No detectable bowel pathology seen.

IMPRESSION

* Normal study.

*** End Of Report ***

Dr. VULAPU CHENNAKRISHNA RAO, .
MBBS, DNB
CONSULTANT RADIOLOGIST

~~1. This report is not valid for medico-legal purpose.~~

2. In case of any discrepancy due to machine error or typing error, please get it rectified immediately.

Medicover Unit
18-1-3, KGH Down, Maharani-peta,
Jagadamba Junction, Visakapatnam,
Andhrapradesh - 530 002.
Ph: +91 96526 69351

Medicover Unit - II
Sry. No. 27, Plot No. 85, BRTS Road,
Health City, Arilova, Chinnagadalu Mandal,
Visakhapatnam, Andhrapradesh - 530 040.
Ph: +91 08916677888

Medicover - MVP
1-1-83, Sector -6, Venkojipalem,
MVP Colony, Visakapatnam,
Andhrapradesh-530017.
Ph: +91 8886655677

PATIENT ID : 180796
PATIENT NAME : MRS PONNADA SWARNALATHA 32/F

Summary Report

Report time
April 13, 2024 09:15 am
09:14 am

PROTOCOL : BRUCE
PATIENT HEIGHT : 148 Cm
PATIENT WEIGHT : 74.00 Kg
PATIENT ADD :
Ref By : Not Applicable
(Not Applicable)

OBJECT OF TEST : Routine check up
RISK FACTOR :
ACTIVITY :
MEDICATION :
BRIEF HISTORY :
OTHER INVESTIGATION :
REASON FOR TERMINATION : ACHIVED THR
EXERCISE TOLERANCE :
EXERCISE INDUCED ARRHYTHMIA :
HAEMO RESPONSE :
CHRONO RESPONSE :
FINAL IMPRESSION : EXCELLENT EXERCISE TOLERANCE
NO SIGNIFICANT ST/TCHANGES
NO ANGINA,ARRHYTHMIAS
NEGATIVE FOR RMI

DR ASHWIN KUMAR PANDA
DNB(NEW DELHI),DM(NIMS,HYD)



Medicover Hospitals

VENKOJIPALAM VISAKHAPATNAM - 530017
ANDHRA PRADESH - INDIA



MEDICOVER
HOSPITALS

A UNIT OF SAHRUDAYA HEALTHCARE PVT LTD.

DEPARTMENT OF RADIOLOGY

Patient Name : Mrs. PONNADA SWARNALATHA	Age /Gender : 32 Y(s)/Female
Bill No/ UMR No : V4BC224201/V4U180796	Referred By : Dr. CMO
Received Dt : 13-Apr-24 08:35 am	Report Date : 13-Apr-24 11:45 am

X-RAY CHEST PA VIEW

FINDINGS

The cardiac size & configuration appear normal.

The Aorta and pulmonary vasculature appear normal.

There is no evidence of mediastinal widening.

Both the lungs and CP angles are clear.

The soft tissues and the bones of the rib cage displayed no abnormality.

IMPRESSION

* Normal study.

- Kindly correlate clinically.

*** End Of Report ***

Dr. DEVARA ANIL K V, MD,DNB,DMRE
CONSULTANT INTERVENTIONAL
RADIOLOGIST

This report is not valid for medico-legal purpose.

Medicover Unit - I
1-1-83, KGH Down, Maharampeta,
Jagadamba Junction, Visakapatnam,
Andhrapradesh - 530 002.
Ph: +91 96526 69351

Medicover Unit - II

Sry. No. 27, Plot No. 05, BRTS Road,
Health City, Arilova, Chinnagadalu Mandal,
Visakhapatnam, Andhrapradesh - 530 040.
Ph: +91 08916677888

Medicover - MVP

1-1-83, Sector -6, Venkojipalem,
MVP Colony, Visakapatnam,
Andhrapradesh-530017.
Ph: +91 8886655677

P SWARNALATHA
female

13/04/2024 08:26:54

MEDCOVER HOSPITALS MVP VZAG

32 Years

WELLNESS

Rate 77 . SINUS RHYTHM.normal P axis, V-rate 50- 99

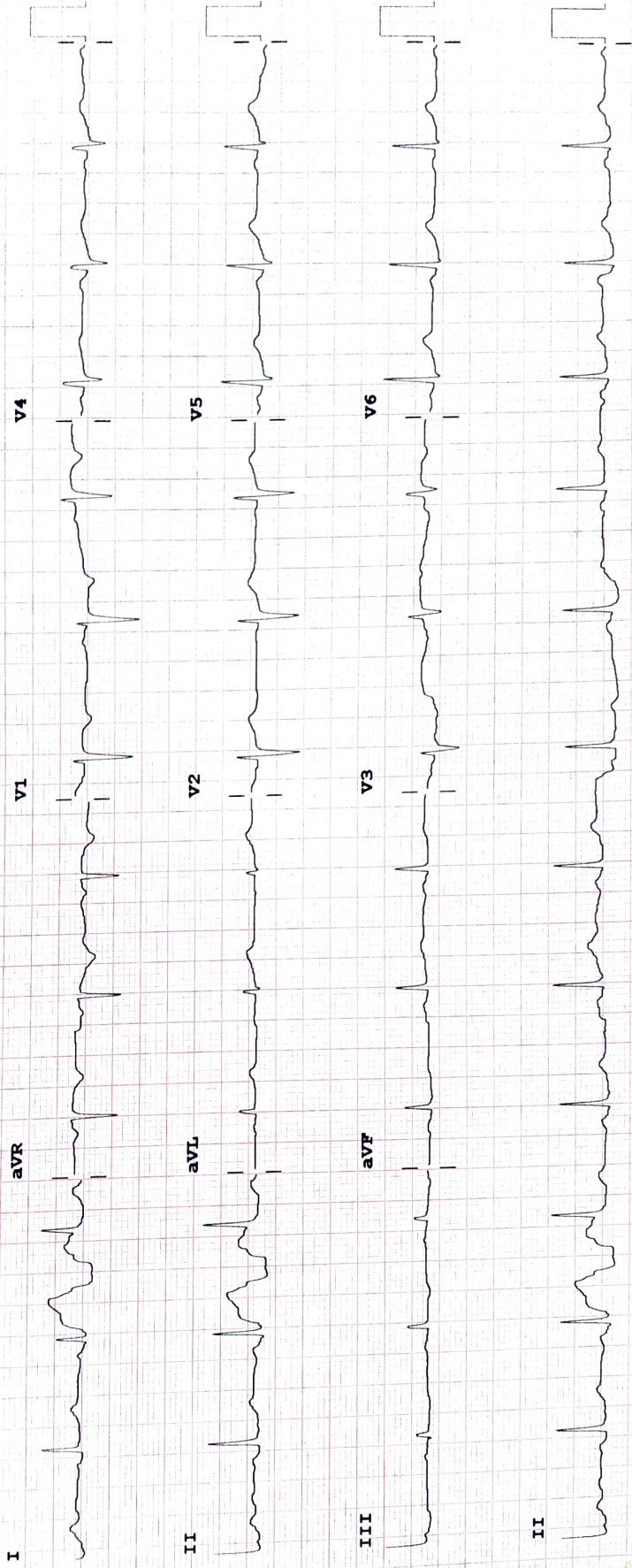
PR 144
QRSD 76
QT 364
QTc 412

--AXIS--
P 50
QRS 42
T 8

12 Lead; Standard Placement

- NORMAL ECG -

Unconfirmed Diagnosis



Device: Speed: 25 mm/sec Limb: 10 mm/mV Chest: 10.0 mm/mV

F 50~ 0.50- 40 Hz W

PH090A CL