

- COMPU. PATHOLOGY • ALLERGY TESTING
- DIGITAL WHOLE BODY X-RAYS
- DIGITAL 3D SONOGRAPHY
- DIGITAL WHOLE BODY COLOUR DOPPLER
- DIGITAL 2-D ECHO WITH COLOUR DOPPLER
- E.C.G. • LUNG FUNCTION TEST
- MAMMOGRAPHY & BONE MINERAL DENSITOMETRY

- COMPUTERISED STRESS TEST
- DENTAL
- ADVANCED DENTISTRY
- PHYSIOTHERAPY
- AUDIOMETRY & SPEECH THERAPY
- FULL BODY HEALTH CHECK-UPS
- CORPORATE HEALTH CHECKUPS



HEALTHCARE

MEDICAL CENTRE & DIAGNOSTICS

NAME	MR ROSHAN PATURDE	DATE	27/04/2024	
HEIGHT :	174 CM	WEIGHT: 73.7 KG	AGE	27 YRS
REFERRED BY	MEDIWHEEL	SEX	MALE	
PRESENT COMPLAINT : OCC BOTH HIP JOINT PAIN SINCE LAST MONTH				
PAST HISTORY : H/O APPENDECTOMY DONE AT THE AGE OF 15 YRS 10 DAYS HOSPI, H/O PERI ANAL ABSCESS SUEGERY DONE IN 2021 3 DAYS HOSPI, H/O ANAL FISTULA SURGERY DONE IN JULY 2023 4 DAYS HOSPI				
ALLERGY : NONE		HABIT: NONE		
BLADDER: NAD		BOWEL: NAD		
FAMILY HISTORY: FATHER :HEALTHY MOTHER : HEALTHY				
GYNEAC HISTORY: NA				
GENERAL EXAMINATION:ADVICE-				
P : 76/ MIN		BP: 120/80 MMHG		
PALLOR: NIL		ICTERUS: NIL		
OEDEMA: NIL		CNS- CONSCIOUS		
RS: AEBE		CVS- NAD		
PA: SOFT				
INVESTIGATION:				

*fit for employment
reduce sugar intake
& oily & fatty food.
fit orthopaedic*

DR. YOGESH J. MEHTA M.B.B.S.
DR. PRADEEP MEHTA (M.D.)
Rajgurunagar

HEALTHCARE MEDICAL CENTRE AND DIAGNOSTICS
UNIT NO 13 RNA LIBERTY CHS,
VIJAY PARK, NEAR JANGID CIRCLE,
MIRA ROAD EAST THANE 401107
MOBILE: 7021804221

- COMPU. PATHOLOGY • ALLERGY TESTING
- DIGITAL WHOLE BODY X-RAYS
- DIGITAL 3D SONOGRAPHY
- DIGITAL WHOLE BODY COLOUR DOPPLER
- DIGITAL 2-D ECHO WITH COLOUR DOPPLER
- E.C.G. • LUNG FUNCTION TEST
- MAMMOGRAPHY & BONE MINERAL DENSITOMETRY

- COMPUTERISED STRESS TEST
- DENTAL
- ADVANCED DENTISTRY
- PHYSIOTHERAPY
- AUDIOMETRY & SPEECH THERAPY
- FULL BODY HEALTH CHECK-UPS
- CORPORATE HEALTH CHECKUPS



HEALTHCARE

MEDICAL CENTRE & DIAGNOSTICS

Patient's Name : MRS RENU ROSHAN PATURDE

Referred By Dr : MEDIWHEEL

Sex : FEMALE Age : 31 Years

Collected At : MIRA ROAD MAIN BRANCH

Lab No. : LDB4124*LDB4124*

Reg. Date : 27-Apr-2024 8:51 am

Report Date: 27-Apr-2024 4:34 pm

Print Date : 28-Apr-2024 8:58 am

COMPLETE BLOOD COUNT

TEST	RESULT	UNITS	NORMAL VALUES
Haemoglobin	13.2	gm %	Female : 11.5 - 14.5 gm%
Erythrocytes (Total RBCs)	4.38	mill. / cmm	Female : 3.8 - 5.2 mill. / cmm
PCV	41	%	Female : 32 - 47 %
MCV	93.70	fl	80- 96 fl
MCH	30.10	pg	27 - 32 pg
MCHC	32.10	gm%	32 - 37 gm%
RDW	13.7	%	12 - 14.5
TOTAL WBC COUNT			
TOTAL WBC COUNT	6350	/ cumm	4,000 - 11,000
DIFFERENTIAL COUNT			
Neutrophils	65	%	40 - 75
Lymphocytes	30	%	20 - 40
Eosinophils	03	%	0 - 6
Monocytes	02	%	2 - 8
Platelet count	409000	Lacs/cmm	150000-450000
PERIPHERAL SMEAR			
RBC Morphology	Normocytic Normochromic		
WBC Morphology	Normal		
Platelets Morphology	Adequate		
ESR (westergren's method)	10	mm/hr	Male: 0 - 10 mm Female: 0 - 20 mm

----- End of Report -----

Bk

- COMPU. PATHOLOGY • ALLERGY TESTING
- DIGITAL WHOLE BODY X-RAYS
- DIGITAL 3D SONOGRAPHY
- DIGITAL WHOLE BODY COLOUR DOPPLER
- DIGITAL 2-D ECHO WITH COLOUR DOPPLER
- E.C.G. • LUNG FUNCTION TEST
- MAMMOGRAPHY & BONE MINERAL DENSITOMETRY

- COMPUTERISED STRESS TEST
- DENTAL
- ADVANCED DENTISTRY
- PHYSIOTHERAPY
- AUDIOMETRY & SPEECH THERAPY
- FULL BODY HEALTH CHECK-UPS
- CORPORATE HEALTH CHECKUPS



Patient's Name : MRS RENU ROSHAN PATURDE

Lab No. : LDB4124*LDB4124*

Referred By Dr : MEDIWHEEL

Reg. Date : 27-Apr-2024 8:51 am

Sex : FEMALE Age : 31 Years

Report Date: 27-Apr-2024 8:40 pm

Collected At : MIRA ROAD MAIN BRANCH

Print Date : 28-Apr-2024 8:58 am

TEST

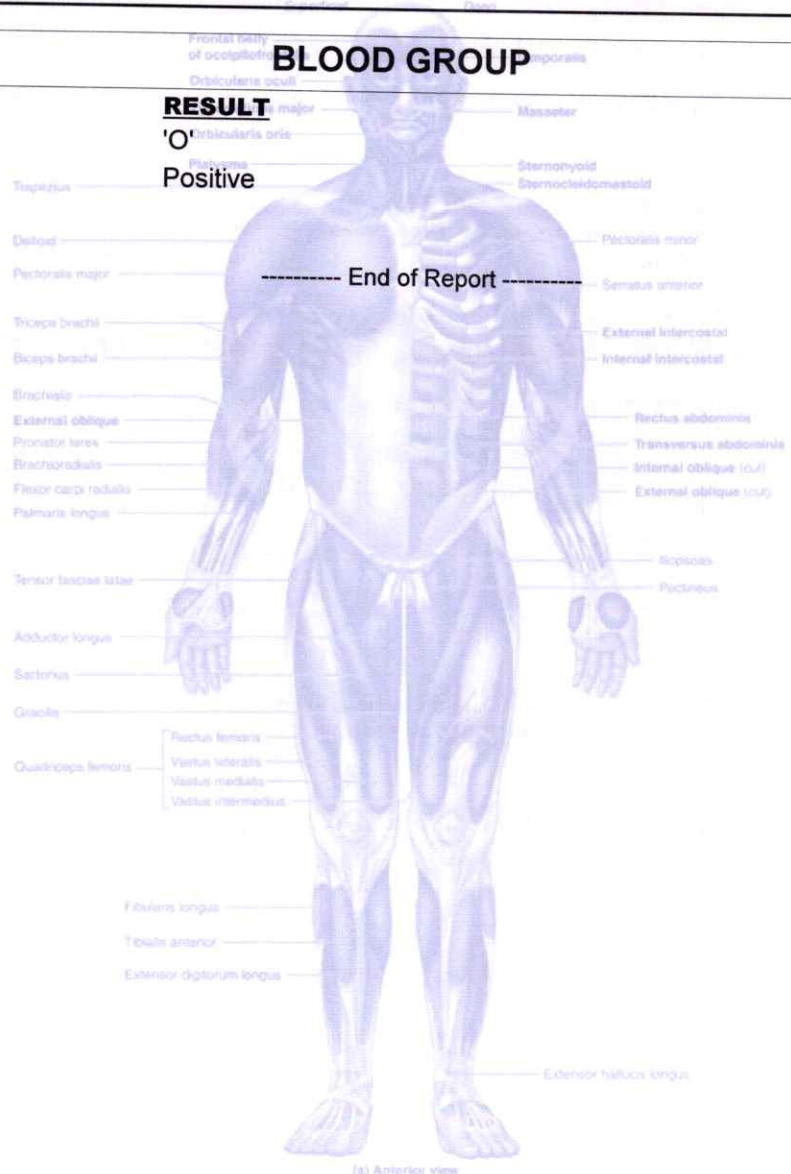
Blood Group
Rh Factor

RESULT

'O'
Positive

BLOOD GROUP

----- End of Report -----



Bk

- COMPU. PATHOLOGY • ALLERGY TESTING
- DIGITAL WHOLE BODY X-RAYS
- DIGITAL 3D SONOGRAPHY
- DIGITAL WHOLE BODY COLOUR DOPPLER
- DIGITAL 2-D ECHO WITH COLOUR DOPPLER
- E.C.G. • LUNG FUNCTION TEST
- MAMMOGRAPHY & BONE MINERAL DENSITOMETRY

- COMPUTERISED STRESS TEST
- DENTAL
- ADVANCED DENTISTRY
- PHYSIOTHERAPY
- AUDIOMETRY & SPEECH THERAPY
- FULL BODY HEALTH CHECK-UPS
- CORPORATE HEALTH CHECKUPS



Patient's Name : MRS RENU ROSHAN PATURDE

Lab No. : LDB4124*LDB4124*

Referred By Dr : MEDIWHEEL

Reg. Date : 27-Apr-2024 8:51 am

Sex : FEMALE Age : 31 Years

Report Date: 27-Apr-2024 4:34 pm

Collected At : MIRA ROAD MAIN BRANCH

Print Date : 28-Apr-2024 8:58 am

BLOOD SUGAR REPORT

TEST

BLOOD SUGAR FASTING

RESULT

93.1

UNITS

mg/dL

NORMAL VALUES

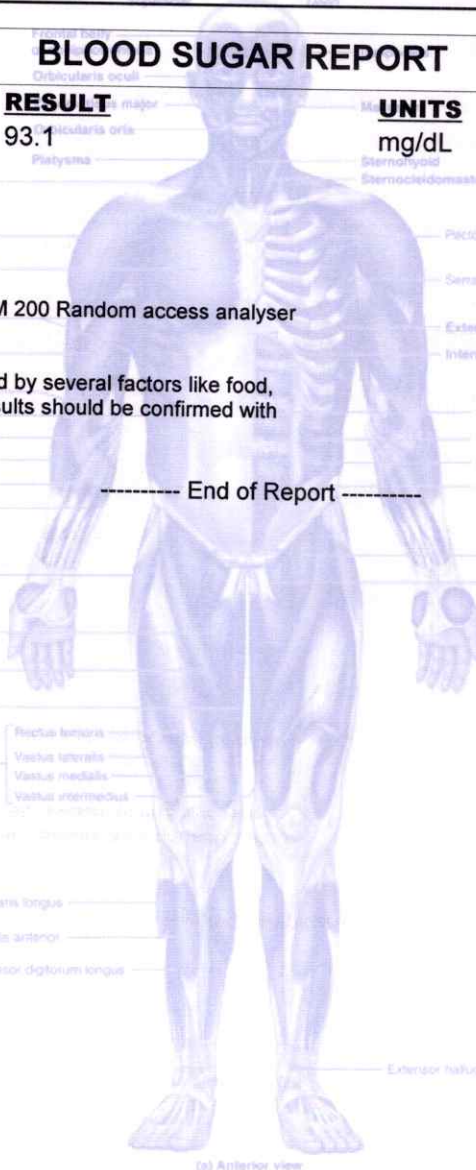
Normal: 70-110 mg/dL
Impaired Fasting Glucose(IFG): 110 -125
Diabetes mellitus: >= 126
(on more than one occasion)

Method: GOD - POD Enzymatic on Erba EM 200 Random access analyser

Comment:

Blood sugar values are known to be affected by several factors like food, stress and medication. So all discrepant results should be confirmed with repeat sample collection.

----- End of Report -----



(a) Anterior view

Bk

- COMPU. PATHOLOGY • ALLERGY TESTING
- DIGITAL WHOLE BODY X-RAYS
- DIGITAL 3D SONOGRAPHY
- DIGITAL WHOLE BODY COLOUR DOPPLER
- DIGITAL 2-D ECHO WITH COLOUR DOPPLER
- E.C.G. • LUNG FUNCTION TEST
- MAMMOGRAPHY & BONE MINERAL DENSITOMETRY

- COMPUTERISED STRESS TEST
- DENTAL
- ADVANCED DENTISTRY
- PHYSIOTHERAPY
- AUDIOMETRY & SPEECH THERAPY
- FULL BODY HEALTH CHECK-UPS
- CORPORATE HEALTH CHECKUPS



Patient's Name : MRS RENU ROSHAN PATURDE

Referred By Dr : MEDIWHEEL

Sex : FEMALE Age : 31 Years

Collected At : MIRA ROAD MAIN BRANCH

Lab No. : LDB4124*LDB4124*

Reg. Date : 27-Apr-2024 8:51 am

Report Date: 27-Apr-2024 4:34 pm

Print Date : 28-Apr-2024 8:58 am

BIOCHEMISTRY

TEST	RESULT	NORMAL VALUES
Blood Urea Nitrogen (BUN)	13.00	5 - 20 mg/dl
CREATININE	0.63	0.5 - 1.3 mg/dl
Serum Uric Acid	4.60	Female : 2.6 - 6.0 mg%
Age of the Patient	31	
eGFR	117.15	ml/min

eGFR calculation based on MDRD guideline 2012
 More than 90 ml / min / 1.73 Sqm - Normal eGFR
 60-89 ml / min / 1.73 Sqm - Mild decrease in eGFR is common in 30% healthy adults .
 Suggest reapt testing in 6 to 12 months.
 Exclude kidney disease in those at high risk (Diabetes & Hypertension
 30-59 ml / min / 1.73 Sqm - consistent with modrate chronic kidney disease if confirmed over
 three month .
 Consider nephrology referral if progressive deterioration of more than 20 % for Egfr or creatinine.
 15 - 29 ml / min / 1.73 Sqm - Consistent with severe chronic kidney disease . Consider nephrology
 referral

----- End of Report -----

Bk

- COMPU. PATHOLOGY • ALLERGY TESTING
- DIGITAL WHOLE BODY X-RAYS
- DIGITAL 3D SONOGRAPHY
- DIGITAL WHOLE BODY COLOUR DOPPLER
- DIGITAL 2-D ECHO WITH COLOUR DOPPLER
- E.C.G. • LUNG FUNCTION TEST
- MAMMOGRAPHY & BONE MINERAL DENSITOMETRY

- COMPUTERISED STRESS TEST
- DENTAL
- ADVANCED DENTISTRY
- PHYSIOTHERAPY
- AUDIOMETRY & SPEECH THERAPY
- FULL BODY HEALTH CHECK-UPS
- CORPORATE HEALTH CHECKUPS



HEALTHCARE

MEDICAL CENTRE & DIAGNOSTICS

Patient's Name : MRS RENU ROSHAN PATURDE

Lab No. : LDB4124*LDB4124*

Referred By Dr : MEDIWHEEL

Reg. Date : 27-Apr-2024 8:51 am

Sex : FEMALE Age : 31 Years

Report Date: 27-Apr-2024 7:57 pm

Collected At : MIRA ROAD MAIN BRANCH

Print Date : 28-Apr-2024 8:58 am

GLYCOSYLATED HAEMOGLOBIN (HbA1c)

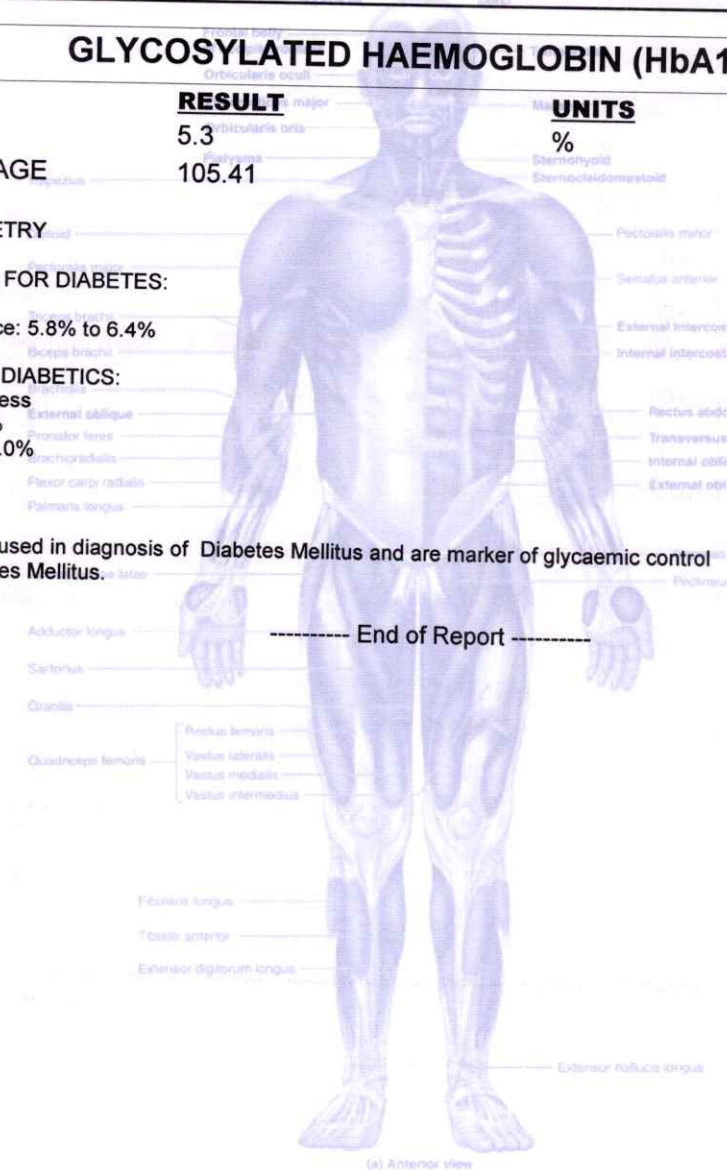
TEST	RESULT	UNITS	NORMAL VALUES
HBA1C	5.3	%	4 - 5.7 %
ESTIMATED AVERAGE GLUCOSE	105.41		
METHOD : NEPHELOMETRY			

DIAGNOSTIC CRITERIA FOR DIABETES:

- Normal: Less than 5.7%
 - Impaired glucose tolerance: 5.8% to 6.4%
 - Diabetes: 6.5% or more
- CONTROL CRITERIA IN DIABETICS:**
- Optimal control: 7.0% or less
 - Fair control: 7.0% to 8.0%
 - Poor control: More than 8.0%

Comment :

HbA1c values should not used in diagnosis of Diabetes Mellitus and are marker of glycaemic control in known cases of Diabetes Mellitus.



* RECHECKED & CONFIRMED

Bk

- COMPU. PATHOLOGY • ALLERGY TESTING
- DIGITAL WHOLE BODY X-RAYS
- DIGITAL 3D SONOGRAPHY
- DIGITAL WHOLE BODY COLOUR DOPPLER
- DIGITAL 2-D ECHO WITH COLOUR DOPPLER
- E.C.G. • LUNG FUNCTION TEST
- MAMMOGRAPHY & BONE MINERAL DENSITOMETRY

- COMPUTERISED STRESS TEST
- DENTAL
- ADVANCED DENTISTRY
- PHYSIOTHERAPY
- AUDIOMETRY & SPEECH THERAPY
- FULL BODY HEALTH CHECK-UPS
- CORPORATE HEALTH CHECKUPS



Patient's Name : MRS RENU ROSHAN PATURDE

Lab No. : LDB4124*LDB4124*

Referred By Dr : MEDIWHEEL

Reg. Date : 27-Apr-2024 8:51 am

Sex : FEMALE Age : 31 Years

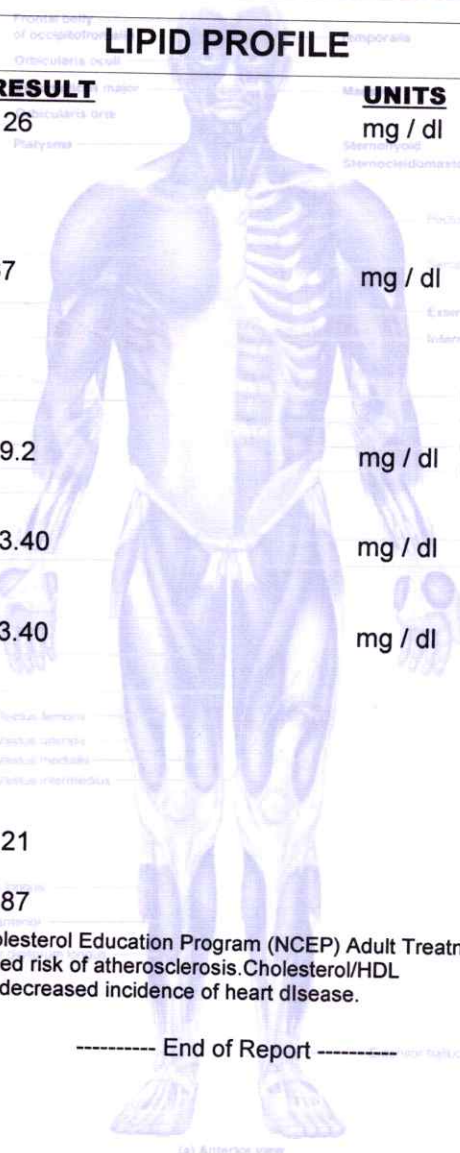
Report Date: 27-Apr-2024 4:33 pm

Collected At : MIRA ROAD MAIN BRANCH

Print Date : 28-Apr-2024 8:58 am

LIPID PROFILE

TEST	RESULT	UNITS	NORMAL VALUES
SR. CHOLESTEROL	126	mg / dl	Desirable: < 200 mg/dl Borderline High: 200-239 mg/dl High: >= 240 mg/dl
SR. TRIGLYCERIDES	67	mg / dl	Normal: < 150 mg/dl Borderline High: 150-199 mg/dl High: 200-499 mg/dl Very High: >= 500 mg/dl
HDL CHOLESTEROL	39.2	mg / dl	35.3 - 79.5 mg / dl
VDL	13.40	mg / dl	6 - 38 mg / dl
LDL CHOLESTEROL	73.40	mg / dl	Optimal: < 100 mg/dl Near Optimal: 100-129 mg/dl Borderline high: 130-159 mg/dl High: 160-189 mg/dl Very High: >= 190 mg/dl
CHOLESTEROL / HDL	3.21		< 5
LDL / HDL	1.87		< 3.5



----- End of Report -----

Bk

- COMPU. PATHOLOGY • ALLERGY TESTING
- DIGITAL WHOLE BODY X-RAYS
- DIGITAL 3D SONOGRAPHY
- DIGITAL WHOLE BODY COLOUR DOPPLER
- DIGITAL 2-D ECHO WITH COLOUR DOPPLER
- E.C.G. • LUNG FUNCTION TEST
- MAMMOGRAPHY & BONE MINERAL DENSITOMETRY

- COMPUTERISED STRESS TEST
- DENTAL
- ADVANCED DENTISTRY
- PHYSIOTHERAPY
- AUDIOMETRY & SPEECH THERAPY
- FULL BODY HEALTH CHECK-UPS
- CORPORATE HEALTH CHECKUPS



HEALTHCARE

MEDICAL CENTRE & DIAGNOSTICS

Patient's Name : MRS RENU ROSHAN PATURDE

Referred By Dr : MEDIWHEEL

Sex : FEMALE Age : 31 Years

Collected At : MIRA ROAD MAIN BRANCH

Lab No. : LDB4124*LDB4124*

Reg. Date : 27-Apr-2024 8:51 am

Report Date: 27-Apr-2024 7:57 pm

Print Date : 28-Apr-2024 8:58 am

T3 T4 TSH

TEST

RESULT

UNITS

NORMAL VALUES

T3 [Tri - iodothyronine]

139.524

ng/dl

91.14 - 237.61 ng/dl

HYPOTHYROID : Less than 35 ng/dl

HYPERTHYROID : Above 193 ng/dl

T4 [Thyroxine]

8.155

ug/dl

4.71 - 13.20 ug/dl

ug/dl

HYPOTHYROID : Less than 4.87 ug/dl

HYPERTHYROID : Above 11.72 ug/dl

TSH [Thyroid Stimulating Hormone]

1.879

uIU/mL

0.3 - 4.3 uIU/ml

Hypothyroid > 15.0

Hyperthyroid : < 0.35

First Trimester : 0.1 - 2.5

Second Trimester : 0.2 - 3.0

Third Trimester : 0.3 - 3.0

METHOD: CLIA

Interpretation :

1. TSH results between 4.5 to 15 show considerable physiologic & seasonal variation, suggest clinical correlation or repeat testing with fresh sample.
2. TSH values may be transiently altered because of non thyroidal illness like severe infections, liver disease, renal and heart failure , severe burns , trauma and surgery etc.
3. Drugs that decrease TSH values e.g:L dropa, Glucocorticoid Drugs that increase TSH values e.g Iodine,Lithium,Amiodarone.
- 4.Total T3 & T4 Values may also be altered in other conditions due to changes in serum proteins or binding sites Pregnancy. Drugs (Androgens,Estrogens. O C Pills,Phenytoin). Nephrosis etc. In such cases Free T3 and Free T4 give corrected values.

----- End of Report -----

(a) Anterior view

Bl

- COMPU. PATHOLOGY • ALLERGY TESTING
- DIGITAL WHOLE BODY X-RAYS
- DIGITAL 3D SONOGRAPHY
- DIGITAL WHOLE BODY COLOUR DOPPLER
- DIGITAL 2-D ECHO WITH COLOUR DOPPLER
- E.C.G. • LUNG FUNCTION TEST
- MAMMOGRAPHY & BONE MINERAL DENSITOMETRY

- COMPUTERISED STRESS TEST
- DENTAL
- ADVANCED DENTISTRY
- PHYSIOTHERAPY
- AUDIOMETRY & SPEECH THERAPY
- FULL BODY HEALTH CHECK-UPS
- CORPORATE HEALTH CHECKUPS



Patient's Name : MRS RENU ROSHAN PATURDE

Lab No. : LDB4124*LDB4124*

Referred By Dr : MEDIWHEEL

Reg. Date : 27-Apr-2024 8:51 am

Sex : FEMALE Age : 31 Years

Report Date: 27-Apr-2024 2:50 pm

Collected At : MIRA ROAD MAIN BRANCH

Print Date : 28-Apr-2024 8:58 am

URINE ROUTINE & MICROSCOPY

TEST

RESULT

PHYSICAL EXAMINATION

Quantity 15 ml
 Colour Pale yellow
 Appearance clear
 Deposit Absent
 pH Acidic (5.0)
 Specific Gravity 1.010

CHEMICAL EXAMINATION

Proteins Absent
 Sugar Absent
 Ketone Absent
 Occult Blood Absent
 Bile Pigment Absent
 Bile Salts Absent
 Urobilinogen Normal

MICROSCOPIC EXAMINATION OF CENTRIFUGED DEPOSIT

Red Blood Cells Absent
 Pus Cells Occasional /hpf
 Epithelial Cells Occasional /hpf
 Casts Not seen
 Crystals Not seen /hpf
 Yeast Not seen
 Bacteria Absent

----- End of Report -----

(a) Anterior view

Health Check up Booking Request(22S29144)

Mediwheel <wellness@mediwheel.in>
To: healthcare.medicals@gmail.com
Cc: customercare@mediwheel.in

Fri, Apr 26, 2024 at 5:44 PM



Mediwheel
...Your wellness partner

011-41195959

Dear Healthcare Medical Centre and Diagnostic

We have received a booking request with the following details. Provide your confirmation by clicking on the Yes button.

You confirm this booking? Yes No

Name : MR. PATURDE ROSHAN GAJANAN

Contact Details : 8600890352

Hospital Package Name : Mediwheel Full Body Health Checkup Female Below 40

Location : UNIT NO 13,RNA LIBERTY BLDG,VIJAY PARK ROAD,NEAR JANGID CIRCLE,MIRA ROAD EAST, THANE 401107

Appointment Date : 27-04-2024

Member Information		
Booked Member Name	Age	Gender
RENU ROSHAN PATURDE	31 year	Female

Tests included in this Package -

- Pap Smear
- Stool Test
- Gynae Consultation
- Thyroid Profile
- ESR
- Blood Glucose (Fasting)
- General Physician Consultation
- TMT OR 2D ECHO
- Blood Group
- Blood Glucose (Post Prandial)
- Chest X-ray
- ECG
- USG Whole Abdomen
- Eye Check-up consultation
- Urine Sugar Fasting
- Urine Sugar PP
- Dental Consultation
- Urine analysis
- CBC
- HbA1c

- Lipid Profile
- Kidney Profile
- Liver profile

Thanks,
Mediwheel Team

Please Download Mediwheel App



You have received this mail because your e-mail ID is registered with **Arcofemi Healthcare Limited** This is a system-generated e-mail please don't reply to this message.

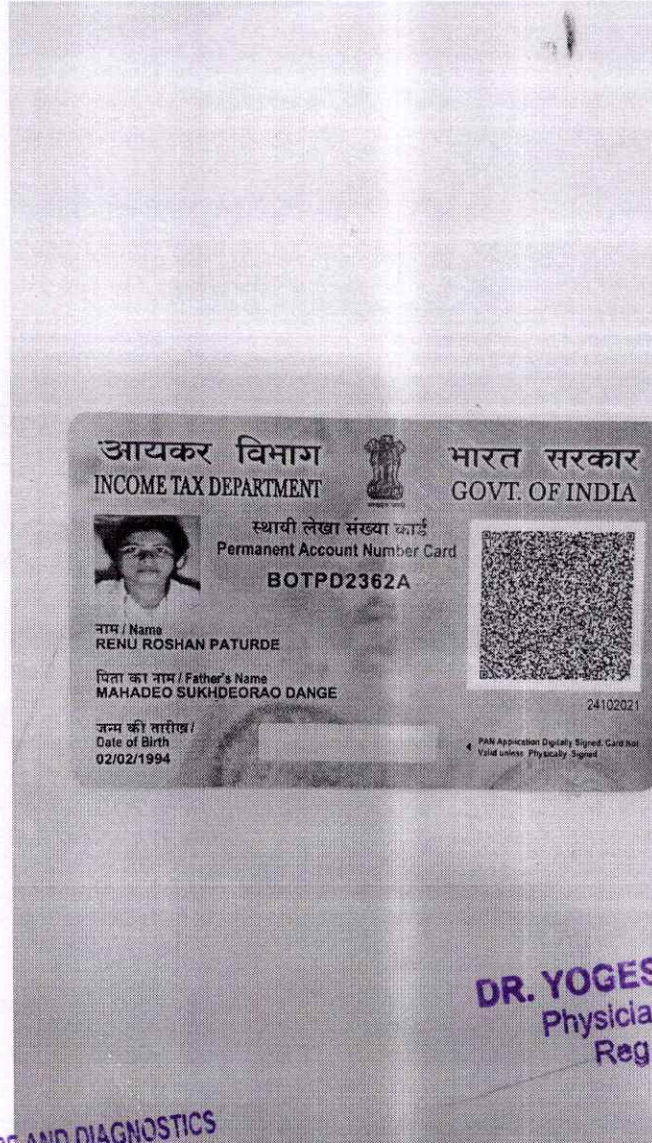Please visit to our [Terms & Conditions](#) for more informaion. [Click here to unsubscribe.](#)

@ 2024 - 25, Arcofemi Healthcare Pvt Limited.(Mediwheel)

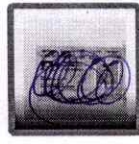


Asmin

Today at 8:49 am



Mohanisjal



- COMPUT. PATHOLOGY • ALLERGY TESTING
- DIGITAL WHOLE BODY X-RAYS
- DIGITAL 3D SONOGRAPHY
- DIGITAL WHOLE BODY COLOUR DOPPLER
- DIGITAL 2-D ECHO WITH COLOUR DOPPLER
- E.C.G. • LUNG FUNCTION TEST
- MAMMOGRAPHY & BONE MINERAL DENSITOMETRY

- COMPUTERISED STRESS TEST
- DENTAL
- ADVANCED DENTISTRY
- PHYSIOTHERAPY
- AUDIOMETRY & SPEECH THERAPY
- FULL BODY HEALTH CHECK-UPS
- CORPORATE HEALTH CHECKUPS



HEALTHCARE

MEDICAL CENTRE & DIAGNOSTICS

NAME	MRS RENU PATURDE	DATE	27/04/2024	
HEIGHT :	153 CM	WEIGHT: 65 KG	AGE	31 YRS
REFERRED BY	MEDIWHEEL	SEX	FEMALE	
PRESENT COMPLAINT : NIL				
PAST HISTORY : NIL				
ALLERGY : NONE		HABIT:NONE		
APPETITE:GOOD				
BLADDER: NAD		BOWEL: NAD		
FAMILY HISTORY: FATHER :HTN SINCE 10 YRS				
MOTHER : HEALTHY				
GYNEAC HISTORY: LMP: 25/04/2024 REGULAR				
GENERAL EXAMINATION:ADVICE-				
P : 84/ MIN		BP: 110/70 MMHG		
<i>ht for employment</i>				
PALLOR: NIL		ICTERUS: NIL		
OEDEMA: NIL CNS- CONSCIOUS				
RS:AEBE CVS-NAD				
PA: SOFT				
INVESTIGATION:				

DR. YOGESH J. MEHTA M.D.
 Physician & Cardiologist
 Reg. No. - 71131

HEALTHCARE MEDICAL CENTRE AND DIAGNOSTICS
 UNIT NO 13 RNA LIBERTY CHS,
 VIJAY PARK, NEAR JANGID CIRCLE,
 MIRA ROAD EAST THANE 401107
 MOBILE: 7021804221

- COMPUTE-PATHOLOGY • ALLERGY TESTING
- DIGITAL WHOLE BODY X-RAYS
- DIGITAL 3D SONOGRAPHY
- DIGITAL WHOLE BODY COLOUR DOPPLER
- DIGITAL 2-D ECHO WITH COLOUR DOPPLER
- E.C.G. • LUNG FUNCTION TEST
- MAMMOGRAPHY & BONE MINERAL DENSITOMETRY

- COMPUTERISED STRESS TEST
- DENTAL
- ADVANCED DENTISTRY
- PHYSIOTHERAPY
- AUDIOMETRY & SPEECH THERAPY
- FULL BODY HEALTH CHECK-UPS
- CORPORATE HEALTH CHECKUPS



HEALTHCARE

MEDICAL CENTRE & DIAGNOSTICS

EYE CHECK UP & COLOUR VISION

Copyright © The McGraw-Hill Companies, Inc. Permission required for reproduction or display.

NAME: MRS RENU PATURDE		DATE :27/04/2024
REF. BY: MEDIWHEEL	AGE- 31 YRS	SEX : FEMALE

	RIGHT EYE	LEFT EYE
CORNEA	NORMAL	NORMAL
PUPIL	NORMAL	NORMAL
SCLERA	NORMAL	NORMAL
EYE MOVEMENTS	NORMAL	NORMAL
REFRACTIVE ERROR	-0.25	-0.25
COLOUR VISION	NORMAL	NORMAL

HEALTHCARE MEDICAL CENTRE AND DIAGNOSTICS
 UNIT NO 13 RNA LIBERTY CHS,
 XIJAY PARK, NEAR JANGID CIRCLE,
 MIRA ROAD EAST THANE 401107
 MOBILE: 7021804221

DR. SIGNATURE

- COMPU. PATHOLOGY • ALLERGY TESTING
- DIGITAL WHOLE BODY X-RAYS
- DIGITAL 3D SONOGRAPHY
- DIGITAL WHOLE BODY COLOUR DOPPLER
- DIGITAL 2-D ECHO WITH COLOUR DOPPLER
- E.C.G. • LUNG FUNCTION TEST
- MAMMOGRAPHY & BONE MINERAL DENSITOMETRY

- COMPUTERISED STRESS TEST
- DENTAL
- ADVANCED DENTISTRY
- PHYSIOTHERAPY
- AUDIOMETRY & SPEECH THERAPY
- FULL BODY HEALTH CHECK-UPS
- CORPORATE HEALTH CHECKUPS



HEALTHCARE

MEDICAL CENTRE & DIAGNOSTICS

NAME	MRS RENU ROSHAN PATURDE	DATE	27.04.2024
		AGE	31YRS
REF. BY	MEDIWHEEL	SEX	FEMALE

X-RAY CHEST (P. A. VIEW)

The lungs on the both side show equal translucency.

The heart and trachea are central in Position.

No mediastinal abnormality is visible.

The peripheral pulmonary vasculature is normal.

No focal lung lesion is seen.

The pleural spaces are normal.

Both hila are normal in size, have equal density and bear normal relationship.

The cardiac size is normal.

The domes of the diaphragms are normal in position, and show smooth outline.

Ribs appear normal.

IMPRESSION: NO EVIDENCE OF PULMONARY, PLEURAL OR CARDIAC PATHOLOGY IS NOTED.

DR. SACHIN JADKAR
M.B.,D.M.R.E.
(CONS. RADIOLOGIST)

- COMPU. PATHOLOGY • ALLERGY TESTING
- DIGITAL WHOLE BODY X-RAYS
- DIGITAL 3D SONOGRAPHY
- DIGITAL WHOLE BODY COLOUR DOPPLER
- DIGITAL 2-D ECHO WITH COLOUR DOPPLER
- E.C.G. • LUNG FUNCTION TEST
- MAMMOGRAPHY & BONE MINERAL DENSITOMETRY

- COMPUTERISED STRESS TEST
- DENTAL
- ADVANCED DENTISTRY
- PHYSIOTHERAPY
- AUDIOMETRY & SPEECH THERAPY
- FULL BODY HEALTH CHECK-UPS
- CORPORATE HEALTH CHECKUPS



Pat.Name	MRS RENU ROSHAN PATURDE	Age:	31Y/FEMALE
Ref. Dr.	MEDIWHEEL	Date:	26/04/2024

ULTRASONOGRAPHY REPORT OF ABDOMEN & PELVIS

Copyright © The McGraw-Hill Companies, Inc. Permission required for reproduction or display

Liver: Liver is normal in size and shape. Parenchyma is homogenous echogenicity. No evidence of solid or cystic mass is noted. Intra & extra hepatic biliary radicals appear normal. Hepatic veins appear normal. PV & CBD are normal in caliber at porta hepatis.

Gall Bladder: gallbladder is physiologically distended and wall in normal in thickness. No intra luminal calculus or mass is seen.

Pancreas: is partially visualized. No obvious mass / collection is seen in region of pancreatic duct appears normal.

Spleen: is normal in size, shape, outlined and position. Parenchyma is homogenous in echo texture. No mass or calcification or collection is seen. Spleen is 9.0cm in length.

Kidneys: Both kidneys are normal in size, shape, outline & Position. Normal cortical echo texture & cortico-medullary differentiation is seen. Pelvic-calicle system appears normal. No obvious mass or Collection is seen. No Calculus is seen.

Right kidney measures 10.4X3.8cms.

Left kidney measures 9.4X4.5cms.

Bladder: UB is distended well smooth in outline & normal wall thickness. No obvious mass or diverticulum or intra luminal calculus is seen. No significant post-void residual urine is seen.

Uterus: Uterus is anteverted. It is normal in size. Shape, outline and position. The uterine myometrium appears normal in echo texture. No mass or collection or calcification is seen in uterine myometrium. Endometrium is central and appears normal. Endometrial thickness is 6.7mms.

Uterus measures 7.7X4.1X3.8cms.

Ovaries: Both ovaries appear normal in size, shape and position. No obvious ovarian / adnexal mass or collection is seen on either side.

Right ovary measures 2.5X1.6cms.

Left ovary measures 2.4X1.6cms.

- COMPU. PATHOLOGY • ALLERGY TESTING
- DIGITAL WHOLE BODY X-RAYS
- DIGITAL 3D SONOGRAPHY
- DIGITAL WHOLE BODY COLOUR DOPPLER
- DIGITAL 2-D ECHO WITH COLOUR DOPPLER
- E.C.G. • LUNG FUNCTION TEST
- MAMMOGRAPHY & BONE MINERAL DENSITOMETRY

- COMPUTERISED STRESS TEST
- DENTAL
- ADVANCED DENTISTRY
- PHYSIOTHERAPY
- AUDIOMETRY & SPEECH THERAPY
- FULL BODY HEALTH CHECK-UPS
- CORPORATE HEALTH CHECKUPS



BOTH ILIAC FOSSAS: No obvious mass or collection is seen on either side. Lot of gas artifact shadow is seen on both sides and abdomen.

No free fluid is seen in abdomen and pelvis.

IMPRESSION:

- NORMAL ABDOMINAL AND PELVIS USG.
- LOT OF GAS ARTIFACTSHADOW SEEN IN ABDOMEN AND PELVIS.

SUGGESTED: Clinico-Pathological correlation & further evaluation.

Thanks for referral.

Reliability of sonographic evaluation reports is not 100%, and is subject to variation. Reports are for interpretation by doctors only, with due clinical correlation.

DR. R. K. SINGH,
MB BS,DMRE(Sonologist)

- COMPU. PATHOLOGY
- ECG ■ PFT
- DIGITAL X-RAY
- COMPU. TREADMILL TEST
- DIGITAL SONOGRAPHY
- PHYSIOTHERAPY
- DIGITAL COLOR DOPPLER
- DENTAL
- 2D ECHO CARDIOGRAPHY
- HEALTH CHECK-UP
- MAMMOGRAPHY & BONE MINERAL DENSITOMETRY (BMD)




HEALTHCARE
 MEDICAL CENTRE & DIAGNOSTICS

MRS RENU KOSHAN
 ELDB4124 27-Apr-2024

 ECG

LECTROCARDIOGRAM (ECG)

PATIENT Mrs Renu R. Patil AGE. 31 SEX F

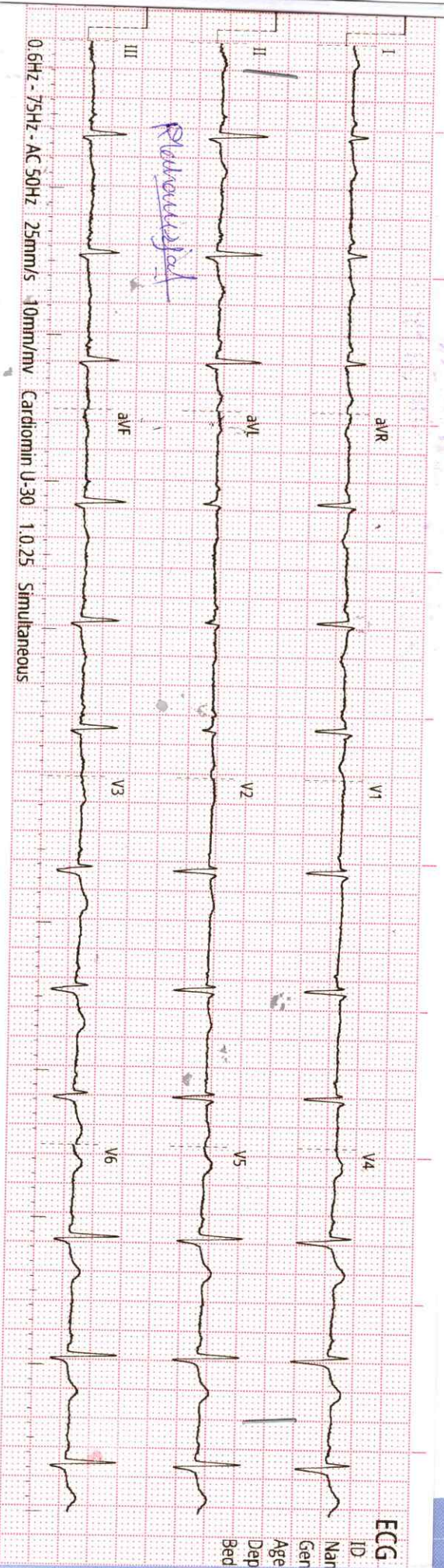
REF. BY DR. Mediwheel DATE 27-04-24

INTERPRETATION : Normal

Dr. 
DR. YOGESH J. KESHTA M.D.
 Physician & Cardiologist
 Reg. No. - 71131



ARE MEDICAL CENTRE AND DIAGNOSTICS
 T NO 13 RIVA LIBERTY CHS
 PARK, NEAR JANGID CIRCLE,
 ROAD EAST THANE 401107
 MOBILE: 7021804221





0.6Hz - 75Hz - AC 50Hz 25mm/s 10mm/mv Cardiomin U-30 1.0.25 Simultaneous

ECG
ID
Nan
Gen
Age
Dep
Bed



History :

B.P. :

Drugs :

Standard :

Auricular Rate : N

Ventricular Rate : N

Rhythm : N

Mechanism :

Voltage :

Axis :

P Waves :

PR Interval :

Q. Waves :

QRS Interval :

ST Segment :

T. Waves :

QT Interval :

Extra Systoles :

REMARKS & CONCLUSIONS : Normal

.....

HEALTHCARE MEDICAL CENTRE & DIAGNOSTICS

MRS RENU PATURDE
 I.D. 964
 Age 31/F
 Date 27-04-2024

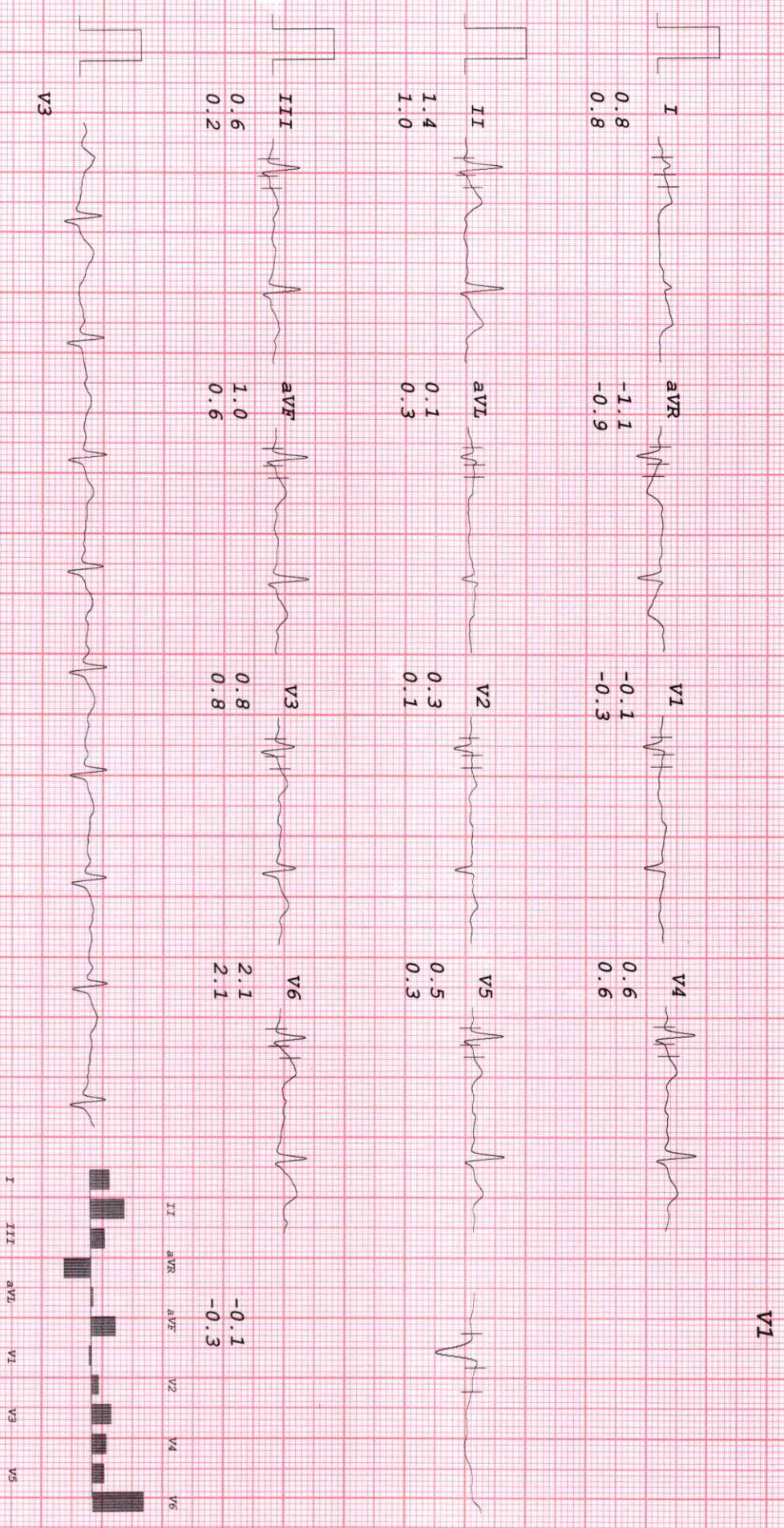
RATE 75bpm
 R.P. 110/70

PRETEST
 SUPINE

ST @ 10mm/mV
 80ms PostJ

LINKED MEDIAN

Mag. X 2



HEALTHCARE MEDICAL CENTRE & DIAGNOSTICS

MRS RENU PATURDE
 I.D. 964
 Age 31/F
 Date 27-04-2024

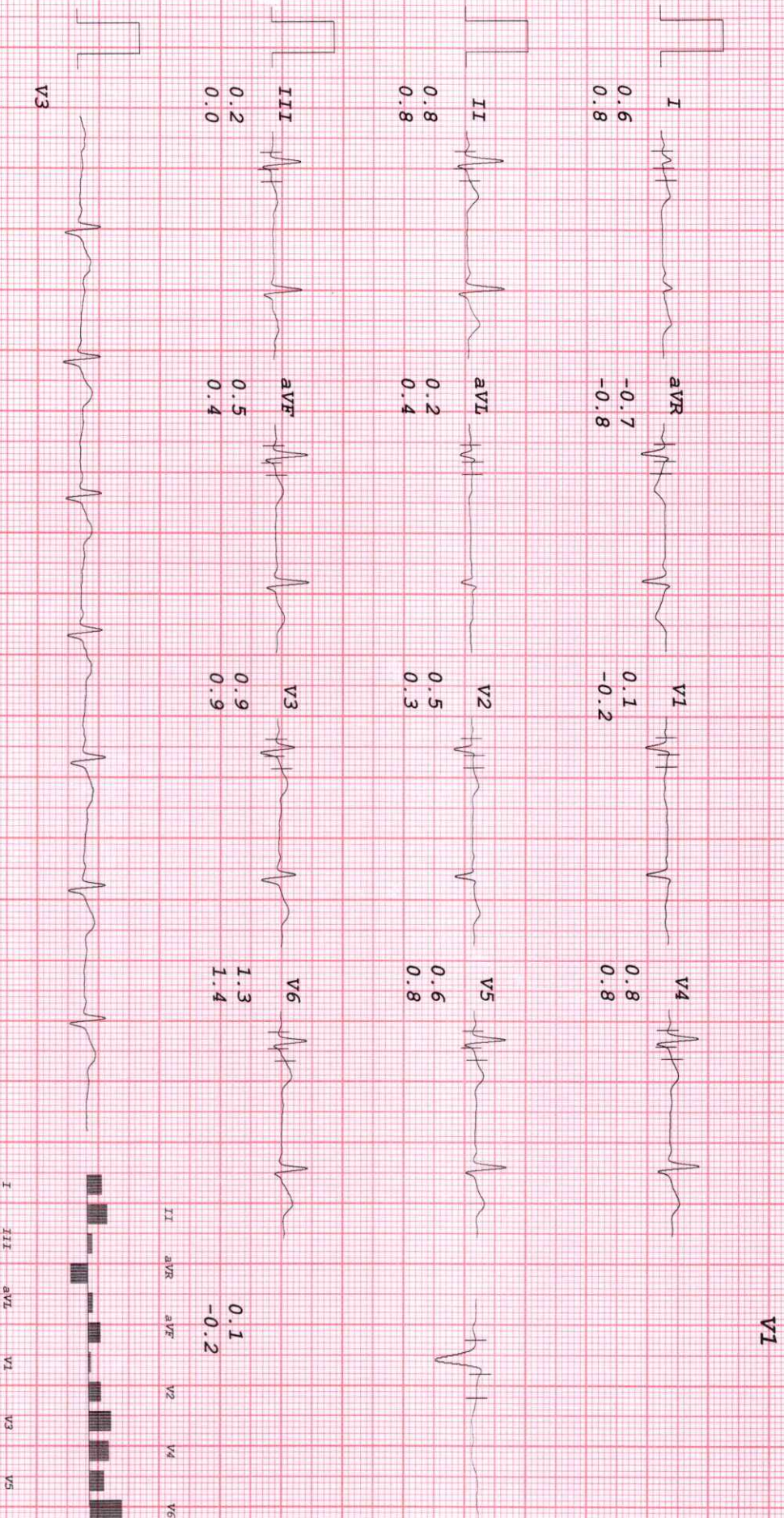
RATE 72bpm
 B.P. 110/70

PRETEST
 STANDING

ST @ 10mm/mV
 80ms PostJ

LINKED MEDIAN

Mag. X 2



HEALTHCARE MEDICAL CENTRE & DIAGNOSTICS

MRS RENU PATILDE
 I.D. 964
 Age 31/F
 Date 27-04-2024

RATE 69bpm
 B.P. 110/70

PRETEST
 HYPERVENT

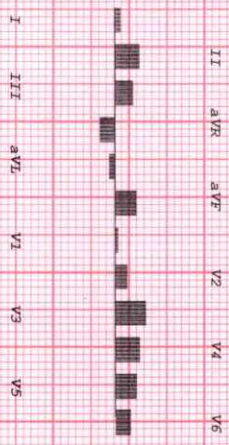
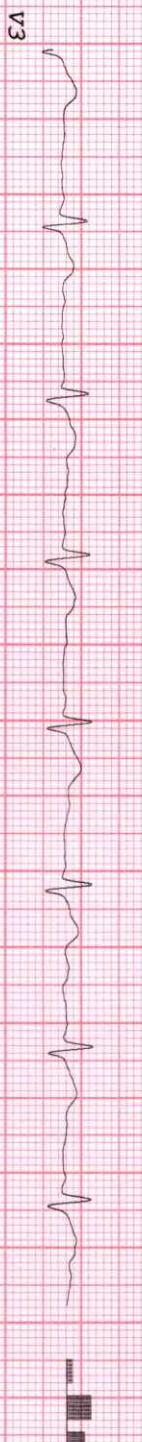
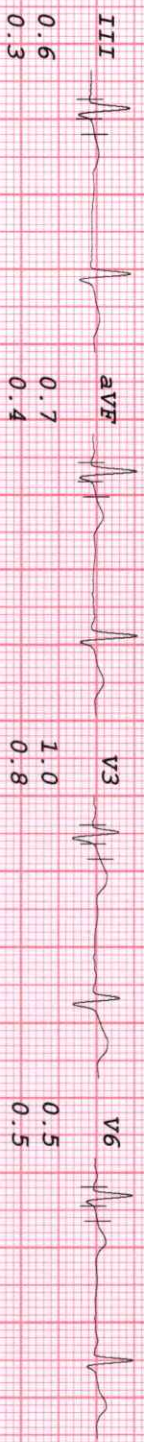
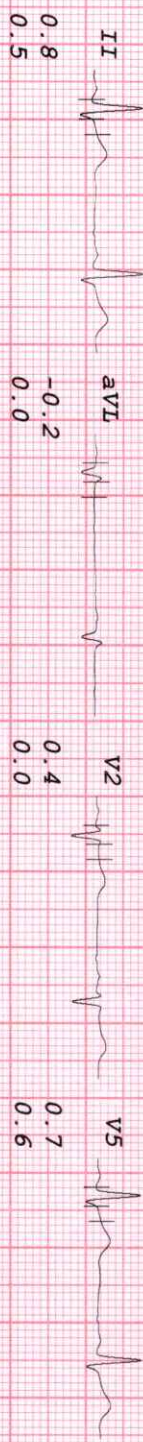
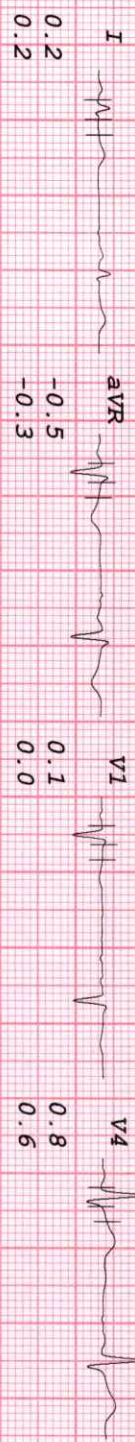
PHASE TIME 0:21

ST @ 10mm/mV
 80ms PostJ

LINKED MEDIAN

Mag. X 2

V1



HEALTHCARE MEDICAL CENTRE & DIAGNOSTICS

MRS RENU PATURDE
 I.D. 964
 Age 31/F
 Date 27-04-2024

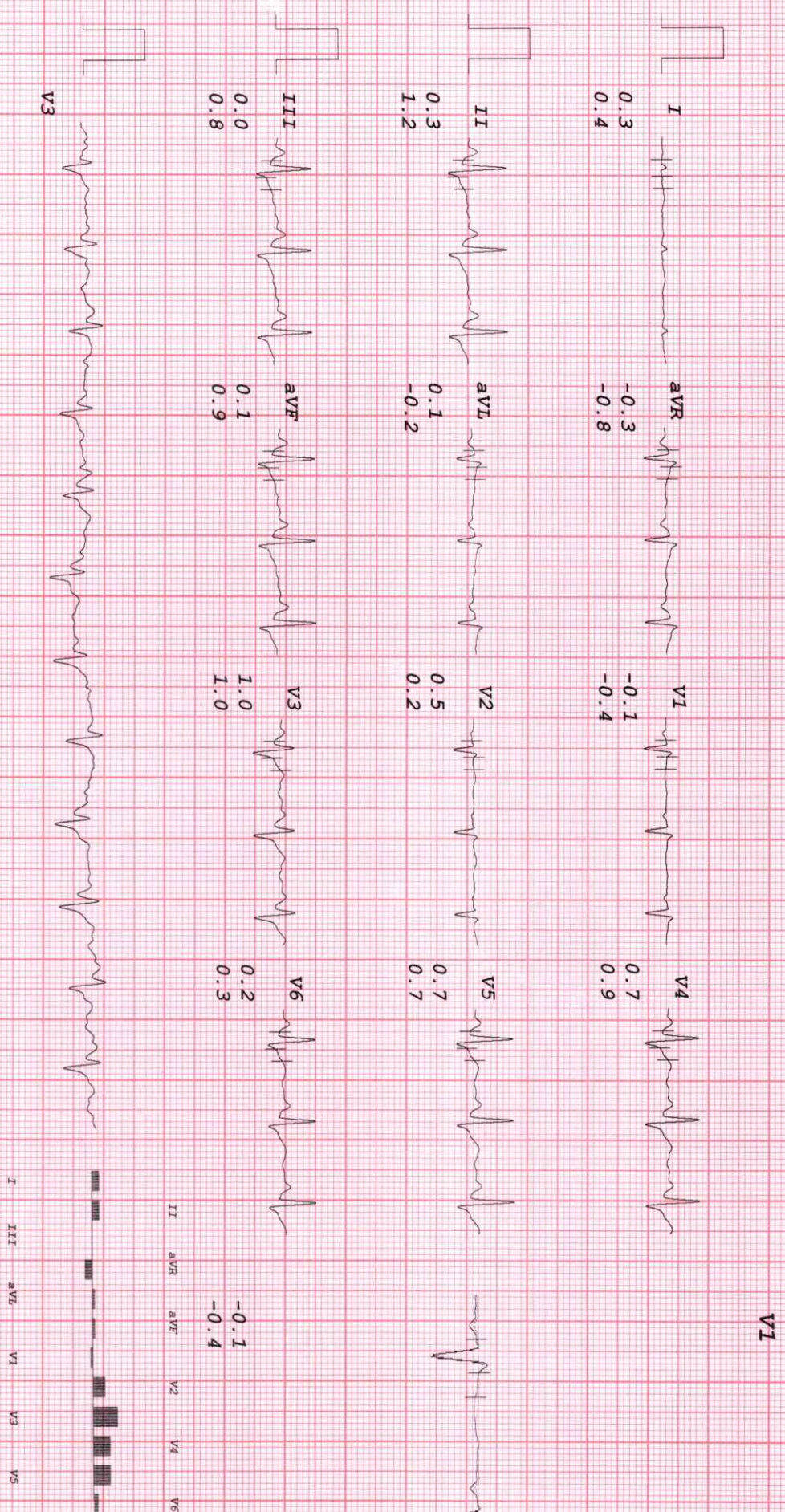
RATE 111bpm
 B.P. 110/70

Bruce
 Stage 1
 TOTAL TIME 2:55
 PHASE TIME 2:55

ST @ 10mm/mV
 80ms Post-J
 Speed 2.7 km/hr
 SLOPE 10 %

LINKED MEDIAN

Mag. X 2



HEALTHCARE MEDICAL CENTRE & DIAGNOSTICS

MRS RENU PATURDE
 I.D. 964
 Age 31/F
 Date 27-04-2024

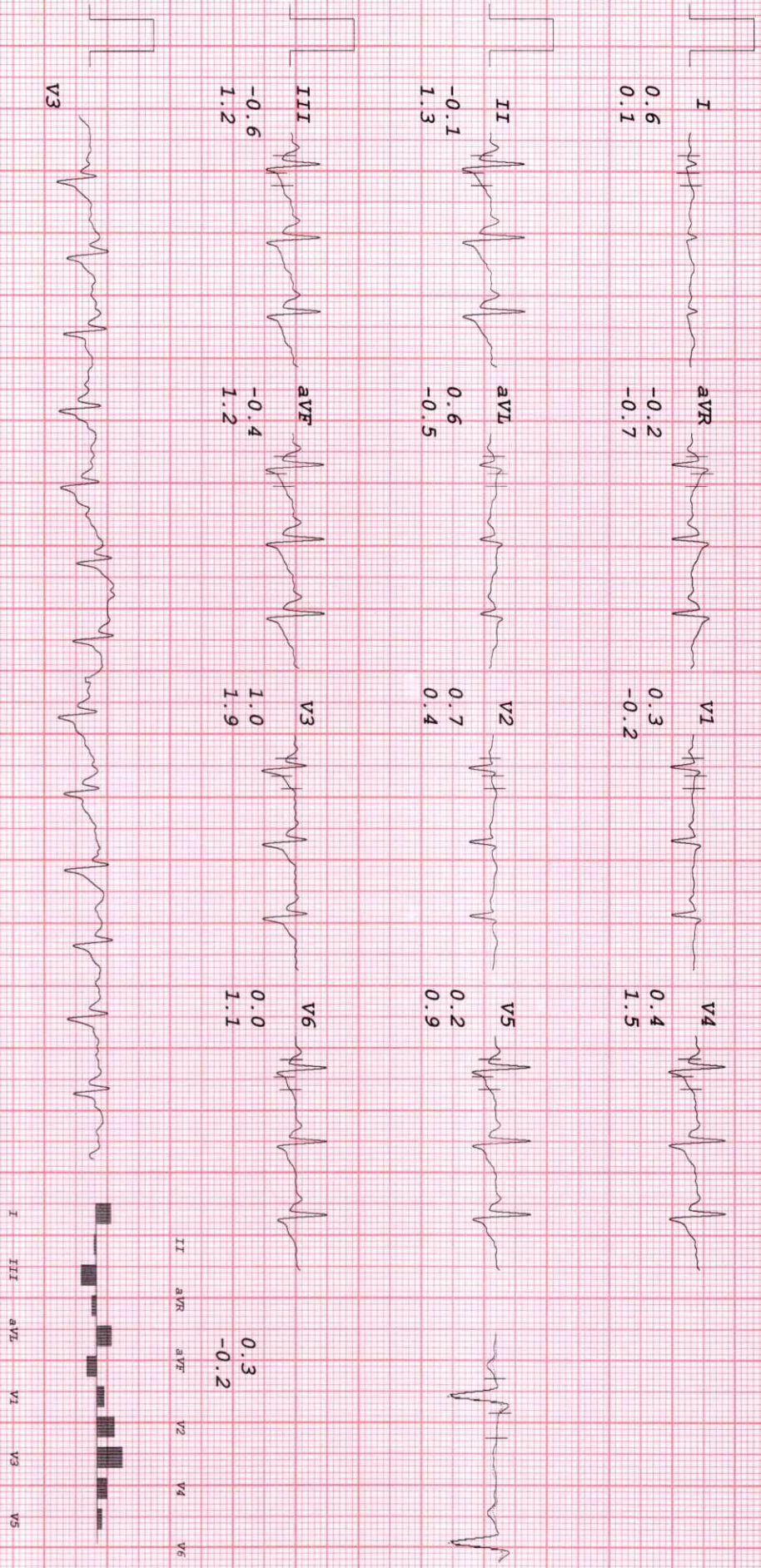
RATE 128bpm
 B.P. 116/76

Bruce
 Stage 2
 TOTAL TIME 5:55
 PHASE TIME 2:55

ST @ 10mm/mV
 80ms PostJ
 Speed 4 km/hr
 SLOPE 12 8

LINKED MEDIAN

Mag. X 2



HEALTHCARE MEDICAL CENTRE & DIAGNOSTICS

MRS RENU PATURDE
 I.D. 964
 Age 31/F
 Date 27-04-2024

RATE 150bpm
 B.P. 122/82

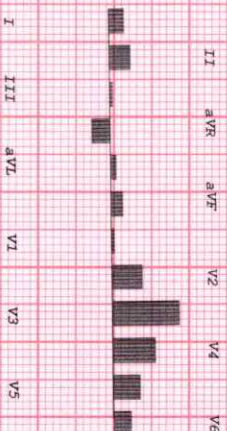
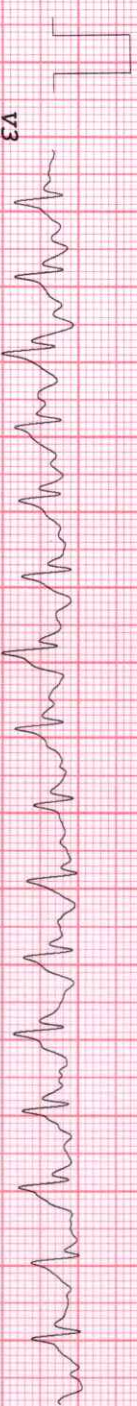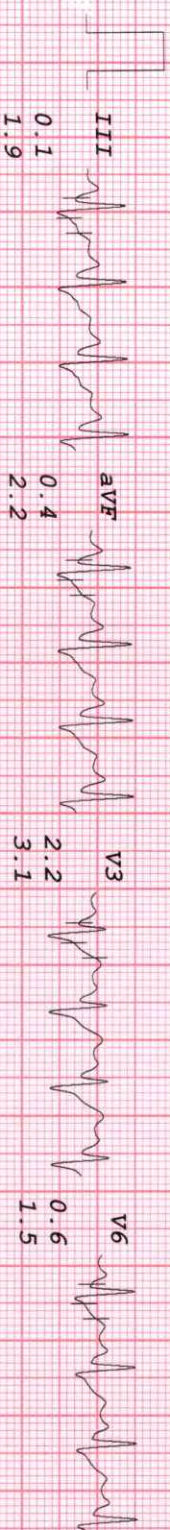
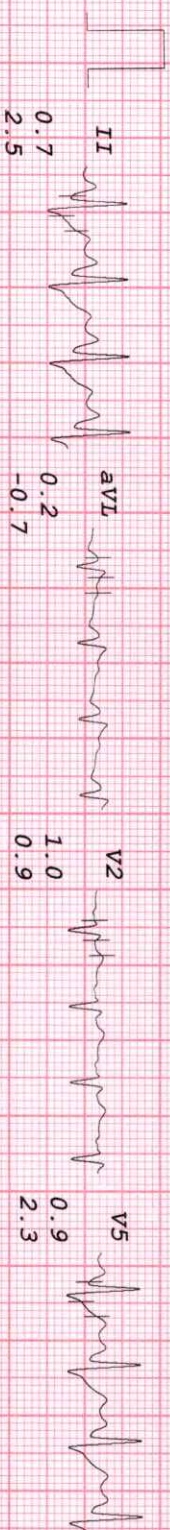
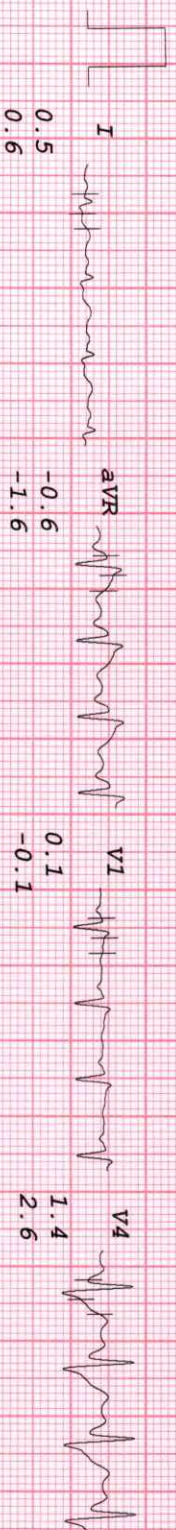
Brice
 Stage 3
 TOTAL TIME 8:55
 PHASE TIME 2:55

ST @ 10mm/mV
 80ms PostJ
 Speed 5.4 km/hr
 SLOPE 14 %

LINKED MEDIAN

Mag. X 2

V1



HEALTHCARE MEDICAL CENTRE & DIAGNOSTICS

MRS RENU PATURDE
 I.D. 964
 Age 31/F
 Date 27-04-2024

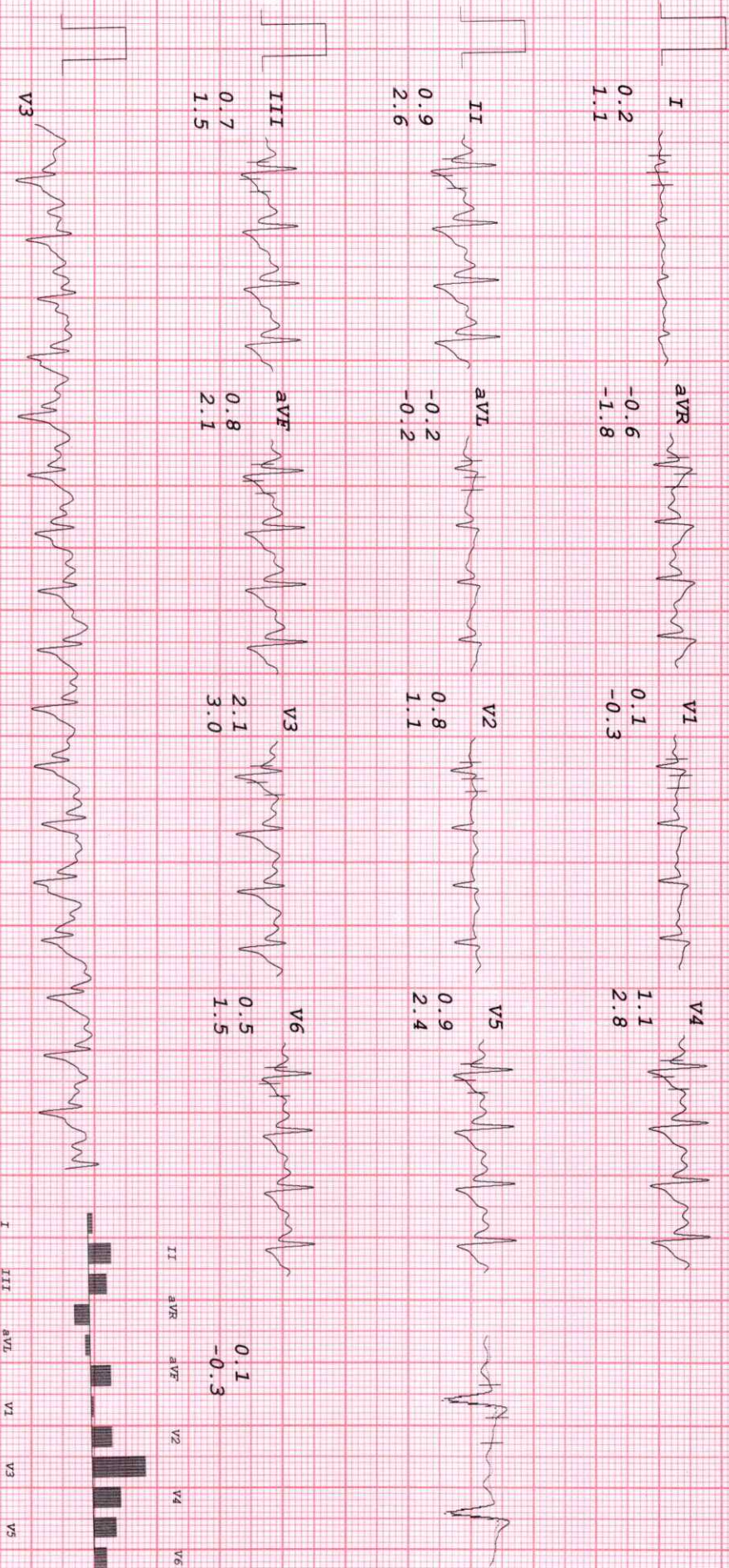
RATE 166bpm
 B.P. 128/88

Bruce
 PR-EXERCISE
 TOTAL TIME 9:20
 PHASE TIME 0:20

ST @ 10mm/mV
 80ms PostJ
 Speed 6.7 km/hr
 SLOPE 16 %

LINKED MEDIAN

Mag. X 2



HEALTHCARE MEDICAL CENTRE & DIAGNOSTICS

MRS RENU PATURDE
 I.D. 964
 Age 31/F
 Date 27-04-2024

RATE 129bpm
 B.P. 128/88

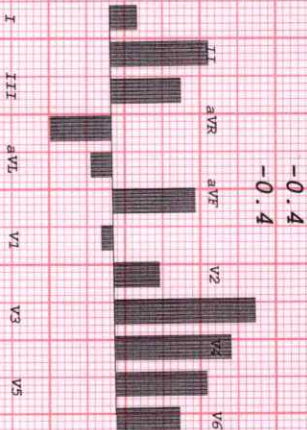
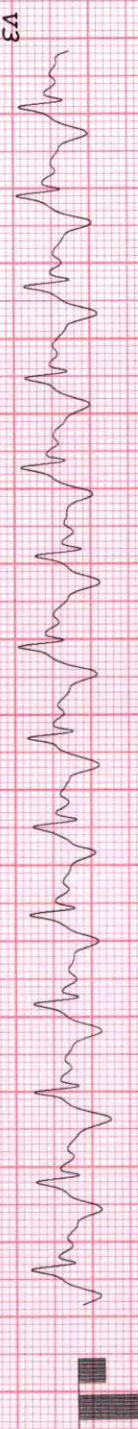
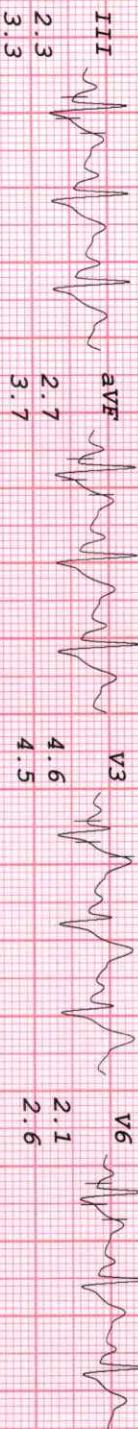
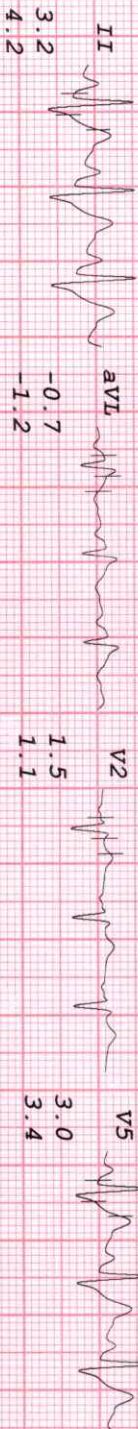
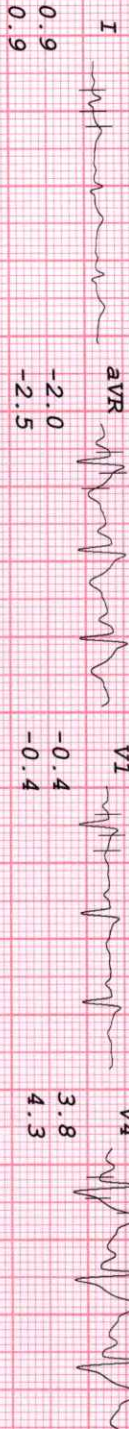
Brice
 RECOVERY
 TOTAL TIME 10:25
 PHASE TIME 0:55

ST @ 10mm/mV
 80ms PostJ

LINKED MEDIAN

Mag. X 2

V1



HEALTHCARE MEDICAL CENTRE & DIAGNOSTICS

MRS RENU PATIL
 I. D. 964
 Age 31/F
 Date 27-04-2024

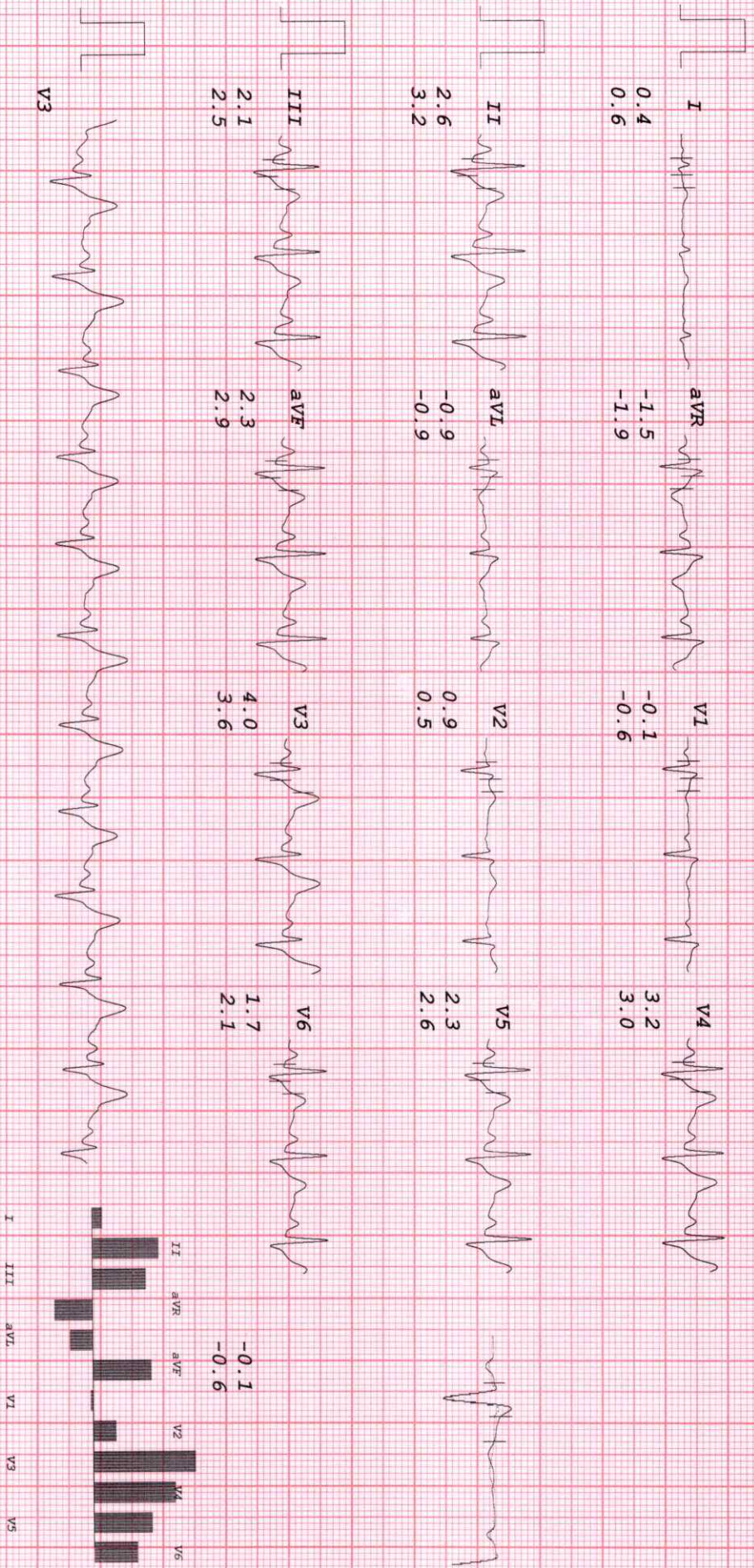
RATE 111bpm
 B.P. 124/84

Bruce
 RECOVERY
 TOTAL TIME 11:25
 PHASE TIME 1:55

ST @ 10mm/mV
 80ms PostJ

LINKED MEDIAN

Mag. X 2



HEALTHCARE MEDICAL CENTRE & DIAGNOSTICS

MRS RENU PATIL
 I.D. 964
 Age 31/F
 Date 27-04-2024

RATE 103bpm
 B.P. 118/78

Bruce
 RECOVERY
 TOTAL TIME 12:25
 PHASE TIME 2:55

ST @ 10mm/mV
 80ms PostJ

LINKED MEDIAN

Mag. X 2

