



MODERN PATHOLOGY & DIAGNOSTIC CENTRE

Dr. R. P. Rastogi
M.B.B.S., M.D. (Path & Bact)



CLINIC :

1/4A, Vineet Khand, (Opp Jaipuria Management)
Gomti Nagar, Lucknow - 226 010
Ph.: 0522-4008184, 4308184 ☎ 8112323230
Mob.: 7618884441, 9450389932, 8177063877

DATE : 24/08/2024

NAME : Mrs Neetu Rai

AGE : 42 Years SEX : F

HEIGHT : 166 CMS

WEIGHT : 77 KGS

BMI : 27.9

Blood Pressure : 124/76


Dr. Smita Rastogi
MBBS, DCP
Reg. No. 37370

Dr. Sanjay Rastogi
M.B.B.S., DCP, CRIAT (BARC)

Dr. Smita Rastogi
M.B.B.S., DCP

Results, adhering to W.H.O. and International Federation of Clinical Chemists Quality Control Standards.

SAMPLE COLLECTION FACILITY AVAILABLE

Report needs clinicopathological correlation ♦ Not for Medico Legal Purpose

e-mail : mpdcgn@gmail.com ♦ For online reports - www.modernpath.in

♦ Please ask for your computerized bill ♦ Pay only the printed collection charges

भारत सरकार
Government of India

नीतू राय
NITU RAI
जन्म तिथि/DOB: 15/08/1982
महिला/ FEMALE

Issue Date: 20/12/2013

2114 6723 8527
VID : 9163 8188 2245 2705

मेरा आधार, मेरी पहचान



भारतीय विश्वविद्यालय
Unique Identification Authority of India

पता:
W/O आशुतोष राय, नारही, बलिया,
उत्तर प्रदेश - 277502

Address:
W/O Ashutosh Rai, Narhi, Narahi, Ballia,
Uttar Pradesh - 277502

2114 6723 8527
VID : 9163 8188 2245 2705

1947 | help@uidai.gov.in | www.uidai.gov.in


Nitu Rai

You have been informed that, ophthalmology, dental consultation, Gynaecological, ENT or Dietician facility is not available at our centre. If you are ready then your test can be started.

2D echo test facility is not available at our centre, instead we do TMT test.

Nitesh Rai





MODERN PATHOLOGY & DIAGNOSTIC CENTRE

DIAGNOSTIC CENTRE

Dr. R. P. Rastogi
M.B.B.S., M.D. (Path & Bact)



CLINIC :

1/4A, Vineet Khand, (Opp Jaipuria Management)
Gomti Nagar, Lucknow - 226 010
Ph.: 0522-4008184, 4308184 ☎ 8112323230
Mob.: 7618884441, 9450389932, 8177063877

Date	: 24-Aug-2024		
Name	: Mrs. NEETU RAI	Age	: 42 Yrs.
Ref.By	: APOLLO HEALTH	Sex	: Female

Haemoglobin	12.9	gm%	11 - 14
-------------	------	-----	---------

Total Leucocyte Count	5200	Cells/cumm.	4000-11000
-----------------------	------	-------------	------------

Differential Leucocyte Count			
Polymorphs	61	%	45 - 70
Lymphocytes	23	%	20 - 45
Eosinophils	10	%	0 - 6
Monocytes	06	%	0 - 8
Basophils	00	%	0 - 1

Erythrocyte Sedimentation Rate (Wintrobe)			
ESR	14	mm in 1st Hr.	0 - 19
PCV	42.0	cc%	40 - 52
Corrected ESR	08	mm in 1st Hr.	0 - 19

Platelet Count	1.70	lakh/cumm.	1.5 - 4.0
----------------	------	------------	-----------

Red Cells Count	4.52	million/cmm	3.90 to 4.60
-----------------	------	-------------	--------------

Absolute values			
MCV	82.1	fL	77 - 97
MCH	25.2	pg	27 - 31
MCHC	30.7	gm /dl	31 - 34

Dr. Sanjay Rastogi
M.B.B.S., (D.P.O. & R.C.P.)

Dr. Smriti Rastogi
M.B.B.S., DCP

Results, adhering to W.H.O. and International Federation of Clinical Chemists Quality Control Standards.

SAMPLE COLLECTION FACILITY AVAILABLE

Report needs clinicopathological correlation ♦ Not for Medico Legal Purpose

e-mail : mpdcgn@gmail.com ♦ For online reports - www.modernpath.in

♦ Please ask for your computerized bill ♦ Pay only the printed collection charges



MODERN PATHOLOGY & DIAGNOSTIC CENTRE

Dr. R. P. Rastogi
M.B.B.S., M.D. (Path & Bact)



CLINIC :

1/4A, Vineet Khand, (Opp Jaipuria Management)
Gomti Nagar, Lucknow - 226 010
Ph.: 0522-4008184, 4308184 • 8112323230
Mob.: 7618884441, 9450389932, 8177063877

Date	: 24-Aug-2024		
Name	: Mrs. NEETU RAI	Age	: 42 Yrs.
Ref.By	: APOLLO HEALTH	Sex	: Female

General Blood Picture	
RBCs	RBCs are Normocytic & Normochromic. No Normoblasts are seen.
WBCs	TLC is within normal range. DLC shows increased number of eosinophils. No immature cells of WBC seen.
PLATELETS	Platelets are adequate in number and morphology.
OTHERS	No haemoparasites are seen.
IMPRESSION	Eosinophilia

Dr. Sanjay Rastogi
M.B.B.S., DCP (Path & Bact)

Dr. Smita Rastogi
M.B.B.S., DCP

Results, adhering to W.H.O. and International Federation of Clinical Chemists Quality Control Standards.

SAMPLE COLLECTION FACILITY AVAILABLE

Report needs clinicopathological correlation ♦ Not for Medico Legal Purpose

e-mail : mpdcgn@gmail.com ♦ For online reports - www.modernpath.in

♦ Please ask for your computerized bill ♦ Pay only the printed collection charges



MODERN PATHOLOGY & DIAGNOSTIC CENTRE

DIAGNOSTIC CENTRE

Dr. R. P. Rastogi
M.B.B.S., M.D. (Path & Bact)



CLINIC :

1/4A, Vineet Khand, (Opp Jaipuria Management)
Gomti Nagar, Lucknow - 226 010
Ph.: 0522-4008184, 4308184 ☎ 8112323230
Mob.: 7618884441, 9450389932, 8177063877

Date	: 24-Aug-2024		
Name	: Mrs. NEETU RAI	Age	: 42 Yrs.
Ref.By	: APOLLO HEALTH	Sex	: Female

Plasma Glucose - F GOD-POD Method	108	mg/dl	70 - 110
--------------------------------------	-----	-------	----------

Plasma Glucose - PP GOD POD Method	126	mg/dl	110 - 170
---------------------------------------	-----	-------	-----------

Blood Group & Rh	"B" Positive		
------------------	--------------	--	--

LFT T&D			
Total Bilirubin	0.48	mg%	0.2 - 1.0
Direct Bilirubin	0.10	mg%	0.0 to 0.40
Indirect Bilirubin	0.38	mg%	0.10 to 0.90
S.G.P.T	64	IU/L	5 - 40
S.G.O.T	58	IU/L	5 - 50
ALP	96	IU/L	35 to 104

Serum Gamma G.T.	18	IU/L	11 - 50
------------------	----	------	---------

KFT			
UREA	19.6	mg %	15 - 50
CREATININE	0.68	mg %	0.5 - 1.5
URIC ACID	5.0	mg %	2 - 6
CALCIUM	9.1	mg %	8.8 - 10.0

Urine Sugar (Fasting)	NIL		
-----------------------	-----	--	--

Urine Sugar (PP)	NIL		
------------------	-----	--	--

Dr. Sanjay Rastogi
M.B.B.S., DCP, CRIAT (BARC)

Dr. Smita Rastogi
Contd... M.B.B.S., DCP

Results, adhering to W.H.O. and International Federation of Clinical Chemists Quality Control Standards.

SAMPLE COLLECTION FACILITY AVAILABLE

Report needs clinicopathological correlation ♦ Not for Medico Legal Purpose

e-mail : mpdcgn@gmail.com ♦ For online reports - www.modernpath.in

♦ Please ask for your computerized bill ♦ Pay only the printed collection charges



MODERN PATHOLOGY & DIAGNOSTIC CENTRE

Dr. R. P. Rastogi
M.B.B.S., M.D. (Path & Bact)



CLINIC :

1/4A, Vineet Khand, (Opp Jaipuria Management)
Gomti Nagar, Lucknow - 226 010
Ph.: 0522-4008184, 4308184 ☎ 8112323230
Mob.: 7618884441, 9450389932, 8177063877

Date	: 24-Aug-2024	Age	: 42 Yrs.
Name	: Mrs. NEETU RAI	Sex	: Female
Ref.By	: APOLLO HEALTH		

LIPID PROFILE

Triglycerids	100	mg%	70 - 190
S. Cholestrol S.	140	mg%	130 - 230
S. HDL Cholestrol	40.4	mg%	35 - 75
S. LDL Cholestrol	79.6	mg%	75 - 150
VLDL	20	mg%	0 - 34
Chol / HDL factor	3.47		
LDL / HDL Factor	1.97		

=====

COMMENTS

=====

- * Triglycerides (TG) are the main dietary lipids. Cholesterol constitutes a small part of the dietary lipids, it is mostly synthesised in the liver. Both TG and Chol. are transported through the plasma by lipoproteins (Chylomicrons, VLDL, LDL, IDL, HDL).
- * LDL is the major cholesterol particle in plasma and high levels are strongly implicated in the formation of atheroma. An increase in the LDL leads to hypercholesterolemia, and therefore a risk factor for IHD. LDL increases with age particularly in females. Oestrogen lowers LDL and raises HDL. Raised chol. in females is mostly due to disturbed thyroid function.
- * Increase in VLDL leads to hyperglyceridaemia. Raised TGs are associated with increased risk of CHD. Very high TGs increase the risk of Pancreatitis. Cholesterol is often raised due to Diabetes, Renal disease, Diuretic or Beta-blocker therapy.

TYPES OF HYPERLIPOPROTEINEMIAS

TYPE 1: Normal cholesterol TG greatly raised	TYPE 3: Cholesterol increased TG increased
TYPE 2a: Cholesterol increased LDL increased TG normal	TYPE 4: Cholesterol normal /increased VLDL increased TG increased
TYPE 2b Chol. increased VLDL raised TG increased LDL increased	TYPE 5: Cholesterol increased LDL reduced VLDL increased TG greatly increased

Dr. Sanjay Rastogi
M.B.B.S., DCP, CRIAT (BARC)

Dr. Smita Rastogi
Contd... M.B.B.S., DCP

Results, adhering to W.H.O. and International Federation of Clinical Chemists Quality Control Standards.

SAMPLE COLLECTION FACILITY AVAILABLE

Report needs clinicopathological correlation ♦ Not for Medico Legal Purpose

e-mail : mpdcgn@gmail.com ♦ For online reports - www.modernpath.in

♦ Please ask for your computerized bill ♦ Pay only the printed collection charges



MODERN PATHOLOGY & DIAGNOSTIC CENTRE

DIAGNOSTIC CENTRE

Dr. R. P. Rastogi
M.B.B.S., M.D. (Path & Bact)



CLINIC :

1/4A, Vineet Khand, (Opp Jaipuria Management)
Gomti Nagar, Lucknow - 226 010
Ph.: 0522-4008184, 4308184 ☎ 8112323230
Mob.: 7618884441, 9450389932, 8177063877

Date	: 24-Aug-2024		
Name	: Mrs. NEETU RAI	Age	: 42 Yrs.
Ref.By	: APOLLO HEALTH	Sex	: Female

THYROID TEST

Tri-iodothyronine (T3)	1.65	nmol/L	0.50 to 2.50
Thyroxine (T4)	7.10	mcg/dL	5.0 to 12.5
Thyroid Stimulating Hormone (TSH)	2.15	mIU/ ml	0.3 to 6.0

=====

COMMENTS

=====

- 1) Primary hyperthyroidism is accompanied by elevated Serum T3 and T4 values along with depressed TSH levels.
- 2) Primary Hypothyroidism is accompanied by depressed serum T3 and T4 values and elevated serum TSH levels.
- 3) Normal T4 levels accompanied by high T3 levels are seen in patients with T3 thyrotoxicosis.
- 4) Slightly elevated T3 levels may be found in pregnancy and estrogen therapy, while depressed levels may be encountered in severe illness, malnutrition, renal failure and during therapy with drugs like propranolol and propylthiouracil.
- 5) Elevated TSH levels may also be indicative of TSH secreting Pituitary Tumour.

Dr. Sanjay Rastogi
M.B.B.S., DCP, CRIAT (BARC)

Dr. Smita Rastogi
Contd... M.B.B.S., DCP

Results, adhering to W.H.O. and International Federation of Clinical Chemists Quality Control Standards.

SAMPLE COLLECTION FACILITY AVAILABLE

Report needs clinicopathological correlation ♦ Not for Medico Legal Purpose

e-mail : mpdcgn@gmail.com ♦ For online reports - www.modernpath.in

♦ Please ask for your computerized bill ♦ Pay only the printed collection charges



MODERN PATHOLOGY & DIAGNOSTIC CENTRE

DIAGNOSTIC CENTRE

Dr. R. P. Rastogi
M.B.B.S., M.D. (Path & Bact)



CLINIC :

1/4A, Vineet Khand, (Opp Jaipuria Management)
Gomti Nagar, Lucknow - 226 010
Ph.: 0522-4008184, 4308184 ☎ 8112323230
Mob.: 7618884441, 9450389932, 8177063877

Date	: 24-Aug-2024		
Name	: Mrs. NEETU RAI	Age	: 42 Yrs.
Ref.By	: APOLLO HEALTH	Sex	: Female

Glycosylated Haemoglobin

Glycosylated Haemoglobin	5.8	%	4.5 TO 6.0
--------------------------	-----	---	------------

=====

INTERPRETATION AND COMMENTS

=====

NON DIABETIC : 4.5 to 6.0 %
 GOOD CONTROL: 6.0 to 7.0
 FAIR CONTROLLED 7.0 AND 8.0
 UNCONTROLLED 8.0 AND ABOVE

Glycosylated haemoglobin is the adducted glucose in the haemoglobin of the red blood cells, this adduction is stable for the life time of the RBC (i.e 120 days). There fore the measure of glycosylated haemoglobin reflects the average blood glucose concentration over the preseding several weeks. The sudden change in blood glucose level would not effect the glycosylated haemoglobin level ,which serves as a better marker of long term metabolic control and the efficacy of therapy.

Dr. Sanjay Rastogi
M.B.B.S., DCP, CRIAT (BARC)

Dr. Smita Rastogi
Contd... M.B.B.S., DCP

Results, adhering to W.H.O. and International Federation of Clinical Chemists Quality Control Standards.

SAMPLE COLLECTION FACILITY AVAILABLE

Report needs clinicopathological correlation ♦ Not for Medico Legal Purpose

e-mail : mpdcgn@gmail.com ♦ For online reports - www.modernpath.in

♦ Please ask for your computerized bill ♦ Pay only the printed collection charges



MODERN PATHOLOGY & DIAGNOSTIC CENTRE

DIAGNOSTIC CENTRE

Dr. R. P. Rastogi
M.B.B.S., M.D. (Path & Bact)



CLINIC :

1/4A, Vineet Khand, (Opp Jaipuria Management)
Gomti Nagar, Lucknow - 226 010
Ph.: 0522-4008184, 4308184 ☎ 8112323230
Mob.: 7618884441, 9450389932, 8177063877

Date	: 24-Aug-2024	Age	: 42 Yrs.
Name	: Mrs. NEETU RAI	Sex	: Female
Ref.By	: APOLLO HEALTH		

Urine Examination

PHYSICAL			
Colour	Straw		
Turbidity	Nil		
Deposit	Nil		
Reaction	Acidic		
*Specific Gravity	1.015		
CHEMICAL			
Protein	Nil		
Sugar	Nil		
*Bile Salts	Nil		
*Bile Pigments	Nil		
Phosphate	Nil		
MICROSCOPIC			
Pus Cells	Nil	/hpf	
Epithelial Cells	1-2	/hpf	
Red Blood Cells	Nil	/hpf	
Casts	Nil		
Crystals	Nil		
Others	Nil		

Dr. Sanjay Rastogi
M.B.B.S., DCP, CRP (BARC)

Dr. Smita Rastogi
M.B.B.S., DCP

Results, adhering to W.H.O. and International Federation of Clinical Chemists Quality Control Standards.

SAMPLE COLLECTION FACILITY AVAILABLE

Report needs clinicopathological correlation ♦ Not for Medico Legal Purpose

e-mail : mpdcgn@gmail.com ♦ For online reports - www.modernpath.in

♦ Please ask for your computerized bill ♦ Pay only the printed collection charges



MODERN PATHOLOGY & DIAGNOSTIC CENTRE

DIAGNOSTIC CENTRE

Dr. R. P. Rastogi
M.B.B.S., M.D. (Path & Bact)



CLINIC :
1/4A, Vineet Khand, (Opp Jaipuria Management)
Gomti Nagar, Lucknow - 226 010
Ph.: 0522-4008184, 4308184 • 8112323230
Mob.: 7618884441, 9450389932, 8177063877

SAMPLE DATE : 24/08/2024
NAME : Mrs Neetu Rai
AGE/SEX : 42/YRS/FEMALE
REFERRED BY : Apollo Health .

Test Name	Result	Bio. Ref. Range	Unit
-----------	--------	-----------------	------

CLINICAL PATHOLOGY TEST REPORT

PAP

GROSS:

Smears collected from the ecto and the endo cervix. Slides prepared and stained with PAP stain.

MICROSCOPIC:

Smears studied show adequate representing material, comprising mainly of squamous epithelial cells. These cells have abundant pale pink eosinophilic cytoplasm and normal appearing round to oval nuclei. Smears from the endocervix show fair number of "stripped nuclei" of the endometrial cells. Occasional small cluster of the endometrial cells are seen. These cells have indistinct cellular borders, scanty basophilic cytoplasm and oval nuclei with clumped chromatin. Smears from both the sites are mildly infiltrated with inflammatory cells, mostly polymorphs

IMPRESSION: SMEARS SUGGESTIVE OF NORMAL PAP SMEAR WITH MODERATE INFLAMMATION

*** End Of Report ***

Dr. Sanjay Rastogi
M.B.B.S., DCP, CRIAT (BARC)

Dr. Smita Rastogi
M.B.B.S., DCP

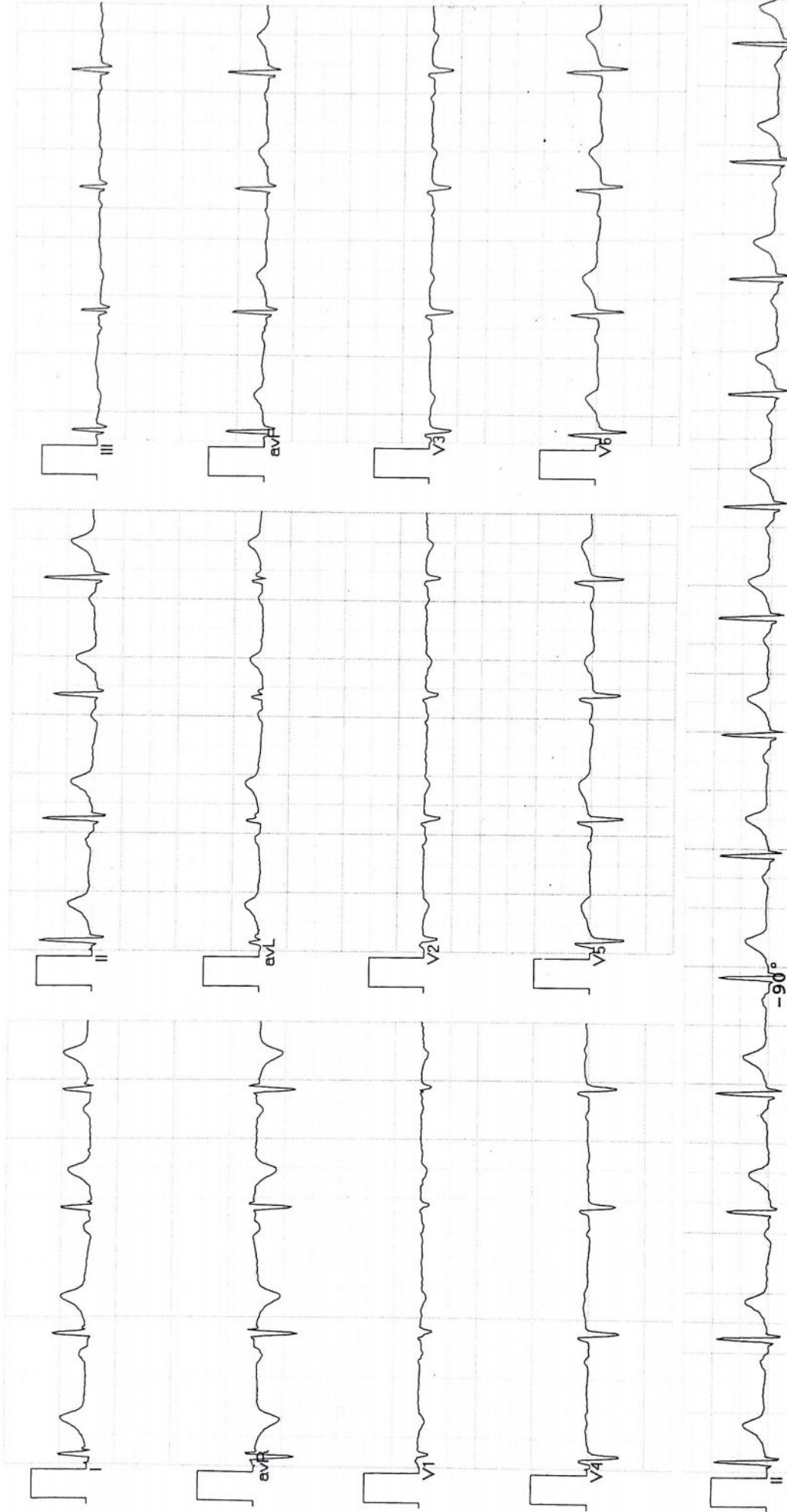
Results, adhering to W.H.O. and International Federation of Clinical Chemists Quality Control Standards.

SAMPLE COLLECTION FACILITY AVAILABLE

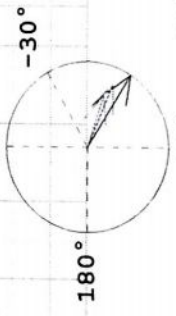
Report needs clinicopathological correlation ♦ Not for Medico Legal Purpose

e-mail : mpdcgn@gmail.com ♦ For online reports - www.modernpath.in

♦ Please ask for your computerized bill ♦ Pay only the printed collection charges



Vent Rate : 76 bpm
 PR Interval : 166 ms
 QRS Duration: 80 ms
 QT/QTc Int : 372/398 ms
 P-QRS-T axis: 18.00 • 32.00 • 23.00 •



Axis

90° R 32° T 23° P 18°

Normal ECG

Nity Rai

Dr. AMIT MOHAN MD
 Reg No. 44559



MODERN PATHOLOGY & DIAGNOSTIC CENTRE

DIAGNOSTIC CENTRE

Dr. R. P. Rastogi
M.B.B.S., M.D. (Path & Bact)



CLINIC :
1/4A, Vineet Khand, (Opp Jaipuria Management)
Gomti Nagar, Lucknow - 226 010
Ph.: 0522-4008184, 4308184 ☎ 8112323230
Mob.: 7618884441, 9450389932, 8177063877



TEST REQUEST ID :012408240026	SAMPLE DATE	:24/Aug/2024 09:31AM
NAME :Mrs. NEETU RAI	SAMPLE REC. DATE	:24/Aug/2024 09:31AM
AGE/SEX :42 YRS/FEMALE	REPORTED DATE	:24/Aug/2024 11:15AM
REFERRED BY : Apollo Health and Lifestyle Limited,	BARCODE NO	:01240026

XRAY CHEST PA

- Trachea is central in position.
- Bilateral lung fields are normally aerated.
- Both hilar shadows are normal.
- Both C.P. angles are clear.
- Cardiac shadow is within normal limits.
- Bony cage appears normal.

Please correlate clinically.

*** End Of Report ***



Sanjay Rastogi
M.B.B.S., DCP, CRIAT (BARC)

Surbhi
Dr.Surbhi
MBBS,MD (Radiodiagnosis)

Dr. Smita Rastogi
M.B.B.S., DCP

Results, adhering to W.H.O. and International Federation of Clinical Chemists Quality Control Standards.

SAMPLE COLLECTION FACILITY AVAILABLE

Report needs clinicopathological correlation ♦ Not for Medico Legal Purpose

e-mail : mpdcgn@gmail.com ♦ For online reports - www.modernpath.in

Print Date/Time: 24/08/2024 12:57 PM

♦ Please ask for your computerized bill ♦ Pay only the printed collection charges



MODERN PATHOLOGY & DIAGNOSTIC CENTRE

CLINIC :

1/4A, Vineet Khand, (Opp Jaipuria Management)
Gomti Nagar, Lucknow - 226 010
Ph.: 0522-4008184, 4308184 ☎ 8112323230
Mob.: 7618884441, 9450389932, 8177060677

Dr. R. P. Rastogi
M.B.B.S., M.D. (Path & Bact)



TEST REQUEST ID :012408240026	SAMPLE DATE	:24/Aug/2024 09:31AM
NAME :Mrs. NEETU RAI	SAMPLE REC. DATE	:24/Aug/2024 09:31AM
AGE/SEX :42 YRS/FEMALE	REPORTED DATE	:24/Aug/2024 11:11AM
REFERRED BY : Apollo Health and Lifestyle Limited,	BARCODE NO	:01240026

USG WHOLE ABDOMEN-FEMALE

Liver: is normal in size (145 mm). Parenchymal echogenicity is normal. No focal echovariant lesion is seen. Intrahepatic biliary radicles are not dilated.

Gall Bladder: is well distended. Lumen is anechoic. Wall is of normal thickness.

CBD: is normal in diameter. Portal vein is normal in diameter.

Pancreas: is normal in size, shape and echotexture. No focal echovariant lesion is seen. Pancreatic duct is not dilated.

Spleen: is normal in size (104 mm), shape and echotexture. No focal echovariant lesion is seen. Splenic vein is normal.

Right Kidney: is normal in size 93x41 mm, shape, position and excursion. Parenchymal echogenicity and echotexture is normal with maintained corticomedullary differentiation. No mass, cyst, or calculi is seen. Pelvicalyceal systems are not dilated. Ureter is not dilated.

Left Kidney: is normal in size 95x40 mm, shape, position and excursion. Parenchymal echogenicity and echotexture is normal with maintained corticomedullary differentiation. No mass, cyst, or calculi is seen. Pelvicalyceal systems are not dilated. Ureter is not dilated.



Surbhi

Dr. Surbhi
MBBS, MD (Radiodiagnosis)

Dr. Sanjay Rastogi
M.B.B.S., DCP, CRIAT (BARC)

Dr. Smita Rastogi
M.B.B.S., DCP

Results, adhering to W.H.O. and International Federation of Clinical Chemists Quality Control Standards.

SAMPLE COLLECTION FACILITY AVAILABLE

Report needs clinicopathological correlation ♦ Not for Medico Legal Purpose

Print Date/Time: 24/08/2024 11:11 AM

e-mail : mpdcgn@gmail.com ♦ For online reports - www.modernpath.in

Checked By: SURBHI

Page 1 of 2

♦ Please ask for your computerized bill ♦ Pay only the printed collection charges



MODERN PATHOLOGY & DIAGNOSTIC CENTRE

Dr. R. P. Rastogi
M.B.B.S., M.D. (Path & Bact)

CLINIC :

1/4A, Vineet Khand, (Opp Jaipuria Management)
Gomti Nagar, Lucknow - 226 010
Ph.: 0522-4008184, 4308184 • 8112323230
Mob.: 7618884441, 9450389932, 8177069877



TEST REQUEST ID :012408240026	SAMPLE DATE	:24/Aug/2024 09:31AM
NAME :Mrs. NEETU RAI	SAMPLE REC. DATE	:24/Aug/2024 09:31AM
AGE/SEX :42 YRS/FEMALE	REPORTED DATE	:24/Aug/2024 11:11AM
REFERRED BY : Apollo Health and Lifestyle Limited,	BARCODE NO	:01240026

Urinary bladder: is well distended. Lumen is anechoic. Wall is of normal thickness. No mass or calculus is seen.

Uterus: is normal in size (38x56x88 mms), shape and echotexture. It is anteverted. Myometrium is homogenous. No focal mass is seen. Endometrial thickness is normal 8.5 mm. Cervix appears normal in size 29.5 mm, shape and echotexture. No evidence of collection in cervical canal.

Bilateral Ovaries and adnexae: Both ovaries are normal in size (RO - 22x23x26 mms vol 7.4 cc & LO - 12x22x26 mms vol 3.6 cc), shape and echotexture. No adnexal solid or cystic mass lesion is seen.

Both iliac fossae are clear. No obvious bowel pathology is noted. There is no free fluid in peritoneal cavity.

OPINION:

- **NORMAL STUDY.**

*** End Of Report ***



Dr. Sanjay Rastogi
M.B.B.S., DCP, CRIAT (BARC)

Surbhi
Dr. Surbhi
MBBS, MD (Radiodiagnosis)

Dr. Smita Rastogi
M.B.B.S., DCP

Results, adhering to W.H.O. and International Federation of Clinical Chemists Quality Control Standards.

SAMPLE COLLECTION FACILITY AVAILABLE

Report needs clinicopathological correlation ♦ Not for Medico Legal Purpose

Print Date/Time: 24/08/2024 11:11 AM

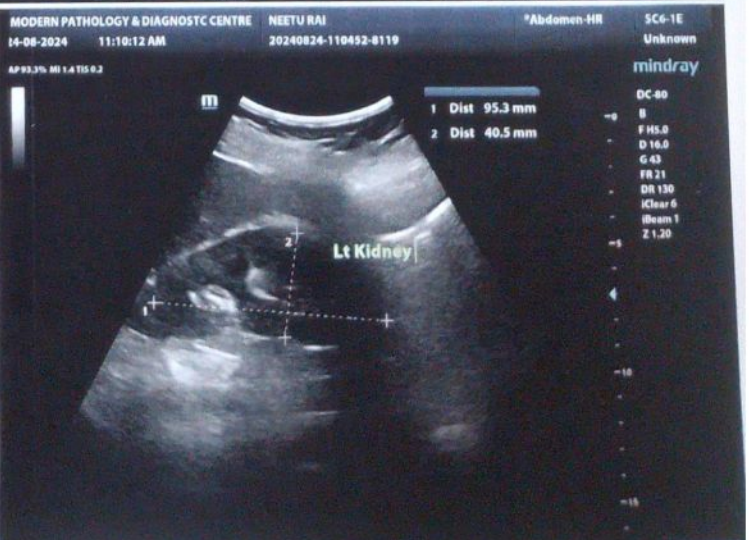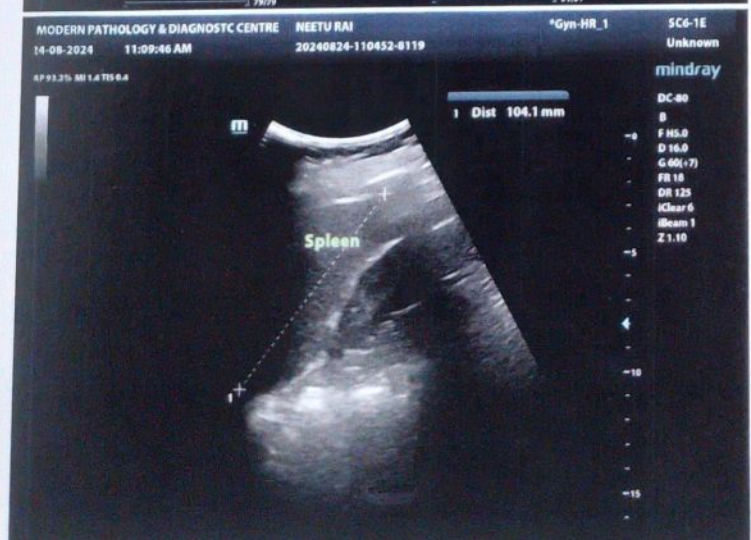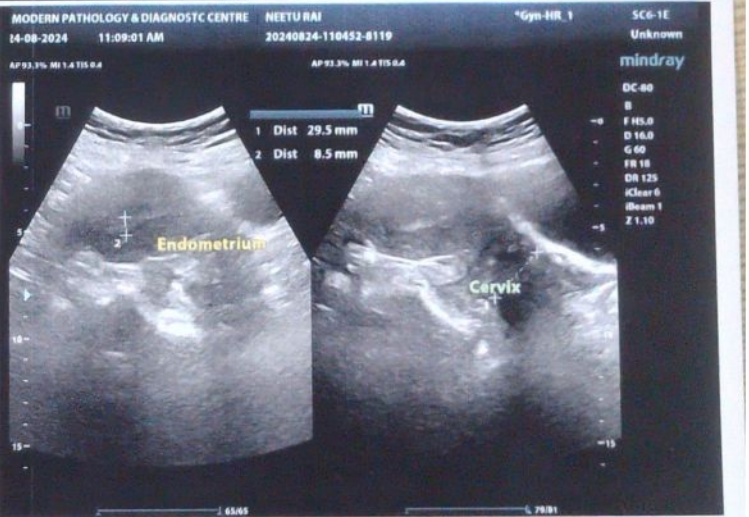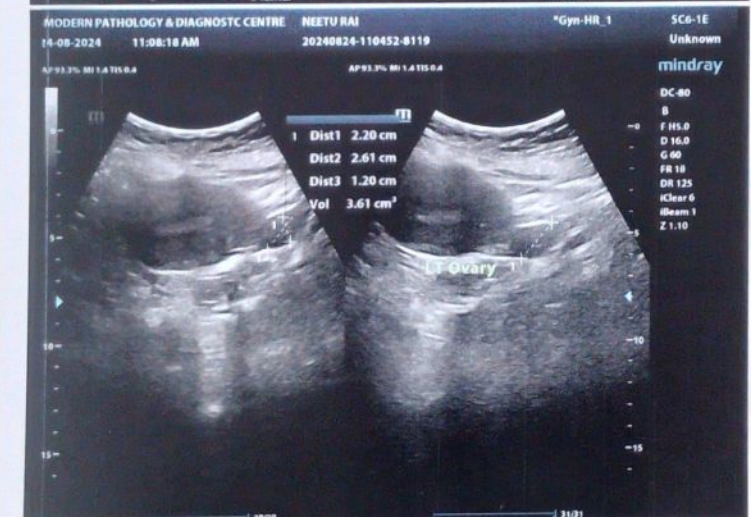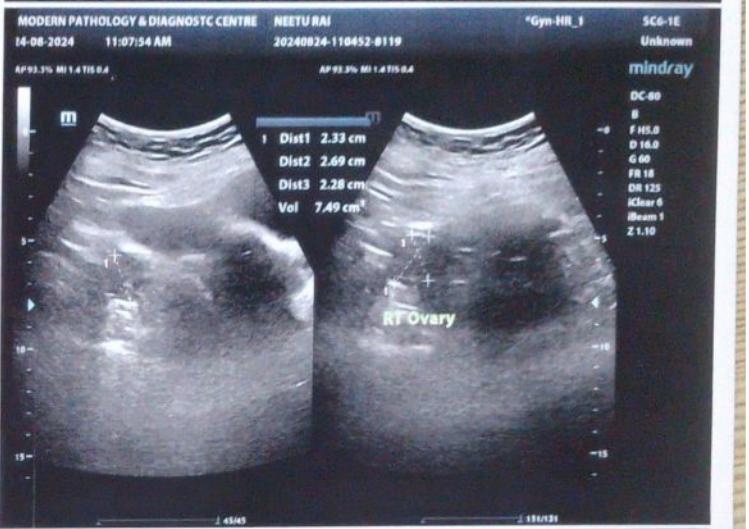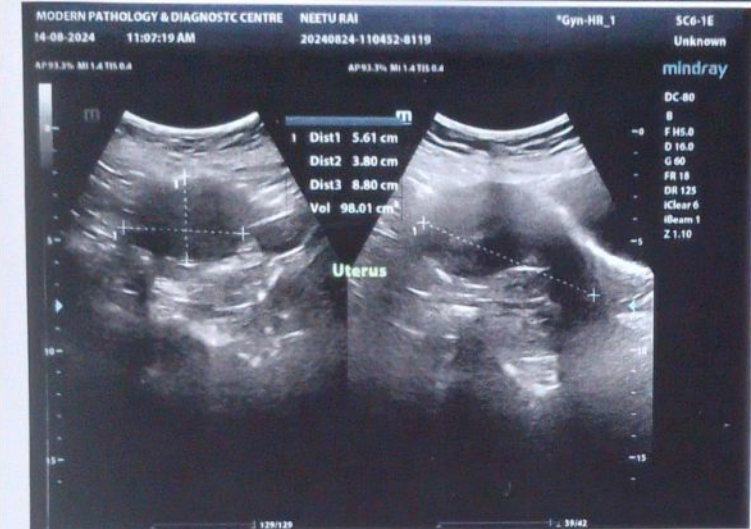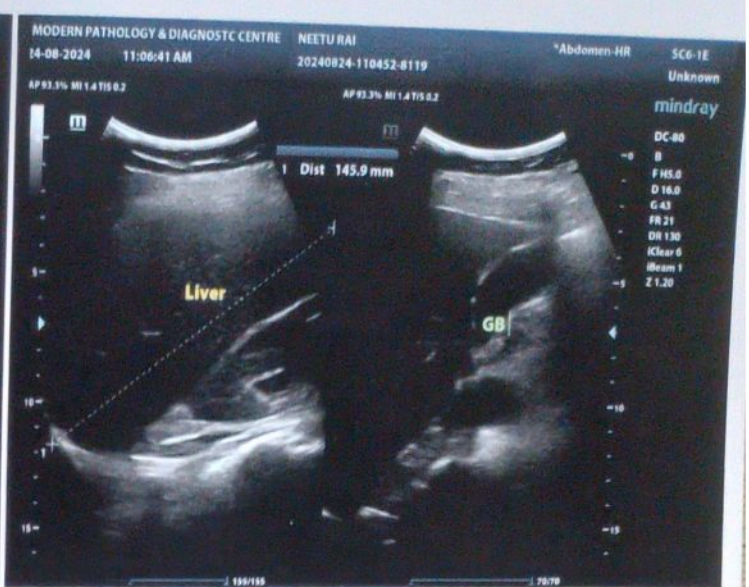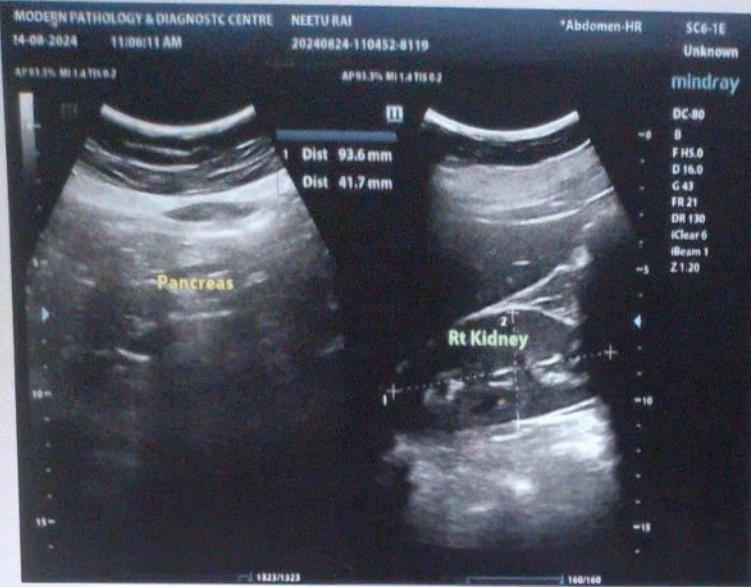Checked By: SURBHI

e-mail : mpdcgn@gmail.com ♦ For online reports - www.modernpath.in

Page 2 of 2

♦ Please ask for your computerized bill ♦ Pay only the printed collection charges

MODERN PATHOLOGY & DIAGNOSTIC CENTRE





MODERN PATHOLOGY & DIAGNOSTIC CENTRE

Dr. R. P. Rastogi
M.B.B.S., M.D. (Path & Bact)



CLINIC :

1/4A, Vineet Khand, (Opp Jaipuria Management)
Gomti Nagar, Lucknow - 226 010
Ph.: 0522-4008184, 4308184 • 8112323230
Mob : 7618884441, 9450389932, 8177063877



TEST REQUEST ID :012408240026	SAMPLE DATE	:24/Aug/2024 09:31AM
NAME :Mrs. NEETU RAI	SAMPLE REC. DATE	:24/Aug/2024 09:31AM
AGE/SEX :42 YRS/FEMALE	REPORTED DATE	:24/Aug/2024 11:16AM
REFERRED BY : Apollo Health and Lifestyle Limited,	BARCODE NO	:01240026

USG B/L SONOMEMOGRAPHY

- Bilateral breasts in all quadrants are normal in echotexture, no obvious focal / diffuse mass lesion seen. No architectural distortion is seen.
- Bilateral breasts are relatively normal in size.
- No evidence of any obvious focal / diffuse ductal dilatation is seen.
- Subareolar regions are normal grossly.
- Axilla and axillary tails are normal.
- No evidence of any obvious loco-regional axillary lymphadenopathy seen.

OPINION:

NO SIGNIFICANT ABNORMALITY DETECTED.

Please correlate clinically.

*** End Of Report ***



Dr. Sanjay Rastogi
M.B.B.S., DCP, CRIAT (BARC)

Surbhi
Dr. Surbhi
MBBS, MD (Radiodiagnosis)

Dr. Smita Rastogi
M.B.B.S., DCP

Results, adhering to W.H.O. and International Federation of Clinical Chemists Quality Control Standards.

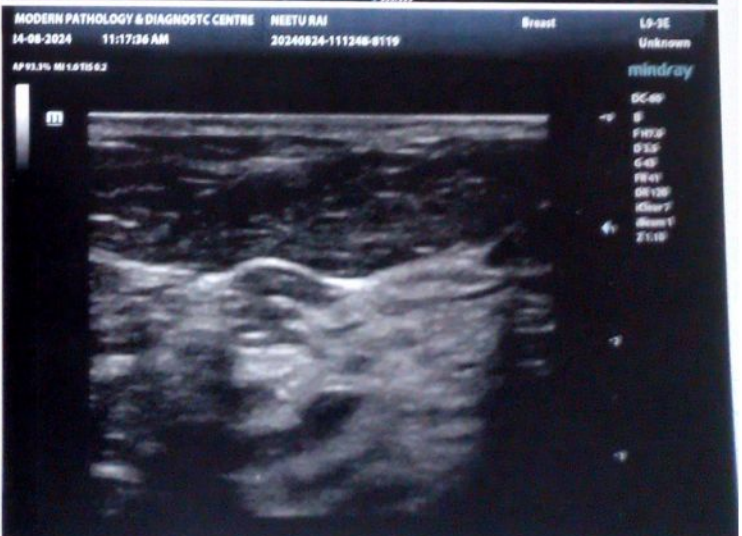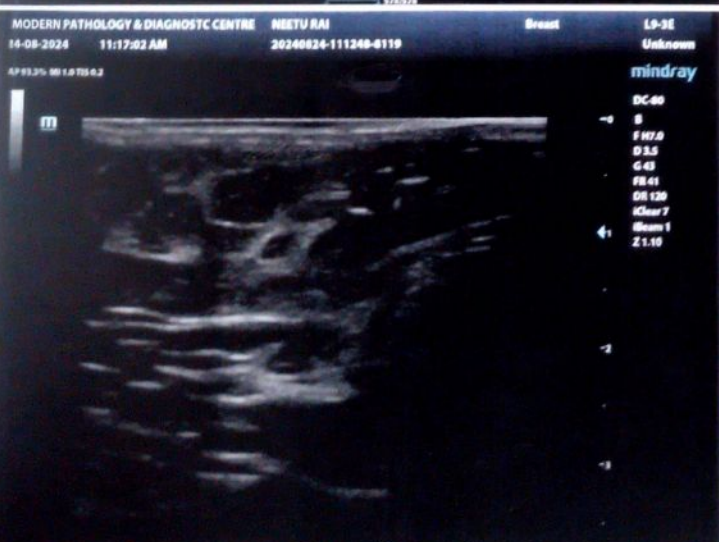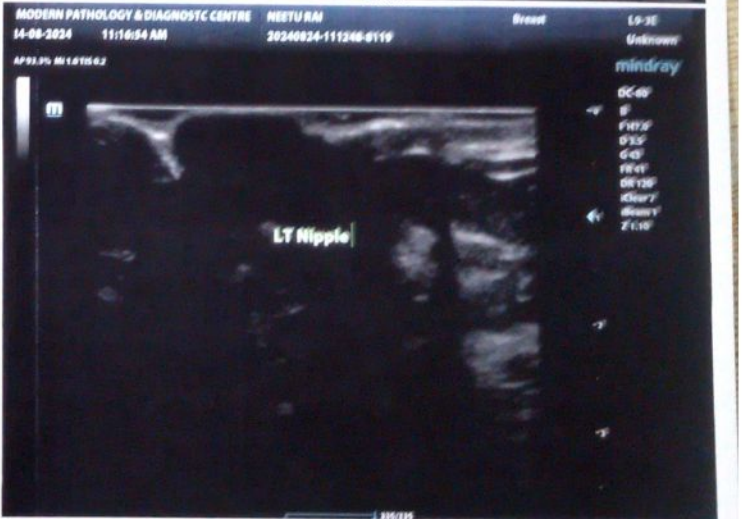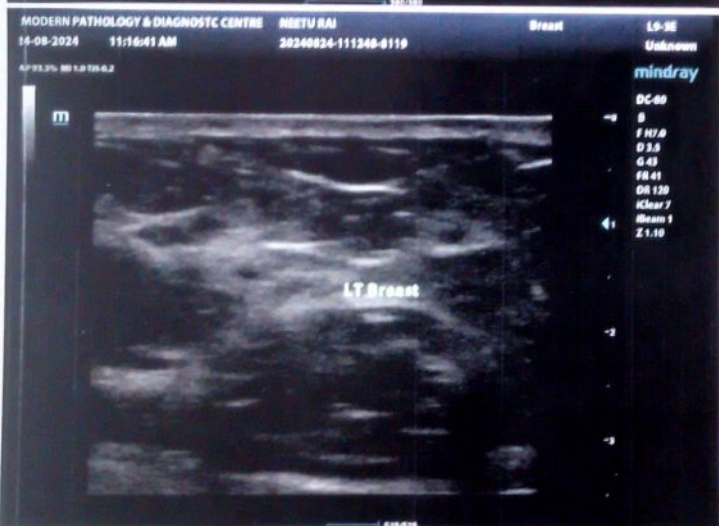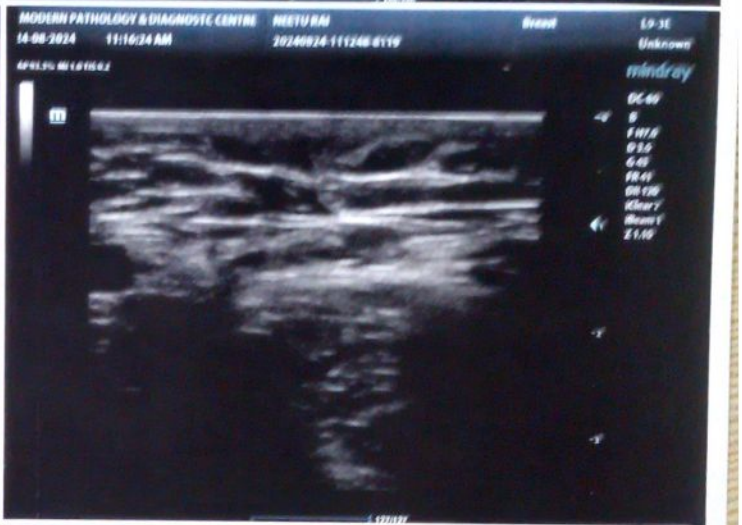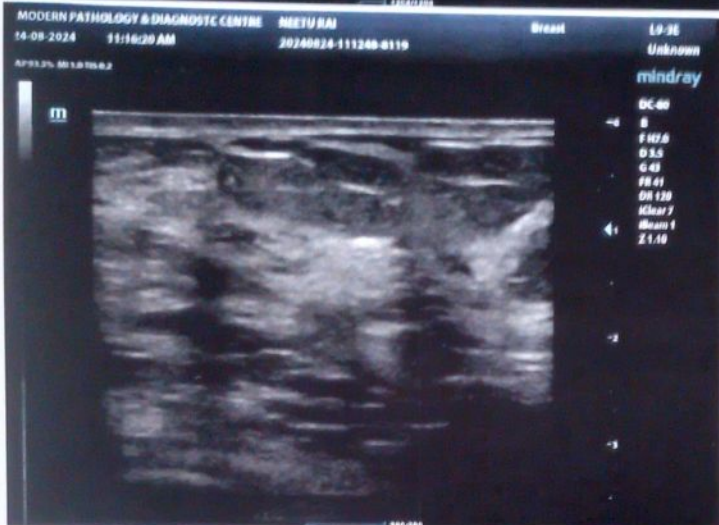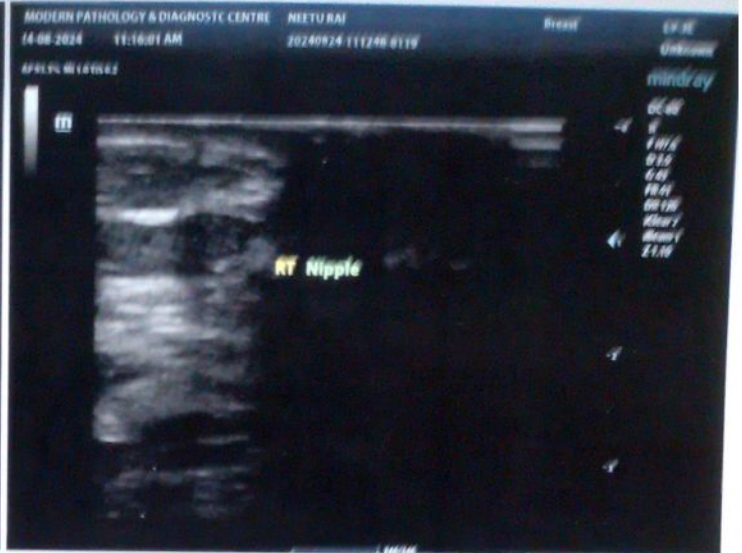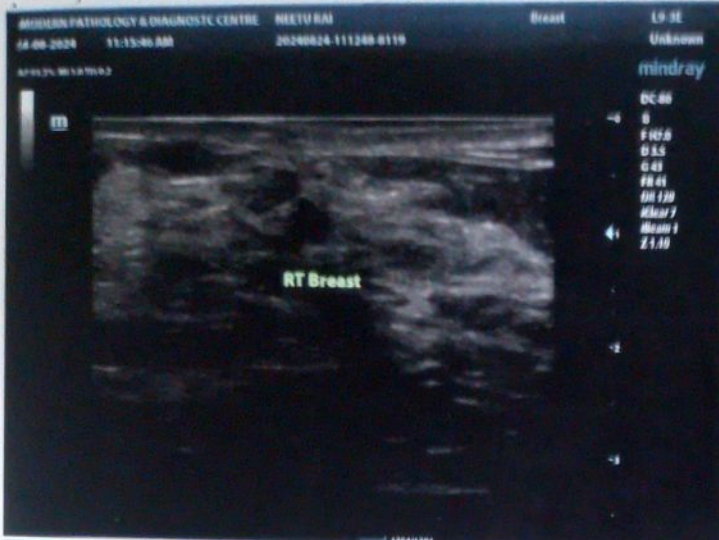SAMPLE COLLECTION FACILITY AVAILABLE

Report needs clinicopathological correlation ♦ Not for Medico Legal Purpose

e-mail : mpdcgn@gmail.com ♦ For online reports - www.modernpath.in

♦ Please ask for your computerized bill ♦ Pay only the printed collection charges

MODERN PATHOLOGY & DIAGNOSTIC CENTRE



MODERN PATHOLOGY AND DIAGNOSTIC CENTER

Gomti Nagar Lucknow

Report



NEETU RAI / 42 Yrs / F / 166 Cms / 77 Kg
 Date: 24 - 08 - 2024 Refd By : APOLLO HEALTH Examined By:

Stage	Time	Duration	Speed(Kmph)	Elevation	METs	Rate	% THR	BP	RPP	PVC	Comments
Supine	00:06	0:06	00.0	00.0	01.0	083	47 %	124/76	102	00	
Standing	00:11	0:05	00.0	00.0	01.0	081	46 %	124/76	100	00	
HV	00:17	0:06	00.0	00.0	01.0	081	46 %	124/76	100	00	
ExStart	00:21	0:04	00.0	00.0	01.0	081	46 %	124/76	100	00	
BRUCE Stage 1	03:21	3:00	02.7	10.0	04.7	133	75 %	140/86	186	00	
PeakEx	05:03	1:42	04.0	12.0	06.1	149	84 %	144/88	214	00	
Recovery	06:03	1:00	00.0	00.0	01.0	112	63 %	142/86	159	00	
Recovery	07:03	2:00	00.0	00.0	01.0	113	63 %	138/82	155	00	
Recovery	08:03	3:00	00.0	00.0	01.0	082	46 %	130/80	106	00	
Recovery	08:28	3:25	00.0	00.0	01.0	089	50 %	130/80	115	00	

FINDINGS :

- Exercise Time : 04:42
- Max HR Attained : 149 bpm 84% of Target 178
- Max BP Attained : 144/88 (mm/Hg)
- Max WorkLoad Attained : 6.1 Fair response to induced stress
- Test End Reasons : Fatigue

REPORT :

1. STRESS TEST IS NON CONCLUSIVE. TEST IS STOPPED BY CLIENT , NOT IN POSITION TO PERFORM FURTHER.

(Signature)
 Dr. ANTONIAN
 MD
 Reg. No. 44559

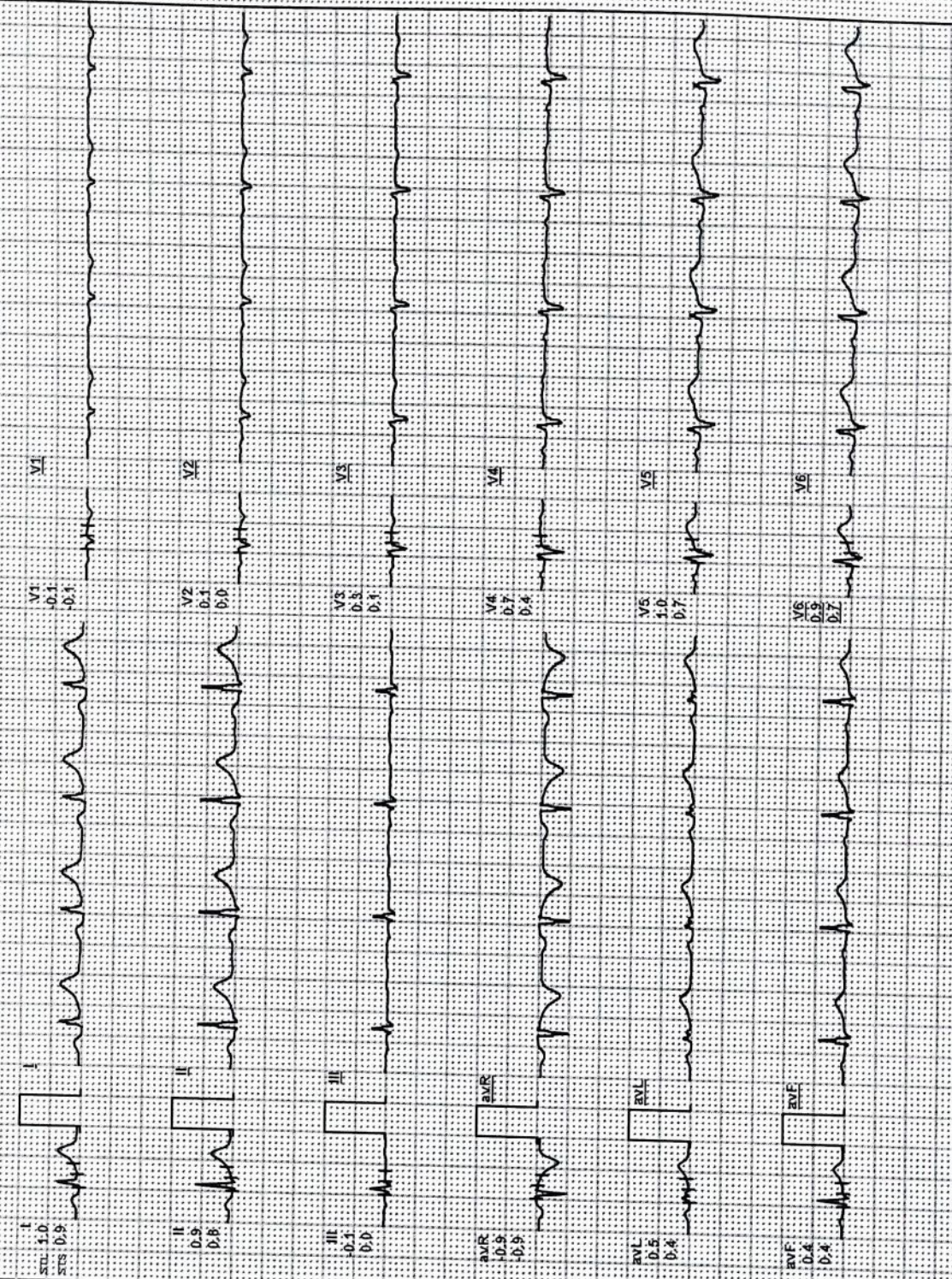
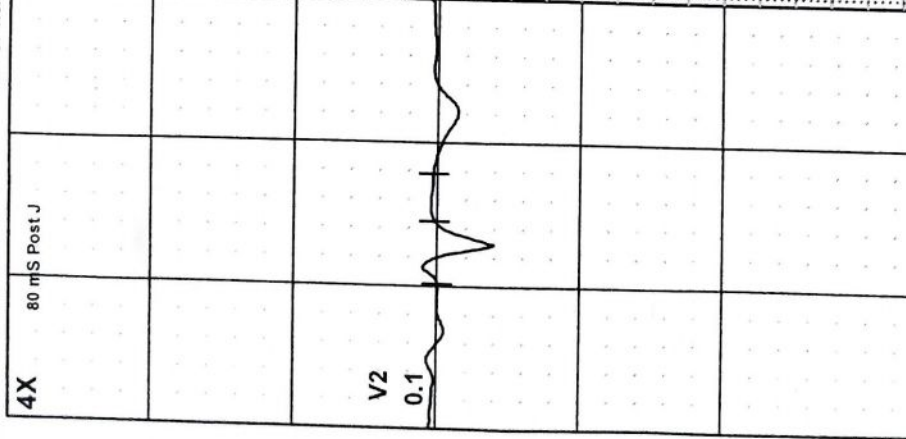


Date: 24 - 08 - 2024

METS: 1.0/ 83 bpm 47% of THR BP: 124/76 mmHg Combined Medians/ BLC On/ Notch On/ HF 0.05 Hz/LF 35 Hz

ExTime: 00:00 0.0 Kmph, 0.0%

25 mm/Sec. 1.0 Cm/mV



I	II	III	avR	avL	avF	V1	V2	V3	V4	V5	V6

REMARKS:

MODERN PATHOLOGY AND DIAGNOSTIC CENTER

NEETU RAI / 42 Yrs / F / 166 Cms / 77 Kg / HR : 81

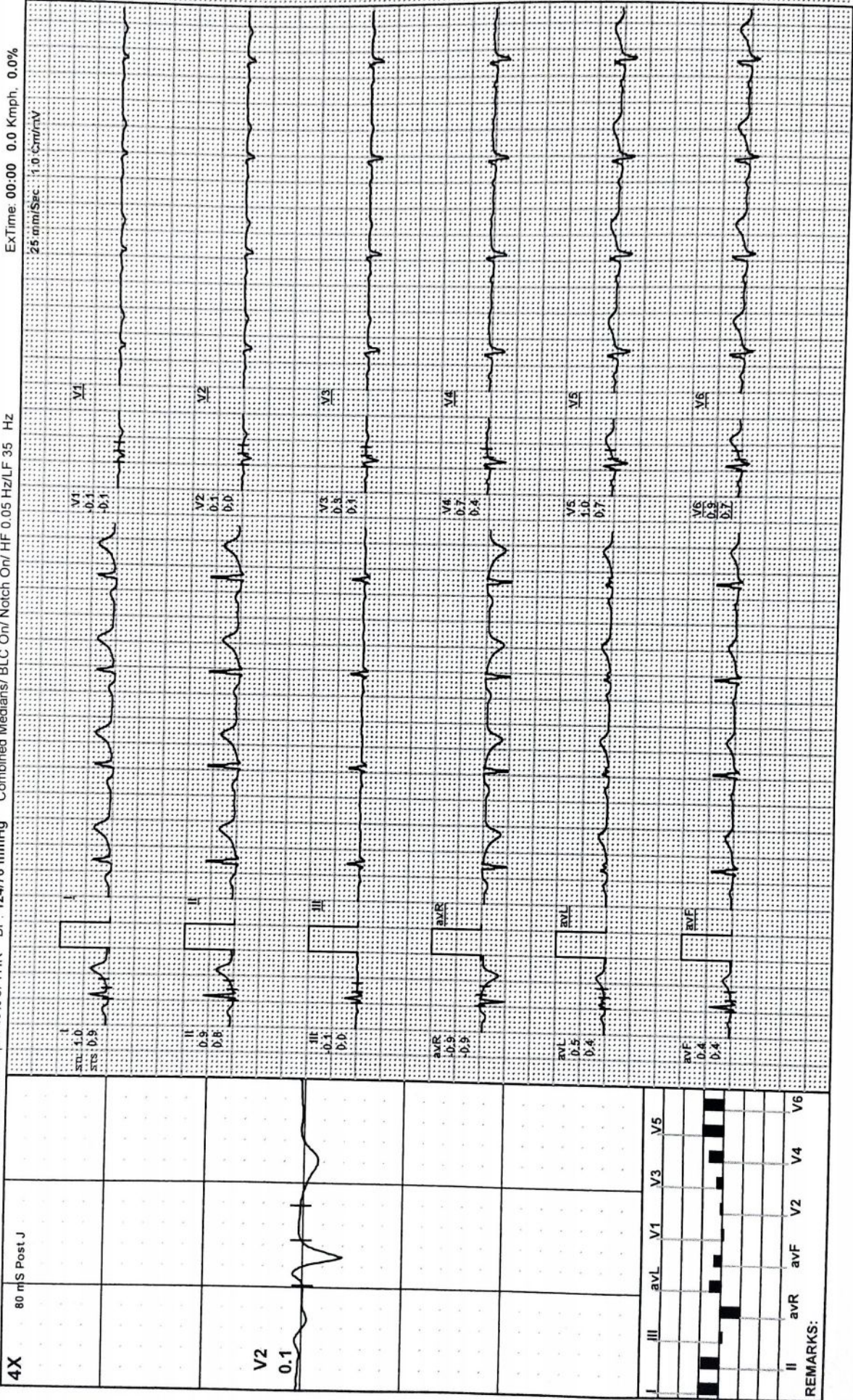
BRUCE: Standing(0:06)



Date: 24 - 08 - 2024

METS: 1.0/ 81 bpm 46% of THR BP: 124/76 mmHg Combined Medians/ BLC On/ HF 0.05 Hz/LF 35 Hz

ExTime: 00:00 0.0 KmPh, 0.0%



4X 80 mS Post J

V2 0.1

	I	II	III	aVR	aVL	aVF	V1	V2	V3	V4	V5	V6
ST-T	1.0	0.3	0.1	0.5	0.5	0.4	0.1	0.1	0.3	0.3	1.0	0.5
ST-S	0.5	0.5	0.0	0.5	0.5	0.4	0.1	0.1	0.3	0.3	1.0	0.5
ST-T	0.5	0.5	0.0	0.5	0.5	0.4	0.1	0.1	0.3	0.3	1.0	0.5

REMARKS:

MODERN PATHOLOGY AND DIAGNOSTIC CENTER

NEETU RAI / 42 Yrs / F / 166 Cms / 77 Kg / HR : 81

BRUCE:HV(0:06)

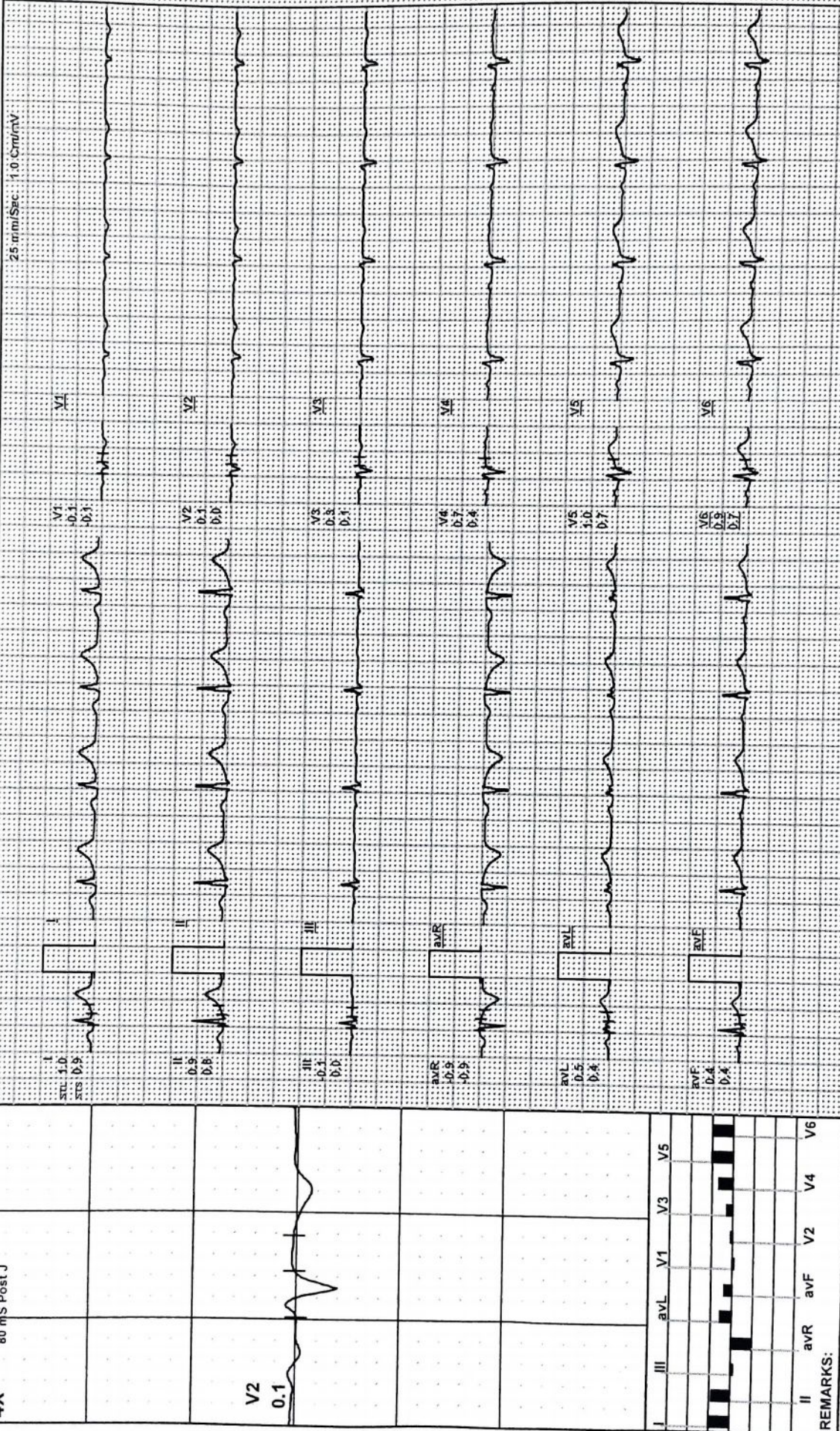


Date: 24 - 08 - 2024

METS: 1.0/ 81 bpm 46% of THR BP: 124/76 mmHg

Combined Medians/ BLC On/ HF 0.05 Hz/LF 35 Hz

ExTime: 00:00 0.0 KmPh, 0.0%



MODERN PATHOLOGY AND DIAGNOSTIC CENTER

NEETURAI / 42 Yrs / F / 166 Cms / 77 Kg / HR : 81

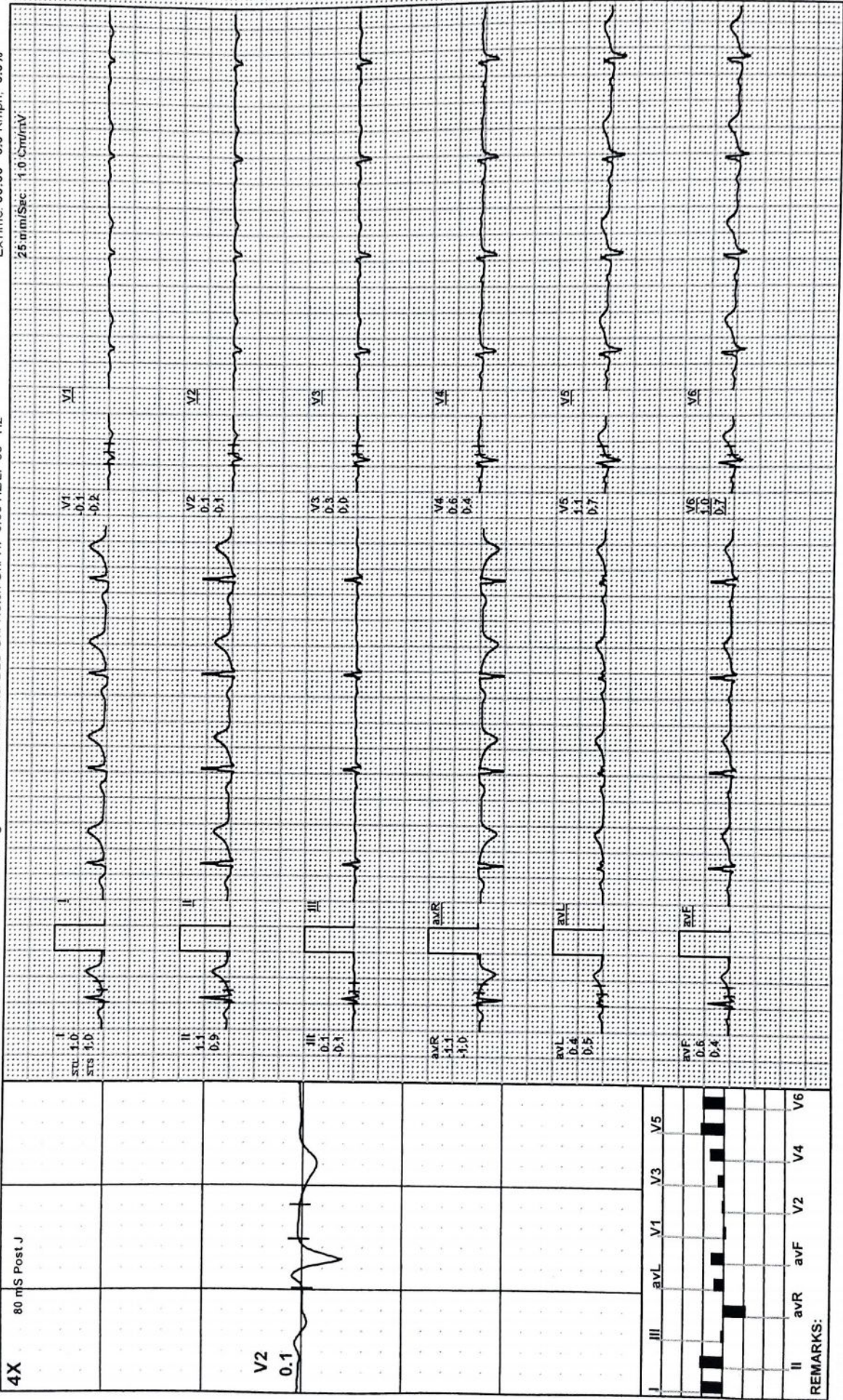
ExStart



Date: 24 - 08 - 2024

METS: 1.0/ 81 bpm 46% of THR BP: 124/76 mmHg Combined Medians/ BLC On/ HF 0.05 Hz/LF 35 Hz

ExTime: 00:00 0.0 Kmph, 0.0%





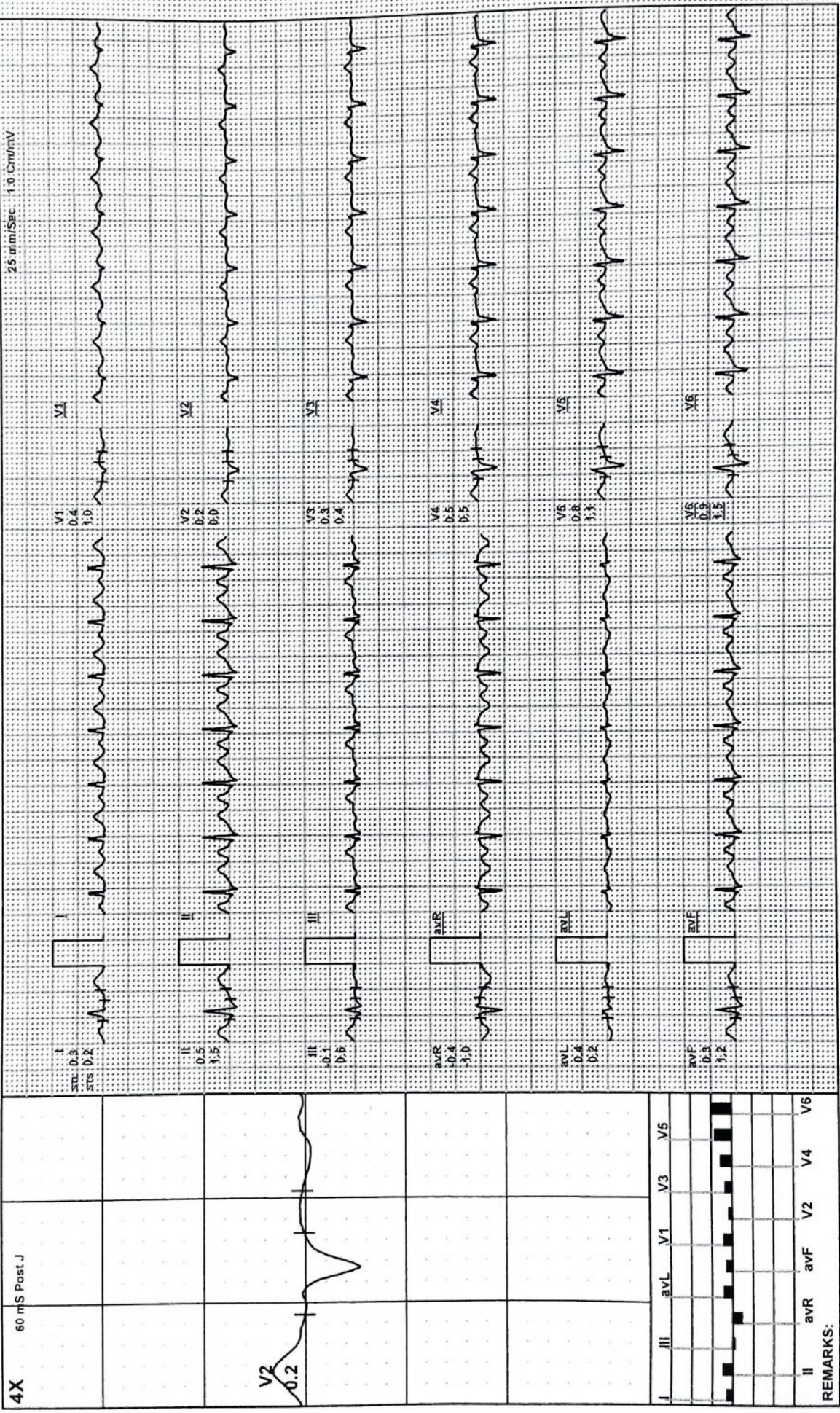
BRUCE: Stage 1 (3:00)

MODERN PATHOLOGY AND DIAGNOSTIC CENTER

NEETU RAI / 42 Yrs / F / 166 Cms / 77 Kg / HR : 133

Date: 24 - 08 - 2024 METS: 4.7/133 bpm 75% of THR BP: 140/86 mmHg Combined Medians/ BLC On/ Notch On/ HF 0.05 Hz/LF 35 Hz ExtTime: 03:00 2.7 Kmph, 10.0%

25 mm/Sec 1.0 Cm/mV



REMARKS:




Recovery(1:00)

MODERN PATHOLOGY AND DIAGNOSTIC CENTER

NEETU RAI / 42 Yrs / F / 166 Cms / 77 Kg / HR : 112

Date: 24 - 08 - 2024 METS: 1.0/ 112 bpm 63% of THR BP: 142/86 mmHg Combined Medians/BLC On/ Notch On/ HF 0.05 Hz/LF 35 Hz ExTime 04:42 0.0 Kmph, 0.0%



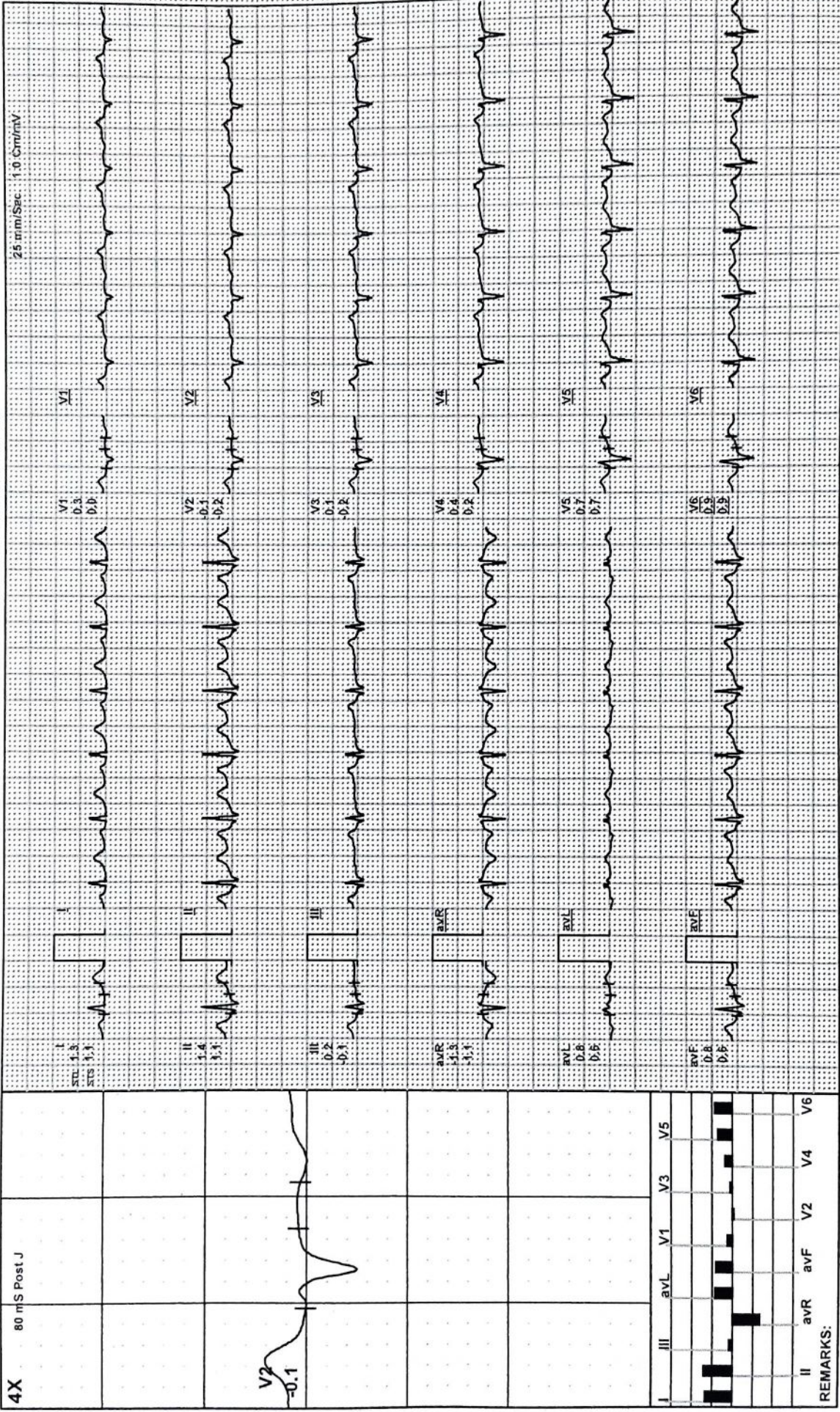
MODERN PATHOLOGY AND DIAGNOSTIC CENTER

NEETU RAI / 42 Yrs / F / 166 Cms / 77 Kg / HR : 113

Recovery(2:00)



Date: 24 - 08 - 2024 METS: 1.0/ 113 bpm 63% of THR BP: 138/82 mmHg Combined Medians/ BLC On/ Notch On/ HF 0.05 Hz/LF 35 Hz ExTime: 04:42 0.0 Kmph 0.0%



REMARKS:

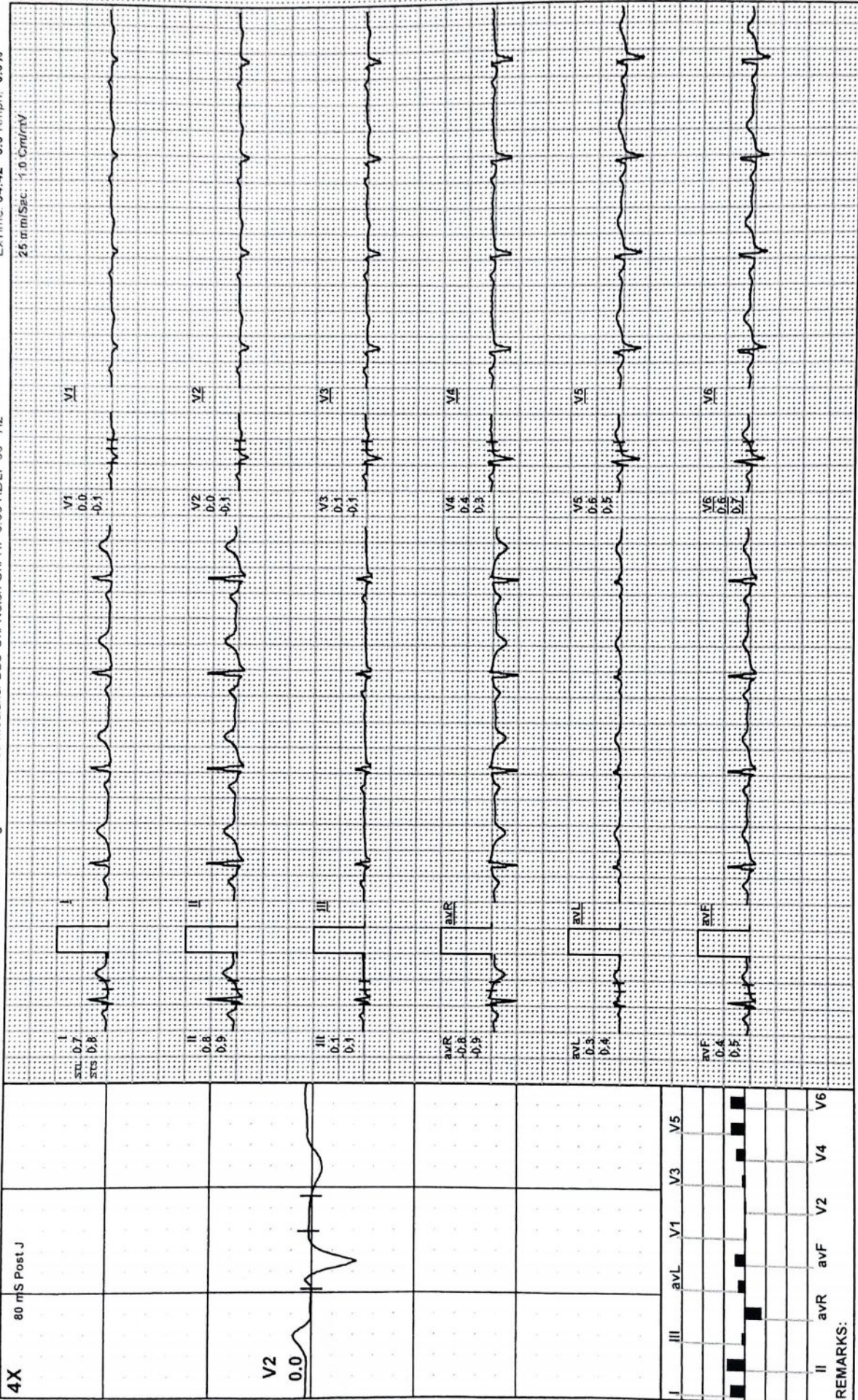
MODERN PATHOLOGY AND DIAGNOSTIC CENTER


NEETU RAI / 42 Yrs / F / 166 Cms / 77 Kg / HR : 82

Recovery(3:00)



Date: 24 - 08 - 2024 METS: 1.0/ 82 bpm 46% of THR BP: 130/80 mmHg Combined Medians/ BLC On/ HF 0.05 Hz/LF 35 Hz ExTime: 04:42 0.0 Km/ph. 0.0%

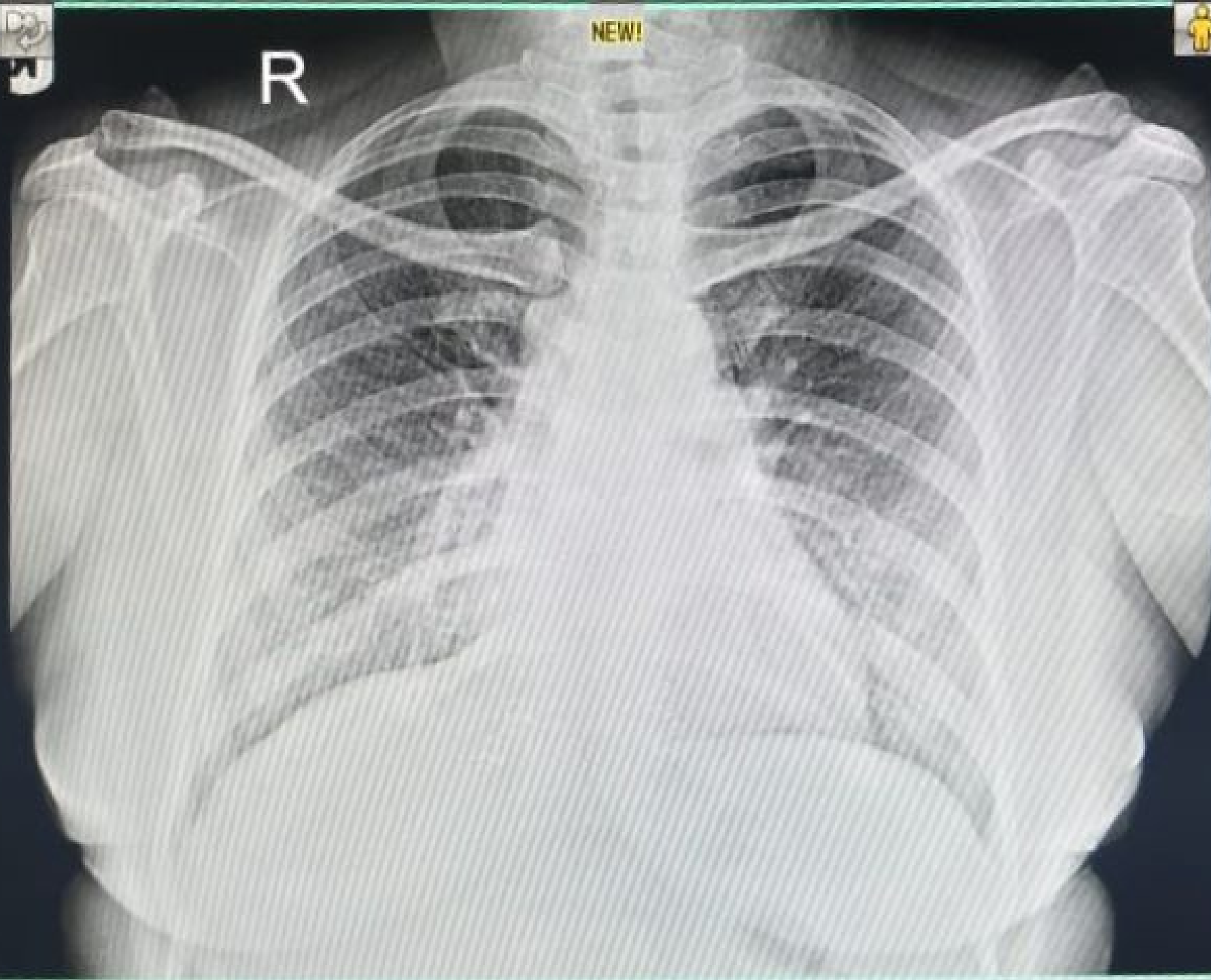




NEW!



R



24082405626 MRS NEETU RAI 42YRS F SELF CHEST PA
08/24/2024 MODERN PATHOLOGY & DIAGNOSTIC CENTRE GOMTI NAGAR LUCKNOW