



Shree Ram Multispeciality Hospital (SRMH)

L o k a h S a m a s t a S u k h i n o B h a v a n t u

OPD - ID : 02024 - 2025-0000001
UH-ID : SRMH-2408879

PT. TYPE : FREE OPD
PRINT DATE : 24-08-2024 / 09:41:47PM



6873038

PATIENT NAME	: MRS. MOLIKA MARTINA JOSEPH	OPD-DATE	: 24-Aug-2024 - 09:41 PM
AGE / SEX	: 29-Y 1-M 19-D / FEMALE	DEPARTMENT	: GENERAL MEDICINE
DOB	: 06-07-1995	CONSULTANT	: DR. AJIT KUMAR
MOB-NO	: 9644489249	COMPANY NAME	: MEDIWHEEL
GUARDIAN NAME	: W/o ONKAR SINGH	OPD PAID FEE	: 0.00
ADDRESS	: B/97 VIKAS NAGAR KUSUMNDA KORBA, RAIPUR, C.G.		

Weight : 70.5 kg Height : Temp : 98.6 °F B.P. : 119/74 Pulse : 77b/w SPO2 : 99%.

C/O - Short Cycle : 3-4 cycle

- Anxious for issue

- Planning Pregnancy LMP = 15/08/24

NCO PCOS. MH = $\frac{3-4}{25-30}$

Hypothyroid on MECTIN 375mcg
: 2yr

Bilateral tonsils size
IA → size No abscess

- TUS to rule
out PCOS.
→ to see follicle

Adv Dairy & Exercise

- Tas Folinepr Gold 100
x 30d

- K4 Jelly. for IA.

Amir

Ⓧ Near Railway Under Bridge, Basant Vihar Gate No. 1, Gondwara Chowk, Gudhiyari, Raipur (Chhattisgarh)

☎ 0771-43 43 161, 0771-43 40 162, 📞 8404 8404 79

✉ shreeramhospital.op@gmail.com 🌐 www.srmhraipur.com



24/08/24

CUS
24/08/24

→ - Grade I fatty Liver
Res. NAD.

Adv Timed Control

- Tab Dydrobion 10mg
TID x 15d.
○ — ○

Amix



Shree Ram Multispeciality Hospital (SRMH)

L o k a h S a m a s t a S u k h i n o B h a v a n t u

PT. NAME : MRS. MOLIKA MARTINA JOSEPH
MOBILE NO : 9644489249 TEST NO 616
DOCTOR : DR. AJIT KUMAR
REFERRED BY : SELF

AGE / SEX : 29Y 1M 19D/FEMALE
UH ID NO. : SRMH-2408879
COLLECTION : 24-08-2024
REPORTING : 24-Aug-2024

HAEMATOLOGY

TEST NAME	RESULT	UNIT	NORMAL VALUES
CBC (COMPLETE BLOOD COUNT)			
HAEMOGLOBIN (Hb)	12.1	gm%	12 - 16
TOTAL RBC COUNT	5.06	Million/cumm	4.5 - 5.1
HAEMATOCRIT (PCV)	36.4	%	35.9 - 44.6
RBC INDICES			
MCV	79.2	f l	78 - 96
MCH	28.3	pg	27 - 32
MCHC	32.5	%	33 - 37
RDW	15.1	%	11 - 16
TOTAL WBC COUNT (TLC)	8900	/cumm	4000 - 11000
DIFFERENTIAL COUNT			
NEUTROPHILS	62	%	40 - 70
LYMPHOCYTES	30	%	22 - 48
EOSINOPHILS	03	%	0 - 6
MONOCYTES	05	%	2 - 10
BASOPHILS	00	%	-
PLATELET COUNT	2.63	/cumm	1.50 - 4.50
PCT	0.21	%	0.10 - 0.28
MPV(MEAN PLATELET VOLUME)	9.2	µm ³	8 - 11
PDW	12.3	%	11 - 18

ESR (ERYTHROCYTE SEDIMENTATION RATE)

ESR 15 mm at end of 1 | 0 - 20

-- End Of Report --

LAB TECHNICIAN

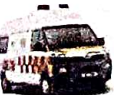Note : This Report is not for medicolegal purpose

Dr. Dhananjay Prasad
Dr. Dhananjay Prasad
MBBS, MD (Pathologist)

📍 Near Railway Under Bridge, Basant Vihar Gate No. 1, Gondwara Chowk,
Gudhiyari, Raipur (Chhattisgarh)

☎ 0771-43 43 161, 0771-43 40 162, 📞 8404 8404 79

✉ shreeramhospital.op@gmail.com 🌐 www.srmhraipur.com





Shree Ram Multispeciality Hospital (SRMH)

L o k a h S a m a s t a S u k h i n o B h a v a n t u

PT. NAME : MRS. MOLIKA MARTINA JOSEPH
MOBILE NO : 9644489249 TEST NO 616
DOCTOR : DR. AJIT KUMAR
REFERRED BY : SELF

AGE / SEX : 29Y 1M 19D/FEMALE
UH ID NO. : SRMH-2408879
COLLECTION : 24-08-2024
REPORTING : 24-Aug-2024

HAEMATOLOGY

TEST NAME

RESULT

UNIT

NORMAL VALUES

BLOOD GROUPING AND RH TYPING

BLOOD GROUP

"O"

-

RH FACTOR


POSITIVE

-

-- End Of Report --

LAB TECHNICIAN

Note : This Report is not for medicolegal purpose


Dr. Dhananjay Prasad
MBBS, MD (Pathologist)

📍 Near Railway Under Bridge, Basant Vihar Gate No. 1, Gondwara Chowk,
Gudhiyari, Raipur (Chhattisgarh)

☎ 0771-43 43 161, 0771-43 40 162, 📞 8404 8404 79

✉ shreeramhospital.op@gmail.com 🌐 www.srmhraipur.com

24/7
Emergency
Services





Shree Ram Multispeciality Hospital (SRMH)

Lokah Samasta Sukhino Bhavantu

PT NAME : MRS. MOLIKA MARTINA JOSEPH
MOBILE NO : 9644489249 TEST NO : 616
DOCTOR : DR AJIT KUMAR
REFERRED BY : SELF

AGE / SEX : 29Y 1M 19D/FEMALE
UH ID NO : SRMH-2408879
COLLECTION : 24-08-2024
REPORTING : 24-Aug-2024

BIOCHEMISTRY

TEST NAME	RESULT	UNIT	NORMAL VALUES
CREATININE			
CREATININE	0.84	mg / dl	0.6 - 1.2
URIC ACID			
URIC ACID	4.91	mg/dL	2.5 - 6.8

-- End Of Report --

LAB TECHNICIAN

Note : This Report is not for medicolegal purpose

Dr. Dhananjay Prasad
MBBS, MD (Pathologist)

Near Railway Under Bridge, Basant Vihar Gate No. 1, Gondwara Chowk,
Gudhiyari, Raipur (Chhattisgarh)

☎ 0771-43 43 161, 0771-43 40 162, 📞 8404 8404 79

✉ shreeramhospital.op@gmail.com 🌐 www.srmhraipur.com

24/7
Emergency
Service





Shree Ram Multispeciality Hospital (SRMH)

L o k a h S a m a s t a S u k h i n o B h a v a n t u

PT. NAME : MRS. MOLIKA MARTINA JOSEPH
MOBILE NO : 9644489249 TEST NO 616
DOCTOR : DR. AJIT KUMAR
REFERED BY : SELF

AGE / SEX : 29Y 1M 19D/FEMALE
UH ID NO. : SRMH-2408879
COLLECTION : 24-08-2024
REPORTING : 24-Aug-2024

BIOCHEMISTRY

TEST NAME	RESULT	UNIT	NORMAL VALUES
LIVER FUNCTION TEST (LFT)			
BILIRUBIN TOTAL	0.49	mg/dL	0.2 - 1
BILIRUBIN DIRECT	0.24	mg / dl	0.1 - 0.6
BILIRUBIN INDIRECT	0.25	mg / dl	0.1 - 0.4
SGOT	29.5	U / L	0 - 46
SGPT	26.4	U / L	0 - 40
ALKALINE PHOSPHATASE	198.3	U / L	0 - 240
TOTAL PROTEIN	6.34	g / dl	6 - 8
ALBUMIN	3.69	g/dl	3.5 - 5.0
GLOBULIN	2.65	g / dl	2 - 3.5
A/G RATIO	1.39		1 - 2.5

Clinical Significance

Alanine transaminase (ALT)
ALT is an enzyme found in the liver that helps your body metabolize protein. When the liver is damaged, ALT is released into the bloodstream and levels increase.

Aspartate transaminase (AST)
AST is an enzyme that helps metabolize alanine, an amino acid. Like ALT, AST is normally present in blood at low levels. A increase in AST levels may indicate liver damage or disease or muscle damage.

Alkaline phosphatase (ALP)
ALP is an enzyme in the liver, bile ducts and bone. Higher-than-normal levels of ALP may indicate liver damage or disease, such as a blocked bile duct, or certain bone diseases.

Albumin and total protein
Albumin is one of several proteins made in the liver. Your body needs these proteins to fight infections and to perform other functions. Lower-than-normal levels of albumin and total protein might indicate liver damage or disease.

Bilirubin
Bilirubin is a substance produced during the normal breakdown of red blood cells. Bilirubin passes through the liver and is excreted in stool. Elevated levels of bilirubin (jaundice) might indicate liver damage or disease or certain types of anemia.

-- End Of Report --

LAB TECHNICIAN

Note : This Report is not for medicolegal purpose

Dr. Dhananjay Prasad
MBBS, MD (Pathologist)

📍 Near Railway Under Bridge, Basant Vihar Gate No. 1, Gondwara Chowk, Gudhiyari, Raipur (Chhattisgarh)

☎ 0771-43 43 161, 0771-43 40 162, 📞 8404 8404 79

✉ shreeramhospital.op@gmail.com 🌐 www.srmhraipur.com





Shree Ram Multispeciality Hospital (SRMH)

Lokah Samasta Sukhino Bhavantu

PT. NAME : MRS. MOLIKA MARTINA JOSEPH
MOBILE NO : 9644489249 TEST NO 616
DOCTOR : DR. AJIT KUMAR
REFERRED BY : SELF

AGE / SEX : 29Y 1M 19D/FEMALE
UH ID NO : SRMH-2408879
COLLECTION : 24-08-2024
REPORTING : 24-Aug-2024


BIOCHEMISTRY

TEST NAME	RESULT	UNIT	NORMAL VALUES
LIPID PROFILE			
CHOLESTEROL	199.5	mg / dl	150 - 220
SERUM TRYGLYCERIDE	101.6	mg / dl	60 - 165
HDL	35.8	mg / dl	35 - 80
LDL	163.7	mg/dL	90 - 160
VLDL	20.32	mg/dL	20 - 50
CHOLESTEROL / HDL RATIO	5.57	mg/dL	3.5 - 5.5
LDL/HDL Ratio	4.57	mg / dl	2.5 - 3.5
TRIGLYCERIDES / HDL RATIO	2.83	mg / dl	2.0 - 4.0

-- End Of Report --

LAB TECHNICIAN

Note : This Report is not for medicolegal purpose


Dr. Dhananjay Prasad
MBBS, MD (Pathologist)

Near Railway Under Bridge, Basant Vihar Gate No. 1, Gondwara Chowk,
Gudhiyari, Raipur (Chhattisgarh)

☎ 0771-43 43 161, 0771-43 40 162, 📞 8404 8404 79
✉ shreeramhospital.op@gmail.com 🌐 www.srmhraipur.com





Shree Ram Multispeciality Hospital (SRMH)

L o k a h S a m a s t a S u k h i n o B h a v a n t u

PT. NAME : MRS. MOLIKA MARTINA JOSEPH
MOBILE NO : 9644489249 TEST NO 616
DOCTOR : DR. AJIT KUMAR
REFERRED BY : SELF

AGE / SEX : 29Y 1M 19D/FEMALE
UH ID NO. : SRMH-2408879
COLLECTION : 24-08-2024
REPORTING : 24-Aug-2024

BIOCHEMISTRY

TEST NAME	RESULT	UNIT	NORMAL VALUES
BLOOD SUGAR - FASTING AND PP			
BLOOD SUGAR FASTING	103.4	mg/dL	70 - 120
BLOOD SUGAR PP	128.5	mg/dL	80 - 140


CLINICAL PATHOLOGY

TEST NAME	RESULT	UNIT	NORMAL VALUES
URINE SUGAR FASTING AND PP			
URINE SUGAR FASTING	Absent		Absent -
URINE SUGAR PP	Absent		Absent -

-- End Of Report --

LAB TECHNICIAN

Note : This Report is not for medicolegal purpose


Dr. Dhananjay Prasad
MBBS, MD (Pathologist)

📍 Near Railway Under Bridge, Basant Vihar Gate No. 1, Gondwara Chowk,
Gudhiyari, Raipur (Chhattisgarh)

☎ 0771-43 43 161, 0771-43 40 162, 📞 8404 8404 79

✉ shreeramhospital.op@gmail.com 🌐 www.srmhraipur.com





Shree Ram Multispeciality Hospital (SRMH)

L o k a h S a m a s t a S u k h i n o B h a v a n t u

PT. NAME : MRS. MOLIKA MARTINA JOSEPH
MOBILE NO : 9644489249 TEST NO 616
DOCTOR : DR. AJIT KUMAR
REFERRED BY : SELF

AGE / SEX : 29Y 1M 19D/FEMALE
UH ID NO. : SRMH-2408879
COLLECTION : 24-08-2024
REPORTING : 24-Aug-2024

BIOCHEMISTRY

TEST NAME	RESULT	UNIT	NORMAL VALUES
HbA1c -Glycosylated hemoglobin			
HbA1c -Glycosylated hemoglobin	4.56	%	Normal Range : <6% Good Control : 6-7% fair Control : 7-8% Unsatisfactory Control : 8-10% Poor Control : >10% - 80 - 120
Estimated average plasma glucose	85.03	mg/dl	

– End Of Report –

LAB TECHNICIAN

Note : This Report is not for medicolegal purpose

Dr. Dhananjay Prasad
MBBS, MD (Pathologist)

📍 Near Railway Under Bridge, Basant Vihar Gate No. 1, Gondwara Chowk,
Gudhiyari, Raipur (Chhattisgarh)

☎ 0771-43 43 161, 0771-43 40 162, 📞 8404 8404 79

✉ shreeramhospital.op@gmail.com 🌐 www.srmhraipur.com





Mrs. **MOLIKA MARTINA JOSEPH** Sample Collected At :

Registered : 24 Aug,24 12:48PM

Age: 29 Years

Ref By : **Dr.AJIT KUMAR**

Collected : 24 Aug,24 12.:42PM

Sex:-Female

UH ID NO. – SRMH -2408879

Reported : 25 Aug,24 01:15PM

GAMAMA GLUTAMYL TRANSFERASE (GGT)

INVESTIGATION	RESULT	REFERENCE VALUE	UNIT
GAMMA – GLUTAMYL TRANSFERASE (GGT) , SERUM	14.9	12.00-18.00	U/L

GENDER	-	NORMAL RANGE(U/L)
MALE	-	12.00-18.00
FEMALE	-	6.00-29.00

COMMENTS:-

Gamma – Glutamyl Transferase (Ggt) Is An Enzyme That Is Found In Many Organs Throughtout The Body , With The Highest Concentrations Found In The Liver .Ggt Is Elevated In The Blood In Most Diseases That Cause Damage To The Liver Or Bile Ducts ,This Test Measures The Lavel Of Ggt In A Blood Samle.

DR. DHANANJAY PRASAD

(MD Pathology)

📍 Near Railway Under Bridge, Basant Vihar Gate No. 1, Gondwara Chowk, Gudhiyari, Raipur (Chhattisgarh)

☎ 0771-43 43 161, 0771-43 40 162, 📞 8404 8404 79

✉ shreeramhospital.op@gmail.com 🌐 www.srmhraipur.com





Shree Ram Multispeciality Hospital (SRMH)

Lokah Samasta Sukhino Bhavantu

Mrs MOLIKA MARTINA JOSEPH
Age: 29 Years Sex: Female

Sample Collected At:
Ref. By: **Dr. AJIT KUMAR (MD)**
UH ID NO. – SRMH - 2408879

Registered: 24 Aug, 24 01:20 PM
Collected: 24 Aug, 24 01:15 PM
Reported: 24 Aug, 24 05:55 PM

BUN / Creatinine Ratio PANAL

Investigation	Observed Value	Unit	Biological Reference Interval
BUN			
BUN	15.1	mg/dL	7.00 - 20.00
Serum Creatinine	0.84	mg/dL	0.55 - 1.20
BUN / Creatinine Ratio	17.97		10:1 - 20:1

Blood urea nitrogen (BUN) is a waste product produced when the liver breaks down protein. The kidneys then filter it out of the blood and eliminate it through urine. Creatinine is a waste product created by the breakdown of phosphocreatine, a molecule stored in muscle tissue. The kidneys filter creatinine from the blood, and its levels in the body reflect the efficiency of the kidney's excretory function. therefore, BUN and creatinine are useful markers in assessing kidney health because they help doctors evaluate the kidney's filtration rate.

Dr. D. Prasad
M.D. (Pathologist)

● Near Railway Under Bridge, Basant Vihar Gate No. 1, Gondwara Chowk, Gudhiyari, Raipur (Chhattisgarh)

☎ 0771-43 43 161, 0771-43 40 162, 📞 8404 8404 79

✉ shreeramhospital.op@gmail.com 🌐 www.srmhraipur.com





Shree Ram Multispeciality Hospital (SRMH)

L o k a h S a m a s t a S u k h i n o B h a v a n t u

Mrs MOLIKA MARTINA JOSEPH
Age: 29 Years Sex: Female

Sample Collected At:
Ref. By: **Dr. AJIT KUMAR (MD)**
UH ID NO. - SRMH - 2408879

Registered: 24 Aug, 24 01:20 PM
Collected: 24 Aug, 24 01:15 PM
Reported: 24 Aug, 24 05:55 PM

TFT

Thyroid Function Test (TFT)

Investigation	Observed Value	Unit	Biological Reference Interval
THYROID SERUM HORMONS			
Serum Triiodothyronine (T3)	1.75	ng/mL	0.89 - 1.87
Serum thyroxine (T4)	13.36	ug/dL	5.1 - 14.28
Thyroid Stimulating Hormone (TSH)	3.21	µIU/mL	0.66 - 5.67

Comments:-

- (i) Ethnicity, iodine intake, gender, age, body mass index and Exercise influences the reference range of Thyroid hormones and serum TSH concentrations.
- (ii) Changes in Thyroid Hormones (especially T3) and TSH may be seen as early as 24 hours after the onset of non-thyroid illness. (Poor nutrition/starvation, sepsis, burns, malignancy, myocardial infarction, post-surgery, and with chronic liver and renal disease)
- (iii) Serum total T4 and T3 concentrations increase to approximately 150% of non-pregnant values – this occurs during the first half of pregnancy and is maintained thereafter until parturition. Free T4 concentrations also change during pregnancy; in the first trimester a transient rise is often observed.
- (iv) Measurement of FT4 and FT3 is best avoided in patients receiving heparin therapy. (When indicated, blood sample should be taken 10 hours after the last injection of heparin, and analyzing it without delay, can reduce the risk of artifactual hyperthyroxinaemia.)
- (v) Phenytoin, carbamazepine and furosemide cause artifactual increase in free T4 (FT4) and decrease in total T4.

Dr. D. Prasad
M.D. (Pathologist)

© Near Railway Under Bridge, Basant Vihar Gate No. 1, Gondwara Chowk, Raipur (Chhattisgarh)

© 0771-43 43 161, 0771-43 40 162, 8404 8404 79

© shreeramhospital.op@gmail.com © www.srmhraipur.com





Shree Ram Multispeciality Hospital (SRMH)

L o k a h S a m a s t a S u k h i n o B h a v a n t u

PT. NAME : MRS. MOLIKA MARTINA JOSEPH
MOBILE NO : 9644489249 TEST NO 616
DOCTOR : DR. AJIT KUMAR
REFERRED BY : SELF

AGE / SEX : 29Y 1M 19D/FEMALE
UH ID NO. : SRMH-2408879
COLLECTION : 24-08-2024
REPORTING : 24-Aug-2024

CLINICAL PATHOLOGY

TEST NAME	RESULT	UNIT	NORMAL VALUES
URINE ROUTINE AND MICROSCOPY			
PHYSICAL EXAMINATION			
QUANTITY	20	ml	-
COLOUR	Yellow		Pale Yellow -
APPEARANCE	Clear		Clear -
REACTION	Acitic		Acitic -
CHEMICAL EXAMINATION			
ALBUMIN	Absent		Absent -
SUGAR	Absent		Absent -
KETONE	Absent		Absent -
BILE SALT	Absent		Absent -
BILE PIGMENT	Absent		-
MICROSCOPIC EXAMINATION			
PUS CELLS	2-3	/hpf	2 - 5
EPITHELIAL CELLS	1-2	/hpf	1 - 5
RBC	Nil	/hpf	0 - 3
CAST	Nil	/lpf	Nil -
YEAST	Nil		Nil -
CRYSTAL	Nil	/lpf	Nil -
BACTERIA	Nil		Nil -
OTHERS	-		-

-- End Of Report --

LAB TECHNICIAN

Note : This Report is not for medicolegal purpose

Dr. Dhananjay Prasad
MBBS, MD (Pathologist)

📍 Near Railway Under Bridge, Basant Vihar Gate No. 1, Gondwara Chowk,
Gudhiyari, Raipur (Chhattisgarh)

☎ 0771-43 43 161, 0771-43 40 162, 📞 8404 8404 79

✉ shreeramhospital.op@gmail.com 🌐 www.srmhraipur.com





Shree Ram Multispeciality Hospital (SRMH)

L o k a h S a m a s t a S u k h i n o B h a v a n t u

OPD - ID : 02024-2025-0000001
UH-ID : SRMH-2408879*

PT. TYPE : NEW REGISTRATION
PRINT DATE : 24-08-2024 / 11:26

TOKEN NO. : 2

PATIENT NAME	: MRS. MOLIKA MARTINA JOSEPH	DEPARTMENT	: ENT
AGE / SEX	: 29-Y 1-M 19-D / FEMALE	DOB	: none
CONSULT-DATE	: 24-AUG-2024 - 11:24 AM		
MOB-NO	: 9644489249	COMPANY NAME	: MEDIWHEEL
GUARDIAN NAME	: W/O ONKAR SINGH	OPD PAID FEE	: 0.00
ADDRESS	: B/97 VIKAS NAGAR KUSUMNDA KORBA		
Weight :	Temp :	B.P. :	Pulse :
			SPO2 :

Please indicate whether you are presently suffering from any one of the following symptoms:

Yes No

Ears, Nose, Mouth, Throat

Ear pain	0	✓
Ear itch	0	✓
Ear drainage	0	✓
Dizziness/ Loss of balance	0	✓
Loss of Hearing	0	✓
Popping Noise	0	✓
Tinnitus	0	✓
Nosebleeds	0	✓
Post-nasal Drip	0	✓
Sinus pain	0	✓
Sinus pressure	0	✓
Nasal congestion	0	✓
Loss of smell/taste	0	✓
Hoarseness	0	✓
Sore Throat	0	✓
Throat tickle	0	✓
Dry Mouth / Throat	0	✓
Throat clearing	0	✓
Snoring	0	✓

Present chief complaints:-

- Nasal Congestion } Chronic Problem
- Snitzing

Dr. Signature

Adv

- Nasal drop Oxymetazoline
1 drop sos
- TAB MONTEK LC 1 TAB
Pro sos.

FOLLOW-UP DATE : ADVICE

FOR ADMISSION

YES	NO
-----	----

Near Railway Under Bridge, Basant Vihar Gate No. 1, Gondwara Chowk, Gudhiyari, Raipur (Chhattisgarh)

☎ 0771-43 43 161, 0771-43 40 162, 📞 8404 8404 79

✉ shreeramhospital.op@gmail.com 🌐 www.srmhraipur.com





Shree Ram Multispeciality Hospital (SRMH)

L o k a h S a m a s t a S u k h i n o B h a v a n t u

ECHOCARDIOGRAPHY REPORT

Name	Mrs. Molika Martina Joseph	Age / Sex	29 years / Female
Date	24-08-2024	UHID no	2408879

PULMOANRY VELOCITY ; 0.86 m/s

AORTIC VELOCITY : 1.00 m/s

TRICUSPID VELOCITY : 1.76 m/s

PASP : 17 mmHg + RAP

M-Measurement Value


Aorta	2.5	LVEDD	4.0
LA	3.4	IVSD	1.1
LVEF	>60%	LVPWD	1.1

FINAL IMPRESSION

- Mild LVH
- No RWMA
- Normal LV Systolic Function
- LVEF >60%
- Trace TR , PASP 17 mmHg + RAP
- No Clot/PE / Vegetation

Dr. Nikhil Motiramani

(MBBS, MD,DM Card)


Dr. Ajay Halbai
(MBBS, MD)

📍 Near Railway Under Bridge, Basant Vihar Gate No. 1, Gondwara Chowk,
Gudhiyari, Raipur (Chhattisgarh)

☎ 0771-43 43 161, 0771-43 40 162, 📞 8404 8404 79

✉ shreeramhospital.op@gmail.com 🌐 www.srmhraipur.com





SHRI RAM IMAGING & DIAGNOSTIC CENTER

Ground Floor, Raheja Towers, Jail Road, Raipur
Ph. : 0771-4099090, Mo. : 9294870000

DR ANAND BANSAL

MBBS MD DNB(Radiodiagnosis)
(IMS BHU) (Gold Medalist)
Ex Senior Resident (AIIMS Raipur)
Ex Assistant Professor (Pt JNMC Raipur)
Reg. No. - CGMC 6359/2015

5D SONOGRAPHY -16 SLICE CT SCAN - DIGITAL X RAY - PATHOLOGY - BIOPSY

PATIENT NAME: MOLIKA MARTINA JOSEPH	DATE: 24/08/2024
REF PHY: SHRIRAM MULTISPECIALITY HOSPITAL GUDHIYARI (SRMS), PATIENT ID: 79109	AGE/SEX: 24 Years / FEMALE

USG WHOLE ABDOMEN

Liver: Liver is normal in size (10.5 cm), smooth in outline & raised echotexture.

Billiry system: IHBR's are not dilated. CBD is not dilated.

Liver vessels: Portal vein and hepatic veins are normal.

Gall bladder: Distended with anechoic lumen and normal wall thickness.

Pancreas & Paraaortic Region: Normal. Pancreatic duct not dilated.


Spleen: Is normal in size measures (8.6 cm) with normal echotexture.

Kidneys	RIGHT	LEFT
SIZE	9.9 x 3.8 cm	10.2 x 4.3 cm
CORTICAL ECHOGENICITY	Normal	Normal
CORTICOMEDULLARY DIFFERENTIATION	Maintained	Maintained
PELVICALYCEAL SYSTEM	Not dilated	Not dilated
URETER	Not dilated	Not dilated
CALCULUS	No	No

Urinary bladder: The urinary bladder shows physiological distention. It shows normal wall thickness.

Uterus is normal in size (7.9 x 4.6 x 3.5 cm, Vol. - 66 cc) and echotexture.

Endometrial thickness 7.5 mm.



SHRI RAM IMAGING & DIAGNOSTIC CENTER

Ground Floor, Raheja Towers, Jail Road, Raipur
Ph. : 0771-4099090, Mo. : 9294870000

DR ANAND BANSAL
MBBS MD DNB(Radiodiagnosis)
(IMS BHU) (Gold Medalist)
Ex Senior Resident (AIIMS Raipur)
Ex Assistant Professor (Pt JNMC Raipur)
Reg. No. - CGMC 6359/2015

5D SONOGRAPHY -16 SLICE CT SCAN - DIGITAL X RAY - PATHOLOGY - BIOPSY

PATIENT NAME: MOLIKA MARTINA JOSEPH	DATE: 24/08/2024
REF PHY: SHRIRAM MULTISPECIALITY HOSPITAL GUDHIYARI (SRMS), PATIENT ID: 79109	AGE/SEX: 24 Years / FEMALE

Ovaries	Right	Left
Size	2.8 x 1.3 x 2.8 cm, (Vol. 5.4 ml).	3.1 x 1.6 x 2.5 cm, (Vol. 6.5 ml).
Shape	Normal	Normal
Echotexture	Normal	Normal
Any other remarks	Nil	Nil

No evidence of free fluid in abdomen or pelvis.
Bowel loops are grossly normal.

IMPRESSION:

- GRADE – I FATTY LIVER CHANGES.

Advised clinical correlation/further evaluation if clinically indicated.

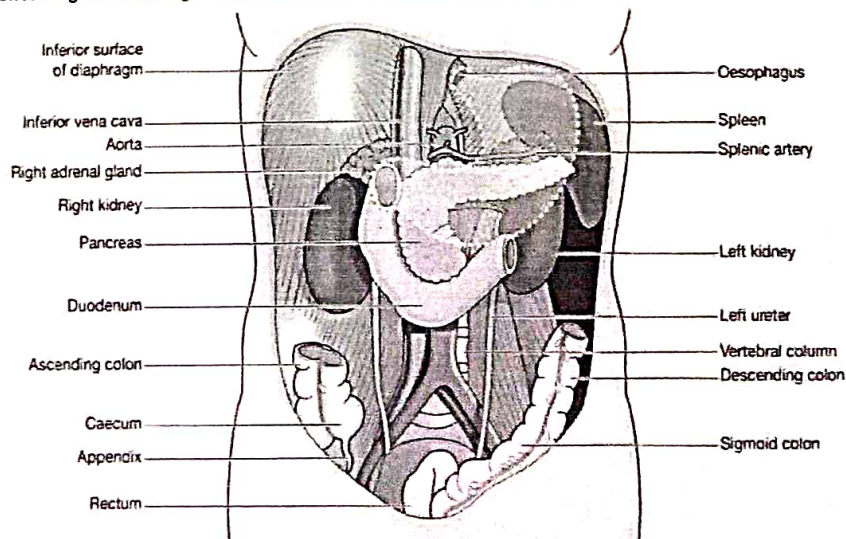


Anand

DR ANAND BANSAL
MD DNB RADIO DIAGNOSIS
CONSULTANT RADIOLOGIST
CGMC 2015/6359

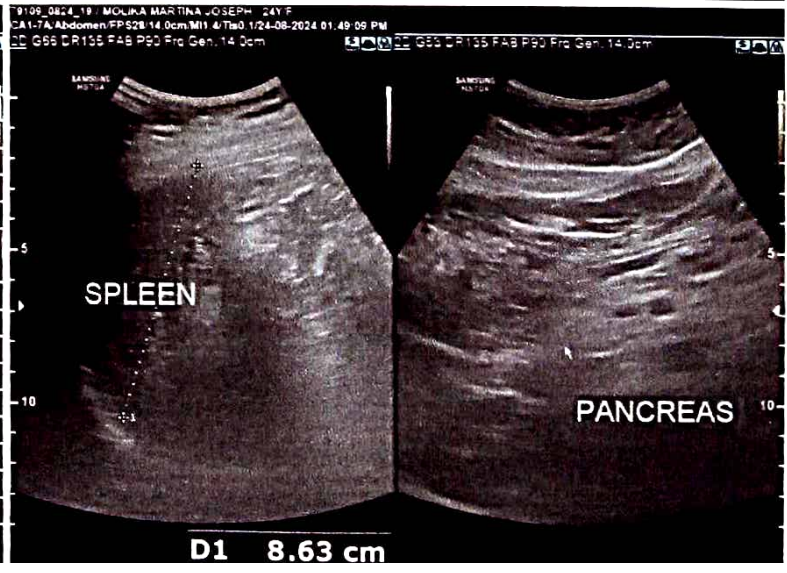
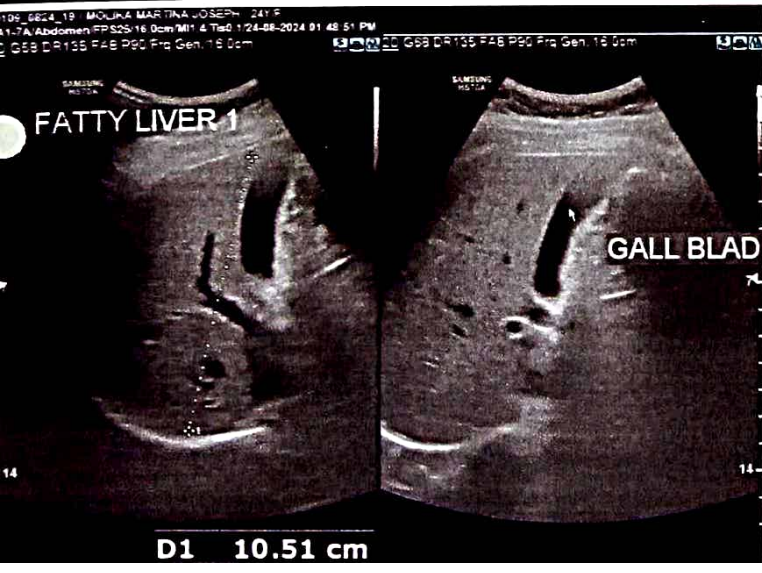
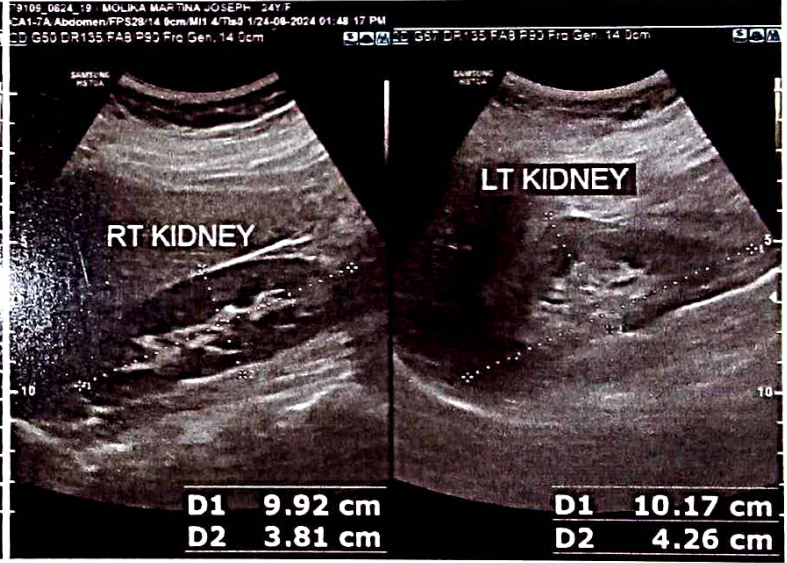
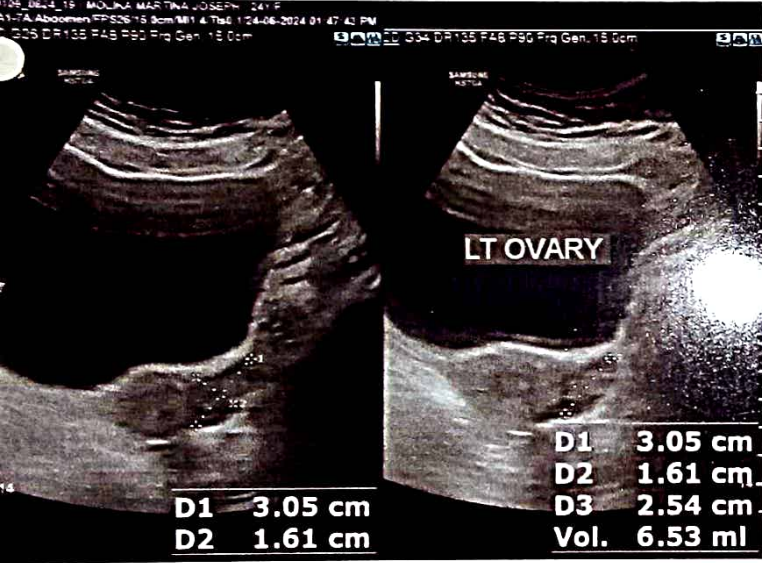
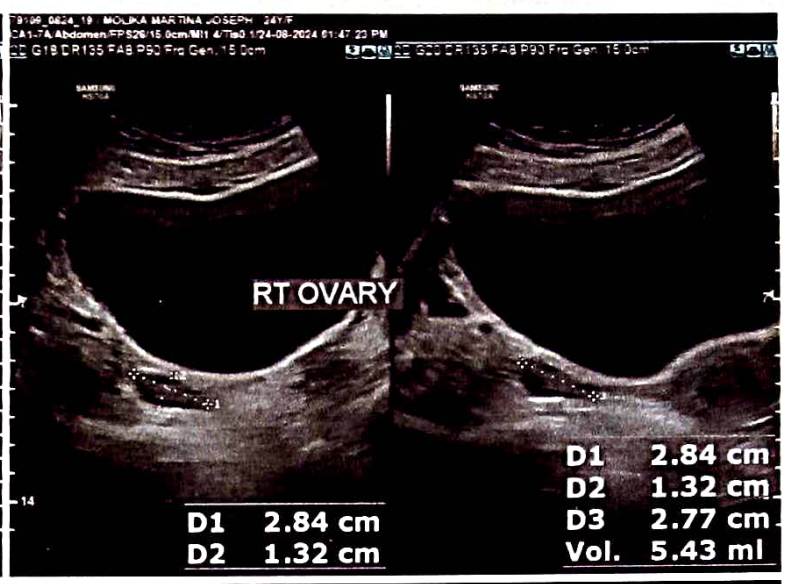
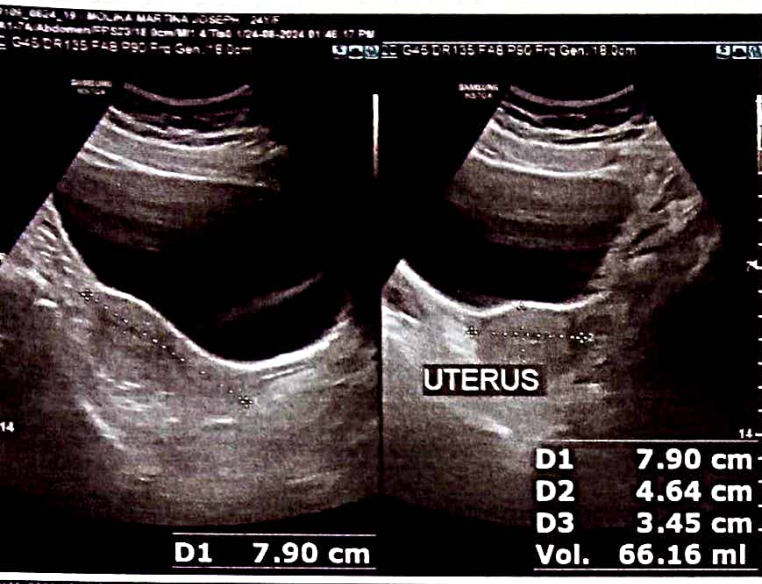
Typist: DEKUMAR SAHU

This report is for perusal of the doctor only not the definitive diagnosis; findings have to be clinically correlated. Ultrasound has its limitations in obese patients and in retroperitoneal organs. All congenital abnormalities cannot be detected on ultrasound. This report is not for medico-legal purposes.



SHRI RAM IMAGING & DIAGNOSTIC CENTRE

Name: **MOLIKA MARTINA JOSEPH** 24Y/F RefDr: **Shriram Multispeciality Hospital Gudhiyari (Srms)** Date: **24-Aug-2024**





Shree Ram Multispeciality Hospital (SRMH)

L o k a h S a m a s t a S u k h i n o B h a v a n t u

Department of Radiology

NAME -; Mrs. Molika Martina Joseph	AGE - 29 YEAR /F
REF.BY -; SHREE RAM MULTI SPECIALITY HOSPITAL	DATE - 24/08/2024

X – RAY CHEST PA VIEW.

FINDINGS:

- Bilateral lung parenchyma is clear.
- Both apices free.
- Trachea in mid line.
- C T ratio within normal limits.
- Both hila are normal.
- Both costo & cardiophrenic angles are clear.
- Bony cage normal.
- Soft tissue appears normal.

IMPRESSION :

No significant abnormality detected.



MD DNB RADIOLOGY

CONSULTANT RADIOLOGIST

CGMC 2015/6359

© Near Railway Under Bridge, Basant Vihar Gate No. 1, Gondwara Chowk,
Gudhiyari, Raipur (Chhattisgarh)

© 0771-43 43 161, 0771-43 40 162, 8404 8404 79

✉ shreeramhospital@gmail.com



