

24.08.2024 10:42:49
LIFE LINE HOSPITAL
496, MADYA
AZAMGARH (U.P)

Location:
Room:
Order Number:
Indication:
Medication 1:
Medication 2:
Medication 3:

63 bpm
-- / -- mmHg

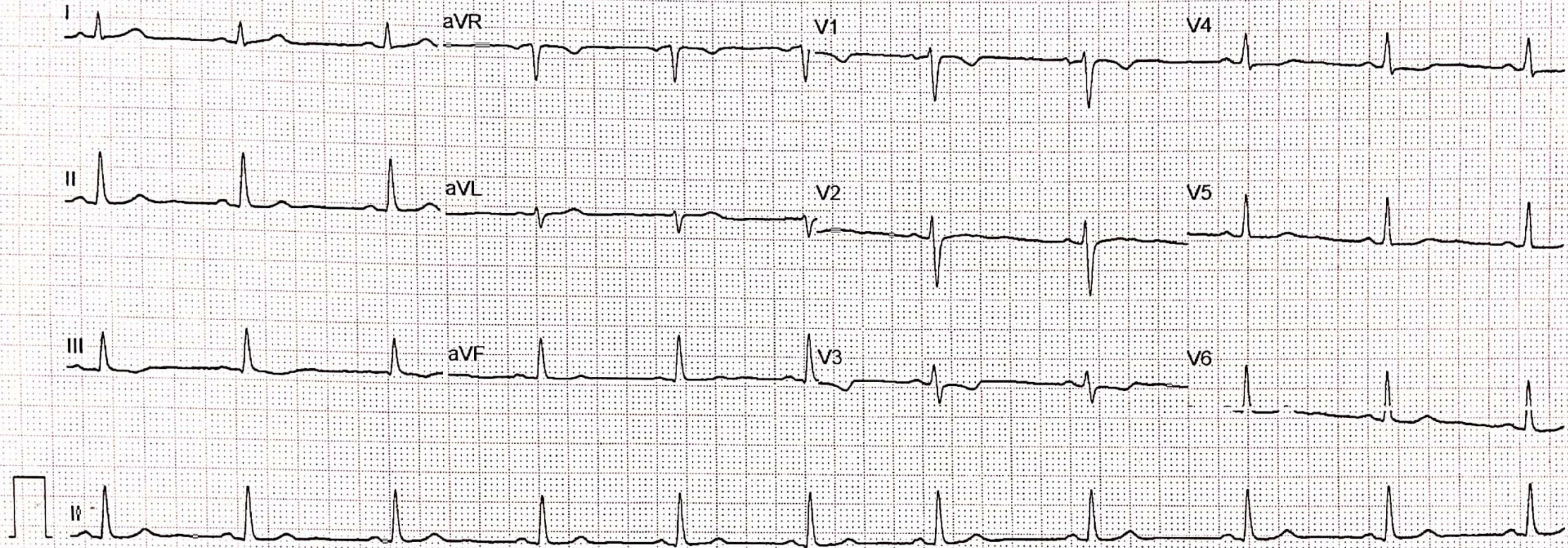
QRS : 82 ms
QT / QTcBaz : 378 / 386 ms
PR : 136 ms
P : 98 ms
RR / PP : 954 / 952 ms
P / QRS / T : 40 / 67 / 13 degrees

Normal sinus rhythm
Nonspecific T wave abnormality
Abnormal ECG

Technician:
Ordering Ph:
Referring Ph:
Attending Ph:

प्रतिभा यादव

Dr. Mohd. Ekram
M.D. Physician
Reg. No. - 61673



DATE – 24/08/2024

To whom so ever it may concern

➤ NAME : PRATIBHA YADAV
➤ AGE : 27Y/F
➤ HEIGHT : 165 cm
➤ WEIGHT : 50 kg
➤ BLOOD PRESSURE : 120/80
➤ PULSE : 92 mm/g

Patient is in normal condition.


M.D Physician
Reg. No.-61673
Consultant Signature & Stamp

 Toll Free No. :
18002129596


 Inquiry No. :
8726047092

 New Registration
8726031220

 Old Patient's
(in Emergency Contact)
8726031226



Visit us
[www. Lifelinehospitals.in](http://www.Lifelinehospitals.in)



Name	PRATIBHA YADAV	Age	27-F
Date	24/08/2024	Patient Id	MEDIWHEEL
Referring Doctor	MEDIWHEEL	Center	LIFE LINE HOSPITAL RAHUL NAGAR MADAY

XRAY CHEST PA VIEW

Both visualised lung fields appears normal. No focal lesion is noted.

Both hila are unremarkable.

Trachea is central and unremarkable.

Bilateral cardiophrenic and costophrenic angles are normal.

Both diaphragms are unremarkable.

Visualised bony thoracic cage is normal.

Adv- Clinical correlation

Dr Chandan Yadav
Consultant radiologist





Life Line[®]

Hospital & Research Centre

496, Madya, Azamgarh- 276001,(U.P.) India




Date-24-08-2024

Dental Health Check-Up (Oral Health Examination)

Patient Name – Mrs. Pratibha Yadav

Age- 27 years

Sex-Female



1- Soft tissues- No signs of inflammation.

2- Hard tissues- No cavity or any other abnormality with minimal plaque.

Examination Result-

Dental examination indicates good oral health, no immediate treatment needed.

Patient is advised to maintain good oral hygiene & continue regular dental checkups in every six months.


Consultant Sign

Toll Free No. : 18002129596

Inquiry No. : 8726047092

New Registration 8726031220

Old Patient's (in Emergency Contact) 8726031226



Visit us www.Lifelinehospitals.in



Scanned with OKEN Scanner

RAJ Lalit Netralaya & Hospital

Dr. Raj Kumar Singh
M.B.B.S., M.S. (Ophthalmology)
I.M.S. BHU-Varanasi
Sr Consultant
Anterior Segment

Dr. Ankit Raj Singh
M.B.B.S., M.S. (Ophthalmology)
S.A.I.M.S., Indore (M.P.)
Assistant Professor, GMC-Azamgarh
Phaco Fellow-Venue Eye Institute, Delhi

Appointment: 8574892867
Opticals: 7311194888
Pharmacy: 7311193888
Manager: 7311195888
Office: 05462-223377

Address: H.No. 217, in front of DAV Inter College Raidopur Azamgarh

Website: rlnyham.in

Gmail: rajlalitnetralaya@gmail.com

UIHD-REH100110346

NAME-PRATIBHA 27Y/F

DATE & TIME- 24/08/2024 11:48 AM

ADDRESS-LIFE LINE HOSPITAL

MOB-8173861119

VA < 6/6
6/6

N/6

Colour vision — Normal.



PATHOLOGY REPORT

PATIENT NAME : Mrs. PRATIBHA YADAV
 AGE / SEX : 27 Year / Female
 UHID : 431614
 REFERRED BY Dr. : MEDIWHEEL

REPORT DATE : 24/08/2024
 COLLECTED AT : OPD
 PATIENT ID : 7,161

INVESTIGATION : Complete Blood Count, E.S.R. (Wintrobe), BLOOD SUGAR FASTING & PP, BLOOD GROUP (ABO), SERUM CALCIUM, KIDNEY FUNCTION TEST, LIVER FUNCTION TEST (LFT), LIPID PROFILE, GLYCOSYLATED HAEMOGLOBIN (HBA1C), URINE EXAMINATION REPORT,

Tests	Results	Biological Reference Range
-------	---------	----------------------------

ROUTINE HAEMATOLOGY REPORT

Complete Blood Count

Haemoglobin	12.9	G%	(Men : 13.5-18.0 G%) (Women : 11.5-16.4 G%)
Total W.b.c. Count	4300	/cumm	(4000-11000 /cumm)
R. B. C.	4.33	million/c	(4.2 - 5.5)million/cmm
Differential W. B. C.			
Polymorph	60	%	(45-75)%
Lymphocyte	35	%	(20-40 %)
Eosinophil	02	%	(0-6)%
Monocyte	03	%	(2-10)%
Basophil	00	%	(<1 %)
-			
P. C. V. (hemotocrite)	37.5	%	(36-50 %)
M. C. V.	86.7	fl	(82-98) fl
M. C. H.	29.7	Pg	(28Pg - 32Pg)
M. C. H. C.	34.3	g/dl	(32g/dl - 36g/dl)
Platelete Count	1.30	/cumm	(1.5-4.0 lacs/cumm)
E.S.R. (Wintrobe)			
Observed	18		Male (0 - 9mm 1 Hours) Female (0 - 20mm 1 Hours)

BLOOD GROUP (ABO)

A.B.O. "O"
 Rh(D) NEGATIVE

Checked By

Dr. A. Ankur
 Pathologist

Note : Every Test has its own inherent limitations. Therefore, in case of any discrepancy with clinical profile, Please inform the lab immediately to confirm. This Medical Report is not meant for any legal purpose.

Toll Free No. : 18002129596

PATHOLOGY REPORT

PATIENT NAME :	Mrs. PRATIBHA YADAV	REPORT DATE :	24/08/2024
AGE / SEX :	27 Year / Female	COLLECTED AT :	OPD
UHID :	431614	PATIENT ID :	7,161
REFERRED BY Dr.:	MEDIWHEEL		

INVESTIGATION : Complete Blood Count, E.S.R. (Wintrobe), BLOOD SUGAR FASTING & PP, BLOOD GROUP (ABO), SERUM CALCIUM, KIDNEY FUNCTION TEST, LIVER FUNCTION TEST (LFT), LIPID PROFILE, GLYCOSYLATED HAEMOGLOBIN (HBA1C), URINE EXAMINATION REPORT,

Tests	Results	Biological Reference Range
-------	---------	----------------------------

BIOCHEMISTRY

KIDNEY FUNCTION TEST

*BLOOD UREA	27.7	mg/dl	13-45 mg/dl
*SERUM CREATNINE	0.8	mg/dl	0.6-1.4 mg/dl
*SERUM URIC ACID	5.1	mg/dl	2.5-7.0 mg/dl
*SERUM SODIUM	141.7	MEq/L	130-145 MEq/L
*SERUM POTASSIUM	4.0	MEq/L	3.5-5.5 MEq/L

BLOOD SUGAR FASTING & PP

BLOOD SUGAR FASTING	91.8	mg/dl	(60-110)mg/dl
*	<140	Normal	
	140<200	Impaired Glucose Tolerance	
	>200	Diabetes Mellitus	


** Hba1c Facility Available**

GLYCOSYLATED HAEMOGLOBIN (HBA1C)

HBA1c	5.72	%	(4.2 - 6.2 %)
-------	------	---	---------------

Interpretation

As Per American Diabetes Association (ada)
 Reference Group Hba1c In %
 Normal Value (ngsp) 4.6% - 6.2%
 At Risk (prediabetes)(ada) 5.7% - 6.4%
 Diagnosing Diabetes Above 6.5

Anrita Anand
 Pathologist
 Reg No - 7847

 Dr. A. Ankur
 Pathologist

Checked By

Note : Every Test has its own inherent limitations. Therefore, in case of any discrepancy with clinical profile, Please inform the lab immediately to confirm. This Medical Report is not meant for any legal purpose.


Toll Free No. : 18002129596



Life Line[®]

HOSPITAL & RESEARCH CENTRE

496, Madya, Azamgarh-27600 1, (U.P) India
Tel. : +91 (05462) 247091-92-93 Mob.: 8726047092
Website- www.lifelinehospitals.in



PATHOLOGY REPORT

PATIENT NAME :	Mrs. PRATIBHA YADAV	REPORT DATE :	24/08/2024
AGE / SEX :	27 Year / Female	COLLECTED AT :	OPD
UHID :	0431614	PATIENT ID :	7,167
REFERRED BY Dr. :	MEDIWHEEL		

INVESTIGATION :	BLOOD SUGAR FASTING & PP,	
Tests	Results	Biological Reference Range

BIOCHEMISTRY

BLOOD SUGAR FASTING & PP

BLOOD SUGER PP	116.3 mg/dl	110-160 mg /dl
----------------	-------------	----------------

- * <140 Normal
- 140<200 Impaired Glucose Tolerance
- >200 Diabetes Mellitus

** Hba1c Facility Available**



Life Line[®]
HOSPITAL & RESEARCH CENTRE

Dr. A. Ankur
Pathologist
Reg No. -78476

Checked By

Dr. A. Ankur
Pathologist

Note : Every Test has its own inherent limitations. Therefore, in case of any discrepancy with clinical profile, Please inform the lab immediately to confirm. This Medical Report is not meant for any legal purpose.

Toll Free No. : 18002129596



Scanned with OKEN Scanner

PATHOLOGY REPORT

PATIENT NAME :	Mrs. PRATIBHA YADAV	REPORT DATE :	24/08/2024
AGE / SEX :	27 Year / Female	COLLECTED AT :	OPD
UHID :	431614	PATIENT ID :	7,161
REFERRED BY Dr.:	MEDIWHEEL		

INVESTIGATION : Complete Blood Count, E.S.R. (Wintrobe), BLOOD SUGAR FASTING & PP, BLOOD GROUP (ABO), SERUM CALCIUM, KIDNEY FUNCTION TEST, LIVER FUNCTION TEST (LFT), LIPID PROFILE, GLYCOSYLATED HAEMOGLOBIN (HBA1C), URINE EXAMINATION REPORT,

Tests	Results	Biological Reference Range
-------	---------	----------------------------

LIVER FUNCTION TEST (LFT)

*SERUM BILIRUBIN (TOTAL)	0.8 mg/dl	0.1-1.2 mg/dl
* BILIRUBIN (DIRECT)	0.3 mg/dl	0.1-0.40 mg/dl
*BILIRUBIN (INDIRECT)	0.5 mg/dl	mg/dl
*SGPT/ALT-SERUM	27.3 U/L	5-40 U/L
*SGOT/AST -SERUM	26.3 IU/L	5-38 IU/L
*ALKALINE PHOSPHATASE -SERUM	187.2 IU/L	64.0 - 306.0 U/L Female 80.0 - 306.0 U/L Male
*TOTAL PROTEIN -SERUM	6.7 gm/dl	6-8.3 gm/dl
*ALBUMIN-SERUM	4.2 gm/dl	3.2-5.0gm/dl
*GLOBULIN-SERUM	2.5 gm/dl	2.3-3.6gm/dl
*A/G RATIO-SERUM	1.68 Ratio	1.3-2. Ratio

LIPID PROFILE

Serum Cholesterol	192.7 mg/dl	(100-200 mg/dl)
SERUM TRIGLYCERIDES	96.4 mg/dl	(25-160 mg/dl)
SERUM HDL CHOLESTROL	48.3 mg/dl	(30-60 mg/dl Male) (35-80 mg/dl Female)
SERUM VLDL	19.28 mg/dl	(10-40 mg/dl)
SERUM LDL CHOLESTROL	125.12 mg/dl	(60-100 mg/dl)
SERUM CALCIUM	8.9 mg%	(8.4-10.8 mg%)

Checked By

Ankur
 Pathologist
 Dr. Ankur
 Pathologist

Note : Every Test has its own inherent limitations. Therefore, in case of any discrepancy with clinical profile, Please inform the lab immediately to confirm. This Medical Report is not meant for any legal purpose.

Toll Free No. : 18002129596

PATHOLOGY REPORT

LAB NO: 431614	AGE/SEX: 27/F Years	COLLECTED 24/08/2024
NAME: PRATIBHA YADAV		REPORTED 24/08/2024
Ref By : DR. MEDIWHEEL		REPORT STATUS : FINAL

Test Name	Results/Units	Bio. Ref. Interval
THYROID PROFILE, TOTAL, SERUM (Immunoassay Method Based on CLIA)		
T3, Total	1.20 ng/ml	0.69 - 2.15
T4, Total	101.3 ng/ml	52.0 - 127.0
TSH	3.77 uIU/MI	0.30 - 4.5

TSH	T4	T3	INTERPRETATION
High	Normal	Normal	Mild (subclinical) hypothyroidism
High	Low	Low or normal	Hypothyroidism
Low	Normal	Normal	Mild (subclinical) hyperthyroidism
Low	High or normal	High or Normal	Hyperthyroidism
Low	Low or normal	Low or normal	Non-thyroidal illness; rare pituitary (secondary) Hypothyroidism

****End of Report****

Checked by.

Dr. Ankur Pathologist
 Reg No. - 78476

Note : Every Test has its own inherent limitations. Therefore, in case of any discrepancy with clinical profile, Please inform the lab immediately to confirm. This Medical Report is not meant for any legal purpose.

Toll Free No. : 18002129596

PATHOLOGY REPORT

PATIENT NAME :	Mrs. PRATIBHA YADAV	REPORT DATE :	24/08/2024
AGE / SEX :	27 Year / Female	COLLECTED AT :	OPD
UHID :	431614	PATIENT ID :	7,161
REFERRED BY Dr. :	MEDIWHEEL		

INVESTIGATION : Complete Blood Count,E.S.R. (Wintrobe),BLOOD SUGAR FASTING & PP,BLOOD GROUP (ABO),SERUM CALCIUM,KIDNEY FUNCTION TEST,LIVER FUNCTION TEST (LFT),LIPID PROFILE,GLYCOSYLATED HAEMOGLOBIN (HBA1C),URINE EXAMINATION REPORT,

Tests	Results	Biological Reference Range
-------	---------	----------------------------

URINE EXAMINATION REPORT

PHYSICAL

Volume	20	ml
Colour	STRAW	
Specific gravity	1.010	
Appearance	CLEAR	

CHEMICAL

Reaction pH	6.5
Sugar	NIL
Protiens	NIL
Blood	NIL
NITRITE	NIL
Ketone bodies	NIL
Bile Pigment (Bilirubin)	NIL
Bile Salt	NIL
Chyle	NIL
Urobilinogen	NIL

MICROSCOPIC

(After Standard centrifugation)

CELLS

Pus cells	1-2	/hpf
Epith Cells	1-2	/hpf
R.B.C.'s cells	NIL	/hpf
Other cells	NIL	/hpf

Checked By

A
Dr. A. Ankur
Pathologist


Note : Every Test has its own inherent limitations. Therefore, in case of any discrepancy with clinical profile, Please inform the lab immediately to confirm. This Medical Report is not meant for any legal purpose.



Life Line[®]

HOSPITAL & RESEARCH CENTRE

496, Madya, Azamgarh-27600 1, (U.P) India
 Tel. : +91 (05462) 247091-92-93 Mob.: 8726047092
 Website- www. lifelinehospitals.in

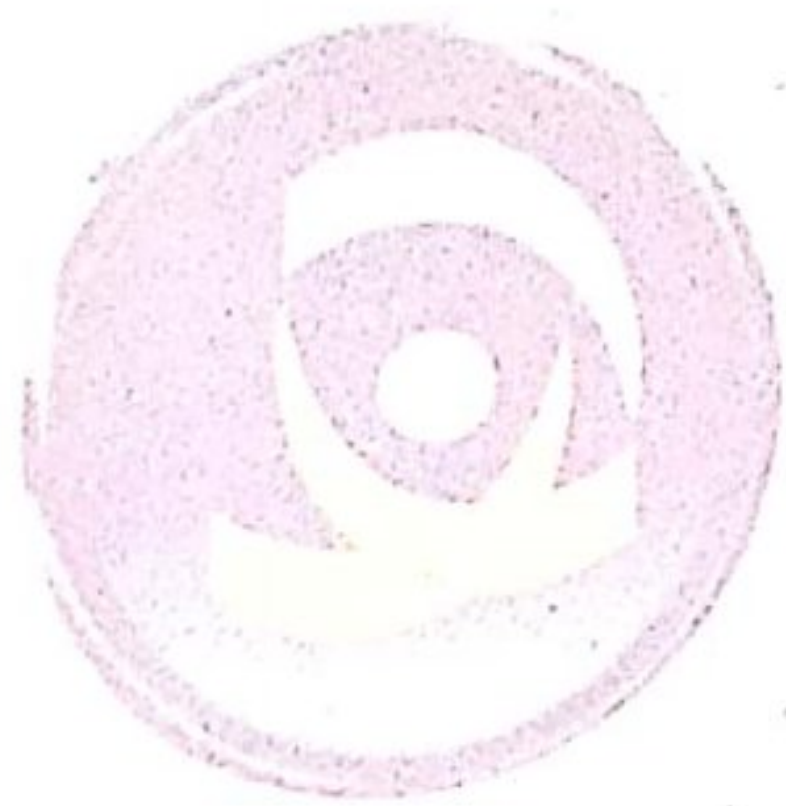


PATHOLOGY REPORT

PATIENT NAME :	Mrs. PRATIBHA YADAV	REPORT DATE :	24/08/2024
AGE / SEX :	27 Year / Female	COLLECTED AT :	OPD
UHID :	431614	PATIENT ID :	7,161
REFERRED BY Dr. :	MEDIWHEEL		

INVESTIGATION : Complete Blood Count, E.S.R. (Wintrobe), BLOOD SUGAR FASTING & PP, BLOOD GROUP (ABO), SERUM CALCIUM, KIDNEY FUNCTION TEST, LIVER FUNCTION TEST (LFT), LIPID PROFILE, GLYCOSYLATED HAEMOGLOBIN (HBA1C), URINE EXAMINATION REPORT,

Tests	Results	Biological Reference Range
CAST	NIL	/hpf
GRANULAR CAST	NIL	/hpf
Cellular	NIL	/hpf
Crystals	NIL	/hpf
Sperms		



Life Line[®]
 HOSPITAL & RESEARCH CENTRE


Checked By

Dr. A. Ankur
 Dr. A. Ankur
 Pathologist

Note : Every Test has its own inherent limitations. Therefore, in case of any discrepancy with clinical profile, Please inform the lab immediately to confirm. This Medical Report is not meant for any legal purpose.

Toll Free No. : 18002129596


मेरा आधार, मेरी पहचान



भारत सरकार
Government of India



Aadhaar no. issued: 18/08/2013



प्रतिभा यादव
PRATIBHA YADAV
जन्म तिथि/DOB: 05/08/1997
महिला/FEMALE

आधार पहचान का प्रमाण है, नागरिकता या जन्मतिथि का नहीं।
इसका उपयोग सत्यापन (ऑनलाइन प्रमाणीकरण, या मधुआर कोड
आधारित एमएसएल की स्कैनिंग) के साथ किया जाना चाहिए।
Aadhaar is proof of identity, not of citizenship
or date of birth. It should be used with verification (online
authentication, or scanning of QR code / offline XML).

4558 5987 1584

मेरा आधार मेरी पहचान



Type here to search




Entities seeking Aadhaar are obligated to seek consent.



भारतीय विशिष्ट पहचान प्राधिकरण
Unique Identification Authority of India



पता:
D/O: गंगाराम यादव, हरबंशपुर, हरबंशपुर, सबर, आजमगढ़,
आजमगढ़, आजमगढ़,
उत्तर प्रदेश - 276001



Details as on: 24/10/2024

Address:
D/O: Gangaram Yadav, HARBANSHPUR,
HARBANSHPUR, SADAR, Azamgarh, PO,
Azamgarh, DIST: Azamgarh,
Uttar Pradesh - 276001

4558 5987 1584

VID : 9153 4594 3308 6553



Signed and all signatures are valid.



Signature Panel

Signature valid

Digitally signed by Unique Identification Authority of India
DN
Date: 2024.08.24 10:12:09
GMT+05:30



आपका **आधार** क्रमांक / Your **Aadhaar** No. :

4558 5987 1584

VID : 9153 4594 3308 6553

मेरा **आधार**, मेरी पहचान



भारत सरकार

Government of India



आधार

Aadhaar no. issued: 18/08/2013



प्रतिभा यादव
PRATIBHA YADAV
जन्म तिथि/DOB: 05/08/1997
महिला/ FEMALE

आधार पहचान का प्रमाण है, नागरिकता या जन्मतिथि का नहीं।
इसका उपयोग सत्यापन (ऑनलाइन प्रमाणीकरण, या वीड्युअर कोड/
ऑफलाइन एक्सएमएल की स्कैनिंग) के साथ किया जाना चाहिए।
Aadhaar is proof of identity, not of citizenship
or date of birth. It should be used with verification (online
authentication, or scanning of QR code / offline XML).

4558 5987 1584

मेरा **आधार**, मेरी पहचान

regulations, submitted by Aadhaar number holder.

- This **Aadhaar** letter should be verified through either online authentication by UIDAI-appointed authentication agency or QR code scanning using mAadhaar or Aadhaar QR Scanner app available in app stores or using secure QR code reader app available on www.uidai.gov.in.
- **Aadhaar** is unique and secure.
- Documents to support identity and address should be updated in **Aadhaar** after every 10 years from date of enrolment for **Aadhaar**.
- **Aadhaar** helps you avail of various Government and Non-Government benefits/services.
- Keep your mobile number and email Id updated in **Aadhaar**.
- Download mAadhaar app to avail of **Aadhaar** services.
- Use the feature of Lock/Unlock **Aadhaar**/biometrics to ensure security when not using **Aadhaar**/biometrics.
- Entities seeking **Aadhaar** are obligated to seek consent.



भारतीय विशिष्ट पहचान प्राधिकरण

Unique Identification Authority of India



AADHAAR

पता:
D/O: गंगाराम यादव, हरबंशपुर, हरबंशपुर, सदर, आजमगढ़,
आजमगढ़, आजमगढ़,
उत्तर प्रदेश - 276001
Address:
D/O: Gangaram Yadav, HARBANSHPUR,
HARBANSHPUR, SADAR, Azamgarh, PO:
Azamgarh, DIST: Azamgarh,
Uttar Pradesh - 276001

Details as on: 24/08/2024



4558 5987 1584

VID : 9153 4594 3308 6553

1947

help@uidai.gov.in

www.uidai.gov.in

Type here to search

Desktop



GPS Map Camera

Azamgarh Division, Uttar Pradesh, India

321/26, Pandit Dindayal Upadhyaya Marg, near Life Line Hospital
And Research Centre, Marhaya, Azamgarh, Uttar Pradesh 276001,

Long 83.186843°

Lat 26.050627°

24/8/2024 10:18 AM

Pandit Dindayal
Upadhyaya Marg



Home Center
Google





Prataap Diagnostic Centre

A complete diagnostic centre

Dr. S. Ghoshly M.D. (Pathology) Dr. Raju Shrivastava M.D. (Pathology) Dr. Suman Yadav M.D. (Pathology) Dr. A. Anur (Pathology)

CIVIL LINE, AZAMGARH. Ph.: 05462 247094, 247095
M-8726038000, 6389938000 Email: pratapdiagnosticazm@gmail.com

ID	: 4914	Age	: 35 Yrs
PATIENT NAME	: Mrs. Pratibha Yadav	SEX	: Female
REFERRED BY	: Dr. Self	DATE	: 24.08.2024

ULTRASONOGRAPHY: WHOLE ABDOMEN

Liver is normal in size (~ 14.2 cm), shape and echotexture. No focal lesion seen. There is no intrahepatic biliary dilatation. Portal and hepatic venous channels are within normal limits. No focal lesion seen.

Gall bladder is normal in position, shape and size. Walls are normal in thickness & regular. Lumen is echofree, no calculus is seen. No peri-cholecystic collection. CBD is not dilated.

Pancreas is normal in size. Margins are regular. Parenchyma shows normal echotexture. Pancreatic duct is not dilated. No focal area of altered echogenecity or calcification is seen.

Spleen is normal in size, shape and echotexture. Margins are regular with uniform parenchymal echogenecity.

Kidneys: Both kidneys are normal in position and size. Margins are regular. Parenchymal echogenecity is normal. Corticomedullary differentiation is maintained. Pelvicalyceal system is not dilated. No calculi / mass lesion seen. Both the ureters are not dilated.

Urinary bladder is well distended. Walls are regular. No calculus or mass seen.

Uterus is normal in size and echotexture. No obvious mass lesion seen. Endometrial thickness is normal (~9.7 mm). Cervix appears normal.

Both ovaries appear normal in size and echotexture. No obvious adnexal mass seen.

- > There is no free fluid in peritoneal cavity.
- > No bowel wall thickening or bowel mass.
- > No pleural effusion on either side.

IMPRESSION:

- ✓ No significant abnormality detected.

Advise: Clinical correlation.

Dr. Suman Yadav
M.D. (Radio diagnosis)

The science of radiology is based upon interpretation of shadows of normal and abnormal tissue. This is neither complete nor accurate; hence, findings should always be interpreted in to the light of clinico-pathological correlation. This is a professional opinion, not a diagnosis. Not meant for medico legal purposes



Prataap Diagnostic Centre

A complete diagnostic centre

Dr. A. Ganguly M.D. (Pathology) Dr. Rajan Shrivastava M.D. (Pathology) Dr. Suman Yadav M.D. (Radio diagnosis) Dr. A. Ankar (Pathology)

CIVIL LINE, AZAMGARH. Ph.: 05462 247094, 247095, M-8726038000, 6389938000 Email: pratapdiagnosticazm@gmail.com

ID	: 4914	Age	: 35 Yrs
PATIENT NAME	: Mrs. Pratibha Yadav	SEX	: Female
REFERRED BY	: Dr. Self	DATE	: 24.08.2024

ULTRASONOGRAPHY: WHOLE ABDOMEN

Liver is normal in size (~ 14.2 cm), shape and echotexture. No focal lesion seen. There is no intrahepatic biliary dilatation. Portal and hepatic venous channels are within normal limits. No focal lesion seen.

Gall bladder is normal in position, shape and size. Walls are normal in thickness & regular. Lumen is echofree, no calculus is seen. No peri-cholecystic collection. CBD is not dilated.

Pancreas is normal in size. Margins are regular. Parenchyma shows normal echotexture. Pancreatic duct is not dilated. No focal area of altered echogenicity or calcification is seen.

Spleen is normal in size, shape and echotexture. Margins are regular with uniform parenchymal echogenicity.

Kidneys: Both kidneys are normal in position and size. Margins are regular. Parenchymal echogenicity is normal. Corticomedullary differentiation is maintained. Pelvicalyceal system is not dilated. No calculi / mass lesion seen. Both the ureters are not dilated.

Urinary bladder is well distended. Walls are regular. No calculus or mass seen.

Uterus is normal in size and echotexture. No obvious mass lesion seen. Endometrial thickness is normal (~9.7 mm). Cervix appears normal.

Both ovaries appear normal in size and echotexture. No obvious adnexal mass seen.

- There is no free fluid in peritoneal cavity.
- No bowel wall thickening or bowel mass.
- No pleural effusion on either side.

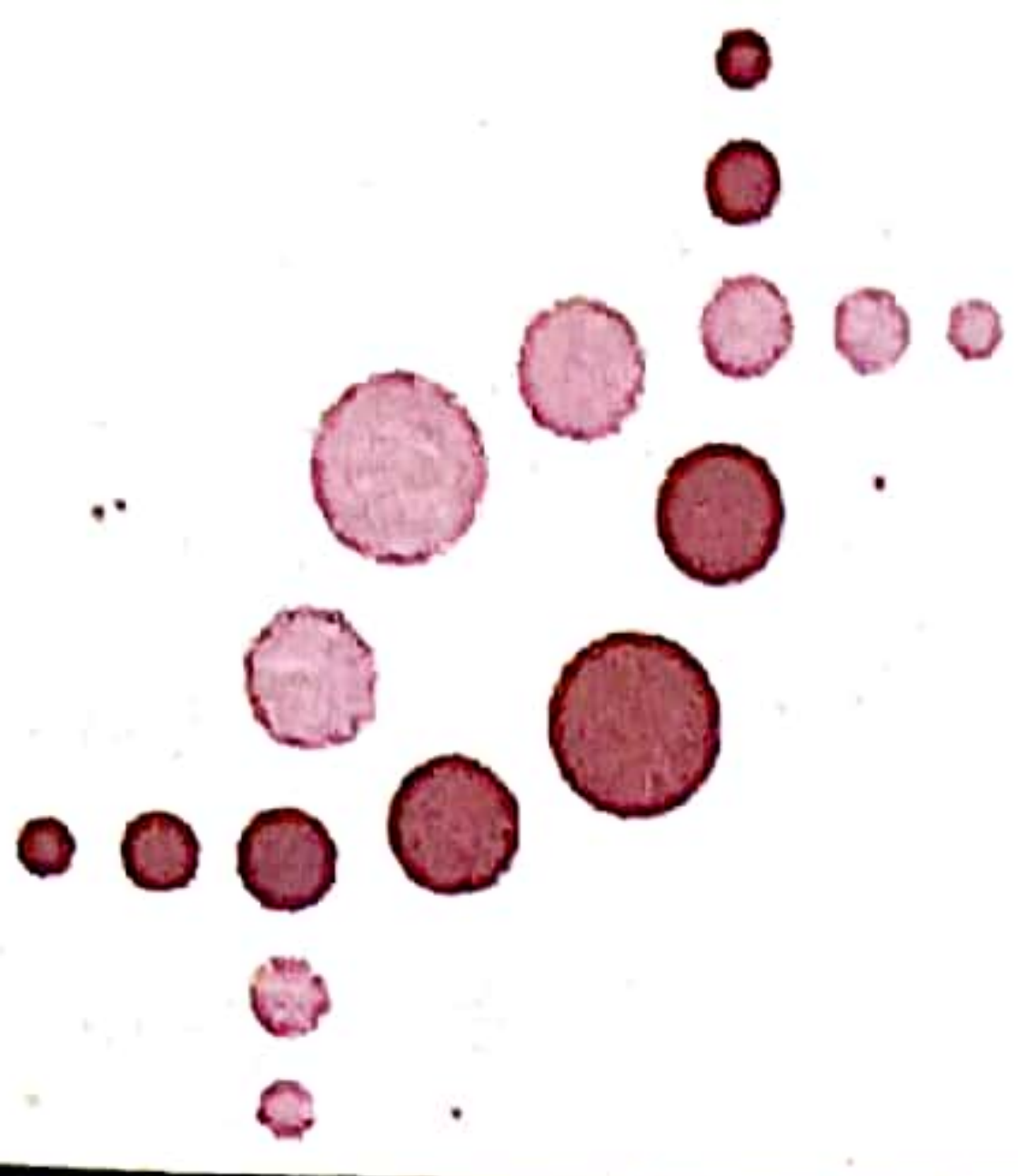
IMPRESSION:

✓ No significant abnormality detected.

Advise: Clinical correlation.

Dr. Suman Yadav
M.D. (Radio diagnosis)

The science of radiology is based upon interpretation of shadows of normal and abnormal tissue. This is neither complete nor accurate; hence, findings should always be interpreted in to the light of clinico-pathological correlation. This is a professional opinion, not a diagnosis. Not meant for medico legal purposes



Pratap Diagnostic Centre

A complete diagnostic centre

CIVIL LINE, AZAMGARH. Ph.: 05462 247094, 247095, M-8726038000 Email: pratapdiagnosticazm@gmail.com

2 D, M MODE ECHO CARDIOGRAPHY & COLOR DOPPLER

PAT.NAME	Mrs.	PRATIBHA	AGE/SEX	27Y/F
REF.BY.	DR.	SELF	DATE	24.08.2024
PAT ID				

ECHO WINDOW : GOOD

- Normal cardiac chamber dimensions (AO =26.9 mm, LA = 28.7mm, LVIDD =36.3 mm, RVD1=29.4mm).
- Normal Aortic root & MPA.
- Normal cardiac valves.
- No regional wall motion abnormality at rest.
- Normal LV systolic function, LVEF = 62.1%
- Normal RV systolic function (TAPSE =24.2 mm).
- No diastolic dysfunction (E/A = 1.4, E/e'=4.25).
- No pericardial effusion.
- Intact IAS, IVS, no PDA, no coarctation.
- Normal LV mass, no concentric hypertrophy of left ventricle.
- Normal aortic arch flow; Normal PV drainage.
- No intra cardiac mass thrombus or vegetation.

IMPRESSION :

- *No regional wall motion abnormality at rest.*
- *Normal LV systolic function, LVEF =62.1 %*
- *Normal RV systolic function.*
- *No diastolic dysfunction.*
- *Normal cardiac valves.*

Dr. Uday Prabhakar
MBBS, MD (Medicine), PGDCC