



# MODERN PATHOLOGY & DIAGNOSTIC CENTRE

**CLINIC :**  
1/4A, Vineet Khand, (Opp Jaipuria Management)  
Gomti Nagar, Lucknow - 226 010  
Ph.: 0522-4008184, 4308184 ☎ 8112323230  
Mob.: 7618884441, 9450389932, 8177063877

Dr. R. P. Rastogi  
M.B.B.S., M.D. (Path & Bact)



DATE : 24/08/2024

NAME : MrS Deepa Yadav

AGE : 34 Years                      SEX : F

HEIGHT : 146 CMS

WEIGHT : 44 KGS

BMI : 20.6

Blood Pressure : 110/70

  
Dr. Smita Rastogi  
MBBS, DCP  
Reg. No. 37370



**Dr. Sanjay Rastogi**  
M.B.B.S., DCP, CRIAT (BARC)

**Dr. Smita Rastogi**  
M.B.B.S., DCP

Results, adhering to W.H.O. and International Federation of Clinical Chemists Quality Control Standards.

SAMPLE COLLECTION FACILITY AVAILABLE

Report needs clinicopathological correlation ♦ Not for Medico Legal Purpose

e-mail : mpdcgn@gmail.com ♦ For online reports - [www.modernpath.in](http://www.modernpath.in)

♦ Please ask for your computerized bill ♦ Pay only the printed collection charges

भारत सरकार

Government of India



दीपा यादव

Deepa Yadav

जन्म तिथि/DOB: 02/08/1990

महिला/ FEMALE



8878 4469 5428

VID : 9102 8345 8093 9937


मेरा आधार, मेरी पहचान

भारतीय विशिष्ट पहचान प्राधिकरण

Unique Identification Authority of India

रंज यादव, 86 / 161 ए, कुर्मी टोला , रिशालदर  
ल कुवां, लखनऊ, लखनऊ,  
श - 226018

SS:  
ankaj Yadav, 86 / 161 A, Kurmi Toia ,  
ar Park, Lal Kuwan, Lucknow,  
W,  
adesh - 226018



8878 4469 5428

VID : 9102 8345 8093 9937

You have been informed that, ophthalmology, dental consultation, Gynaecological, ENT or Dietician facility is not available at our centre. If you are ready then your test can be started.

2D echo test facility is not available at our centre, instead we do TMT test.

A handwritten signature in black ink, appearing to be 'Deep'.



# MODERN PATHOLOGY & DIAGNOSTIC CENTRE

Dr. R. P. Rastogi  
M.B.B.S., M.D. (Path & Bact)



**CLINIC :**  
1/4A, Vineet Khand, (Opp Jaipuria Management)  
Gomti Nagar, Lucknow - 226 010  
Ph.: 0522-4008184, 4308184 ☎ 8112323230  
Mob.: 7618884441, 9450389932, 8177063877

Date	: 24-Aug-2024		
Name	: Mrs. DEEPA YADAV	Age	: 34 Yrs.
Ref.By	: APOLLO HEALTH	Sex	: Female

Haemoglobin	12.9	gm%	11 - 14
-------------	------	-----	---------

Total Leucocyte Count	8400	Cells/cumm.	4000-11000
-----------------------	------	-------------	------------

Differential Leucocyte Count			
Polymorphs	63	%	45 - 70
Lymphocytes	23	%	20 - 45
Eosinophils	<b>10</b>	%	0 - 6
Monocytes	04	%	0 - 8
Basophils	00	%	0 - 1

Erythrocyte Sedimentation Rate (Wintrobe)			
ESR	16	mm in 1st Hr.	0 - 19
PCV	40.8	cc%	40 - 52
Corrected ESR	04	mm in 1st Hr.	0 - 19

Platelet Count	2.37	lakh/cumm.	1.5 - 4.0
----------------	------	------------	-----------

Red Cells Count	4.45	million/cmm	3.90 to 4.60
-----------------	------	-------------	--------------

Absolute values			
MCV	84.1	fL	77 - 97
MCH	<b>26.6</b>	pg	27 - 31
MCHC	31.6	gm /dl	31 - 34

**Dr. Sanjay Rastogi**  
M.B.B.S., D.C.P. (BARC)

**Dr. Smita Rastogi**  
M.B.B.S., DCP


Results, adhering to W.H.O. and International Federation of Clinical Chemists Quality Control Standards.

SAMPLE COLLECTION FACILITY AVAILABLE

Report needs clinicopathological correlation ♦ Not for Medico Legal Purpose

e-mail : mpdcgn@gmail.com ♦ For online reports - [www.modernpath.in](http://www.modernpath.in)

♦ Please ask for your computerized bill ♦ Pay only the printed collection charges



# MODERN PATHOLOGY & DIAGNOSTIC CENTRE

## DIAGNOSTIC CENTRE

CLINIC :  
1/4A, Vineet Khand, (Opp Jaipuria Management)  
Gomti Nagar, Lucknow - 226 010  
Ph.: 0522-4008184, 4308184 • 8112323230  
Mob.: 7618884441, 9450389932, 8177063877

Dr. R. P. Rastogi  
M.B.B.S., M.D. (Path & Bact)



Date : 24-Aug-2024

Name : **Mrs. DEEPA YADAV**

Age : 34 Yrs.

Ref.By : APOLLO HEALTH

Sex : Female

### General Blood Picture

<b>RBCs</b>	RBCs are Normocytic & Normochromic. No Normoblasts are seen.
<b>WBCs</b>	TLC is within normal range. DLC shows increased number of eosinphils. No immature cells of WBC seen.
<b>PLATELETS</b>	Platelets are adequate in number and morphology.
<b>OTHERS</b>	No haemoparasites are seen.
<b>IMPRESSION</b>	EOSINOPHILIA

Dr. Sanjay Rastogi  
M.B.B.S., DCP, (BARC)

Dr. Smita Rastogi  
M.B.B.S., DCP

Results, adhering to W.H.O. and International Federation of Clinical Chemists Quality Control Standards.

SAMPLE COLLECTION FACILITY AVAILABLE

Report needs clinicopathological correlation ♦ Not for Medico Legal Purpose

e-mail : mpdcgn@gmail.com ♦ For online reports - [www.modernpath.in](http://www.modernpath.in)

♦ Please ask for your computerized bill ♦ Pay only the printed collection charges



# MODERN PATHOLOGY & DIAGNOSTIC CENTRE

Dr. R. P. Rastogi  
M.B.B.S., M.D. (Path & Bact)



## CLINIC :

1/4A, Vineet Khand, (Opp Jaipuria Management)  
Gomti Nagar, Lucknow - 226 010  
Ph.: 0522-4008184, 4308184 ☎ 8112323230  
Mob.: 7618884441, 9450389932, 8177063877

Date	: 24-Aug-2024		
Name	: Mrs. DEEPA YADAV	Age	: 34 Yrs.
Ref.By	: APOLLO HEALTH	Sex	: Female
Plasma Glucose - F GOD-POD Method	91	mg/dl	70 - 110
Plasma Glucose - PP GOD POD Method	<b>102</b>	mg/dl	110 - 170
Blood Group & Rh	"B" Negative		
Serum Bilirubin	0.61	mg%	0.2 - 1.0
Direct Bilirubin	0.24	mg%	0.0 to 0.40
Indirect Bilirubin	0.37	mg%	0.10 to 0.90
SGOT	8	IU/L	UPTO 40
SGPT	11	IU/L	Upto 40
S. Alkaline Phosphatase	216	IU/L	100 - 275
Serum Gamma G.T.	28	IU/L	11 - 50
<b>KFT</b>			
UREA	21.2	mg %	15 - 50
CREATININE	0.75	mg %	0.5 - 1.5
URIC ACID	4.8	mg %	2 - 6
CALCIUM	9.1	mg %	8.8 - 10.0
Urine Sugar (Fasting)	NIL		
Urine Sugar (PP)	NIL		

Dr. Sanjay Rastogi  
M.B.B.S., DCP, CRIAT (BARC)

Dr. Smita Rastogi  
Contd... M.B.B.S., DCP

Results, adhering to W.H.O. and International Federation of Clinical Chemists Quality Control Standards.

SAMPLE COLLECTION FACILITY AVAILABLE

Report needs clinicopathological correlation ♦ Not for Medico Legal Purpose

e-mail : mpdcgn@gmail.com ♦ For online reports - [www.modernpath.in](http://www.modernpath.in)

♦ Please ask for your computerized bill ♦ Pay only the printed collection charges

**CLINIC :**  
1/4A, Vineet Khand, (Opp Jaipuria Management)  
Gomti Nagar, Lucknow - 226 010  
Ph.: 0522-4008184, 4308184 ☎ 8112323230  
Mob.: 7618884441, 9450389932, 8177063877

Date	: 24-Aug-2024		
Name	: Mrs. DEEPA YADAV	Age	: 34 Yrs.
Ref.By	: APOLLO HEALTH	Sex	: Female

### LIPID PROFILE

Triglycerids	69	mg%	70 - 190
S. Cholestrol S.	124	mg%	130 - 230
S. HDL Cholestrol	40.0	mg%	35 - 75
S. LDL Cholestrol	70.2	mg%	75 - 150
VLDL	13.8	mg%	0 - 34
Chol / HDL factor	3.1		
LDL / HDL Factor	1.76		

### COMMENTS

- \* Triglycerides (TG) are the main dietary lipids. Cholesterol constitutes a small part of the dietary lipids, it is mostly synthesised in the liver. Both TG and Chol. are transported through the plasma by lipoproteins (Chylomicrons, VLDL, LDL, IDL, HDL).
- \* LDL is the major cholesterol particle in plasma and high levels are strongly implicated in the formation of atheroma. An increase in the LDL leads to hypercholesterolemia, and therefore a risk factor for IHD. LDL increases with age particularly in females. Oestrogen lower LDL and raise HDL. Raised chol. in females is mostly due to disturbed thyroid function.
- \* Increase in VLDL leads to hyperglyceridaemia. Raised TGs are associated with increased risk of CHD. Very high TGs increase the risk of Pancreatitis. Cholesterol is often raised due to Diabetes, Renal disease, Diuretic or Betablocker therapy.

### TYPES OF HYPERLIPOPROTEINEMIAS

TYPE 1: Normal cholesterol TG greatly raised	TYPE 3: Cholesterol increased TG increased
TYPE 2a: Cholesterol increased LDL increased TG normal	TYPE 4: Cholesterol normal /increased VLDL increased TG increased
TYPE 2b Chol. increased VLDL raised TG increased LDL increased	TYPE 5: Cholesterol increased LDL reduced VLDL increased TG greatly increased

Dr. Sanjay Rastogi  
M.B.B.S., DCP, CRIAT (BARC)

Dr. Smita Rastogi  
M.B.B.S., DCP

Results, adhering to W.H.O. and International Federation of Clinical Chemists Quality Control Standards.

SAMPLE COLLECTION FACILITY AVAILABLE

Report needs clinicopathological correlation ♦ Not for Medico Legal Purpose

e-mail : mpdcgn@gmail.com ♦ For online reports - [www.modernpath.in](http://www.modernpath.in)

♦ Please ask for your computerized bill ♦ Pay only the printed collection charges





# MODERN PATHOLOGY & DIAGNOSTIC CENTRE

Dr. R. P. Rastogi  
M.B.B.S., M.D. (Path & Bact)



**CLINIC :**

1/4A, Vineet Khand, (Opp Jaipuria Management)  
Gomti Nagar, Lucknow - 226 010  
Ph.: 0522-4008184, 4308184 ☎ 8112323230  
Mob.: 7618884441, 9450389932, 8177063877

Date	: 24-Aug-2024		
Name	: Mrs. DEEPA YADAV	Age	: 34 Yrs.
Ref.By	: APOLLO HEALTH	Sex	: Female

### THYROID TEST

Tri-iodothyronine (T3)	1.40	nmol/L	0.50 to 2.50
Thyroxine (T4)	6.56	mcg/dL	5.0 to 12.5
Thyroid Stimulating Hormone (TSH)	2.96	mlU/ ml	0.3 to 6.0

=====

COMMENTS

=====

- 1) Primary hyperthyroidism is accompanied by elevated Serum T3 and T4 values along with depressed TSH levels.
- 2) Primary Hypothyroidism is accompanied by depressed serum T3 and T4 values and elevated serum TSH levels.
- 3) Normal T4 levels accompanied by high T3 levels are seen in patients with T3 thyrotoxicosis.
- 4) Slightly elevated T3 levels may be found in pregnancy and estrogen therapy, while depressed levels maybe encountered in severe illness, malnutrition, renal failure and during therapy with drugs like propranolol and propylthiouracil.
- 5) Elevated TSH levels may also be indicative of TSH secreting Pituitary Tumour.

**Dr. Sanjay Rastogi**  
M.B.B.S., DCP, CRIAT (BARC)

**Dr. Smita Rastogi**  
Contd... M.B.B.S., DCP

Results, adhering to W.H.O. and International Federation of Clinical Chemists Quality Control Standards.

SAMPLE COLLECTION FACILITY AVAILABLE

Report needs clinicopathological correlation ♦ Not for Medico Legal Purpose

e-mail : mpdcgn@gmail.com ♦ For online reports - [www.modernpath.in](http://www.modernpath.in)

♦ Please ask for your computerized bill ♦ Pay only the printed collection charges



# MODERN PATHOLOGY & DIAGNOSTIC CENTRE

Dr. R. P. Rastogi  
M.B.B.S., M.D. (Path & Bact)



CLINIC :  
1/4A, Vineet Khand, (Opp Jaipuria Management)  
Gomti Nagar, Lucknow - 226 010  
Ph.: 0522-4008184, 4308184 ☎ 8112323230  
Mob.: 7618884441, 9450389932, 8177063877

Date	: 24-Aug-2024	Age	: 34 Yrs.
Name	: Mrs. DEEPA YADAV	Sex	: Female
Ref.By	: APOLLO HEALTH		

## Glycosylated Haemoglobin

Glycosylated Haemoglobin	5.5	%	4.5 TO 6.0
--------------------------	-----	---	------------

### INTERPRETATION AND COMMENTS

NON DIABETIC : 4.5 to 6.0 %  
GOOD CONTROL: 6.0 to 7.0  
FAIR CONTROLLED 7.0 AND 8.0  
UNCONTROLLED 8.0 AND ABOVE

Glycosylated haemoglobin is the adducted glucose in the haemoglobin of the red blood cells, this adduction is stable for the life time of the RBC (i.e 120 days). There fore the measure of glycosylated haemoglobin reflects the average blood glucose concentration over the preseding several weeks. The sudden change in blood glucose level would not effect the glycosylated haemoglobin level ,which serves as a better marker of long term metabolic control and the efficacy of therapy.

Dr. Sanjay Rastogi  
M.B.B.S., DCP, CRIAT (BARC)

Dr. Smity Rastogi  
Contd... M.B.B.S., DCP

Results, adhering to W.H.O. and International Federation of Clinical Chemists Quality Control Standards.

SAMPLE COLLECTION FACILITY AVAILABLE

Report needs clinicopathological correlation ♦ Not for Medico Legal Purpose

e-mail : mpdcgn@gmail.com ♦ For online reports - [www.modernpath.in](http://www.modernpath.in)

♦ Please ask for your computerized bill ♦ Pay only the printed collection charges



# MODERN PATHOLOGY & DIAGNOSTIC CENTRE

**DIAGNOSTIC CENTRE**

Dr. R. P. Rastogi  
M.B.B.S., M.D. (Path & Bact)



**CLINIC :**

1/4A, Vineet Khand, (Opp Jaipuria Management)  
Gomti Nagar, Lucknow - 226 010  
Ph.: 0522-4008184, 4308184 ☎ 8112323230  
Mob.: 7618884441, 9450389932, 8177063877

Date	: 24-Aug-2024		
Name	: <b>Mrs. DEEPA YADAV</b>	Age	: 34 Yrs.
Ref.By	: APOLLO HEALTH	Sex	: Female

### Urine Examination

<b>PHYSICAL</b>			
Colour	Straw		
Turbidity	Nil		
Deposit	Nil		
Reaction	Acidic		
*Specific Gravity	1.020		
<b>CHEMICAL</b>			
Protein	Nil		
Sugar	Nil		
*Bile Salts	Nil		
*Bile Pigments	Nil		
Phosphate	Nil		
<b>MICROSCOPIC</b>			
Pus Cells	Nil	/hpf	
Epithelial Cells	Few	/hpf	
Red Blood Cells	Nil	/hpf	
Casts	Nil		
Crystals	Nil		
Others	Nil		

**Dr. Sanjay Rastogi**  
M.B.B.S., D.C.P. (BARC)

**Dr. Smita Rastogi**  
M.B.B.S., DCP

Results, adhering to W.H.O. and International Federation of Clinical Chemists Quality Control Standards.

SAMPLE COLLECTION FACILITY AVAILABLE

Report needs clinicopathological correlation ♦ Not for Medico Legal Purpose

e-mail : [mpdcgn@gmail.com](mailto:mpdcgn@gmail.com) ♦ For online reports - [www.modernpath.in](http://www.modernpath.in)

♦ Please ask for your computerized bill ♦ Pay only the printed collection charges



# MODERN PATHOLOGY & DIAGNOSTIC CENTRE

Dr. R. P. Rastogi  
M.B.B.S., M.D. (Path & Bact)



**CLINIC :**  
1/4A, Vineet Khand, (Opp Jaipuria Management)  
Gomti Nagar, Lucknow - 226 010  
Ph.: 0522-4008184, 4308184 ☎ 8112323230  
Mob.: 7618884441, 9450389932, 8177063877

SAMPLE DATE	: 24/08/2024
NAME	: Mrs Deepa yadav
AGE/SEX	: 34/YRS/FEMALE
REFERRED BY	: Apollo Health .

Test Name	Result	Bio. Ref. Range	Unit
-----------	--------	-----------------	------

## CLINICAL PATHOLOGY TEST REPORT

PAP

**GROSS:**

Smears collected from the ecto and the endo cervix. Slides prepared and stained with PAP stain.

**MICROSCOPIC:**

Smears studied show adequate representing material, comprising mainly of squamous epithelial cells. These cells have abundant pale pink eosinophilic cytoplasm and normal appearing round to oval nuclei. Smears from the endocervix show fair number of "stripped nuclei" of the endometrial cells. Occasional small cluster of the endometrial cells are seen. These cells have indistinct cellular borders, scanty basophilic cytoplasm and oval nuclei with clumped chromatin. Smears from both the sites are mildly infiltrated with inflammatory cells, mostly polymorphs

**IMPRESSION:** SMEARS SUGGESTIVE OF NORMAL PAP SMEAR WITH MODERATE INFLAMMATION

\*\*\* End Of Report \*\*\*

**Dr. Sanjay Rastogi**  
M.B.B.S., DCP, CRIAT (BARC)

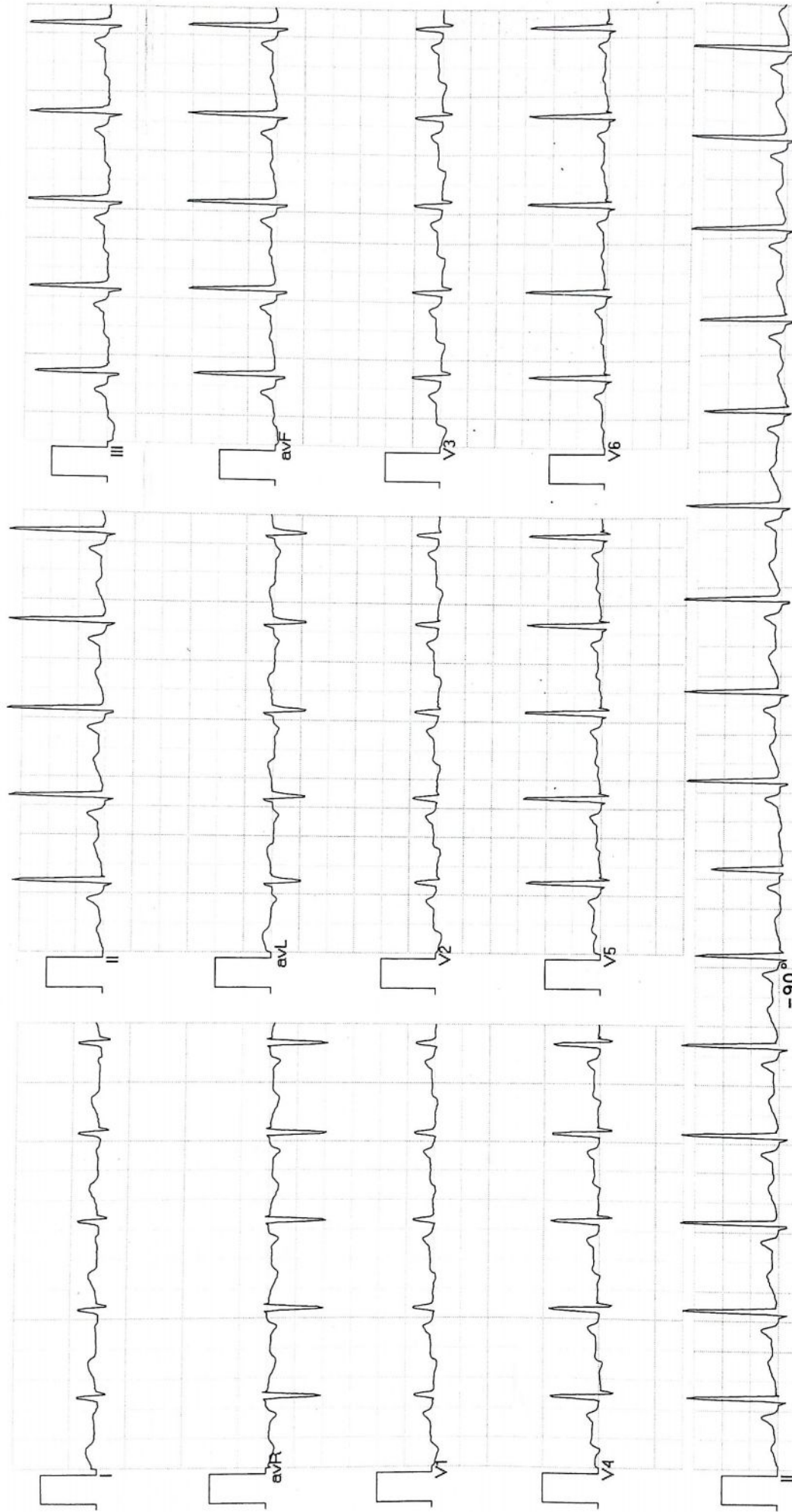
**Dr. Smita Rastogi**  
M.B.B.S., DCP

Results, adhering to W.H.O. and International Federation of Clinical Chemists Quality Control Standards.  
SAMPLE COLLECTION FACILITY AVAILABLE

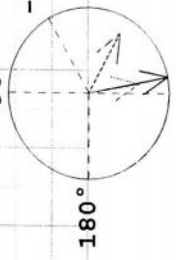
Report needs clinicopathological correlation ♦ Not for Medico Legal Purpose

e-mail : mpdcgn@gmail.com ♦ For online reports - [www.modernpath.in](http://www.modernpath.in)

♦ Please ask for your computerized bill ♦ Pay only the printed collection charges.



Vent Rate : 97 bpm  
 PR Interval : 144 ms  
 QRS Duration: 70 ms  
 QT/QTc Int : 342/407 ms  
 P-QRS-T axis: 80.00 • 79.00 • 29.00 •



*Normal ECG*

Axis  
 90° R 79° T 29° P 80°

*[Signature]*  
 DR. AMIT MOHAN MD  
 Reg. No. 44559



# MODERN PATHOLOGY & DIAGNOSTIC CENTRE

Dr. R. P. Rastogi  
M.B.B.S., M.D. (Path & Bact)



**CLINIC :**

1/4A, Vineet Khand, (Opp Jaipuria Management)  
Gomti Nagar, Lucknow - 226 010  
Ph.: 0522-4008184, 4308184 • 8112323230  
Mob : 7618884441, 9450389932, 8177069877



TEST REQUEST ID :012408240031	SAMPLE DATE	:24/Aug/2024 09:38AM
NAME :Mrs. DEEPA YADAV	SAMPLE REC. DATE	:24/Aug/2024 09:38AM
AGE/SEX :34 YRS/FEMALE	REPORTED DATE	:24/Aug/2024 11:26AM
REFERRED BY : Apollo Health and Lifestyle Limited,	BARCODE NO	:01240031

## USG WHOLE ABDOMEN-FEMALE

**Liver:** is normal in size ( 107 mm). Parenchymal echogenicity is normal. No focal echovariant lesion is seen. Intrahepatic biliary radicles are not dilated.

**Gall Bladder:** is well distended. Lumen is anechoic. Wall is of normal thickness.

**CBD:** is normal in diameter. Portal vein is normal in diameter.

**Pancreas:** is normal in size, shape and echotexture. No focal echovariant lesion is seen. Pancreatic duct is not dilated.

**Spleen:** is normal in size ( 64 mm), shape and echotexture. No focal echovariant lesion is seen. Splenic vein is normal.

**Right Kidney:** is normal in size 86x34 mm, shape, position and excursion. Parenchymal echogenicity and echotexture is normal with maintained corticomedullary differentiation. No mass, cyst, or calculi is seen. Pelvicalyceal systems are not dilated. Ureter is not dilated.

**Left Kidney:** is normal in size 79x37 mm, shape, position and excursion. Parenchymal echogenicity and echotexture is normal with maintained corticomedullary differentiation. No mass, cyst, or calculi is seen. Pelvicalyceal systems are not dilated. Ureter is not dilated.



**Dr. Sanjay Rastogi**  
M.B.B.S., DCP, CRIAT (BARC)

*Surbhi*  
**Dr. Surbhi**  
MBBS, MD (Radiodiagnosis)

**Dr. Smita Rastogi**  
M.B.B.S., DCP

Results, adhering to W.H.O. and International Federation of Clinical Chemists Quality Control Standards.

SAMPLE COLLECTION FACILITY AVAILABLE

Report needs clinicopathological correlation ♦ Not for Medico Legal Purpose

Print Date/Time: 24/08/2024 11:26 AM

e-mail : mpdcgn@gmail.com ♦ For online reports - [www.modernpath.in](http://www.modernpath.in)

Checked By: SURBHI

Page 1 of 2

♦ Please ask for your computerized bill ♦ Pay only the printed collection charges



# MODERN PATHOLOGY & DIAGNOSTIC CENTRE

Dr. R. P. Rastogi  
M.B.B.S., M.D. (Path & Bact)



**CLINIC :**

1/4A, Vineet Khand, (Opp Jaipuria Management)  
Gomti Nagar, Lucknow - 226 010  
Ph.: 0522-4008184, 4308184 • 8112323230  
Mob.: 7618884441, 9450389932, 8177060977



TEST REQUEST ID :012408240031	SAMPLE DATE	:24/Aug/2024 09:38AM
NAME :Mrs. DEEPA YADAV	SAMPLE REC. DATE	:24/Aug/2024 09:38AM
AGE/SEX :34 YRS/FEMALE	REPORTED DATE	:24/Aug/2024 11:26AM
REFERRED BY : Apollo Health and Lifestyle Limited,	BARCODE NO	:01240031

**Urinary bladder:** is well distended. Lumen is anechoic. Wall is of normal thickness. No mass or calculus is seen.

**Uterus:** is normal in size ( 41x45x85 mms), shape and echotexture. It is anteverted. Myometrium is homogenous. No focal mass is seen. Endometrial thickness is normal 5.3 mm. Cervix appears normal in size 19.6 mm, shape and echotexture. No evidence of collection in cervical canal.

**Bilateral Ovaries and adnexae:** Both ovaries are normal in size (RO - 18x24x26 mms vol 6.2 cc & LO - 16x22x25 mms vol 4.8 cc), shape and echotexture. No adnexal solid or cystic mass lesion is seen.

Both iliac fossae are clear. No obvious bowel pathology is noted. There is no free fluid in peritoneal cavity.

**OPINION:**

- **NORMAL STUDY.**

\*\*\* End Of Report \*\*\*



**Dr. Sanjay Rastogi**  
M.B.B.S., DCP, CRIAT (BARC)

*Surbhi*  
**Dr. Surbhi**  
MBBS, MD (Radiodiagnosis)

**Dr. Smita Rastogi**  
M.B.B.S., DCP

Results, adhering to W.H.O. and International Federation of Clinical Chemists Quality Control Standards.

SAMPLE COLLECTION FACILITY AVAILABLE

Report needs clinicopathological correlation ♦ Not for Medico Legal Purpose

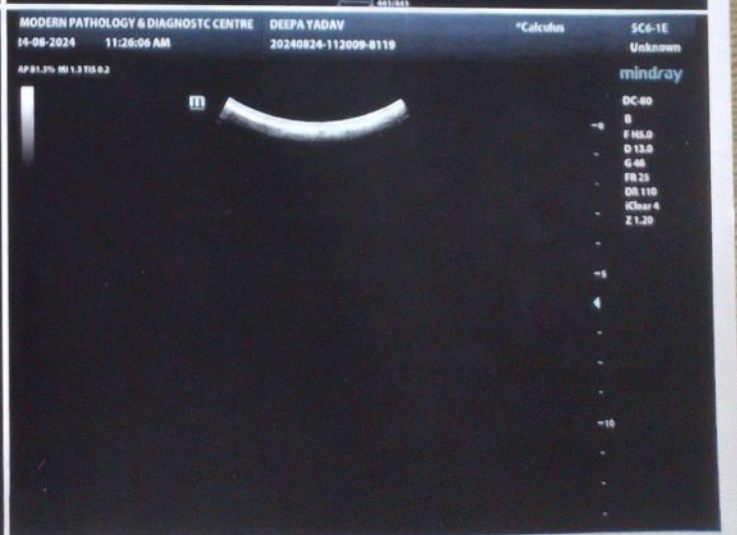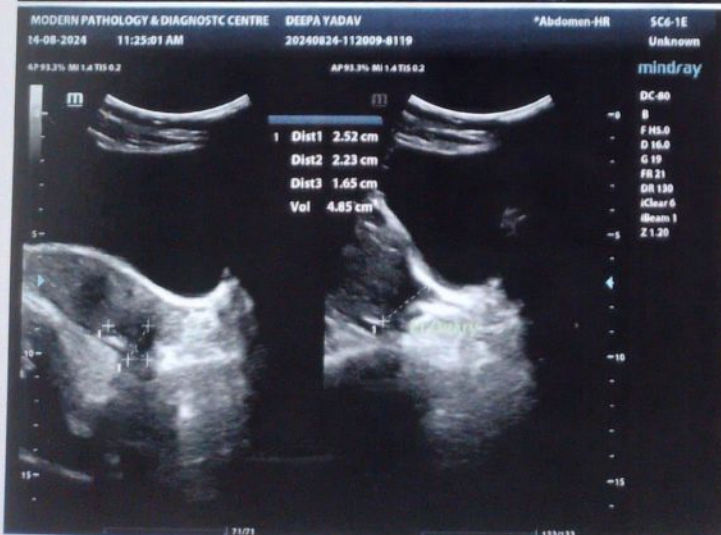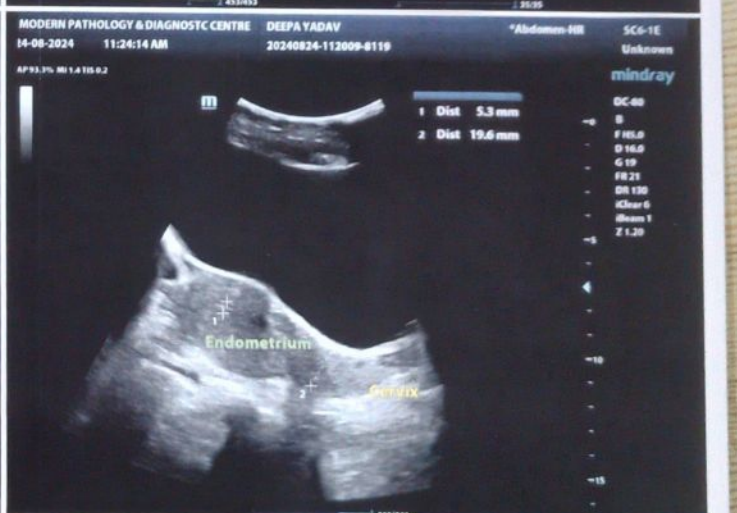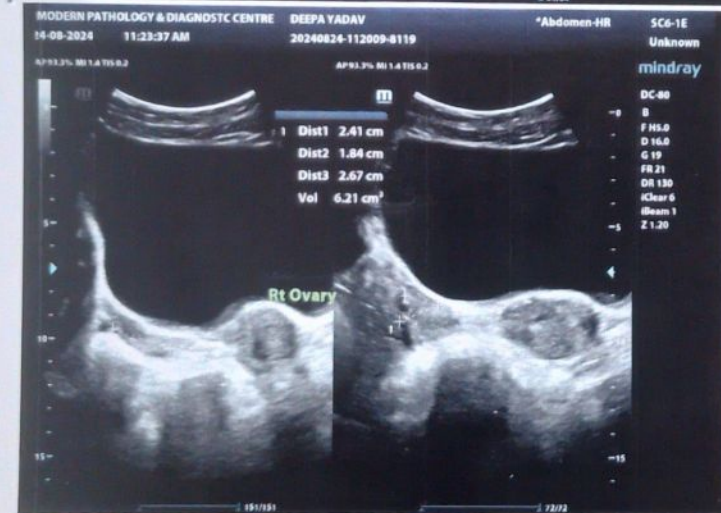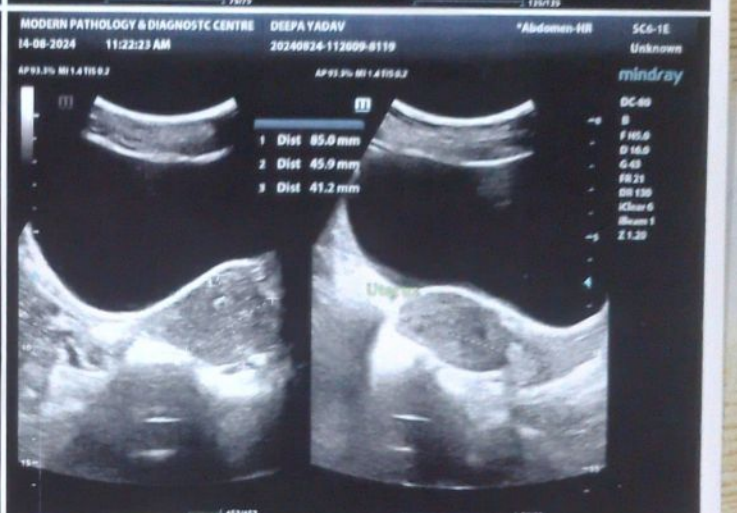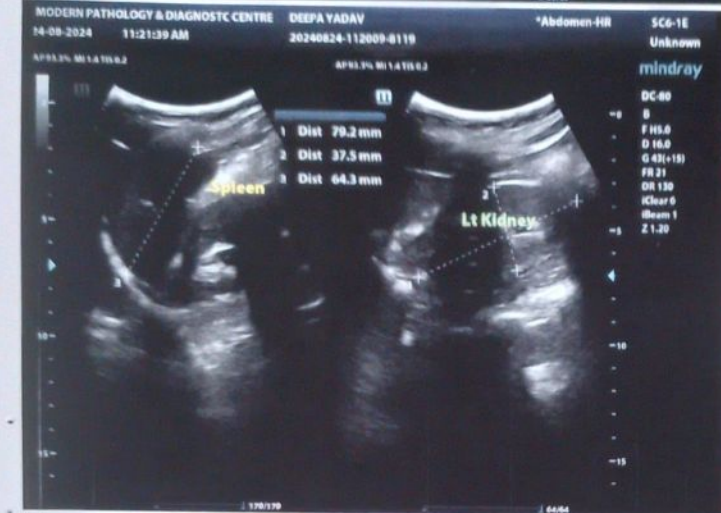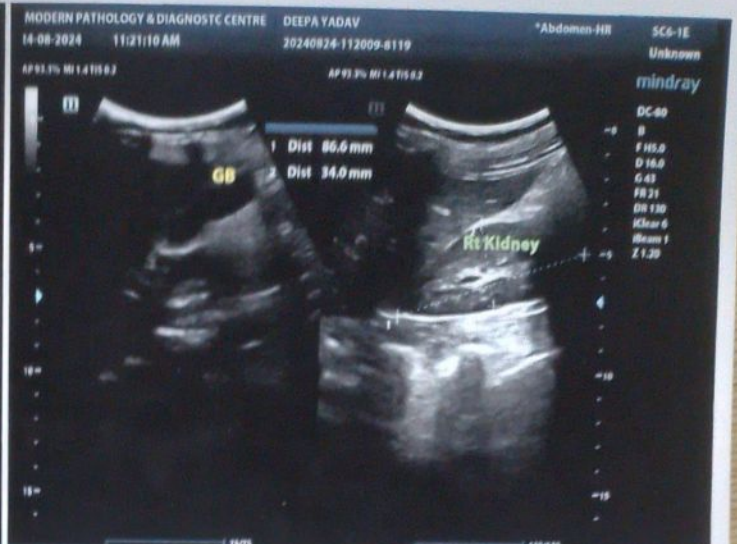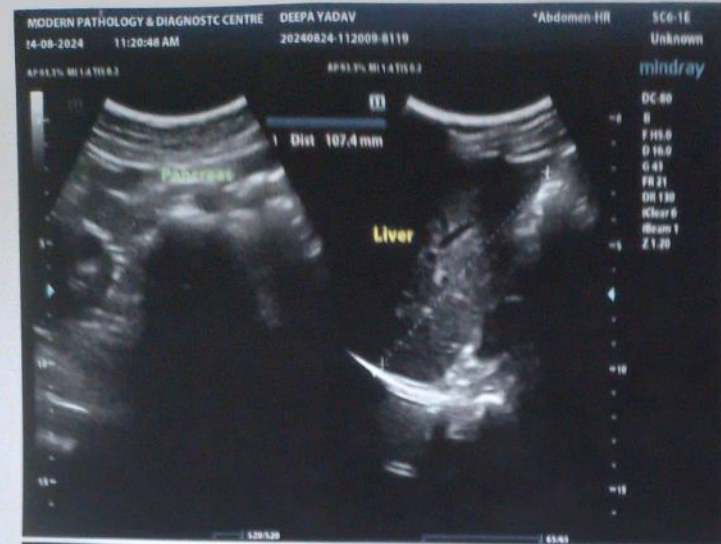Print Date/Time: 24/08/2024 11:26 AM

e-mail : mpdcgn@gmail.com ♦ For online reports - [www.modernpath.in](http://www.modernpath.in)

Page 2 of 2

♦ Please ask for your computerized bill ♦ Pay only the printed collection charges

# MODERN PATHOLOGY & DIAGNOSTIC CENTRE





MODERN PATHOLOGY AND DIAGNOSTIC CENTER

Gomti Nagar Lucknow



Report

DEEPA YADAV / 34 Yrs / F / 146 Cms / 44 Kg  
 Date: 24 - 08 - 2024 Refd By : APOLLO HEALTH Examined By:

Stage	Time	Duration	Speed(Kmph)	Elevation	METs	Rate	% THR	BP	RPP	PVC	Comments
Supine	00:04	0:04	00.0	00.0	01.0	094	51 %	110/70	103	00	
Standing	00:08	0:04	00.0	00.0	01.0	094	51 %	110/70	103	00	
HV	00:12	0:04	00.0	00.0	01.0	097	52 %	110/70	106	00	
ExStart	00:21	0:09	00.0	00.0	01.0	097	52 %	110/70	106	00	
BRUCE Stage 1	03:21	3:00	02.7	10.0	04.7	149	80 %	126/80	187	00	
BRUCE Stage 2	06:21	3:00	04.0	12.0	07.1	167	90 %	134/86	223	00	
PeakEx	07:36	1:15	05.5	14.0	08.4	179	96 %	138/90	247	00	
Recovery	08:36	1:00	00.0	00.0	01.2	140	75 %	136/86	190	00	
Recovery	09:36	2:00	00.0	00.0	01.0	118	63 %	130/82	153	00	
Recovery	10:36	3:00	00.0	00.0	01.0	115	62 %	124/80	142	00	
Recovery	10:54	3:18	00.0	00.0	01.0	109	59 %	122/80	132	00	

**FINDINGS :**

Exercise Time : 07:15  
 Max HR Attained : 179 bpm 96% of Target 186  
 Max BP Attained : 138/90 (mm/Hg)  
 Max WorkLoad Attained : 8.4 Fair response to induced stress  
 Test End Reasons : Test Complete, Fatigue

**REPORT :**

CONCLUSIONS:

1. STRESS TEST IS NEGATIVE FOR EXERCISE INDUCED ISCHAEMIC HEART DISEASE.

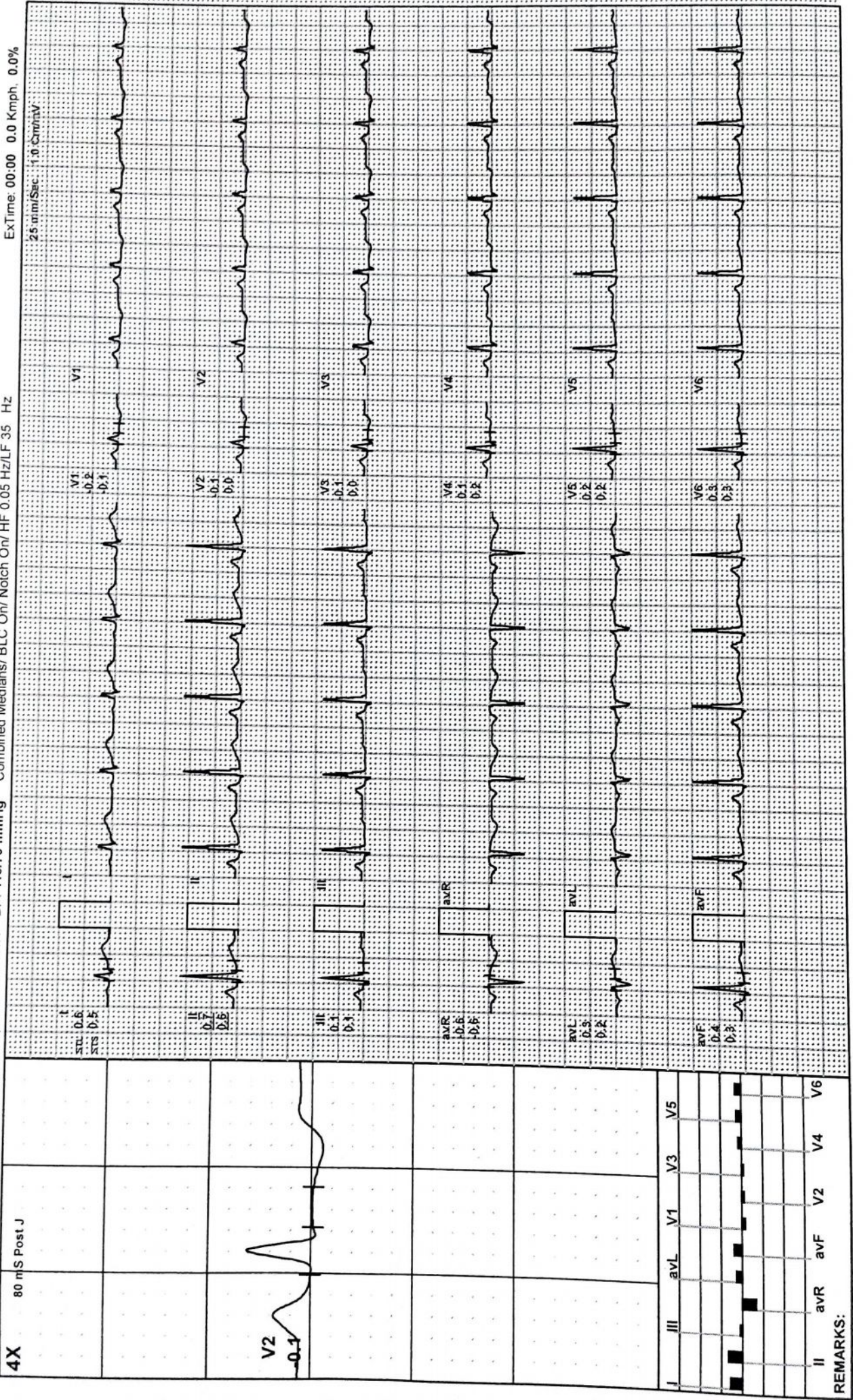
Dr. AMN MOHAN  
 MD  
 Reg. No. 44559



Date: 24 - 08 - 2024

METS: 1.0 / 94 bpm 51% of THR BP: 110/70 mmHg Combined Medians/ BLC On/ Notch On/ HF 0.05 Hz/LF 35 Hz

ExTime: 00:00 0.0 Km/h 0.0%



I	II	III	aVR	aVL	aVF	V1	V2	V3	V4	V5	V6
<input type="checkbox"/>	<input type="checkbox"/>	<input type="checkbox"/>	<input type="checkbox"/>	<input type="checkbox"/>	<input type="checkbox"/>	<input type="checkbox"/>	<input type="checkbox"/>	<input type="checkbox"/>	<input type="checkbox"/>	<input type="checkbox"/>	<input type="checkbox"/>

REMARKS:

**MODERN PATHOLOGY AND DIAGNOSTIC CENTER**

DEEPA YADAV / 34 Yrs / F / 146 Cms / 44 Kg / HR : 94

**BRUCE:Standing(0:04)**

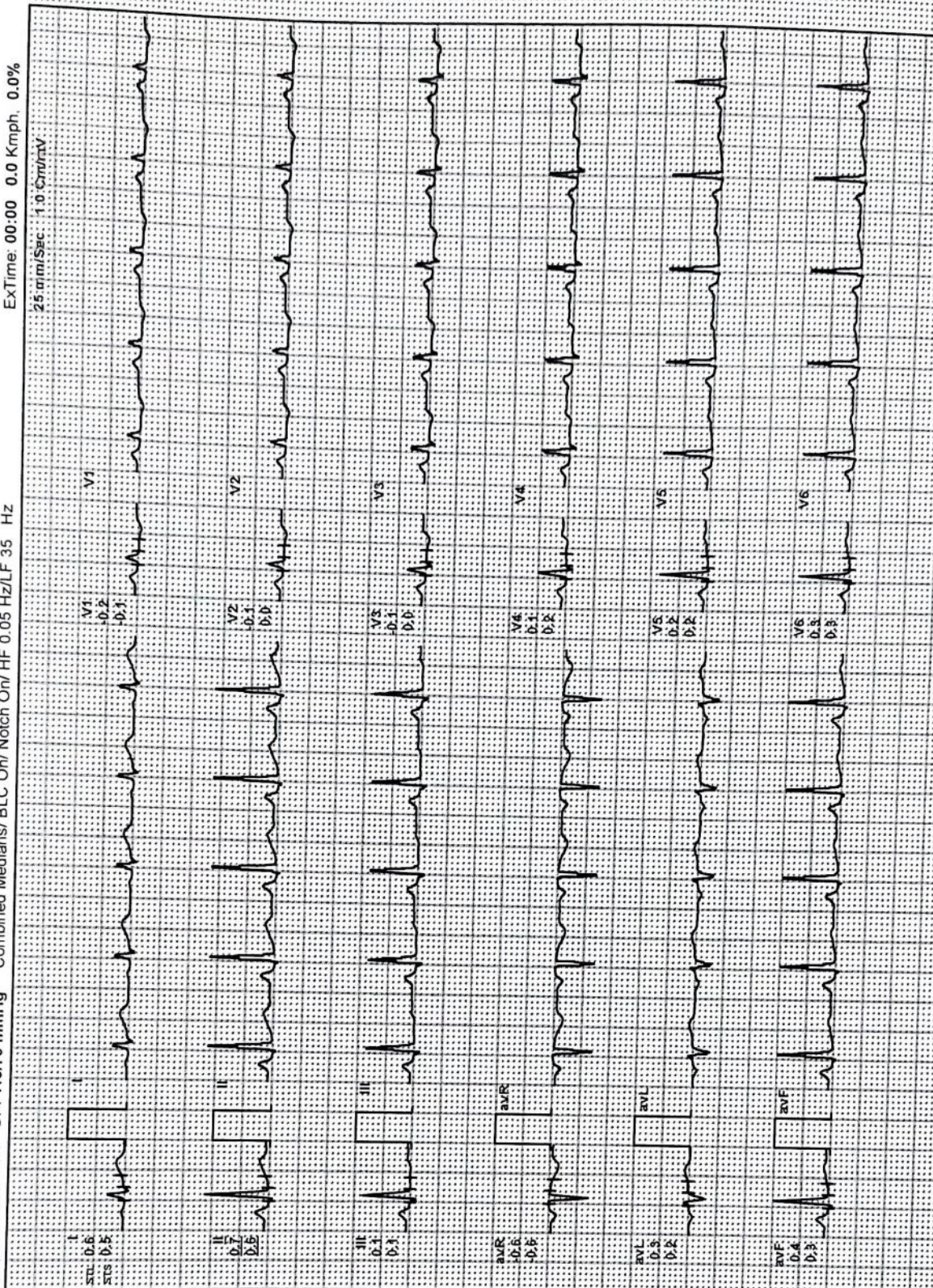


Date: 24 - 08 - 2024

METS: 1.0/ 94 bpm 51% of THR    BP: 110/70 mmHg    Combined Medians/ BLC On/ HF 0.05 Hz/LF 35 Hz

ExTime: 00:00    0.0 Kmph.    0.0%

25.0mm/Sec.    1.0 Cm/mV



<b>4X</b> 80 mS Post J			<b>V2</b> 0.4					
I	II	III	aVR	aVL	aVF	V1	V2	V3
V4	V5	V6	II	avR	avF	V4	V5	V6
<b>REMARKS:</b>								

**MODERN PATHOLOGY AND DIAGNOSTIC CENTER**

DEEPA YADAV / 34 Yrs / F / 146 Cms / 44 Kg / HR : 97

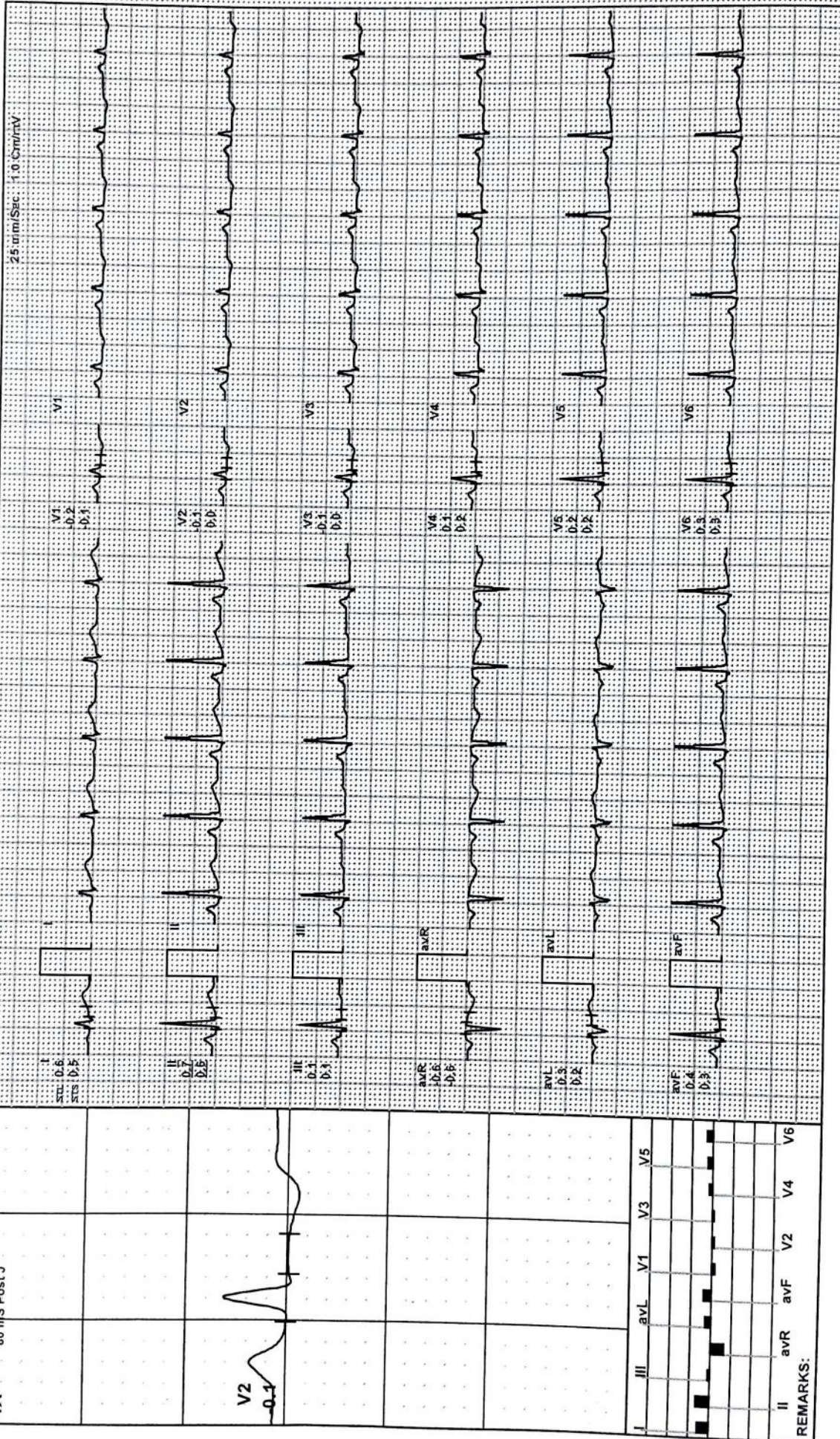
BRUCE:HV(0:06)



Date: 24 - 08 - 2024

METS: 1.0/ 97 bpm 52% of THR BP: 110/70 mmHg Combined Medians/ BLC On/ HF 0.05 Hz/LF 35 Hz

ExTime: 00:00 0.0 Kmph, 0.0%



REMARKS:

**MODERN PATHOLOGY AND DIAGNOSTIC CENTER**

DEEPA YADAV / 34 Yrs / F / 146 Cms / 44 Kg / HR : 97

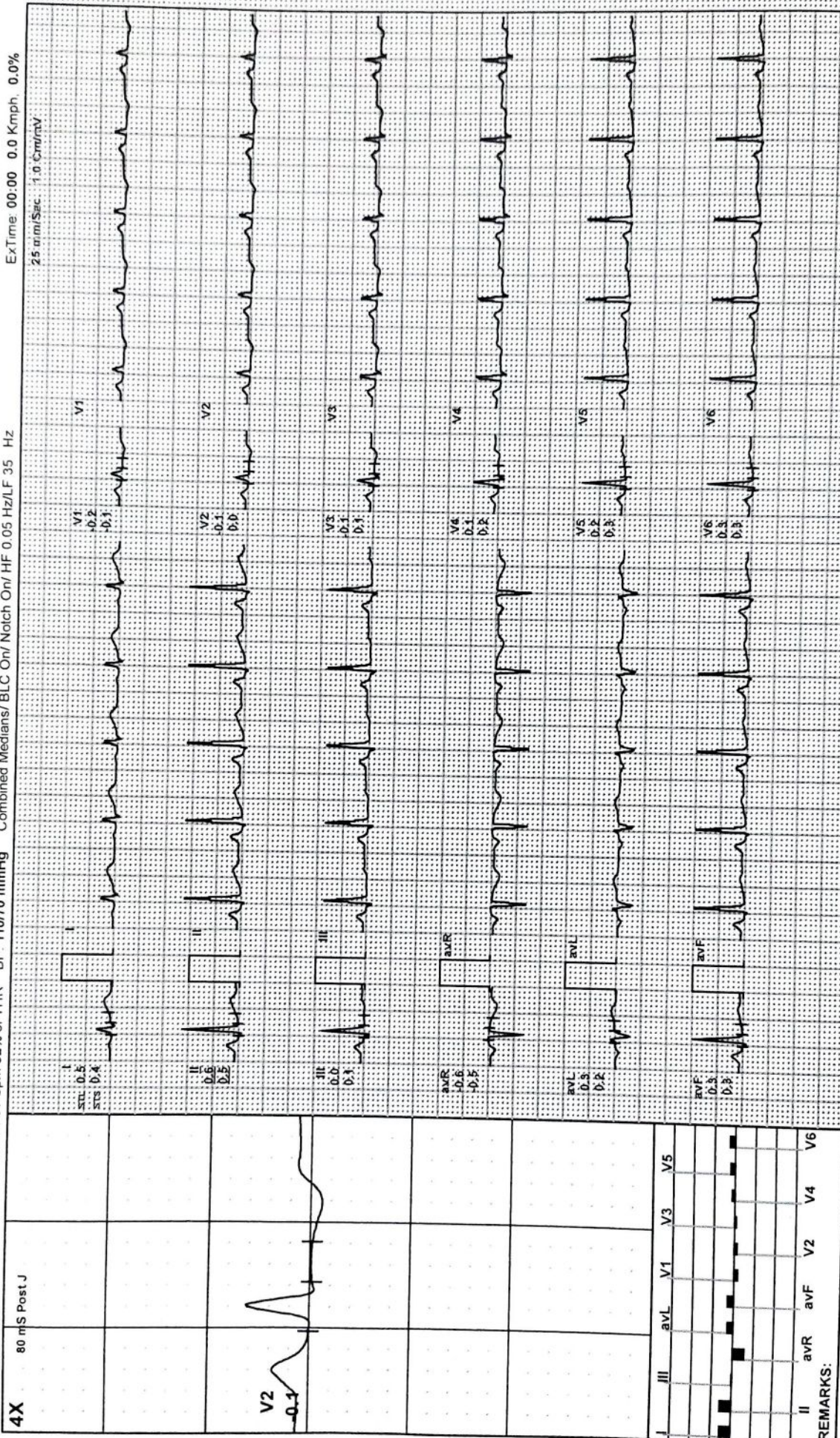
ExStart



Date: 24 - 08 - 2024

METS: 1.0/ 97 bpm 52% of THR BP: 110/70 mmHg Combined Medians/ BLC On/ HF 0.05 Hz/LF 35 Hz

ExTime: 00:00 0.0 KmPh. 0.0%  
25 mm/Sec. 1.0 Cm/mV



4X

80 mS Post J

V2

0.1

	I	II	III	aVR	aVL	aVF	V1	V2	V3	V4	V5	V6
ST-T	0.5	0.6	0.0	0.6	0.3	0.3	0.2	0.1	0.1	0.2	0.2	0.3
ST-S	0.2	0.1	0.1	0.1	0.1	0.2	0.2	0.1	0.1	0.2	0.2	0.3
ST-X	0.1	0.1	0.1	0.1	0.1	0.2	0.2	0.1	0.1	0.2	0.2	0.3

REMARKS:

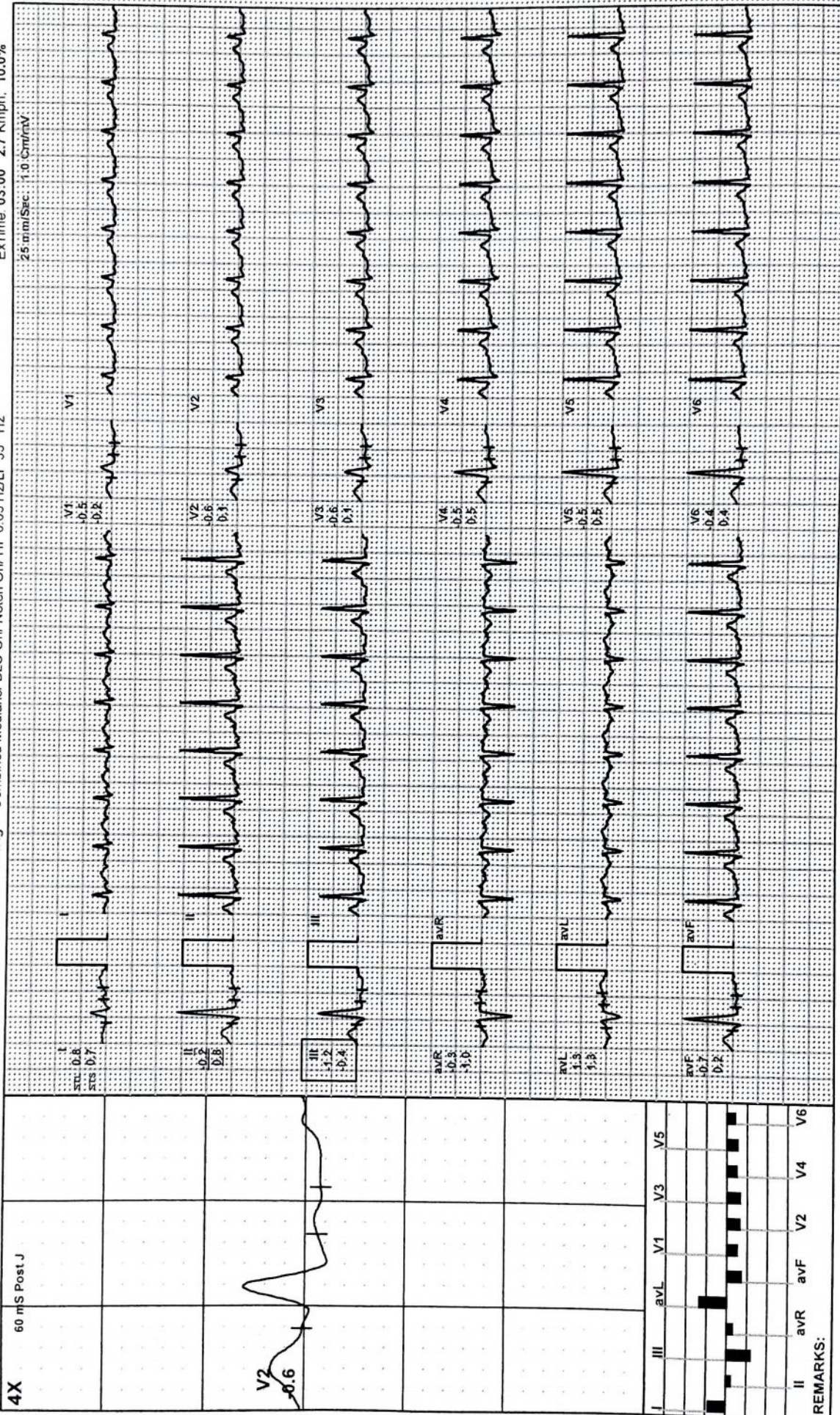
**MODERN PATHOLOGY AND DIAGNOSTIC CENTER**

DEEPA YADAV / 34 Yrs / F / 146 Cms / 44 Kg / HR : 149

**BRUCE: Stage 1(3:00)**



Date: 24 - 08 - 2024 METS: 4.7/ 149 bpm 80% of THR BP: 126/80 mmHg Combined Medians/ BLC On/ HF 0.05 Hz/LF 35 Hz ExTime: 03:00 2.7 Kmph, 10.0%



**MODERN PATHOLOGY AND DIAGNOSTIC CENTER**

DEEPA YADAV / 34 Yrs / F / 146 Cms / 44 Kg / HR : 167

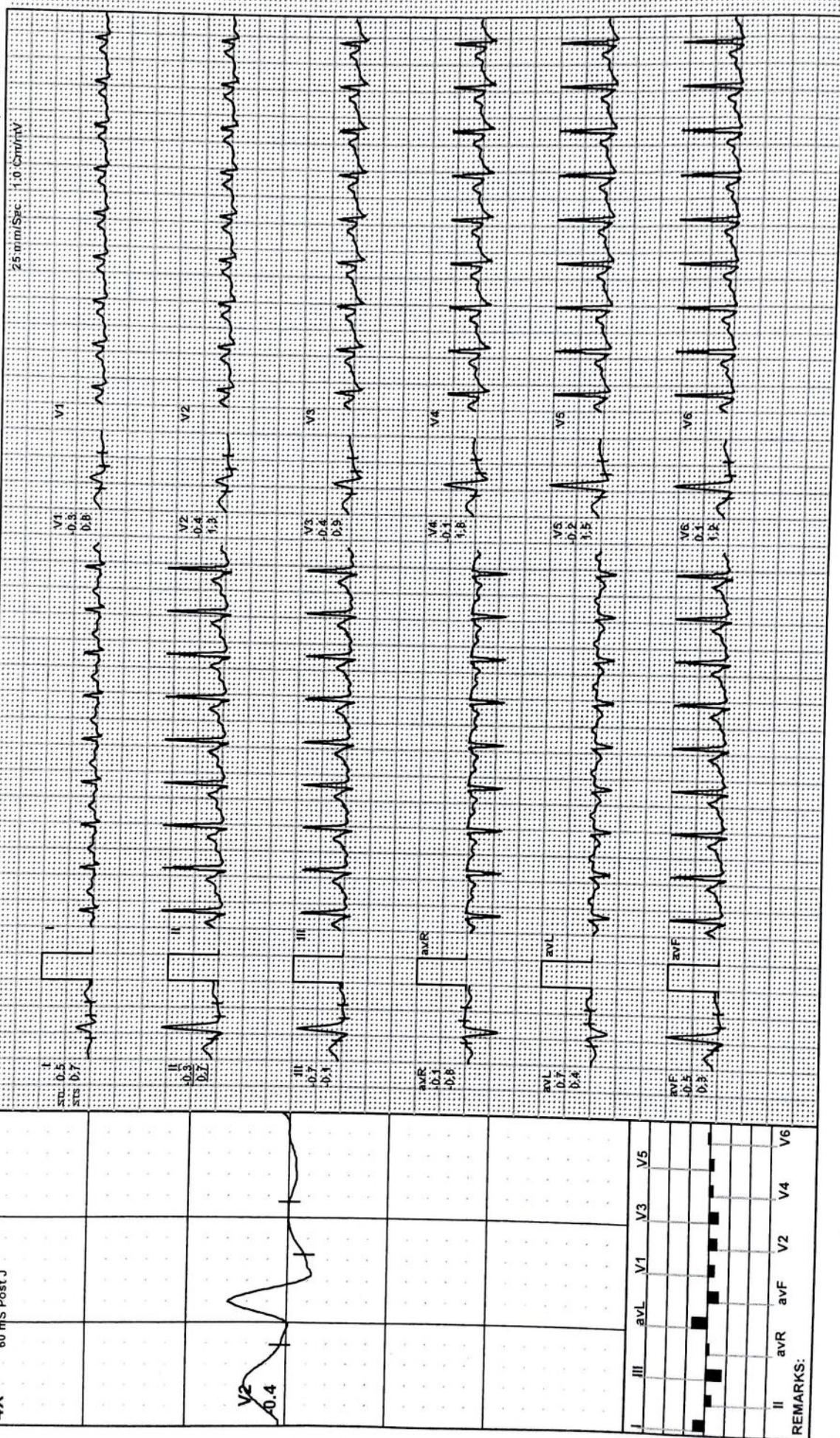
**BRUCE: Stage 2(3:00)**



Date: 24 - 08 - 2024

METS: 7.1/ 167 bpm 90% of THR BP: 134/86 mmHg Combined Medians/ BLC On/ Notch On/ HF 0.05 Hz/LF 35 Hz

ExTime: 06:00 4.0 Kmph. 12.0%



REMARKS:

**MODERN PATHOLOGY AND DIAGNOSTIC CENTER**

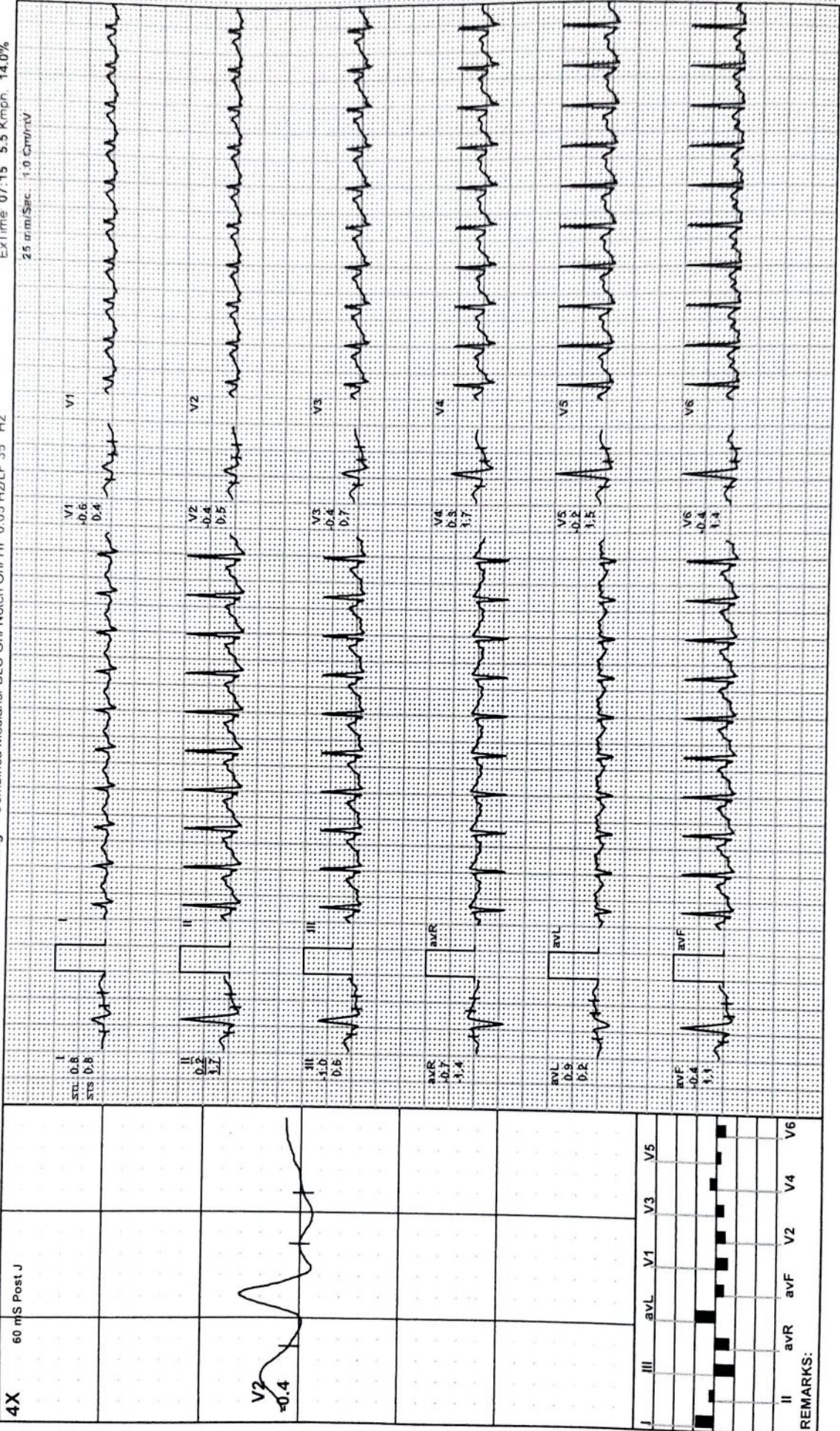
DEEPA YADAV / 34 Yrs / F / 146 Cms / 44 Kg / HR : 179



Date: 24 - 08 - 2024

METS: 8.4 / 179 bpm 96% of THR BP: 138/90 mmHg Combined Medians/ BLC On/ Notch On/ HF 0.05 Hz/LF 35 Hz

ExTime 07:15 5.5 Kmph 14.0%



Lead	I	II	III	aVR	aVL	aVF	V1	V2	V3	V4	V5	V6
ST-T												
ST-S												

REMARKS:



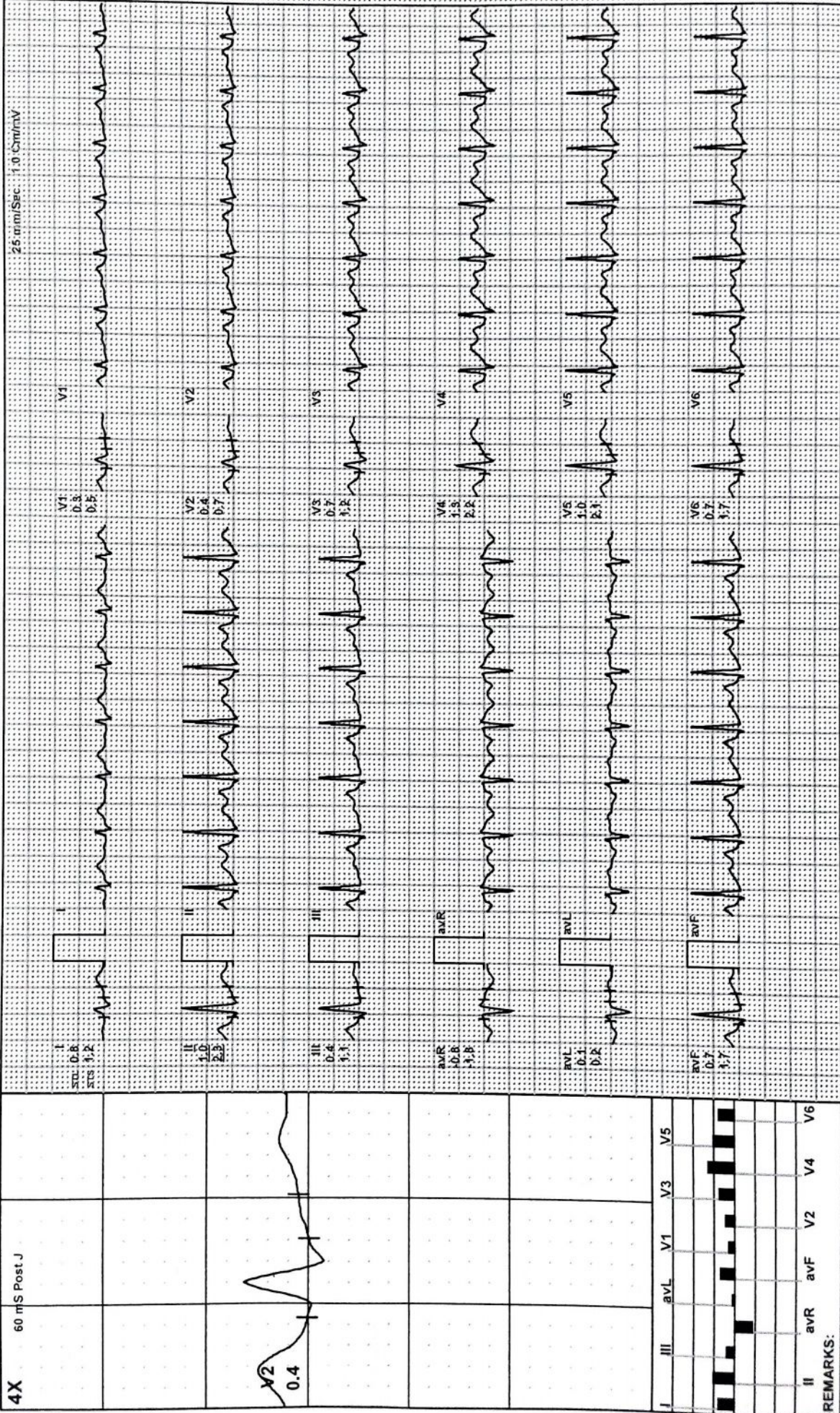
**MODERN PATHOLOGY AND DIAGNOSTIC CENTER**

DEEPA YADAV / 34 Yrs / F / 146 Cms / 44 Kg / HR : 140

Recovery(1:00)



Date: 24 - 08 - 2024 METS: 1.2/ 140 bpm 75% of THR BP: 136/86 mmHg Combined Medians/ BLC On/ Notch On/ HF 0.05 Hz/LF 35 Hz ExTime: 07:15 0.0 Kmph. 0.0%



REMARKS:

# MODERN PATHOLOGY AND DIAGNOSTIC CENTER

DEEPA YADAV / 34 Yrs / F / 146 Cms / 44 Kg / HR : 118

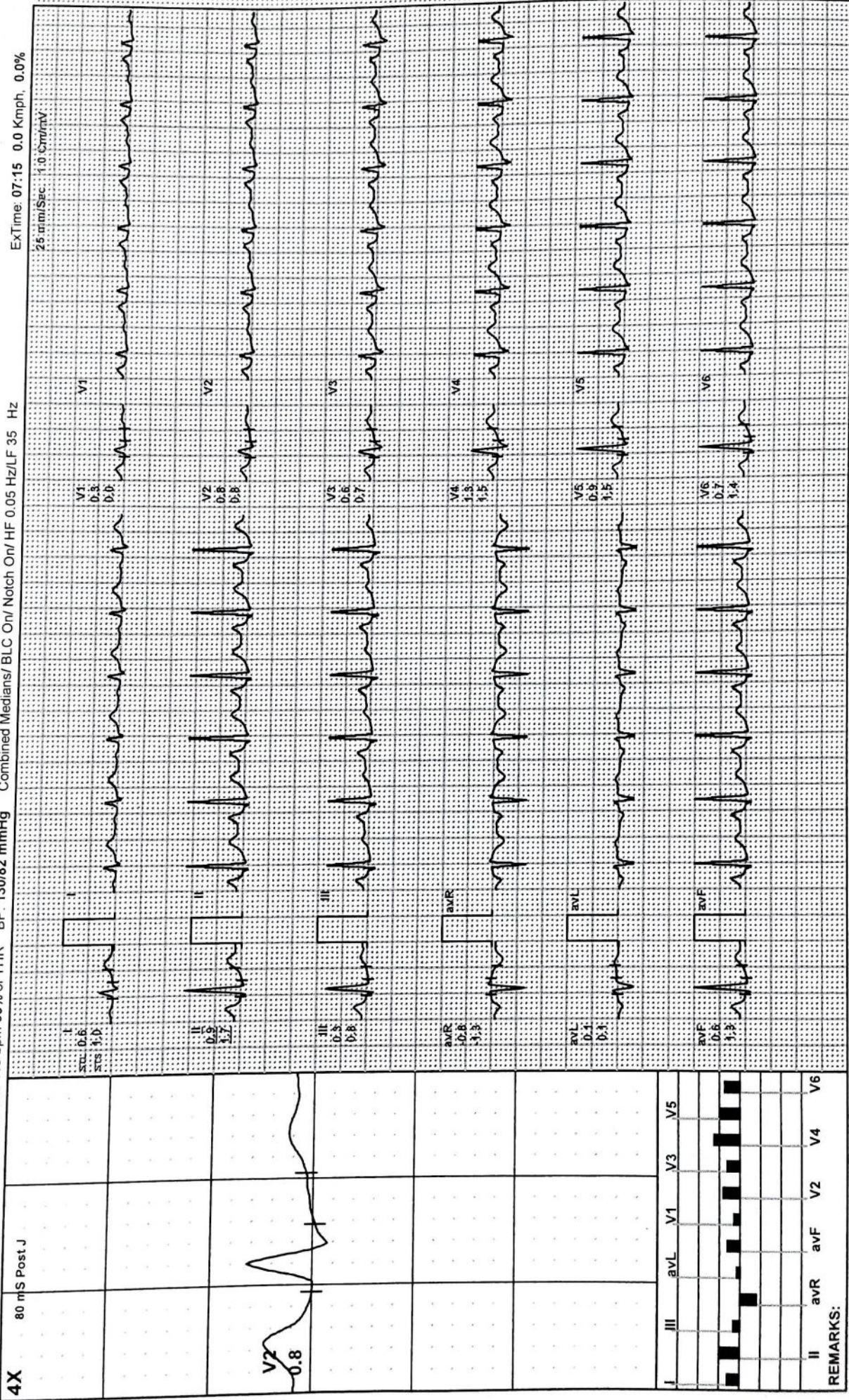
Recovery(2:00)



Date: 24 - 08 - 2024

METS: 1.0/ 118 bpm 63% of THR BP: 130/82 mmHg Combined Medians/ BLC On/ HF 0.05 Hz/LF 35 Hz

ExTime: 07:15 0.0 KmPh, 0.0%



REMARKS:

**MODERN PATHOLOGY AND DIAGNOSTIC CENTER**

DEEPA YADAV / 34 Yrs / F / 146 Cms / 44 Kg / HR : 115

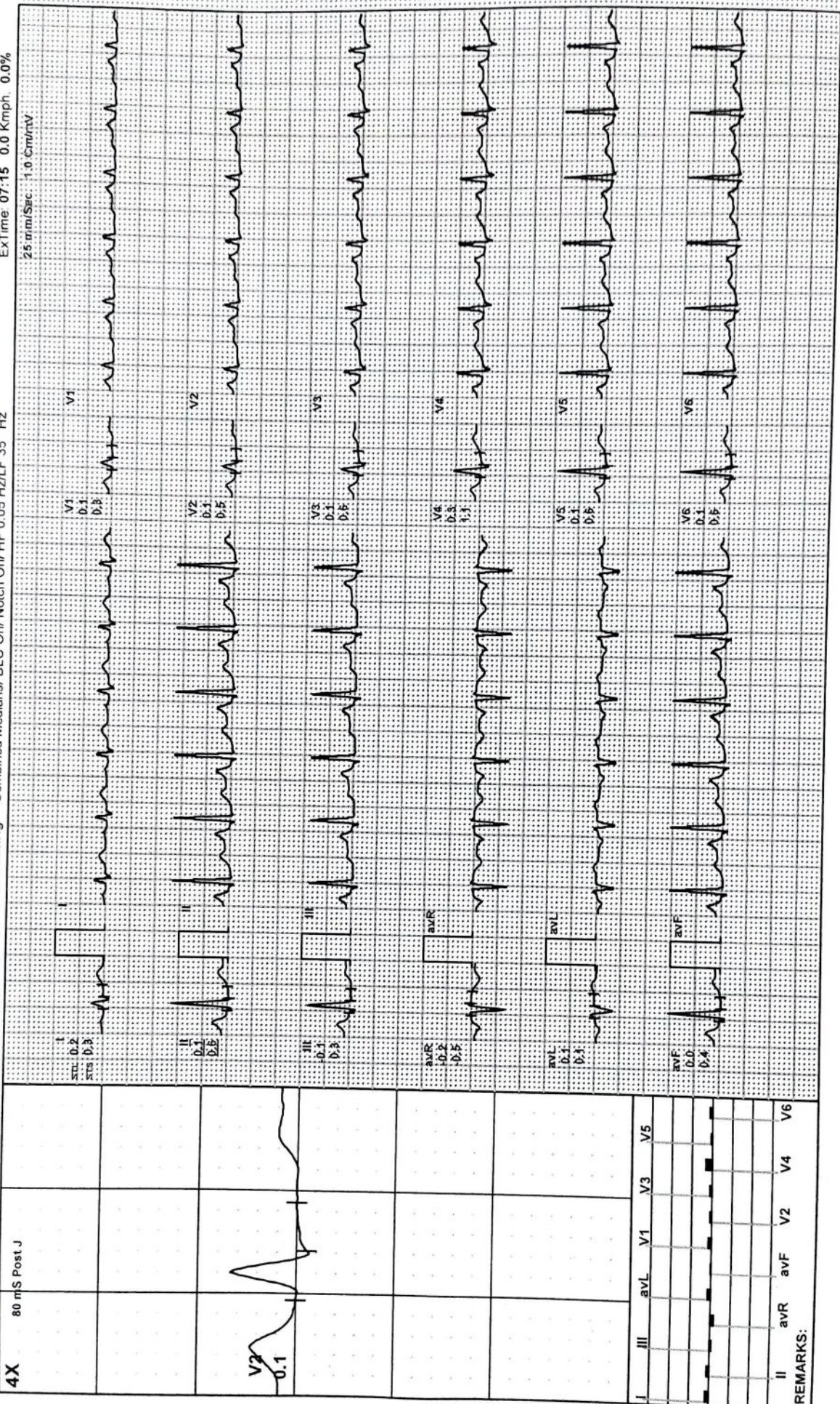
Recovery(3:00)



Date: 24 - 08 - 2024

METS: 1.0/ 115 bpm 62% of THR BP: 124/80 mmHg Combined Medians/ BLC On/ Notch On/ HF 0.05 Hz/LF 35 Hz

EXTime: 07:15 0.0 Kmph 0.0%



REMARKS:

MODERN PATHOLOGY AND DIAGNOSTIC CENTER

DEEPA YADAV / 34 Yrs / F / 146 Cms / 44 Kg / HR : 109

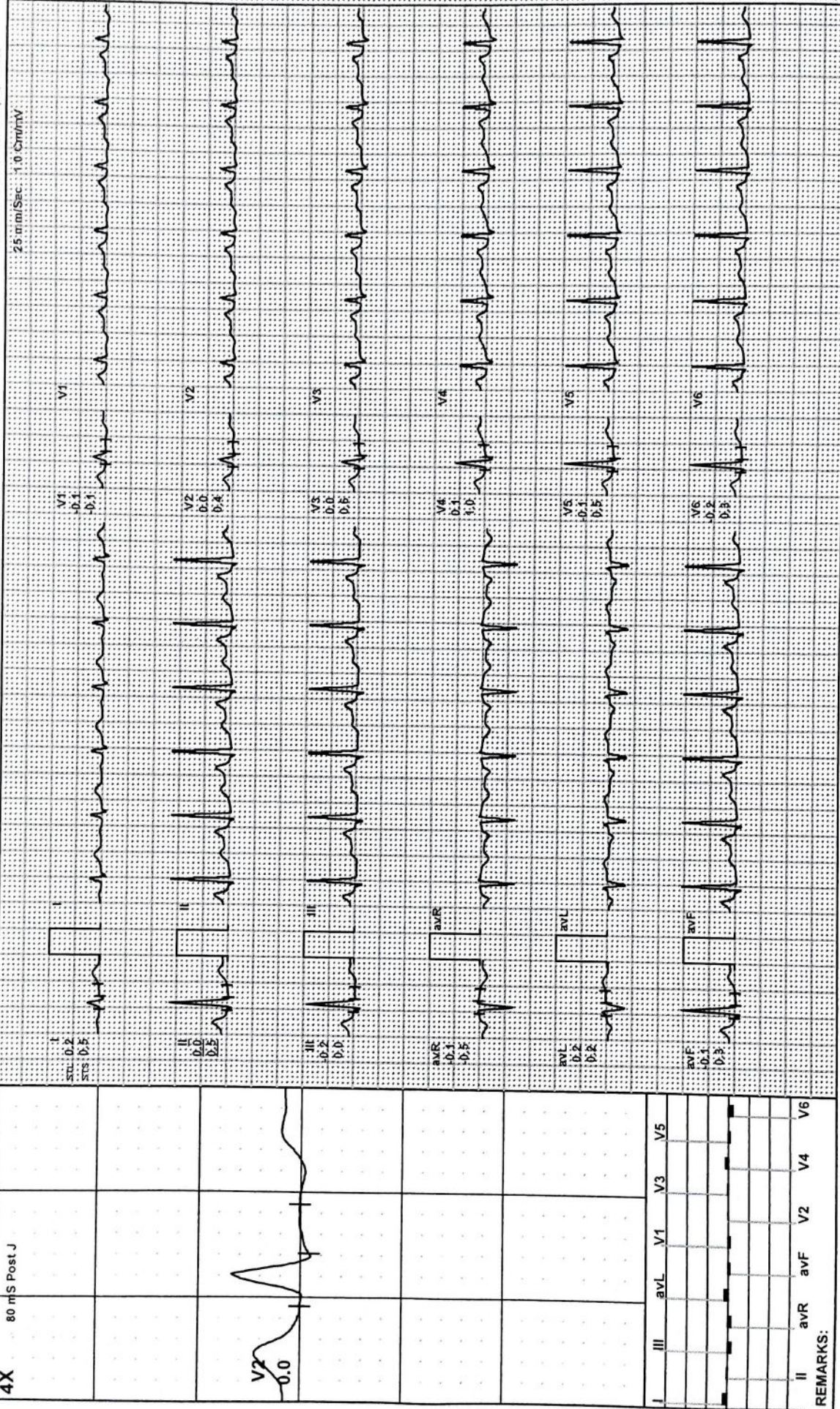
Recovery(3:18)



Date: 24 - 08 - 2024

METS: 1.0/ 109 bpm 59% of THR BP: 122/80 mmHg Combined Medians/ BLC On/ Notch On/ HF 0.05 Hz/LF 35 Hz

ExtTime: 07:15 0.0 Kmph, 0.0%



REMARKS:



# MODERN PATHOLOGY & DIAGNOSTIC CENTRE

Dr. R. P. Rastogi  
M.B.B.S., M.D. (Path & Bact)



**CLINIC :**

1/4A, Vineet Khand, (Opp Jaipuria Management)  
Gomti Nagar, Lucknow - 226 010  
Ph.: 0522-4008184, 4308184 • 8112323230  
Mob.: 7618884441, 9450389932, 8177063877



TEST REQUEST ID :012408240031	SAMPLE DATE	:24/Aug/2024 09:38AM
NAME :Mrs. DEEPA YADAV	SAMPLE REC. DATE	:24/Aug/2024 09:38AM
AGE/SEX :34 YRS/FEMALE	REPORTED DATE	:24/Aug/2024 11:15AM
REFERRED BY : Apollo Health and Lifestyle Limited,	BARCODE NO	:01240031

### XRAY CHEST PA

- Trachea is central in position.
- Bilateral lung fields are normally aerated.
- Both hilar shadows are normal.
- Both C.P. angles are clear.
- Cardiac shadow is within normal limits.
- Bony cage appears normal.

Please correlate clinically.

\*\*\* End Of Report \*\*\*



**Dr. Sanjay Rastogi**  
M.B.B.S., DCP, CRIAT (BARC)

*Surbhi*  
**Dr. Surbhi**  
MBBS, MD (Radiodiagnosis)

**Dr. Smita Rastogi**  
M.B.B.S., DCP

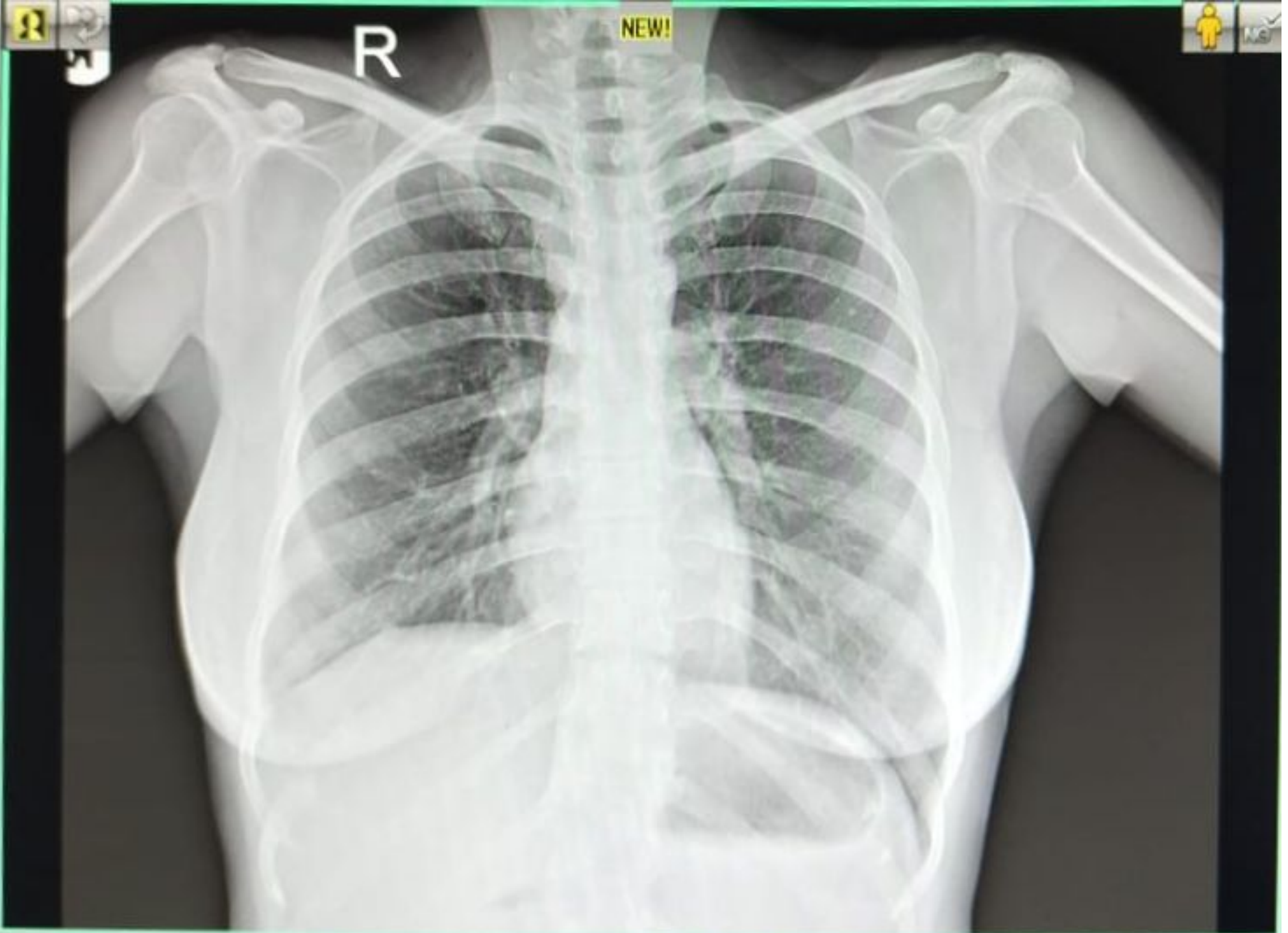
Results, adhering to W.H.O. and International Federation of Clinical Chemists Quality Control Standards.

SAMPLE COLLECTION FACILITY AVAILABLE

Report needs clinicopathological correlation ♦ Not for Medico Legal Purpose

e-mail : mpdcgn@gmail.com ♦ For online reports - [www.modernpath.in](http://www.modernpath.in)

♦ Please ask for your computerized Bill ♦ Pay only the printed collection charges



24082405627 MRS DEEPA YADAV 00YRS F SELF CHEST PA  
08/24/2024 MODERN PATHOLOGY & DIAGNOSTIC CENTRE GOMTI NAGAR LUCKNOW