

SENTINI HOSPITALS

D.No:54-15-5, B&C, Beside Vinayaka Theatre,
Ring Road, Vijayawada - 520 008.Ph:0866-6677869

DEPARTMENT OF BIOCHEMISTRY

Name	: Mrs. BALAMMA .D	Age /Sex	: 53 Y(s)/Female
Bill Date	: 24-Aug-2024 09:03 AM	UMR No.	: UMR2410858
Rept. Dt	: 24-Aug-2024 12:31 PM	Bill No.	: BIL24017266
Ref By	: Dr.GENERAL HEALTH CHECK UP	Result No	: 0 / RES24016664

<u>Parameter</u>	<u>Result</u>	<u>Normal Values</u>
Post Prandial Blood Sugar	: 155 mg/dl	80 - 199 mg/dl

*** End Of Report ***

Lab Tech. Bio-Chemist Lab In-Charge Incharge Pathologist

Correlate Clinically

We use only sterilised disposable syringes & needles.

This report is to help you for better management of patient and not valid for medicolegal purpose.

Discrepancies due to technical or typing errors should be reported within 3 days for correction.

SENTINI HOSPITALS

D.No:54-15-5, B&C, Beside Vinayaka Theatre,
Ring Road, Vijayawada - 520 008.Ph:0866-6677869

DEPARTMENT OF BIOCHEMISTRY

Name	: Mrs. BALAMMA .D	Age /Sex	: 53 Y(s)/Female
Bill Date	: 24-Aug-2024 09:03 AM	UMR No.	: UMR2410858
Rept. Dt	: 24-Aug-2024 11:54 AM	Bill No.	: BIL24017266
Ref By	: Dr.GENERAL HEALTH CHECK UP	Result No	: 0 / RES24016655

<u>Parameter</u>	<u>Result</u>	<u>Normal Values</u>
Fasting Blood Sugar	: 98 mg/dl	70 - 110 mg/dl
HB A1C	: 4.9 %	Non Diabetic : < 6.0 % Good Control : 6.0 - 7.5 % Fair control : 7.5 - 8.5 % Poor Control : > 8.5 %
RFT (RENAL FUNCTION TEST)		
BLOOD UREA	: 16 mg/dl	13 - 45 mg/dl
Serum Creatinine	: * 0.5 mg/dl	0.7 - 1.4 mg/dl
TFT (THYROID FUNCTION TEST)		
T3 (TRI IODO THYRONINE)	: 117 ng/dl	80 - 200 ng/dl
T4 (THYROXINE)	: 7.1 ug/dl	5.1 - 14.1 ug/dl
TSH (THYROID STIMULATING HORMONE)	: 1.7 mIU/l	0.3 - 4.2 mIU/l
LIPID PROFILE		
Fasting Blood Sugar	: 98 mg/dl	70 - 110 mg/dl
Total Cholesterol	: 169 mg/dl	150 - 240 mg/dl
Triglycerides	: * 240 mg/dl	50 - 200 mg/dl
HDL Cholesterol	: 36 mg/dl	
LDL Cholesterol	: 85 mg/dl	80 - 160 mg/dl
VLDL	: 48 mg/dl	10 - 50 mg/dl
Cholesterol / HDL ratio	: 4.7	< 6
LDL / HDL	: 2.4	< 4
LFT(LIVER FUNCTION TEST)		
Total Bilirubin	: 0.3 mg/dl	0.1 - 1.2 mg/dl
Direct Bilirubin	: 0.1 mg/dl	0.0 - 0.3 mg/dl
Indirect Bilirubin	: 0.2 mg/dl	
SGOT	: 22 IU/L	5 - 55 IU/L
SGPT	: 17 IU/L	5 - 55 IU/L
Alkaline Phosphatase	: 104 IU/L	Adult : 35 - 125 IU/L Children : 125 - 330 IU/L
Total Protein	: * 8.6 gm/dl	6.0 - 8.3 gm/dl
Albumin	: 4.4 gm/dl	3.2 - 5.0 gm/dl
Globulin	: * 4.2 gm/dl	2.5 - 3.0 gm/dl
A / G RATIO	: * 1.0	1.51 - 1.81

SENTINI HOSPITALS

D.No: 54-15-5, B&C, Beside Vinayaka Theatre,
Ring Road, Vijayawada - 520 008.Ph:0866-6677869

DEPARTMENT OF BIOCHEMISTRY

Name	: Mrs. BALAMMA .D	Age /Sex	: 53 Y(s)/Female
Bill Date	: 24-Aug-2024 09:03 AM	UMR No.	: UMR2410858
Rept. Dt	: 24-Aug-2024 11:54 AM	Bill No.	: BIL24017266
Ref By	: Dr.GENERAL HEALTH CHECK UP	Result No	: 0 / RES24016655

Parameter

Result

Normal Values

*** End Of Report ***

Lab Tech.

Bio-Chemist

Lab In-Charge

Consultant Pathologist

Correlate Clinically

We use only sterilised disposable syringes & needles.

This report is to help you for better management of patient and not valid for medicolegal purpose.
Discrepancies due to technical or typing errors should be reported within 3 days for correction.

SENTINI HOSPITALS

D.No: 54-15-5, B&C, Beside Vinayaka Theatre,
Ring Road, Vijayawada - 520 008.Ph:0866-6677869

DEPARTMENT OF HAEMATOLOGY

Name	: Mrs. BALAMMA .D	Age /Sex	: 53 Y(s)/Female
Bill Date	: 24-Aug-2024 09:03 AM	UMR No.	: UMR2410858
Rept. Dt	: 24-Aug-2024 11:54 AM	Bill No.	: BIL24017266
Ref By	: Dr.GENERAL HEALTH CHECK UP	Result No	: 0 / RES24016655

<u>Parameter</u>	<u>Results</u>	<u>Normal Values</u>
ESR	: 80 mm/1hour	0 - 15 mm/1hour
CBC (COMPLETE BLOOD COUNT)		
HAEMOGLOBIN	: * 7.5 g/dl	11.5 - 16.0 g/dl
Total WBC Count	: 6,200 cells/cumm	4000 - 11000 cells/cumm
DC COUNT		
Neutrophils	: 57 %	50 - 70 %
Lymphocytes	: 35 %	15 - 40 %
Eosinophils	: 05 %	0 - 7 %
Monocytes	: 03 %	0 - 4 %
Basophils	: 00 %	0 - 1 %
RBC COUNT	: * 2.7 millions/cumm	4.5 - 6.5 millions/cumm
PLATELET COUNT	: 3.5 lakhscells/cumm	1.5 - 4.0 lakhscells/cumm

*** End Of Report ***

Lab Tech.

Bio-Chemist

Lab In-Charge

Consultant Pathologist

Correlate Clinically, We use only sterilised disposable syringes & needles.

Discrepancies due to technical or typing errors should be reported within 3 days for correction.

This report is to help you for better management of patient and not valid for medicolegal purpose.

SENTINI HOSPITALS

D.No: 54-15-5, B&C, Beside Vinayaka Theatre,
Ring Road, Vijayawada - 520 008.Ph:0866-6677869

DEPARTMENT OF PATHOLOGY

Name	: Mrs. BALAMMA .D	Age /Sex	: 53 Y(s)/Female
Bill Date	: 24-Aug-2024 09:03 AM	UMR No.	: UMR2410858
Rept. Dt	: 24-Aug-2024 11:54 AM	Bill No.	: BIL24017266
Ref By	: Dr.GENERAL HEALTH CHECK UP	Result No	: 0 / RES24016655

<u>Parameter</u>	<u>Result</u>	<u>Normal Values</u>
URINE ROUTINE EXAMINATION		
Sugar	: Nil	
Albumin	: Nil	
Microscopic Examination		
Pus cells	: 2-4 /HPF	
Epithelial cells	: 1-2 /HPF	
RBC	: Absent /HPF	

*** End Of Report ***

Lab Tech.

Bio-Chemist

Lab In-Charge

Dr. K.MADHAVI, MD PATHOI
CONSULTANT PATHOLOGIS

Correlate Clinically, We use only sterilised disposable syringes & needles.

Discrepancies due to technical or typing errors should be reported within 3 days for correction.

This report is to help you for better management of patient and not valid for medicolegal purpose.

SENTINI HOSPITALS

D.No: 54-15-5, B&C, Beside Vinayaka Theatre,
Ring Road, Vijayawada - 520 008.Ph:0866-6677869

DEPARTMENT OF SEROLOGY

Name	: Mrs. BALAMMA .D	Age /Sex	: 53 Y(s)/Female
Bill Date	: 24-Aug-2024 09:03 AM	UMR No.	: UMR2410858
Rept. Dt	: 24-Aug-2024 11:54 AM	Bill No.	: BIL24017266
Ref By	: Dr.GENERAL HEALTH CHECK UP	Result No	: 0 / RES24016655

Blood Grouping & Rh Typing : "B" POSITIVE

*** End Of Report ***

Lab Tech.

Bio-Chemist

Lab In-Charge

Consultant Pathologist

D. BALAMMA

Date: 24/08/2024

UMR : 2410858

Age/Sex: 53Y/F

Ref : GENERAL

REAL TIME ULTRASONOGRAPHY OF THE ABDOMEN

LIVER: Normal in size, shape and outline. Parenchymal echotexture normal. No focal cystic or solid mass lesion. No intrahepatic biliary dilatation. Intrahepatic portion of IVC is normal.
Portal vein is normal. Porta hepatis is normal.

G. B: Partially distended. No obvious calculus to the visualized extent, advised review scan with fasting if detailed evaluation required.

C.B.D: Not dilated.

PANCREAS: Parenchymal echotexture normal. No ductal dilatation. No calculi.

SPLEEN: Normal in size & echotexture.

KIDNEYS: **Right kidney** measures 9.0 x 4.2cm .
Normal in size, shape and outline. Parenchymal echotexture normal.
Corticomedullary differentiation is well made out and is normal.
No evidence of calculi/ Hydronephrosis.

Left kidney measures 9.5 x 4.3cm
Normal in size, shape and outline. Parenchymal echotexture normal.
Corticomedullary differentiation is well made out and is normal.
No evidence of calculi / Hydronephrosis.

URINARY BLADDER : Empty

PELVIS: Poor window. review scan with full bladder SOS. No Adnexal cysts noted.
* No evidence of free fluid / lymphadenopathy.

IMPRESSION:

- **NO SIGNIFICANT ABNORMALITY.**

- For clinical correlation & follow up.

[Consultant Radiologist]

2024-08-11 22:58

Name: e

Sex: Age:

Section: Cardiology/ICU

RoomID:

BedID:

ID:

Operator:

Custom1:

Custom2:

Custom3:

AUTO 10mm/mV

Data for reference only:

HR bpm : 64
 PR Interval ms : 163
 P Duration ms : 114
 QRS Duration ms : 72
 T Duration ms : 183
 QT/QTc ms : 369/382
 P/QRS/T Axis deg : 10.4/18.8/23.3
 R(V5)/S(V1) mV : 0.77/0.58
 R(V5)+S(V1) mV : 1.35

10mm/mV

10mm/mV

Physician:

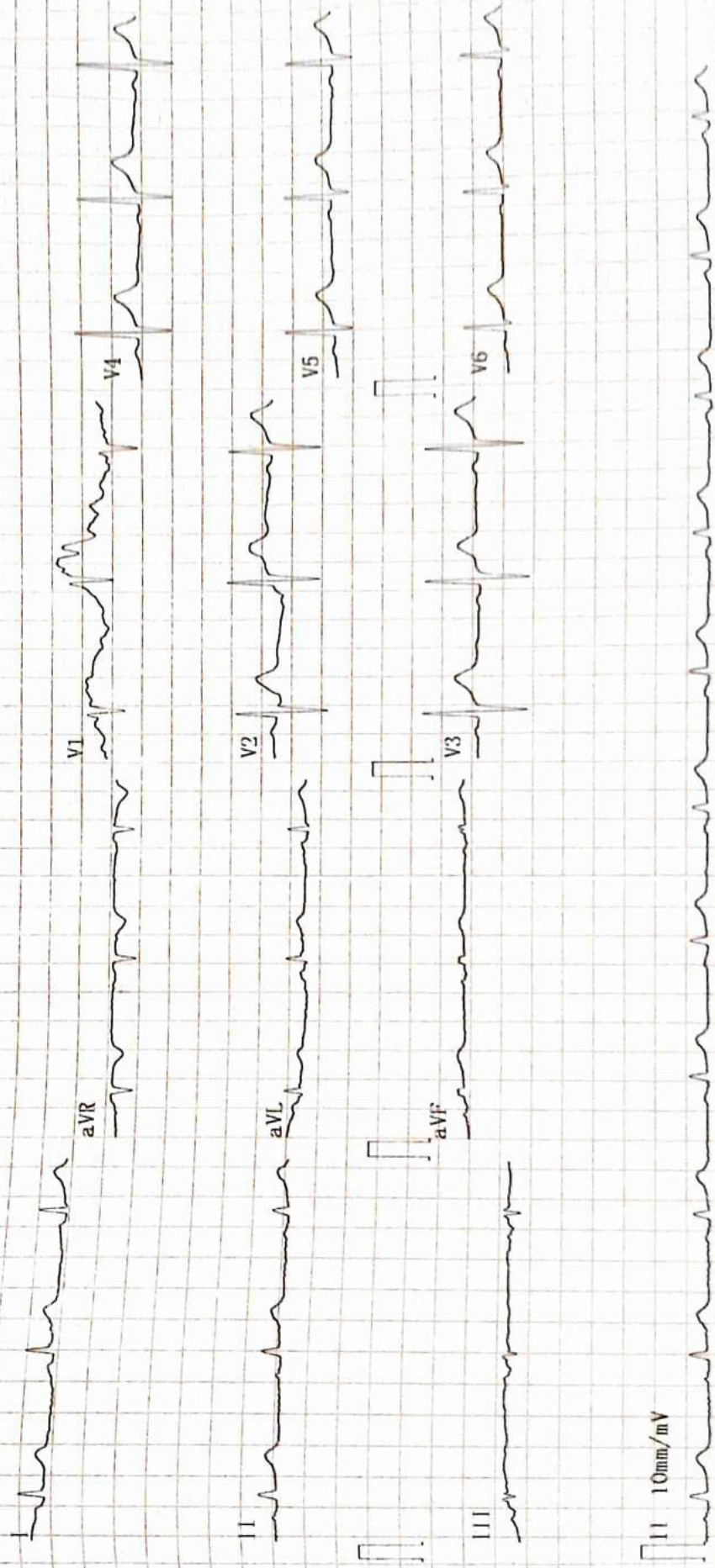
10mm/mV

<< Conclusions >>

Normal Sinus Rhythm,
Longitudinal Left axis deviation.

Report need physician confirmation

D. Reddy
53 years





Sentini Hospitals (P) Limited

Cardiology Department

ECHOCARDIOGRAM REPORTS

Name : D. Balamma	UMR/OP/IP No :2410858
Age :53 Years	Sex :Female
Date :24 /08/2024	Echo No :599
Technician: Praveen	

MITRAL VALVE : Normal
AORTIC VALVE : Normal
TRICUSPID VALVE : Normal
PULMONARY VALVE : Normal
AORTA : 30 mm
LEFT ATRIUM : 34 mm
LEFT VENTRICLE : Mild Concentric LVH
RWMA : No LV RWMA
IVS : 13 mm LV IDd : 42 mm
PW : 13 mm LVIDs : 28 mm
LV EF : 50 %
RIGHT ATRIUM : Normal
RIGHT VENTRICLE : Normal
PULMONARY ARTERY : Normal
PULMONARY VEINS : Normal
IAS : Intact
IVS : Intact
PERICARDIUM : Normal
PERICARDIAL EFFUSION : No Effusion

DOPPLER STUDY

MITRAL FLOW : A>E
TRICUSPID FLOW : TRJV- m/s TR Gr :20 mmHg RVSP: 30mmHg
AORTIC JET VELOCITY : 1.5 m/s AV Gr: mmHg
PULMONARY JET VELOCITY : 0.9 m/s
COLOUR DOPPLER : 2+MR 2+TR 2+AR No PR
IVC : Normal
SVC : Normal
OTHERS :
CONCLUSION :

**Mild Concentric LVH
No Obvious RWMA
Mild MR, Mild AR
Mild TR, NO PAH
Adequate LV systolic function
Grade I diastolic dysfunction
No PE /No Clot**

DR RAGHURAM MD.DM
SENIOR INTERVENTIONAL CARDIOLOGIST

DR K. KRISHNA CHAND MD.DNB
SENIOR INTERVENTIONAL CARDIOLOGIST

Sentini Hospital, Do. No: 54-15-5, B & C, Beside Vinayaka Theatre, Ring Road, Vijayawada-520008
Phone No: 0866-6465111 Email: info@sentinihospitals.co