


8, 9, 12

<b>Name</b> : Mr. YATHEESHA S  <b>Address</b> : mysore  <b>Plan</b> : ARCOFEMI MEDIWHEEL MALE AHC CREDIT PAN INDIA OP AGREEMENT	<b>Age</b> : 34 Y  <b>Sex</b> : M	<b>UHID</b> :CMYS.0000060194  <b>OP Number</b> :CMYSOPV123782 <b>Bill No</b> :CMYS-OCR-22798 <b>Date</b> : 23.03.2024 09:22
---	---	---

Sno	Service Type/ServiceName	Department
1	ARCOFEMI - MEDIWHEEL - FULL BODY ANNUAL PLUS MALE - 2D ECHO - PAN INDIA - FY2324	
<del>1</del>	<del>GAMMA GLUTAMYL TRANSFERASE (GGT)</del>	
<del>2</del>	<del>2D ECHO</del> → P	
3	LIVER FUNCTION TEST (LFT)	
4	GLUCOSE, FASTING	
5	HEMOGRAM + PERIPHERAL SMEAR	
6	DIET CONSULTATION → P	
7	COMPLETE URINE EXAMINATION	
8	URINE GLUCOSE(POST PRANDIAL)	
9	PERIPHERAL SMEAR	
10	EKG	HE → 164
11	RENAL PROFILE/RENAL FUNCTION TEST (RFT/KFT)	
12	DENTAL CONSULTATION → P	WG → 76.2
13	GLUCOSE, POST PRANDIAL (PP), 2 HOURS (POST MEAL)	
14	URINE GLUCOSE(FASTING)	BG → 120/80
15	HbA1c, GLYCATED HEMOGLOBIN	
16	X-RAY CHEST PA	
17	DENT CONSULTATION → P	
18	FITNESS BY GENERAL PHYSICIAN → P	
19	BLOOD GROUP ABO AND RH FACTOR	
20	LIPID PROFILE	
21	BODY MASS INDEX (BMI)	
22	OPTICAL BY GENERAL PHYSICIAN → P	
23	ULTRASOUND - WHOLE ABDOMEN → P	
24	THYROID PROFILE (TOTAL T3, TOTAL T4, TSH)	


**CERTIFICATE OF MEDICAL FITNESS**

This is to certify that I have conducted the clinical examination

of YATHHESHA A.S on 23/3/2029

After reviewing the medical history and on clinical examination it has been found that he/she is

<ul style="list-style-type: none"> <li>• Medically Fit</li> </ul>	<p>Tick</p> <input checked="" type="checkbox"/>
<ul style="list-style-type: none"> <li>• Fit with restrictions/recommendations</li> </ul> <p>Though following restrictions have been revealed, in my opinion, these are not impediments to the job.</p> <p>1.....</p> <p>2.....</p> <p>3.....</p> <p>However the employee should follow the advice/medication that has been communicated to him/her.</p> <p>Review after _____</p>	<input type="checkbox"/>
<ul style="list-style-type: none"> <li>• Currently Unfit. Review after _____</li> <li>• Unfit</li> </ul>	<input type="checkbox"/>

*Recommended*  
  
**Dr. Ravi Prakash Agrawal**  
 Medical Officer  
 Apollo Clinic, Mysore

**Apollo Health and Lifestyle Limited**

CIN: U65110TG2000PLC115819

Head Office: 110-60 62, Avinaka Rajmudra Chambers, 1st Floor, Bengaluru, Karnataka, India - 560016

Ph: 080-4004 7777 Fax: 080-4004 7766 | Email: enquiry@apollohospitals.com | www.apollohospitals.com

**APOLLO CLINICS NETWORK BANGALORE**

Bangalore: Saranahalli | Bellandur | Electronic City | Frazer Town | MSR Layout | Indira Nagar | J.P. Nagar

Koramangala | Sarjapur Road | Mysore: VV Mohalla

Online appointments: www.apollohospitals.com

**Apollo Clinic**  
 23, 1st Floor,  
 Kallada Road, Mysore

Ph: 0822-4004 7777

**1860 500 7788**

Date : 23-03-2024  
 MR NO : CMYS.0000060194  
 Name : Mr. YATHEESHA S  
 Age/ Gender : 34 Y / Male

Department : GENERAL  
 Doctor :  
 Registration No :  
 Qualification :

Consultation Timing: 09:22

Height : 164	Weight : 76.3	BMI :	Waist Circum :
Temp :	Pulse :	Resp :	B.P : 120/80

General Examination /  
Allergies History

FBS - 132.7  
 HbA1c - 6.1  
 PPBS - 144  
 Dyslipidemia  
 Persistent Gyn  
 UGI endoscopy  
 for H-pylori  
 safe.

Clinical Diagnosis & Management Plan

AHC 40 Per a/c  
 No Complaints like gyn.

O/E vit  
 as  
 as  
 as

Can Cause

ADW  
 1. Tab. Nexpa-20  
 1/2 two (20)

RA 3 mo  
 FBS  
 PPBS  
 HbA1c  
 Lipid profile.

Follow up date :

Dr. Raj Chethan Kumar A  
 MD (General Medicine)  
 KMC Reg. No. 62099  
 Apollo Clinic  
 # 23, 1st Floor,  
 Kalidasa Road, Mysore - 02  
 Ph : 0821-4006040/41

Date : 23-03-2024  
 MR NO : CMYS.0000060194  
 Name : Mr. YATHEESHA S  
 Age/ Gender : 34 Y / Male

Department : GENERAL Dietetics  
 Doctor : K. Mallikarjuna. B.P

Registration No :  
 Qualification : M.Sc Nutrition & Dietetics  
 PHD\*

Consultation Timing: 09:22

New - 64kg

Height : 164	Weight : 76	BMI : 28.7	Waist Circum : 100
Temp :	Pulse :	Resp :	B.P : 120/80


**General Examination / Allergies History**

ESR - 20  
 FBS - 132  
 PPBS - 144  
 HbA1c - 6.1%  
 Total cholesterol - 256  
 Triglycerides - 199  
 Non HDL - 215  
 LDL - 175.71  
 VLDL - 39.69  
 Chol/HDL - 6.31

**Clinical Diagnosis & Management Plan**

→ Advised low fat, diabetic diet with fiber rich food.  
 → Avoid sweets like Mango, sapota, Jackfruit, custard apple & sug banana.  
 → Avoid potato, sweet potato, Yau & Auli.

Follow up date :

Doctor Signature :   
 23/3/2024

**Apollo Clinic**  
 # 23, 1st Floor,  
 Kalidasa Road, Mysore - 57  
 Ph : 0821-4006040/41

Date : 23-03-2024  
MR NO : CMYS.0000060194

Department : GENERAL  
Doctor :

Name : Mr. YATHEESHA S

Registration No :

Age/ Gender : 34 Y / Male

Qualification :

Consultation Timing: 09:22

Height: 164	Weight: 76.2	BMI:	Waist Circum:
Temp:	Pulse:	Resp:	B.P: 120/80

General Examination /  
Allergies History

Clinical Diagnosis & Management Plan

Rae - of Im - Nout.

Abc - ~~not~~ ones to @ & @ spw.

theft - Nout.



Follow up date :

Doctor Signature

**Apollo Clinic**  
# 23, 1st Floor,  
Kalidasa Road, Mysore - 02  
Ph : 0821-4006040/41

Date : 23-03-2024  
 MR NO : CMYS.0000060194  
 Name : Mr. YATHEESHA S  
 Age/ Gender : 34 Y / Male

Department : GENERAL (Ophthal)  
 Doctor :  
 Registration No :  
 Qualification :

Consultation Timing: 09:22

Height: 164	Weight: 76.5	BMI:	Waist Circum:
Temp: (M)	Pulse: 92/min	Resp: 20/min	B.P: 120/80

General Examination /  
 Allergies History

NO


Clinical Diagnosis & Management Plan

Wearing Spectacles - corrected  
 vision lens - 76cm.

No H/O Ty II DM | HTN.

vision	(R)	(L)
Far	6/6	6/6
Near	N <sub>6</sub>	N <sub>6</sub>
colour.	NOT affected	

Follow up date :

Doctor Signature  


Regular Eye  
 checks.

**Apollo Clinic**  
 # 23, 1st Floor,  
 Kalidasa Road, Mysore - 02  
 Ph : 0821-4006040/41

Patient Name	: Mr. YATHEESHA S	Age	: 34 Y M
UHID	: CMYS.0000060194	OP Visit No	: CMYSOPV123782
Reported on	: 23-03-2024 15:24	Printed on	: 23-03-2024 15:24
Adm/Consult Doctor	:	Ref Doctor	: SELF

**DEPARTMENT OF RADIOLOGY**

**X-RAY CHEST PA**

Both lung fields and hila are normal .

No obvious active pleuro-parenchymal lesion seen .

Both costophrenic and cardiophrenic angles are clear .

Both diaphragms are normal in position and contour .

Thoracic wall and soft tissues appear normal.

**IMPRESSION :NORMAL STUDY .**

Printed on:23-03-2024 15:24

---End of the Report---

  
**Dr. CHETAN HOLEPPAGOL**  
**MBBS, DNB(RADIO DIAGNOSIS)**  
Radiology

**Apollo Health and Lifestyle Limited**

(CPY UBS110TG2000PLC115819)

Head Office 1 1D-6D 62, Ashoka Raghupathi Chambers, 5th Floor Begumpet, Hyderabad, Telangana - 500 016  
Ph No: (04) 4904 7777 Fax No: 4904 7744 | Email ID: enquiry@apollohl.com | www.apollohl.com

**APOLLO CLINICS NETWORK KARNATAKA**

Bangalore | Basavanagudi | Bellandur | Electronic City | Fraser Town | HSR Layout | Indira Nagar | JP Nagar | Kundalahalli |  
Koramangala | Sarjapur Road | Mysore (VV Mohalla)

Online appointments: www.apolloclinic.com

TO BOOK AN APPOINTMENT

 **1860 500 7788**

Patient's Name : Mr. YATHEESHA S	Age & Sex; 34Yrs /Male
Date : 23.03.2024	UHID No:0060194

## 2D ECHOCARDIOGRAPHY STUDY

### Impression:

- Normal chambers and valves
- No regional wall motion abnormality
- Normal left ventricular systolic function. EF 62 %
- No clots. No pericardial effusion

### Findings

Left Ventricle:	No RWMA
Right Ventricle	Normal
Left Atrium	Normal
Right Atrium	Normal
Aorta	Normal
Pulmonary Artery	Normal
IAS	Intact
IVS	Intact
Valves	Normal
Pericardium	Normal
Doppler	Normal

#### **Apollo Health and Lifestyle Limited**

UIN: UAS110762000PLC1158191

Head Office: 1-10 RD 62, Ashoka Raghupathi Chambers, 5th Floor, Begumpet, Hyderabad, Telangana - 500 016

Ph. No: (08) 4904 7777 | Fax No: 4904 7744 | Email ID: enquiry@apollohl.com | www.apollohl.com

#### **APOLLO CLINICS NETWORK KARNATAKA**

Bangalore: Basavanagudi | Bellandur | Electronic City | Fraser Town | HSR Layout | Indira Nagar | JP Nagar | Kundalahalli |  
Koramangala | Sarjapur Road | Mysore (VV Mohalla)

Online appointments: www.apolloclinic.com

TO BOOK AN APPOINTMENT

 **1860 500 7788**



Patient's Name : Mr. YATHEESHA S

Age & Sex: 34Yrs/Male

Date : 23.03.2024

UHID No. 0060194

Measurements

AO : 2.4 cm  
LA : 2.2 cm

RV : 2.3 cm

LVIDd : 4.27 cm

LVIDs : 2.76 cm

IVSd : 0.84 cm

IVSs : 1.22 cm

PWd : 0.88 cm

PWs : 1.03 cm

EF : 65.0 %

FS : 35.0 %

Doppler

	MV		TV		AV		PV	
E	0.82 m/s	E	---	m/s	V max	1.23 m/s	V max	0.98 m/s

A: 0.52 m/s A --- m/s

**Dr. GURU PRASAD, B. V, MBBS, PGDCC**  
**CONSULTANT - NON-INVASIVE CARDIOLOGY**

DR. GURU PRASAD B. V.  
MBBS, PGDCC, FRCG  
FRCG (C), FRCG (I), FRCG (E)  
FRCG (A), FRCG (S), FRCG (H)  
FRCG (M), FRCG (N), FRCG (O)  
FRCG (P), FRCG (Q), FRCG (R)  
FRCG (T), FRCG (U), FRCG (V)  
FRCG (W), FRCG (X), FRCG (Y)  
FRCG (Z)

**Apollo Health and Lifestyle Limited**

Dr. B. V. RAO (CEO), Apollo Hospitals

Apollo Health and Lifestyle Limited, 100 Feet Road, Apollo Hospitals, Hyderabad, Telangana - 500016

Dr. B. V. RAO (CEO), Apollo Hospitals, 100 Feet Road, Apollo Hospitals, Hyderabad, Telangana - 500016

Dr. B. V. RAO (CEO), Apollo Hospitals, 100 Feet Road, Apollo Hospitals, Hyderabad, Telangana - 500016

Bangalore | Chennai | Coimbatore | Delhi | Hyderabad | Kolkata | Lucknow | Mumbai | Pune | Raipur | Secunderabad |

Chennai | Coimbatore | Hyderabad | Kolkata | Lucknow | Mumbai | Pune | Raipur | Secunderabad |

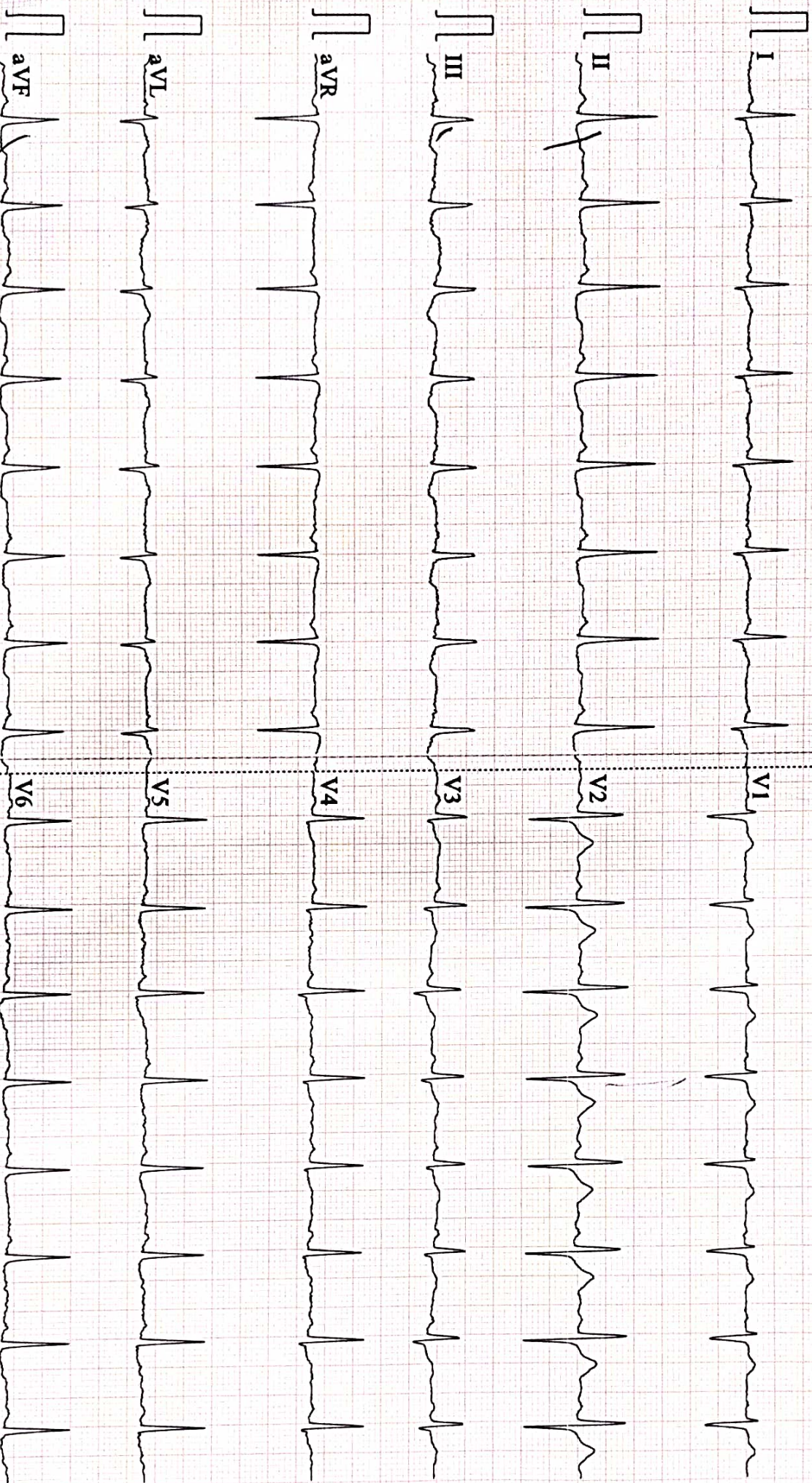
Chennai | Coimbatore | Hyderabad | Kolkata | Lucknow | Mumbai | Pune | Raipur | Secunderabad |

TO BOOK AN APPOINTMENT

**1860 500 7788**

Unconfirmed Report.

**Apollo Clinic**  
# 23, 1st Floor,  
Kallidasa Road, Mysore - 02  
Ph : 0821-4006040/41



Patient Name: Mr. YATHEESHA S	Date: 23.03.2024	Referring Doctor: Self
Age / Sex : 34yrs /Male	UHID : 060194	
<b>ULTRASONOGRAPHY – ABDOMEN &amp; PELVIS</b>		

**LIVER:** It is normal in size, outline and is increased in echotexture. No focal lesions seen. IHBR are not dilated. CBD and Portal vein are normal.

**GALL BLADDER:** It is contracted and shows a tiny calculus measuring 3mm.

**SPLEEN:** It is normal in size, outline and echopattern. No e/o focal lesions.

**PANCREAS:** It is normal in size, outline and echopattern.

**RIGHT KIDNEY:** It measures 10.5x3.8 cm with parenchymal thickness of 1.2 cm. It is normal in size, outline and echotexture. No e/o calculus or hydronephrosis seen.

**LEFT KIDNEY:** It measures 10.1x4.6 cm with parenchymal thickness of 1.1 cm. It is normal in size, outline and echotexture. No e/o calculus or hydronephrosis seen.

**URINARY BLADDER:** It is well distended. The UB wall is normal. No e/o calculi.

**PROSTATE:** It is normal in size, outline and echotexture.

No e/o free fluid in the abdomen.

**IMPRESSION:**

- GRADE I FATTY LIVER.
- CHOLELITHIASIS.



**Dr. Chetan H, DNB**  
Consultant Radiologist.

**Apollo Health and Lifestyle Limited**

CIN: U65110TG2000PLC1158104  
 Regd Office: 1-10-60-62, Ashoka Raghupathi Chambers, 5th Floor, Begumpet, Hyderabad, Telangana - 500 016  
 Ph. No. (04) 4204 7777 Fax No. 4204 7764 | Email ID: enquiry@apolloh.com | www.apolloh.com

**APOLLO CLINICS NETWORK KARNATAKA**

Bangalore: Bannerghatta | Bellandur | Electronic City | Fraser Town | HSR Layout | Indira Nagar | JP Nagar | Kulkarninagar |  
 Kalyanahalli | Sarjapur Road | Mysore (VV Mahalle)

Online appointments: www.apolloclinic.com

TO BOOK AN APPOINTMENT

**1860/500 7788**