

PATIENT NAME : PARVATHY R

REF. DOCTOR : SELF

CODE/NAME & ADDRESS : CA00010147 -

MEDIWHEEL ARCOFEMI HEALTHCARE LIMITED
F701A, LADO SARAI, NEW DELHI,SOUTH DELHI,
DELHI,
SOUTH DELHI 110030
8800465156ACCESSION NO : **4071XC005396**

PATIENT ID : PARVF2904904071

CLIENT PATIENT ID:

ABHA NO :

AGE/SEX : 33 Years Female

DRAWN :

RECEIVED : 23/03/2024 09:46:11

REPORTED : 24/03/2024 11:52:21

Test Report Status **Final**

Results

Biological Reference Interval Units

MEDIWHEEL HEALTH CHECKUP BELOW 40(F)TMT**PHYSICAL EXAMINATION**

PHYSICAL EXAMINATION

TEST COMPLETED

JIBI J
LAB TECHNOLOGIST

Page 1 Of 9



View Details



View Report

PERFORMED AT :DDRC AGILUS PATHLABS LIMITED
Phoenix Tower, Near Central Park Hotel,
Prathibha Junction, Kadappakada,
KOLLAM, 691008
KERALA, INDIA
Tel : 93334 93334
Email : customercare.ddrc@agilus.in

Patient Ref. No. 66600008308279

PATIENT NAME : PARVATHY R	REF. DOCTOR : SELF	
CODE/NAME & ADDRESS : CA00010147 - MEDIWHEEL ARCOFEMI HEALTHCARE LIMITED F701A, LADO SARAI, NEW DELHI,SOUTH DELHI, DELHI, SOUTH DELHI 110030 8800465156	ACCESSION NO : 4071XC005396 PATIENT ID : PARVF2904904071 CLIENT PATIENT ID: ABHA NO :	AGE/SEX : 33 Years Female DRAWN : RECEIVED : 23/03/2024 09:46:11 REPORTED : 24/03/2024 11:52:21

Test Report Status	Final	Results	Units
--------------------	-------	---------	-------

MEDIWHEEL HEALTH CHECKUP BELOW 40(F)TMT

ECG WITH REPORT

REPORT

TEST COMPLETED

USG ABDOMEN AND PELVIS

REPORT

Reported

CHEST X-RAY WITH REPORT

REPORT

TEST COMPLETED

HAEMATOLOGY

MEDIWHEEL HEALTH CHECKUP BELOW 40(F)TMT

GLYCOSYLATED HEMOGLOBIN(HBA1C), EDTA WHOLE BLOOD

HBA1C	5.3	Normal	: 4.0 -	%
		5.6%.		
		Non-diabetic level	: < 5.7%.	
		Diabetic	: >6.5%	

Glycemic control goal
 More stringent goal : < 6.5 %.
 General goal : < 7%.
 Less stringent goal : < 8%.

Glycemic targets in CKD :-
 If eGFR > 60 : < 7%.
 If eGFR < 60 : 7 - 8.5%.

MEAN PLASMA GLUCOSE	105.4	< 116.0	mg/dL
---------------------	-------	---------	-------

ANJU A
LAB TECHNOLOGIST

ARYA KG
LAB TECHNOLOGIST

DR.AKHILA SEKHAR, M.D
Pathology
(Reg No - TCMC 55174)
CONSULTANT PATHOLOGIST



View Details



View Report

PERFORMED AT :

DDRC AGILUS PATHLABS LIMITED
 Phoenix Tower, Near Central Park Hotel,
 Prathibha Junction, Kadappakada,
 KOLLAM, 691008
 KERALA, INDIA
 Tel : 93334 93334
 Email : customercare.ddrc@agilus.in



Patient Ref. No. 66600008308279

PATIENT NAME : PARVATHY R

REF. DOCTOR : SELF

CODE/NAME & ADDRESS : CA00010147 -
MEDIWHEEL ARCOFEMI HEALTHCARE LIMITED
F701A, LADO SARAI, NEW DELHI,SOUTH DELHI,
DELHI,
SOUTH DELHI 110030
8800465156

ACCESSION NO : **4071XC005396**
PATIENT ID : PARVF2904904071
CLIENT PATIENT ID:
ABHA NO :

AGE/SEX : 33 Years Female
DRAWN :
RECEIVED : 23/03/2024 09:46:11
REPORTED : 24/03/2024 11:52:21

Test Report Status	Final	Results	Units
--------------------	-------	---------	-------

BLOOD COUNTS,EDTA WHOLE BLOOD

HEMOGLOBIN	12.0	12.0 - 15.0	g/dL
RED BLOOD CELL COUNT	4.56	3.8 - 4.8	mil/ μ L
WHITE BLOOD CELL COUNT	4.79	4.0 - 10.0	thou/ μ L
PLATELET COUNT	264	150 - 410	thou/ μ L

RBC AND PLATELET INDICES


HEMATOCRIT	38.3	36 - 46	%
MEAN CORPUSCULAR VOL	84.1	83 - 101	fL
MEAN CORPUSCULAR HGB.	26.4 Low	27.0 - 32.0	pg
MEAN CORPUSCULAR HEMOGLOBIN CONCENTRATION	31.4 Low	31.5 - 34.5	g/dL
RED CELL DISTRIBUTION WIDTH	14.2 High	11.6 - 14.0	%
MENTZER INDEX	18.4		
MEAN PLATELET VOLUME	8.6	6.8 - 10.9	fL

WBC DIFFERENTIAL COUNT


SEGMENTED NEUTROPHILS	58	40 - 80	%
LYMPHOCYTES	35	20 - 40	%
MONOCYTES	05	2 - 10	%
EOSINOPHILS	2	1 - 6	%
BASOPHILS	00	< 1 - 2	%
ABSOLUTE NEUTROPHIL COUNT	2.78	2.0 - 7.0	thou/ μ L
ABSOLUTE LYMPHOCYTE COUNT	1.68	1.0 - 3.0	thou/ μ L
ABSOLUTE MONOCYTE COUNT	0.24	0.2 - 1.0	thou/ μ L
ABSOLUTE EOSINOPHIL COUNT	0.10	0.02 - 0.50	thou/ μ L
ABSOLUTE BASOPHIL COUNT	00		thou/ μ L
NEUTROPHIL LYMPHOCYTE RATIO (NLR)	1.7		



ANJU A
LAB TECHNOLOGIST



ARYA KG
LAB TECHNOLOGIST



DR.AKHILA SEKHAR, M.D
Pathology
(Reg No - TCMC 55174)
CONSULTANT PATHOLOGIST



View Details



View Report

Page 3 Of 9

PERFORMED AT :

DDRC AGILUS PATHLABS LIMITED
Phoenix Tower, Near Central Park Hotel,
Prathibha Junction, Kadappakada,
KOLLAM, 691008
KERALA, INDIA
Tel : 93334 93334
Email : customercare.ddrc@agilus.in



Patient Ref. No. 66600008308279

PATIENT NAME : PARVATHY R

REF. DOCTOR : SELF

CODE/NAME & ADDRESS : CA00010147 -

MEDIWHEEL ARCOFEMI HEALTHCARE LIMITED
F701A, LADO SARAI, NEW DELHI,SOUTH DELHI,
DELHI,
SOUTH DELHI 110030
8800465156

ACCESSION NO : 4071XC005396

PATIENT ID : PARVF2904904071

CLIENT PATIENT ID:

ABHA NO :

AGE/SEX : 33 Years Female

DRAWN :

RECEIVED : 23/03/2024 09:46:11

REPORTED : 24/03/2024 11:52:21

Test Report Status **Final**

Results

Units

ERYTHROCYTE SEDIMENTATION RATE (ESR),EDTA BLOOD

SEDIMENTATION RATE (ESR) 07 0 - 20 mm at 1 hr

SUGAR URINE - POST PRANDIAL

SUGAR URINE - POST PRANDIAL NOT DETECTED NOT DETECTED

SUGAR URINE - FASTING

SUGAR URINE - FASTING NOT DETECTED NOT DETECTED

IMMUNOHAEMATOLOGY**MEDIWHEEL HEALTH CHECKUP BELOW 40(F)TMT****ABO GROUP & RH TYPE, EDTA WHOLE BLOOD**ABO GROUP TYPE O
RH TYPE POSITIVE

Interpretation(s)

ABO GROUP & RH TYPE, EDTA WHOLE BLOOD-Blood group is identified by antigens and antibodies present in the blood. Antigens are protein molecules found on the surface of red blood cells. Antibodies are found in plasma. To determine blood group, red cells are mixed with different antibody solutions to give A,B,O or AB.

Disclaimer: "Please note, as the results of previous ABO and Rh group (Blood Group) for pregnant women are not available, please check with the patient records for availability of the same."

The test is performed by both forward as well as reverse grouping methods.

BIO CHEMISTRYDR.AKHILA SEKHAR, M.D
Pathology
(Reg No - TCMC 55174)
CONSULTANT PATHOLOGISTLAVANYA
LAB TECHNOLOGISTARYA KG
LAB TECHNOLOGIST

Page 4 Of 9



View Details



View Report

PERFORMED AT :DDRC AGILUS PATHLABS LIMITED
Phoenix Tower, Near Central Park Hotel,
Prathibha Junction, Kadappakada,
KOLLAM, 691008
KERALA, INDIA
Tel : 93334 93334
Email : customercare.ddrc@agilus.in

Patient Ref. No. 66600008308279

PATIENT NAME : PARVATHY R
REF. DOCTOR : SELF
CODE/NAME & ADDRESS : CA00010147 -
 MEDIWHEEL ARCOFEMI HEALTHCARE LIMITED
 F701A, LADO SARAI, NEW DELHI,SOUTH DELHI,
 DELHI,
 SOUTH DELHI 110030
 8800465156

ACCESSION NO : 4071XC005396
PATIENT ID : PARVF2904904071
CLIENT PATIENT ID:
ABHA NO :
AGE/SEX : 33 Years Female
DRAWN :
RECEIVED : 23/03/2024 09:46:11
REPORTED : 24/03/2024 11:52:21

Test Report Status	Final	Results	Units
--------------------	-------	---------	-------

MEDIWHEEL HEALTH CHECKUP BELOW 40(F)TMT
BLOOD UREA NITROGEN (BUN), SERUM

BLOOD UREA NITROGEN	10	Adult(<60 yrs) : 6 to 20	mg/dL
---------------------	----	--------------------------	-------

BUN/CREAT RATIO

BUN/CREAT RATIO	12.6		
-----------------	------	--	--

CREATININE, SERUM

CREATININE	0.79	18 - 60 yrs : 0.6 - 1.1	mg/dL
------------	------	-------------------------	-------

GLUCOSE, POST-PRANDIAL, PLASMA


GLUCOSE, POST-PRANDIAL, PLASMA	118	Diabetes Mellitus : > or = 200. Impaired Glucose tolerance/ Prediabetes : 140 - 199. Hypoglycemia : < 55.	mg/dL
--------------------------------	-----	--	-------

GLUCOSE FASTING,FLUORIDE PLASMA

FBS (FASTING BLOOD SUGAR)	84	Diabetes Mellitus : > or = 126. Impaired fasting Glucose/ Prediabetes : 101 - 125. Hypoglycemia : < 55.	mg/dL
---------------------------	----	--	-------

LIVER FUNCTION TEST WITH GGT

BILIRUBIN, TOTAL	0.52	General Range : < 1.1	mg/dL
BILIRUBIN, DIRECT	0.18	General Range : < 0.3	mg/dL
BILIRUBIN, INDIRECT	0.34	0.00 - 0.60	mg/dL


DR.AKHILA SEKHAR, M.D
 Pathology
 (Reg No - TCMC 55174)
 CONSULTANT PATHOLOGIST


ARYA KG
 LAB TECHNOLOGIST

Page 5 Of 9



View Details



View Report

PERFORMED AT :

 DDRC AGILUS PATHLABS LIMITED
 Phoenix Tower, Near Central Park Hotel,
 Prathibha Junction, Kadappakada,
 KOLLAM, 691008
 KERALA, INDIA
 Tel : 93334 93334
 Email : customercare.ddrc@agilus.in

Patient Ref. No. 66600008308279

PATIENT NAME : PARVATHY R		REF. DOCTOR : SELF	
CODE/NAME & ADDRESS : CA00010147 - MEDIWHEEL ARCOFEMI HEALTHCARE LIMITED F701A, LADO SARAI, NEW DELHI,SOUTH DELHI, DELHI, SOUTH DELHI 110030 8800465156	ACCESSION NO : 4071XC005396	AGE/SEX : 33 Years	Female
	PATIENT ID : PARVF2904904071	DRAWN :	
	CLIENT PATIENT ID:	RECEIVED : 23/03/2024 09:46:11	
	ABHA NO :	REPORTED : 24/03/2024 11:52:21	

Test Report Status	Final	Results	Units
TOTAL PROTEIN	7.3	Ambulatory : 6.4 - 8.3 Recumbant : 6 - 7.8	g/dL
ALBUMIN	4.6	20-60yrs : 3.5 - 5.2	g/dL
GLOBULIN	2.7	General Range : 2 - 3.5 Premature Neonates : 0.29 - 1.04	g/dL
ALBUMIN/GLOBULIN RATIO	1.7	1.0 - 2.0	RATIO
ASPARTATE AMINOTRANSFERASE (AST/SGOT)	23	Adults : < 33	U/L
ALANINE AMINOTRANSFERASE (ALT/SGPT)	37	Adults : < 34	U/L
ALKALINE PHOSPHATASE	60	Adult (<60yrs) : 35 - 105	U/L
GAMMA GLUTAMYL TRANSFERASE (GGT)	15	Adult (female) : < 40	U/L

TOTAL PROTEIN, SERUM

TOTAL PROTEIN	7.3	Ambulatory : 6.4 - 8.3 Recumbant : 6 - 7.8	g/dL
---------------	-----	---	------

URIC ACID, SERUM

URIC ACID	5.1	Adults : 2.4-5.7	mg/dL
-----------	-----	------------------	-------

BIOCHEMISTRY - LIPID

MEDIWHEEL HEALTH CHECKUP BELOW 40(F)TMT

LIPID PROFILE, SERUM

CHOLESTEROL	139	Desirable : < 200 Borderline : 200-239 High : >or= 240	mg/dL
TRIGLYCERIDES	87	Normal : < 150 High : 150-199 Hypertriglyceridemia : 200-499 Very High : > 499	mg/dL

DR.AKHILA SEKHAR, M.D
 Pathology
 (Reg No - TCMC 55174)
 CONSULTANT PATHOLOGIST

ARYA KG
 LAB TECHNOLOGIST



View Details



PATIENT NAME : PARVATHY R	REF. DOCTOR : SELF		
CODE/NAME & ADDRESS : CA00010147 - MEDIWHEEL ARCOFEMI HEALTHCARE LIMITED F701A, LADO SARAI, NEW DELHI,SOUTH DELHI, DELHI, SOUTH DELHI 110030 8800465156	ACCESSION NO : 4071XC005396	AGE/SEX : 33 Years Female	
	PATIENT ID : PARVF2904904071	DRAWN :	
	CLIENT PATIENT ID :	RECEIVED : 23/03/2024 09:46:11	
	ABHA NO :	REPORTED : 24/03/2024 11:52:21	

Test Report Status	Final	Results	Units
HDL CHOLESTEROL		65	mg/dL
LDL CHOLESTEROL, DIRECT		66	mg/dL
		General range : 40-60	
		Optimum : < 100	
		Above Optimum : 100-129	
		Borderline High : 130-159	
		High : 160-189	
		Very High : >or= 190	
NON HDL CHOLESTEROL		74	mg/dL
		Desirable: Less than 130	
		Above Desirable: 130 - 159	
		Borderline High: 160 - 189	
		High: 190 - 219	
		Very high: > or = 220	
VERY LOW DENSITY LIPOPROTEIN		17.4	mg/dL
		Desirable value :	
		10 - 35	
CHOL/HDL RATIO		2.1 Low	
		3.3-4.4 Low Risk	
		4.5-7.0 Average Risk	
		7.1-11.0 Moderate Risk	
		> 11.0 High Risk	
LDL/HDL RATIO		1.0	
		0.5 - 3.0 Desirable/Low Risk	
		3.1 - 6.0 Borderline/Moderate Risk	
		>6.0 High Risk	

SPECIALISED CHEMISTRY - HORMONE

MEDIWHEEL HEALTH CHECKUP BELOW 40(F)TMT

THYROID PANEL, SERUM

T3	99.18	Non-Pregnant : 80-200	ng/dL
		Pregnant Trimester-wise	
		1st : 81-190	
		2nd : 100-260	
		3rd : 100-260	
T4	6.95	Adults : 4.5-12.1	µg/dl
TSH 3RD GENERATION	1.230	Non-Pregnant : 0.4-4.2	µIU/mL

DR. AKHILA SEKHAR, M.D
Pathology
(Reg No - TCMC 55174)
CONSULTANT PATHOLOGIST

JIBI J
LAB TECHNOLOGIST

DR. AMJAD A, M.D Pathology
(Reg No - TCMC 38949)
CONSULTANT PATHOLOGIST



View Details



View Report

PERFORMED AT :

DDRC AGILUS PATHLABS LIMITED
Phoenix Tower, Near Central Park Hotel,
Prathibha Junction, Kadappakada,
KOLLAM, 691008
KERALA, INDIA
Tel : 93334 93334
Email : customercare.ddrc@agilus.in



Patient Ref. No. 66600008308279

PATIENT NAME : PARVATHY R

REF. DOCTOR : SELF

CODE/NAME & ADDRESS : CA00010147 -

MEDIWHEEL ARCOFEMI HEALTHCARE LIMITED
F701A, LADO SARAI, NEW DELHI,SOUTH DELHI,
DELHI,
SOUTH DELHI 110030
8800465156ACCESSION NO : **4071XC005396**

PATIENT ID : PARVF2904904071

CLIENT PATIENT ID:

ABHA NO :

AGE/SEX : 33 Years Female

DRAWN :

RECEIVED : 23/03/2024 09:46:11

REPORTED : 24/03/2024 11:52:21

Test Report Status **Final**

Results

Units

Pregnant Trimester-wise :

1st : 0.1 - 2.5

2nd : 0.2 - 3

3rd : 0.3 - 3

CLINICAL PATH - URINALYSIS

MEDIWHEEL HEALTH CHECKUP BELOW 40(F)TMT

PHYSICAL EXAMINATION, URINE

COLOR	PALE YELLOW
APPEARANCE	SLIGHTLY HAZY

CHEMICAL EXAMINATION, URINE

PH	6.5	4.8 - 7.4
SPECIFIC GRAVITY	1.015	1.015 - 1.030
PROTEIN	NOT DETECTED	NOT DETECTED
GLUCOSE	NOT DETECTED	NOT DETECTED
KETONES	NOT DETECTED	NOT DETECTED
BLOOD	NOT DETECTED	NOT DETECTED
BILIRUBIN	NOT DETECTED	NOT DETECTED
UROBILINOGEN	NORMAL	NORMAL
NITRITE	NOT DETECTED	NOT DETECTED

MICROSCOPIC EXAMINATION, URINE

RED BLOOD CELLS	NOT DETECTED	NOT DETECTED	/HPF
WBC	3-5	0-5	/HPF
EPITHELIAL CELLS	8-10	0-5	/HPF
CASTS	NIL		

DR.KARTHIKA RAMANATHAN, M.D
Pathology
(Reg No - TCMC 53950)
CONSULTANT PATHOLOGIST

ATHIRA S
LAB TECHNOLOGIST

JIBI J
LAB TECHNOLOGIST

Page 8 Of 9



View Details



View Report

PERFORMED AT :

DDRC AGILUS PATHLABS LIMITED
Phoenix Tower, Near Central Park Hotel,
Prathibha Junction, Kadappakada,
KOLLAM, 691008
KERALA, INDIA
Tel : 93334 93334
Email : customercare.ddrc@agilus.in



Patient Ref. No. 66600008308279

PATIENT NAME : PARVATHY R		REF. DOCTOR : SELF	
CODE/NAME & ADDRESS : CA00010147 - MEDIWHEEL ARCOFEMI HEALTHCARE LIMITED F701A, LADO SARAI, NEW DELHI,SOUTH DELHI, DELHI, SOUTH DELHI 110030 8800465156	ACCESSION NO : 4071XC005396	AGE/SEX : 33 Years Female	
	PATIENT ID : PARVF2904904071	DRAWN :	
	CLIENT PATIENT ID:	RECEIVED : 23/03/2024 09:46:11	
	ABHA NO :	REPORTED : 24/03/2024 11:52:21	

Test Report Status	Final	Results	Units
CRYSTALS		NIL	
BACTERIA		DETECTED (FEW)	NOT DETECTED
YEAST		NOT DETECTED	NOT DETECTED

DR.KARTHIKA RAMANATHAN, M.D
 Pathology
 (Reg No - TCMC 53950)
 CONSULTANT PATHOLOGIST

ATHIRA S
 LAB TECHNOLOGIST



View Details



View Report

If the examinee is suffering from an acute life threatening situation, you may be obliged to disclose the result of the medical examination to the examinee.

1. Name of the examinee	: Mr./Mrs./Ms. <i>Parvathy R.</i>
2. Mark of Identification	: (Mole/Scar/any other (specify location)):
3. Age/Date of Birth	: <i>33 / 29/04/1990</i> Gender: <i>F</i> <input checked="" type="checkbox"/> M
4. Photo ID Checked	: (Passport/Election Card/PAN Card/Driving Licence/Company ID) <i>realhaar</i>

PHYSICAL DETAILS:

a. Height <i>168</i> (cms)	b. Weight <i>60</i> (Kgs)	c. Girth of Abdomen <i>84</i> (cms)
d. Pulse Rate <i>70</i> (/Min)	e. Blood Pressure:	Systolic <i>130</i> Diastolic <i>90</i>
	1 st Reading	<i>130</i> <i>90</i>
	2 nd Reading	

FAMILY HISTORY:

Relation	Age if Living	Health Status	If deceased, age at the time and cause
Father	<i>68</i>	<i>healthy</i>	
Mother	<i>58</i>	<i>healthy</i>	
Brother(s)			
Sister(s)	<i>34</i>	<i>healthy</i>	

HABITS & ADDICTIONS: Does the examinee consume any of the following?

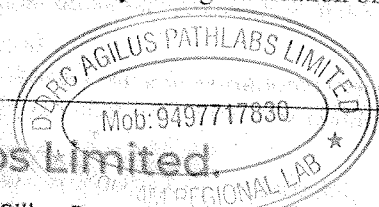
Tobacco in any form	Sedative	Alcohol
<i>No</i>	<i>No</i>	<i>No</i>

PERSONAL HISTORY

- a. Are you presently in good health and entirely free from any mental or Physical impairment or deformity. If No, please attach details. Y/N
- b. Have you undergone/been advised any surgical procedure? Y/N
- c. During the last 5 years have you been medically examined, received any advice or treatment or admitted to any hospital? Y/N
- d. Have you lost or gained weight in past 12 months? Y/N

Have you ever suffered from any of the following?

- Psychological Disorders or any kind of disorders of the Nervous System? Y/N
- Any disorders of Respiratory system? Y/N
- Any Cardiac or Circulatory Disorders? Y/N
- Enlarged glands or any form of Cancer/Tumour? Y/N
- Any Musculoskeletal disorder? Y/N
- Any disorder of Gastrointestinal System? Y/N
- Unexplained recurrent or persistent fever, and/or weight loss Y/N
- Have you been tested for HIV/HBsAg / HCV before? If yes attach reports Y/N
- Are you presently taking medication of any kind? Y/N



DDRC Agilus Pathlabs Limited

Corp. Office : Express House, Second Floor, Opp. Pothys Silks, Banerjee Road, Kaloor -682017
 Contact :- 93334 93334, Web :- www.ddrcagilus.com Email :- info.ddrc@agilus.in

• Any disorders of Urinary System?

Y/N ✓

• Any disorder of the Eyes, Ears, Nose, Throat or Mouth & Skin

Y/N ✓

FOR FEMALE CANDIDATES ONLY

a. Is there any history of diseases of breast/genital organs?

Y/N ✓

d. Do you have any history of miscarriage/abortion or MTP

Y/N ✓

b. Is there any history of abnormal PAP Smear/Mammogram/USG of Pelvis or any other tests? (If yes attach reports)

Y/N ✓

e. For Parous Women, were there any complication during pregnancy such as gestational diabetes, hypertension etc

Y/N ✓

c. Do you suspect any disease of Uterus, Cervix or Ovaries?

Y/N ✓

f. Are you now pregnant? If yes, how many months?

Y/N ✓

CONFIDENTIAL COMMENTS FROM MEDICAL EXAMINER

➤ Was the examinee co-operative?

✓ Y/N

➤ Is there anything about the examinee's health, lifestyle that might affect him/her in the near future with regard to his/her job?

Y/N

➤ Are there any points on which you suggest further information be obtained?

Y/N

➤ Based on your clinical impression, please provide your suggestions and recommendations below:

.....
.....
.....

➤ Do you think he/she is **MEDICALLY FIT** or **UNFIT** for employment.

MEDICAL EXAMINER'S DECLARATION

I hereby confirm that I have examined the above individual after verification of his/her identity and the findings stated above are true and correct to the best of my knowledge.

Name & Signature of the Medical Examiner :

Dr. Akhila Sekhar

Akhila

Dr. Akhila Sekhar MBBS, MD
Consultant Pathologist
Reg.No. 55174


Seal of Medical Examiner :

Name & Seal of DDRC SRL Branch :

DDRC Agilus Pathlabs Kadappalekads

Date & Time :

23/03/24



DDRC agilus Pathlabs Limited.

Corp. Office : Express House, Second Floor, Opp. Pothys Silks, Banerjee Road, Kaloor -682017

Contact :- 93334 93334, Web :- www.ddrcagilus.com Email :- info.ddrc@agilus.in

Name : Miss. Parvathy.R	Age : 33 yrs	Sex: F	YOUR LAB PARTNER SINCE 1983
Ref. from. Mediwheel Arcofemi			RADIOLOGY DIVISION Date : 23.03.2024

USG OF ABDOMEN (TAS only)

(Technical consideration: Poor sonological window)

LIVER: Is normal in size (13.8 cms) . *Echotexture is mildly increased through out of liver, suggestive of fatty changes.* No focal lesions are seen. No dilatation of intra-hepatic biliary radicles present. Portal vein is normal. Common bile duct is normal.

GALL BLADDER: Is minimally distended. Normal in wall thickness. No calculus or mass.

PANCREAS: Visualized head and body appears normal. Rest obscured by bowel gas

SPLEEN: Is normal in size (8.0 cms) and echotexture.

RIGHT KIDNEY: Measures 9.6 x 3.4 cms. Normal in size and echotexture. Cortico medullary differentiation is well maintained. No calculus, hydronephrosis or mass.

LEFT KIDNEY: Measures 10.0 x 5.5 cms. Normal in size and echotexture. Cortico medullary differentiation is well maintained. No calculus, hydronephrosis or mass.

URINARY BLADDER: Is partially distended. Normal wall thickness. No obvious calculus or mass. No vesical diverticulum present.

UTERUS: Measures 8.2 x 3.9 x 4.6 cms. Normal in size. Myometrial echoes normal. No focal lesions noted. Endometrial thickness measures 10 mm.

Cervix shows few Nabothian cysts.

Right ovary measures - 35.7 x 24.5 x 30.6 mm, volume - 14 cc

Left ovary measures - 35.8 x 23.1 x 31.3 mm, volume- 13.6 cc

Both ovaries are slightly bulky in size and shows mild increase in stromal echoes with multiple small follicles of size 3-5mm. No dominant follicle noted in either side.

No adnexal mass lesion seen. No free fluid in POD.

Both iliac fossae appear normal and there is no obvious evidence of bowel mass or bowel wall thickening present.

IMPRESSION:

- ❖ *Grade I fatty infiltration of liver.*
- ❖ *Polycystic appearance in both ovaries*

- Suggested follow up & clinical correlation
- Images overleaf.


Dr. AISALUTH THULASEEDHARAN
MBBS, DMRD

(Note: Diagnosis should not be made solely on one investigation. Advised further / repeat investigation and clinical correlation in suspected cases and in case of unexpected results, ultrasound is not 100% accurate and this report is not valid for medico legal purpose)

DDRC agilus Pathlabs Limited.

Corp. Office : Express House, Second Floor, Opp. Pothys Silks, Banerjee Road, Kaloor -682017
Contact :- 93334 93334, Web :- www.ddrcagilus.com Email :- info.ddrc@agilus.in

Gynecology Report

Patient ID : 23_03_2024_12_24_53

Sex : F

Age :

Patient Name : parvathy

Study Date : 23/03/2024

Referring MD :

Performing MD :

Sonographer :

Indication :

Exam Type : GYN

Height :

Weight :

Gravida :

Para :

AB :

Ectopic :

LMP :

2D Mode Measurements

Rt Ovary

Length : 35.7 mm

Width : 30.6 mm

Depth : 24.5 mm

Volume : 14.0 cc

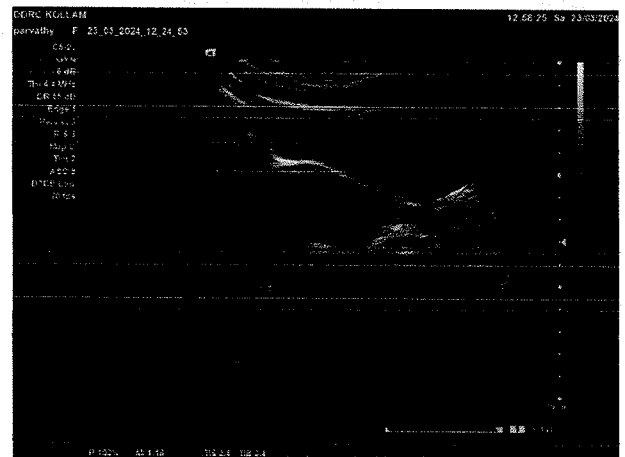
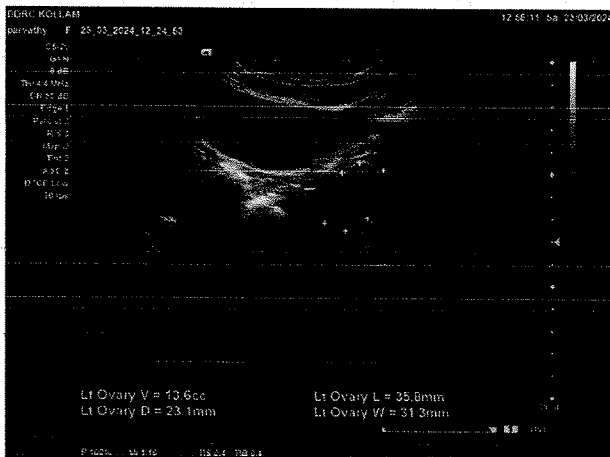
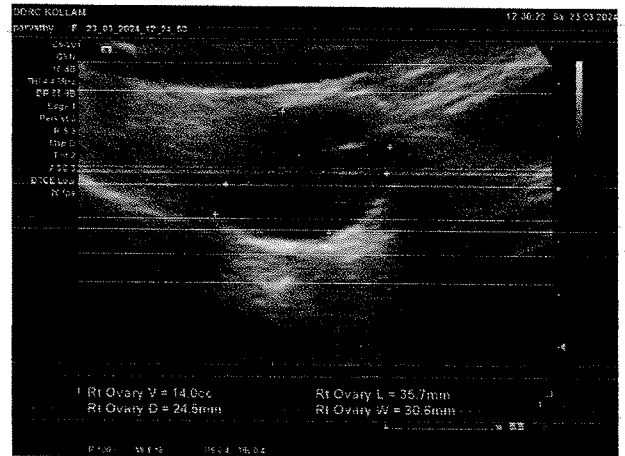
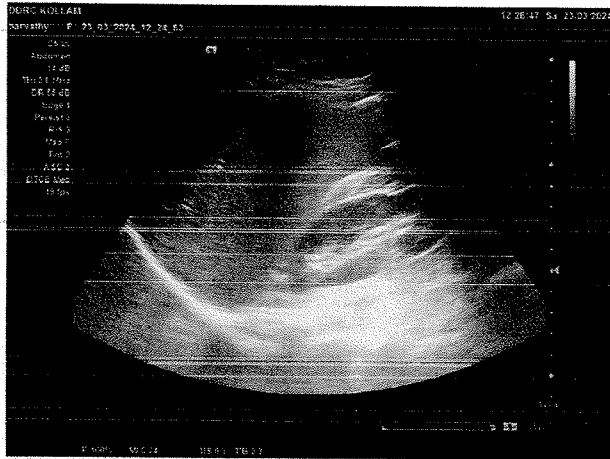
Lt Ovary

Length : 35.8 mm

Width : 31.3 mm

Depth : 23.1 mm

Volume : 13.6 cc



Signature _____

NAME : PARVATHY	AGE/ SEX : 33 /F	23.03.2024
-----------------	------------------	------------

ELECTRO CARDIOGRAM REPORT

ELECTRO CARDIOGRAM

: NSR – ⁸⁴...../minute. No evidence of ischaemia or chamber hypertrophy.

Impression

: **ECG with in normal limits.**


Dr. Akhila Sekhar MBBS MD
Consultant Pathologist
Reg.No. 55174



DR AKHILA SEKHAR

MBBS, MD

CONSULTANT PATHOLOGIST



NAME	AGE/ SEX	DATE
PARVATHY S	33/F	23.03.2024

X-RAY- CHEST WITH REPORT

CHEST X RAY : NORMAL

Impression : Within radiological limits

Calcific enlargement +


Dr. Akhila Sekhar MBBS.MD
Consultant Pathologist
Reg.No. 55174

Akhila

DR AKHILA SEKHAR


MBBS, MD


CONSULTANT PATHOLOGIST

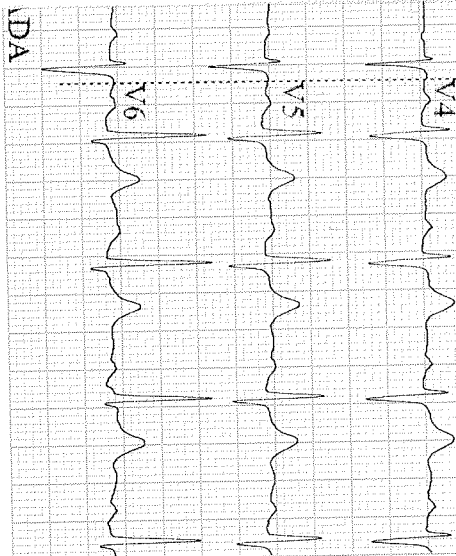


To
DDRC
Kadappakkada

I hereby provide consent that the mentioned TMT,
stool test and ophthal test need not be taken for
me as I have recently undergone the same and
the reports are available with me


Parathy R






AVR V1

ID: 9420
 Female
 33 Years
 cm
 kg
 mmHg

Diagnosis Information:

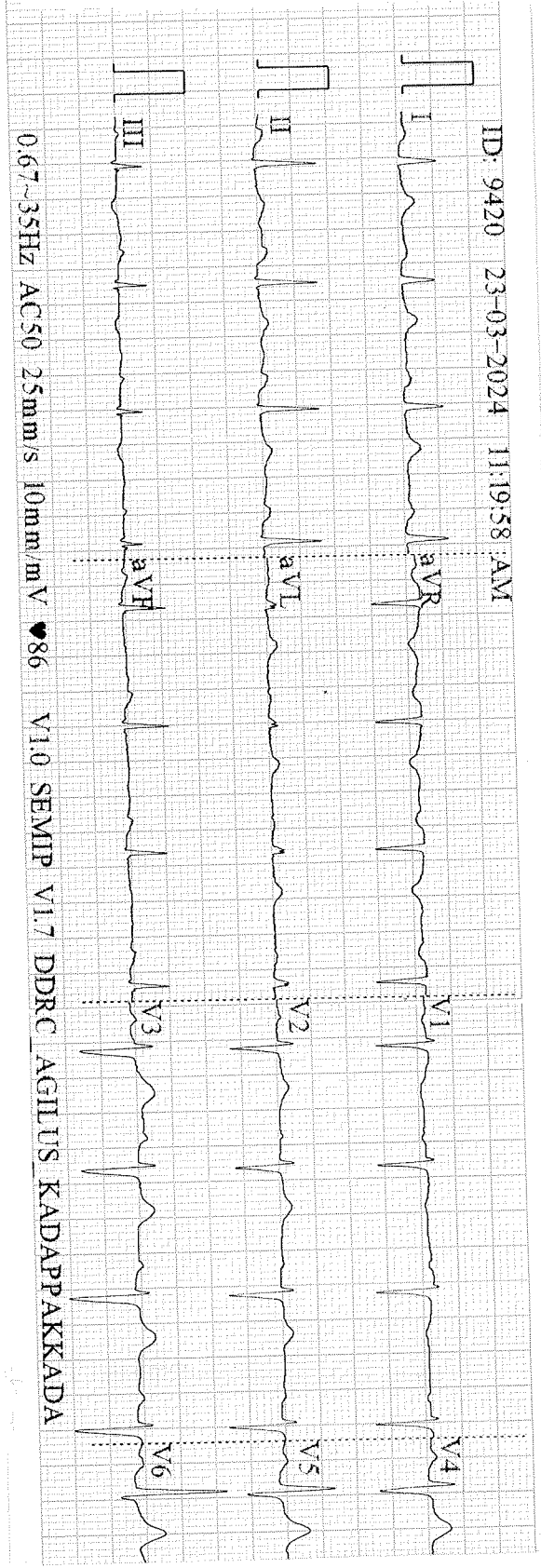
HR : 84 bpm
 P : 116 ms
 PR : 178 ms
 QRS : 78 ms
 QT : 365 ms
 QTc : 39.40 ms
 P/QRS/T : 39.40/16
 RV5/SV1 : 0.783/0.748 mV



pena fly R
9/3/17

Report Confirmed by:

ID: 9420 23-03-2024 11:19:58 AM



0.67~35Hz AC50 25mm/s 10mm/mV 86 V1.0 SEMIP V1.7 DDRC AGILUS KADAPPAKADA