

DAKSH HOSPITAL

396 - 397, Gandhi Nagar, Scheme No. 8, ALWAR -301001

Ref. No.

Date.....

MEDICAL EXAMINATION REPORT

Mediwheel (BOB)


Name: Mr Aman Saveda Age: 27 yrs Sex: Male

Date: 26/10/2024

General Physical Examination

Height	:	185 cm.	Weight	:	90.8 kg
Pulse	:	66 bpm	BP	:	120/70 mm/hg.
Temp.	:	97.6 F	Respiration SpO2	:	93 %
BMI	:	26.5			

Systemic Exam:- NORMALDental Check up :- NORMALEye check-up :- NORMALSkin Check up:- NORMALENT Check up:- NORMALGenae Check up:-Impression:- NORMALRecommendation:- NO


Dr. Mukesh Kumar Gupta
MD Gen. Medicine
Reg. No 5423/16262

डॉ० मुकेश गुप्ता
M.D.F.C.C.S.
फिजिशियन एवं मधुमेह रोग विशेषज्ञ
दक्ष हॉस्पिटल, अलवर
रजि० नं०-5423/16262

Date: 20/10/2024 Name: MR. AMAN SEVADA

Age & Sex: 45 yrs Male

Refd. :- Dr Mukesh Gupta M.D.

	TEST NAME	RESULT	REFERENCE RANGE
	ESR	12	00 -20 mm/hrs
	Blood Group & Rh Factor	A ⁺ POSITIVE	
	HbA1C	5.0	4 - 5.6%
	Blood Sugar (F)	87.3	< 70 - 100 mg/dl
	Blood Sugar (PP)	-	< 140 mg/dl
	Urine Sugar (F)	NIL	-
	Urine Sugar (PP)	-	-
LIVER	S.Bilirubin Total	0.90	0.30 - 1.20 mg/dl
	S.Bilirubin Direct	0.20	0.10 - 0.30 mg/dl
	S.Bilirubin Indirect	0.70	0.30 - 0.90 mg/dl
	S.C.O.T.	17	> 37 u/l
	S.G.P.T.	25	> 40 u/l
	S.Aik. Phosp.	184	80 - 305 u/l
	G.G.T.	25.0	5 -40 u/l
	Total Protein	7.0	6.5 - 8.5 gm/dl
	Albumin	4.0	3.8 - 5.4 gm/dl
	Globulin	3.0	2.3 - 3.5 gm/dl
	A/G Ratio	1.3	-
	AST/ALT Ratio	0.6	-
KIDNEY	Blood Urea	31.2	15 -45 mg/dl
	S.Creatinine	1.1	0.60 - 1.30 mg/dl
	BUN	17.0	6 -24 mg/dl
	S.Uric Acid	5.1	M 3.1 - 7.0, F 2.5 - 5.6 mg/dl
	BUN/Creatinine Ratio	15.4	-
LIPID PROFILE	Total Cholesterol	190.0	Up to 200 mg/dl
	S.HDL	44.0	30 - 70 mg/dl
	S.LDL	80.1	Up to 170 mg/dl
	S.VLDL	26.1	5.0 - 40 mg/dl
	S. Triglycerides	130.0	Up to 170 mg/dl
	LDL/HDL Ratio	1.8	-
	Total Cholesterol/ HDL Ratio	3.4	-
THYROID	T3	110.2	40 - 181 ng/dl
	T4	7.6	4.8 - 10.5 µg/dl
	TSH	5.44	0.30 - 5.0 mIU/l
	URINE EXAMINATION		Microscopic Examination:
General/Chemical Examination:			RBC Absent
	Colour	Pale Yellow	WBC 1-2
	Reaction	Acidic	Epithelial Cells 0-1
	Specific Gravity	QNS	Cast Absent
	Appearance	Clear	Crystal Absent
	Albumin	TRACE	Spermatozoa Absent
	Sugar	Nil	Amorphous Sediments Absent
			Other Absent
X-RAY CHEST		NORMAL STUDY	

R.S. Gupta

Dr. R.S. GUPTA
MD (Pathology) (MAHE)

Doc. No. 7924/19778

TECHNOLOGIST

All investigation have their own limitations regarding the sensitivity & specificity of individual assay procedures, Isolated laboratory investigations never confirm the final diagnosis of the disease. They only help in arriving at a diagnosis in conjunction with clinical presentation and other related investigations. Report is not valid for medico-legal purpose subject to ALWAR jurisdiction only.



दक्ष हॉस्पिटल

396, गाँधी नगर स्कीम नं.8, अलवर (राज०) ☎ 0144-2703340

Sonography / 2D Echo Cardiography / Doppler Report

2D/ ECHO REPORT

Name: - Mr AMAN SAVEDA

Age: - 27 Yrs

Date: - 26-Oct-24

Reg. No.: - Alw/2009/04

BOB health checkup

PROCEDURES:

M-MODE/2D/DOPPLER/COLOR/CONTRAST B.A.S. M²

MEASUREMENT:			DOPPLER:				
AOD	20	NORMAL (20-37mm)	MV	0.8	NORMAL (cm/sec.)		
LA	22	(19-40mm)	AV	1.5	MR	No	
AVO	16	(12-25mm)	TV	0.6	AR	No	
RVDd	11.6	(03-09mm)	PV	0.8	TR	No	
LVDd	51	(37-56mm)	MITRAL VALVE-			PR	No
LVDs	32	(22-40mm)	AML			Normal	
IVS d	10	(06-12mm)	PML			Normal	
IVS s	13.6		AORTIC VALVE			Normal	
PWd	5.8	(05-10mm)	TV & PV are normal.				
LV FUNCTION							
M- E- S Separation		<0.9cm					
Minor		24.42%					
LV Ejection Fraction	66%	65 +/- 12%					

LV WALL MOTION: NO RWMA
ALL CARDIAC CHAMBERS ARE NORMAL
ALL VALVES ARE NORMAL
NO CLOT, VEGETATION, PERICARDIAL EFFUSION

FINAL DIAGNOSIS: NORMAL STUDY

Adv: - Follow up/ review at higher center for confirmation

Note: - Please Correlate clinically. Due to technical limitations as well as inaccuracies inherent in the laboratory and statistical analysis of biological process. Diagnostic accuracy of ECHO is up to 95% only.
Report is not valid for medico-legal purpose.


Dr. Mukesh Kumar Gupta
DR. MUKESH GUPTA
PHYSICIAN ^{Cardiologist}
RM 5423/16262



"भ्रूण लिंग परीक्षण की शिकायत
104 टोल फ्री सेवा पर भी की
जा सकती है"

भ्रूण लिंग परीक्षण की शिकायत 104 टोल फ्री सेवा पर भी की जा सकती है।



दक्ष हॉस्पिटल

396, गाँधी नगर स्कीम नं.8, अलवर (राज०) ☎ 0144-2703340

Sonography / 2D Echo Cardiography / Doppler Report

Name: MR. AMAN SEVADA /M/27 YRS

Date: 26-Oct-24

BOB HEALTH CHECK UP

U.S.G. OF ABDOMEN & PELVIS

LIVER

Liver is normal in size shape with normal echo-texture. Intra hepatic biliary radicals are not dilated. No evidence of focal or diffuse lesion.

GALL BLADDER

Gall bladder is partially distended, visualized Lumen appear clear. Wall thickness normal. CBD normal

PANCREAS

Pancreas is normal in size, shape & echo-texture.

SPLEEN

Normal in size with normal shape & echo- texture.

BOTH KIDNEY

Both kidney normal shape, size & echo texture. CMD maintained

PROSTATE is normal shape, size & echo texture..

URINARY BLADDER is well distended, visualized lumen appear clear. Wall thickness normal.

Advice- X Ray KUB / URINE EXAM

Please correlate clinically. USG accuracy is 95 % due to technical limitations as well as inaccuracies inherent in the laboratory and statistical analysis biological process.

This report is not valid for medico-legal cases.


DR. MUKESH GUPTA
Sonologist
Physician & Sonologist
RM 5423/16262



भ्रूण लिंग परीक्षण की शिकायत
104 टोल फ्री सेवा पर भी की
जा सकती है।

भ्रूण लिंग परीक्षण की शिकायत 104 टोल फ्री सेवा पर भी की जा सकती है।

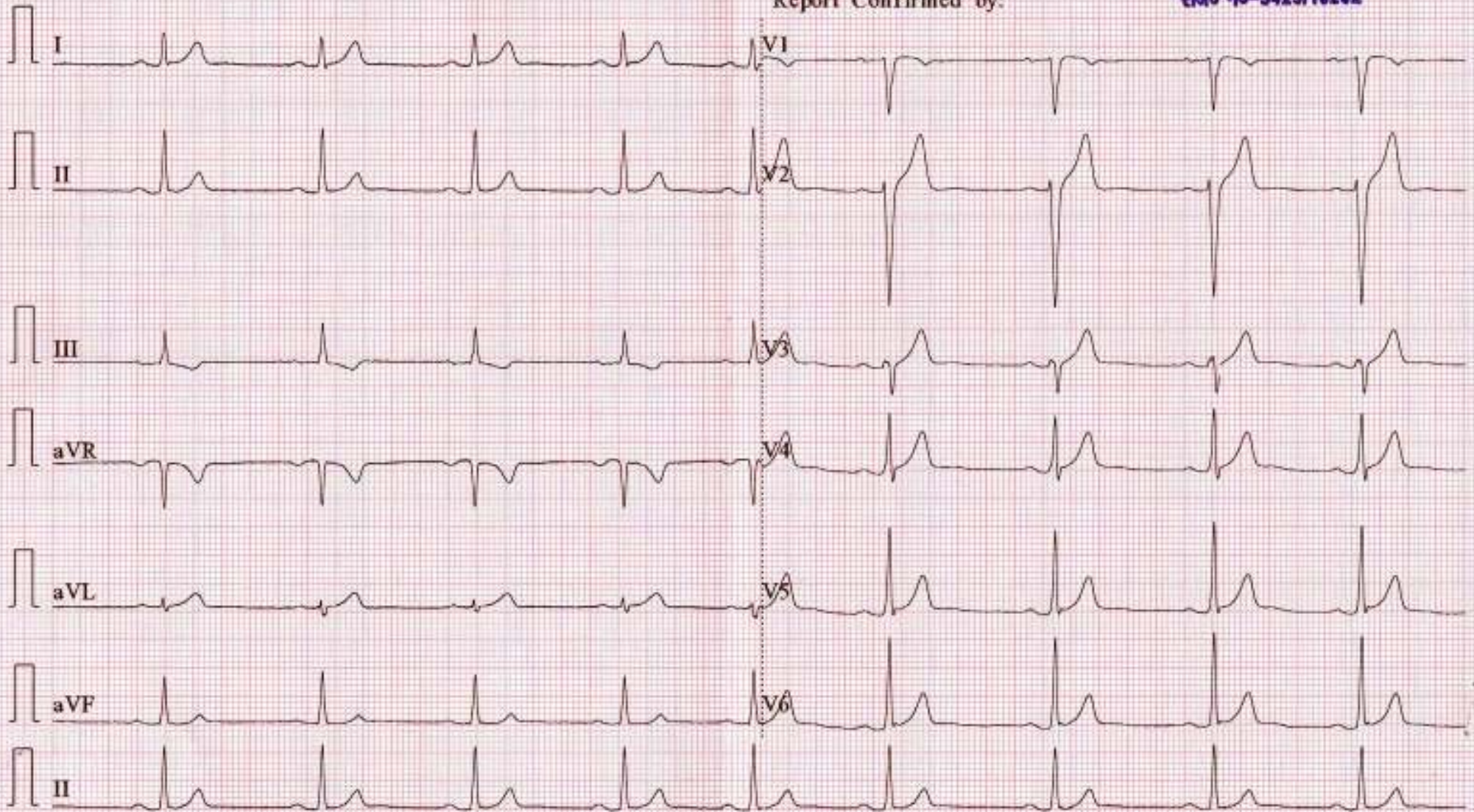
ID: 3
MR. AMAN SAVEDA
male 27 Years

HR : 56 bpm
P : 117 ms
PP : 194 ms
QRS : 92 ms
QT/QTc : 365/353 ms
P/QRS/T : 39/60/18 °
RV5/SV1 : 1.549/0.937 mV

Diagnosis Information:
Sinus Bradycardia
Poor R Wave Progression(V3)

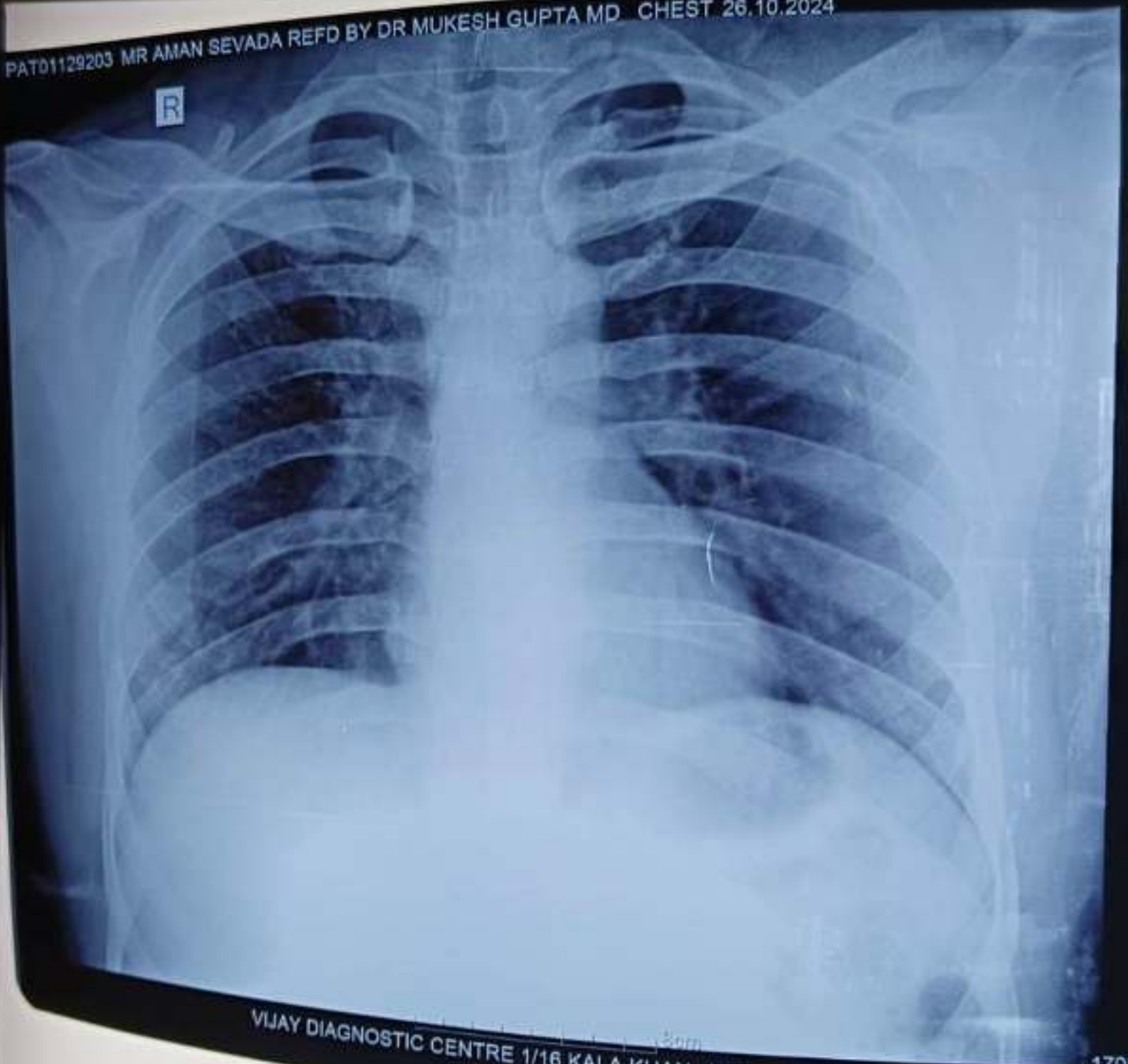डॉ० मुकेश गुप्ता
M.D.F.C.C.S.
कियुशिबन एवं भयुमेह रोग विशेषज्ञ
दास हॉस्पिटल, अलवर
रजि० नं०-5423/16262

Report Confirmed by:



PAT01129203 MR AMAN SEVADA REFD BY DR MUKESH GUPTA MD CHEST 26.10.2024

R



VIJAY DIAGNOSTIC CENTRE 1/16 KALA KUAN .ALWAR

1709