



भारत सरकार
Government of India



आधार

भारत सरकार
Government of India



भारतीय विशिष्ट पहचान प्राधिकरण
Unique Identification Authority of India

Enrollment No. : 0664/10016/72849

To
Nilofer Salim Shaikh


19/03/2012

BLDG No B 2 Flat No 1805 Poonam Estate Cluster 2,
Near Balaji Hotel,
Mira Road East,
VTC: Mira-Bhayander, PO: Mira Road,
Sub District: Thane, District: Thane,
State: Maharashtra, PIN Code: 401107,
Mobile: 9673020349

96820068



KA968200680FH



आपका आधार क्रमांक / Your Aadhaar No. :

2825 4388 3535

मेरा आधार, मेरी पहचान



भारत सरकार
Government of India



आधार



Nilofer Salim Shaikh
DOB: 08/10/1996
Female

19/03/2012

2825 4388 3535

मेरा आधार, मेरी पहचान

rdh
DR. ANITA CHOUDHARY
M.B.B.S.
CONSULTANT PHYSICIAN
Reg. No. 2017/12/5553

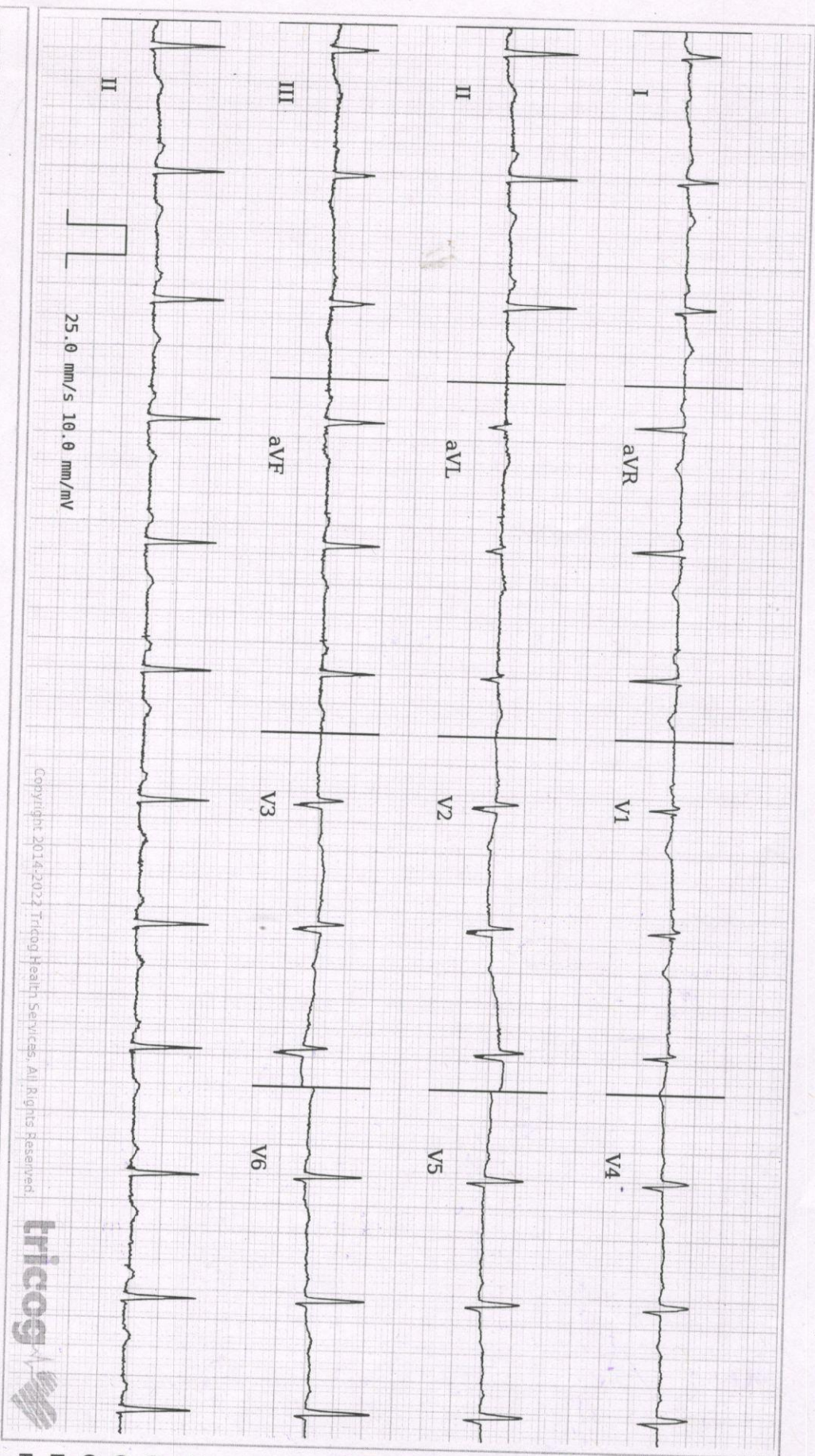
Anita

SUBURB PVT. LTD.
Shop No. 101-A, Kshitij Building,
Above Raymond, Near Kinga Hospital,
Mira - Bhayander Road, Bhaynader (E)
Dist. Thane-401105.
Phone No : 022 - 61700000

Patient Name: NILOFER SHAIKH

Patient ID: 2200870724

Date and Time: 8th Jan 22 11:08 AM



Age 35 3 0
years months days

Gender Female

Heart Rate 71 bpm

Patient Vitals

BP: 110/70 mmHg

Weight: 66 kg

Height: 162 cm

Pulse: NA

Spo2: NA

Resp: NA

Others:

Measurements

OSRD: 78 ms

QT: 372 ms

QTc: 404 ms

PR: 158 ms

P-R-T: 55° 70° 13°

ECG Within Normal Limits: Sinus Rhythm, Normal Axis Incomplete RBBB No significant ST-T changes. Please correlate clinically.

Disclaimer: 1) Analysis in this report is based on ECG alone and should be used as an adjunct to clinical history, symptoms, and results of other invasive and non-invasive tests and must be interpreted by a qualified physician. 2) Patient vitals are as entered by the clinician and not derived from the ECG.

[Signature]

REPORTED BY

Dr. Smita Valani
MBBS, D. Cardiology
2011/03/0587



Copyright 2014-2022 Tricog Health Services. All Rights Reserved.



CID : 2200870724
Name : Mrs Nilofer Shaikh
Age / Sex : 35 Years/Female
Ref. Dr :
Reg. Location : Bhayander East Main Centre

Reg. Date : 08-Jan-2022 / 09:48
Reported : 08-Jan-2022 / 12:51

X-RAY CHEST PA VIEW

Both lung fields are clear.

Both costo-phrenic angles are clear.

The cardiac size and shape are within normal limits.

The domes of diaphragm are normal in position and outlines.

The skeleton under review appears normal.

IMPRESSION:


NO SIGNIFICANT ABNORMALITY IS DETECTED.

-----End of Report-----

Khilji Faizur

Dr.FAIZUR KHILJI
MBBS,RADIO DIAGNOSIS
Reg No-74850
Consultant Radiologist

Click here to view images <http://202.143.96.162/Suburban/Viewer?ViewerType=3&AccessionNo=2022010809212287>



CID : 2200870724
Name : Mrs Nilofer Shaikh
Age / Sex : 35 Years/Female
Ref. Dr :
Reg. Location : Bhayander East Main Centre

Reg. Date : 08-Jan-2022 / 10:38
Reported : 08-Jan-2022 / 12:08

USG WHOLE ABDOMEN

LIVER:

The liver is normal in size (12.5 cm), shape and smooth margins. It shows altered parenchymal echotexture. The intra hepatic biliary and portal radicals appear normal. No evidence of any intra hepatic cystic or solid lesion seen. The main portal vein appears normal.

GALL BLADDER:

The gall bladder is removed-Post surgery.

COMMON BILE DUCT:

The visualized common bile duct is normal in caliber. Terminal common bile duct is obscured due to bowel gas artifacts.

PANCREAS:

The pancreas appears altered. No evidence of solid or cystic mass lesion.

KIDNEYS:

Right kidney measures 9.8 x 5.1 cm. It is ectopic, malrotated and is situated inferior to the left kidney in the left renal fossa. It appears normal in size, shape and echotexture. Left kidney measures 12.2 x 4.9 cm. It is normal in size, shape, position and echotexture. Corticomedullary differentiation is well maintained. Pelvicalyceal system is normal. No evidence of any calculus, hydronephrosis or mass lesion seen on both sides.

SPLEEN:

The spleen is normal in size (10.0 cm) and echotexture. No evidence of focal lesion is noted.

URINARY BLADDER:

The urinary bladder is well distended and reveals no intraluminal abnormality. Bladder wall appears normal. No obvious calculus or mass lesion made out in the lumen.

Click here to view images <http://202.143.96.162/Suburban/Viewer?ViewerType=3&AccessionNo=2022010809212285>

ADDRESS: 2nd Floor, Aston, Sundervan Complex, Above Mercedes Showroom, Andheri West - 400053

HEALTHLINE - MUMBAI: 022-6170-0000 | OTHER CITIES: 1800-266-4343

For Feedback - customerservice@suburbandiagnosics.com | www.suburbandiagnosics.com

Authenticity Check



Use a QR Code Scanner
Application To Scan the Code

CID : 2200870724
Name : Mrs Nilofer Shaikh
Age / Sex : 35 Years/Female
Ref. Dr :
Reg. Location : Bhayander East Main Centre

Reg. Date : 08-Jan-2022 / 10:38
Reported : 08-Jan-2022 / 12:08

UTERUS :

The uterus is anteverted and appears normal. It measures 6.9 x 4.3 x 3.3 cms in size. Myometrium appears normal. No obvious hypo or hyperechoic mass lesion made out in the myometrium. The endometrium appears normal and measures 4.0 mm.

OVARIES:

Right ovary : 2.8 x 2.5 x 1.9 cm, Vol : 7.4 cc.
Left ovary : 2.9 x 2.1 x 2.5 cm, Vol : 8.3 cc.
Both the ovaries are well visualised and appear normal in size, shape, position and echotexture.

There is no evidence of any ovarian or adnexal mass seen.

No free fluid is seen in the pouch of douglas.

IMPRESSION:

Fatty liver grade I.
Ectopic and malrotated right kidney present inferior to the left kidney in the left renal fossa.

Kindly correlate clinically.

Investigations have their limitation. Solitary pathological/Radiological & other investigations never confirm the final diagnosis. They only help in diagnosing the disease in correlation to clinical symptoms & other related tests. Please interpret accordingly.

-----End of Report-----

Khilji Faizur

Dr.FAIZUR KHILJI
MBBS,RADIO DIAGNOSIS
Reg No-74850
Consultant Radiologist

Click here to view images <http://202.143.96.162/Suburban/Viewer?ViewerType=3&AccessionNo=2022010809212285>

Date:- 8/01/2022

CID: 2200870724

Name:- Nilofar Surtikh

Sex / Age: 135 / R

EYE CHECK UP

Chief complaints:

Systemic Diseases:

Past history: NM

Unaided Vision:

RE LE
6/9 6/9
6/16 6/16

Aided Vision:

Refraction:

	(Right Eye)				(Left Eye)			
	Sph	Cyl	Axis	Vn	Sph	Cyl	Axis	Vn
Distance								
Near								

Colour Vision: Normal / Abnormal

Remark:

SUBURBAN DIAGNOSTICS (I) PVT. LTD
Shop No. 101-A, 1st Floor, Keshavnagar Building
Above Raymond, Near Thane Railway Station
Thane - Bhayander Road, B. K. Road (E)
Dist. Thane-401006.
Phone No : 022 - 61700000

CID: 2200870724	Age/Gender : 35 Years/Female
Name : Mrs. Nilofer Shaikh	Registered : 08/01/2022
Ref. By: -----	Reported : 08/01/2022
Reg.Location : Bhayander	Printed : 08/01/2022

2D-Echocardiogram & Doppler Report

Cardiac Evaluation:

DIMENSIONS:

IVSd	11.3	mm
IVSs	11.8	mm
LVIDd	46.1	mm
LVIDs	23.0	mm
LVPWd	9.6	mm
LVPWS	12.9	mm
LVEF	60	%
AO	25.7	mm
LA	30.2	mm
AVC	15.0	mm

MORPHOLOGICAL DATA

Mitral Valve	Normal
Aortic Valve	Normal
Tricuspid Valve	Normal
Pulmonary Valve	Normal
Right Ventricle	Normal
IAS / IVS	Intact
Pulmonary Artery	Normal
Aorta	Normal
Right Atrium	Normal
Left Atrium	Normal
Pericardium	Normal
LV Studies	Normal

ADDRESS: 2nd Floor, Aston, Sundervan Complex, Above Mercedes Showroom, Andheri West - 400053

HEALTHLINE - MUMBAI: 022-6170-0000 | OTHER CITIES: 1800-266-4343

For Feedback - customerservice@suburbandiagnosics.com | www.suburbandiagnosics.com


DOPPLER DATA:

Mitral E velocity	0.75	cm/s	
Mitral A velocity	0.54	cm/s	
Mitral E/A	1.39		
AV max	1.15	cm/s	PG 5.3 mmhg
PV max	1.09	cm/s	PG 4.8 mmhg
TR max	1.70	cm/s	PG 25 mmhg

IMPRESSION:

- Normal dimensions of all cardiac chambers.
- No RWMA.
- Good LV systolic Function. LVEF = 60 %.
- No clot/vegetation/effusion.
- No PH. (PASP by TR jet 25 mm hg).

----- End of Report -----



DR. SMITA VALANI
M.B.B.S., D. Cardiology
Reg. No. 2011/03/0587
CONSULTANT CARDIOLOGIST

ADDRESS: 2nd Floor, Aston, Sundervan Complex, Above Mercedes Showroom, Andheri West - 400053

HEALTHLINE - MUMBAI: 022-6170-0000 | **OTHER CITIES:** 1800-266-4343

For Feedback - customerservice@suburbandiagnosics.com | www.suburbandiagnosics.com

CID#	: 2200870724	SID#	: 177804065053
Name	: MRS.NILOFER SHAIKH	Registered	: 08-Jan-2022 / 09:20
Age / Gender	: 35 Years/Female	Collected	: 08-Jan-2022 / 09:20
Consulting Dr.	: -	Reported	: 10-Jan-2022 / 13:46
Reg.Location	: Bhayander East (Main Centre)	Printed	: 10-Jan-2022 / 14:01

PHYSICAL EXAMINATION REPORT

History and Complaints:

No Complaint

EXAMINATION FINDINGS:

Height (cms):	162	Weight (kg):	66
Temp (0c):	Afebrile	Skin:	NAD
Blood Pressure (mm/hg):	100/70 mmHg	Nails:	NAD
Pulse:	72/min	Lymph Node:	Not Palpable

Systems

Cardiovascular: S1S2-Normal
Respiratory: Chest-Clear
Genitourinary: NAD
GI System: NAD
CNS: NAD

**IMPRESSION:ECG,CXR,TFT ,Biochemistry ,Diabetic Profile are WNL
R/E of Urine ,lipid profile and CBC are Borderline
USG is s/o Grade1 Fatty Liver and Ectopic and malrotated Rt Kidney**

ADVICE:Expert consultation

CHIEF COMPLAINTS:

1) Hypertension:	No
2) IHD	No

CID#	: 2200870724	SID#	: 177804065053
Name	: MRS.NILOFER SHAIKH	Registered	: 08-Jan-2022 / 09:20
Age / Gender	: 35 Years/Female	Collected	: 08-Jan-2022 / 09:20
Consulting Dr.	: -	Reported	: 10-Jan-2022 / 13:46
Reg.Location	: Bhayander East (Main Centre)	Printed	: 10-Jan-2022 / 14:01

- | | |
|--|------------------------------|
| 3) Arrhythmia | No |
| 4) Diabetes Mellitus | No |
| 5) Tuberculosis | No |
| 6) Asthama | No |
| 7) Pulmonary Disease | No |
| 8) Thyroid/ Endocrine disorders | No |
| 9) Nervous disorders | No |
| 10) GI system | No |
| 11) Genital urinary disorder | No |
| 12) Rheumatic joint diseases or symptoms | No |
| 13) Blood disease or disorder | No |
| 14) Cancer/lump growth/cyst | No |
| 15) Congenital disease | No |
| 16) Surgeries | Yes,Lap,Cholecystectomy,2020 |
| 17) Musculoskeletal System | No |

PERSONAL HISTORY:

- | | |
|---------------|------------|
| 1) Alcohol | Yes,Rarely |
| 2) Smoking | No |
| 3) Diet | Mixed |
| 4) Medication | No |

DR. ANITA CHOUDHARY
M.D.
CONSULTANT PHYSICIAN
Reg. No. 2017/12/5553

SUBURBAN DIAGNOSTICS (I) PVT. LTD.
Shop No. 101-A, 1st Floor, Kshitij Building,
Above Reymond, Near Thunga Hospital
Mira - Bhayander Road, Bhaynader (E)
Dist. Thane-401105.
Phone No : 022 - 61700000

ADDRESS: 2nd Floor, Aston, Sundervan Complex, Above Mercedes Showroom, Andheri West - 400053

HEALTHLINE - MUMBAI: 022-6170-0000 | OTHER CITIES: 1800-266-4343

For Feedback - customerservice@suburbandiagnosics.com | www.suburbandiagnosics.com