



Pathology Department



Patient's name : THAKOR KANUBHAI
 Age/Sex : 44 Years/Male
 Referred by : MEDI WHEEL
 Collection Time : 09:53

Reg. ID : P-6544-23
 Accession : 23684
 Order Dt/time : 09/03/2024 09:53

Complete Blood Count

Sample Type: EDTA

Test Name	Result	Units	Biological Reference Interval
<u>Blood Counts</u>			
Haemoglobin :	12.6	Gms%	13.5 - 18.0
Total R.B.C. :	5.67	mill/c.mm	4.7 - 6.0
Total W. B. C. :	6110	/cu mm	4000 - 10500
Platelet Count :	310000	/cu.mm	1,50,000 - 4,50,000
<u>Differential Count</u>			
Neutrophils :	57	%	40 - 70
Lymphocytes :	37	%	20 - 40
Eosinophils :	03	%	1 - 4
Monocytes :	03	%	2 - 6
Basophils :	00	%	0 - 01
<u>Blood Indices</u>			
P. C. V :	40.3	%	42 - 52
M. C. V. :	71.2	fl	78 - 100
M.C.H :	22.2	pg	27 - 31
M. C. H. C :	31.1	%	32 - 36
R.D.W :	16.0	%	11.5 - 14.0

E.S.R.(Westergren Method)

After one hour : 06 mm/hr 1 - 7

TESTS DONE ON FULLY AUTOMATED HEMATOLOGY ANALYZER.

Dr. Gayatri M. Mehta
 M. D. Patho)
 Reg. No. : G-32215

DR GAYATRI MEHTA
 MD(PATHOLOGY)

DR. ANAND D. PARIKH
 MD(PATHOLOGY)

LAB USE ONLY (Entered by :GM Enter Date/Time:09/03/2024 17:02:00) (Verify by :GM Verify Date/Time:09/03/2024 17:02:00)



Vidhi Diagnostics | Pathology Department

L-86, Swatantra Senani Nagar, Opp. Akhbarnagar Petrol Pump, Nr. Akhbarnagar Circle, Nava-Vadaj, Ahmedabad - 380 013.

M. - Pathology : 8849893954, Ph. : 079-27621406, M. 98799 29406, 98250 09406, E-mail : vidhidiagnostics@gmail.com, Web. : www.vidhidiagnostics.com

Time (Pathology) : Mon. to Sat. 8.30 am to 8.00 pm, Sunday 9 am to 12 Noon

Pathology means science behind medicine

CT SCAN & CBCT FACILITY NOW AVAILABLE



Patient's name : THAKOR KANUBHAI
Age/Sex : 44 Years/Male
Referred by : MEDI WHEEL
Collection Time : 09:53

Reg. ID : P-6544-23
Accession : 23684
Order Dt/time : 09/03/2024 09:53

Blood Group

Sample Type: EDTA sample.

Test Name	Result
BG :	" AB "
RH :	POSITIVE
Remarks	Done by forward grouping method.

Blood Glucose

Sample Type: Serum

Test Name	Result	Units	Biological Reference Interval
Fasting Blood Glucose :	189.4	mg/dl	70 - 110
Urine Sugar :	Present (Trace)		Absent
<i>GOD-POD Method.</i>			

Blood Glucose

Sample Type: Serum

Test Name	Result	Units	Biological Reference Interval
Post Prandial Blood Glucose After 2hr. :	405.4	mg/dl	80 - 140
Urine Sugar :	Present (++++)		Absent
<i>GOD-POD Method.</i>			

Dr. Gayatri M. Mehta
M. D. Patho)

Reg. No. : G-32215

DR GAYATRI MEHTA
MD(PATHOLOGY)

DR. ANAND D. PARIKH
MD(PATHOLOGY)

LAB USE ONLY (Entered by :GM Enter Date/Time:09/03/2024 17:03:00) (Verify by :GM Verify Date/Time:09/03/2024 17:03:00)



Vidhi Diagnostics | Pathology Department

L-86, Swatantra Senani Nagar, Opp. Akhbarnagar Petrol Pump, Nr. Akhbarnagar Circle, Nava-Vadaj, Ahmedabad - 380 013.

M. - Pathology : 8849893954, Ph. : 079-27621406, M. 98799 29406, 98250 09406, E-mail : vidhidiagnostics@gmail.com, Web. : www.vidhidiagnostics.com

Time (Pathology) : Mon. to Sat. 8.30 am to 8.00 pm, Sunday 9 am to 12 Noon

Pathology means science behind medicine

CT SCAN & CBCT FACILITY NOW AVAILABLE



Pathology Department

VIDHI
DIAGNOSTICS



Patient's name : THAKOR KANUBHAI
Age/Sex : 44 Years/Male
Referred by : MEDI WHEEL
Collection Time : 09:53

Reg. ID : P-6544-23
Accession : 23684
Order Dt/time : 09/03/2024 09:53

Lipid Profile

Sample Type: Serum

Test Name	Result	Units	Biological Reference Interval
S. Cholesterol : Oxidase-esterase method.	192	mg/dl	0 - 200
S. Triglyceride : Enzymatic Colorimetry method	106.9	mg/dL	0 - 200
S. HDL - Cholesterol : Serum by Enzymatic method.	50.3	mg/dL	35 - 65
S. LDL - Cholesterol : Serum by Enzymatic method	120.32	mg/dL	0 - 130
S. VLDL - Cholesterol :	21.38	mg/dL	0 - 30
S. Chole/HDL.Ratio :	3.82		1 - 6
S. LDL/ HDL Cholesterol Ratio :	2.39		0 - 3.5

Dr. Gayatri M. Mehta
M. D. Patho)
Reg. No. : G-32215

DR GAYATRI MEHTA
MD(PATHOLOGY)

DR. ANAND D. PARIKH
MD(PATHOLOGY)

LAB USE ONLY (Entered by :GM Enter Date/Time:09/03/2024 17:02:00) (Verify by :GM Verify Date/Time:09/03/2024 17:02:00)



Vidhi Diagnostics | Pathology Department

L-86, Swatantra Senani Nagar, Opp. Akhbarnagar Petrol Pump, Nr. Akhbarnagar Circle, Nava-Vadaj, Ahmedabad - 380 013.

M. - Pathology : 8849893954, Ph. : 079-27621406, M. 98799 29406, 98250 09406, E-mail : vidhidiagnostics@gmail.com, Web. : www.vidhidiagnostics.com

Time (Pathology) : Mon. to Sat. 8.30 am to 8.00 pm, Sunday 9 am to 12 Noon

Pathology means science behind medicine

CT SCAN & CBCT FACILITY NOW AVAILABLE



Patient's name : THAKOR KANUBHAI
Age/Sex : 44 Years/Male
Referred by : MEDI WHEEL
Collection Time : 09:53

Reg. ID : P-6544-23
Accession : 23684
Order Dt/time : 09/03/2024 09:53

HbA1C

Sample Type: EDTA

Test Name	Result	Units	Biological Reference Interval
HbA1C :	9.4	%	Non-diabetic: 4.2-6.2 Pre-diabetic : 6.3-7.2 Diabetic : 7.3-8.2
Mean Blood Glucose of Last 03 months.	223.08	mg/dl	

Comment *As per the new 2009 update of American Diabetes Association regarding HbA1C & Mean Blood Glucose relationship.

NOTE: This test is used to monitor diabetic patients compliance with the therapeutic regimen and logo It's level is proportional to both the average blood glucose concentration and the life span of the red blood cells (RBC) in circulation. HbA1c values are free of day to day glucose fluctuations and are unaffected by exercise or recent food intake.

Dr. Gayatri M. Mehta
M. D. Patho)
Reg. No. : G-32215

DR GAYATRI MEHTA
MD(PATHOLOGY)

DR. ANAND D. PARIKH
MD(PATHOLOGY)

LAB USE ONLY (Entered by :GM Enter Date/Time:09/03/2024 17:02:00) (Verify by :GM Verify Date/Time:09/03/2024 17:02:00)



Vidhi Diagnostics | Pathology Department

L-86, Swatantra Senani Nagar, Opp. Akhbarnagar Petrol Pump, Nr. Akhbarnagar Circle, Nava-Vadaj, Ahmedabad - 380 013.

M. - Pathology : 8849893954, Ph. : 079-27621406, M. 98799 29406, 98250 09406, E-mail : vidhidiagnostics@gmail.com, Web. : www.vidhidiagnostics.com

Time (Pathology) : Mon. to Sat. 8.30 am to 8.00 pm, Sunday 9 am to 12 Noon

Pathology means science behind medicine

CT SCAN & CBCT FACILITY NOW AVAILABLE



Patient's name : THAKOR KANUBHAI
 Age/Sex : 44 Years/Male
 Referred by : MEDI WHEEL
 Collection Time : 09:53

Reg. ID : P-6544-23
 Accession : 23684
 Order Dt/time : 09/03/2024 09:53

BIOCHEMISTRY

Sample type :Serum

Test Name	Result	Units	Biological Reference Interval
Urea, (Serum by GLDH method) :	17.8	mg/dl	10 - 50
S.Uric acid, (Serum by Uricase method) :	3.6	mg/dl	3.4 - 7.0
Bun :	8.3	mg/dl	6-20
Creatinine, (Serum by Enzymatic reaction) :	0.56	mg/dl	0.5-1.2
S.G.P.T (ALT) : (Serum by IFCC method)	42.2	U/L	0 - 40
S.G.O.T (AST) : (Serum by IFCC method)	37.4	U/L	0 - 37
ALK.PHOSPHATASE : (Serum by PNP method)	115	U/L	40-129
G.G.T :	57.4	U/L	8 - 78
BILIRUBIN			
Total :	0.39	mg/dl	Up to 1.2
Direct :	0.19	mg/dl	0-0.7
Indirect :	0.2	mg/dl	0 - 0.5
SERUM PROTEINS			
Total Protein (Serum by Biuret method) :	7.00	gms/dl	6.4 - 8.5
Albumin (Serum by BCG method) :	4.32	gms/dl	3.97-4.94
Globulins :	2.68	gms/dl	2.3 - 3.5
A/G Ratio :	1.612		0.9 - 2.9

Dr. Gayatri M. Mehta
 M. D. Patho)
 Reg. No. : G-32215

DR GAYATRI MEHTA
MD(PATHOLOGY)

DR. ANAND D. PARIKH
MD(PATHOLOGY)

LAB USE ONLY (Entered by :GM Enter Date/Time:09/03/2024 17:02:00) (Verify by :GM Verify Date/Time:09/03/2024 17:02:00)



Vidhi Diagnostics | Pathology Department

L-86, Swatantra Senani Nagar, Opp. Akhbarnagar Petrol Pump, Nr. Akhbarnagar Circle, Nava-Vadaj, Ahmedabad - 380 013.

M. - Pathology : 8849893954, Ph. : 079-27621406, M. 98799 29406, 98250 09406, E-mail : vidhidiagnostics@gmail.com, Web. : www.vidhidiagnostics.com

Time (Pathology) : Mon. to Sat. 8.30 am to 8.00 pm, Sunday 9 am to 12 Noon

Pathology means science behind medicine

CT SCAN & CBCT FACILITY NOW AVAILABLE



Pathology Department



Patient's name : THAKOR KANUBHAI
Age/Sex : 44 Years/Male
Referred by : MEDI WHEEL
Collection Time : 09:53

Reg. ID : P-6544-23
Accession : 23684
Order Dt/time : 09/03/2024 09:53

Thyroid Function Test

Sample Type: Serum

Test Name	Result	Units	Biological Reference Interval
TOTAL T3 :	1.60	ng/ml	1.1 - 1.84
TOTAL T4 :	9.56	µg/dL	6.09 - 12.23
TSH(Ultra sensitive) :	1.95	µIU/mL	0.4001 - 4.049

Dr. Gayatri M. Mehta
M. D. Patho)
Reg. No. : G-32215

DR GAYATRI MEHTA
MD(PATHOLOGY)

DR. ANAND D. PARIKH
MD(PATHOLOGY)

LAB USE ONLY (Entered by :GM Enter Date/Time:09/03/2024 16:50:00) (Verify by :GM Verify Date/Time:09/03/2024 17:03:00)



Vidhi Diagnostics | Pathology Department

L-86, Swatantra Senani Nagar, Opp. Akharnagar Petrol Pump, Nr. Akharnagar Circle, Nava-Vadaj, Ahmedabad - 380 013.

M. - Pathology : 8849893954, Ph. : 079-27621406, M. 98799 29406, 98250 09406, E-mail : vidhidiagnostics@gmail.com, Web. : www.vidhidiagnostics.com

Time (Pathology) : Mon. to Sat. 8.30 am to 8.00 pm, Sunday 9 am to 12 Noon

Pathology means science behind medicine

CT SCAN & CBCT FACILITY NOW AVAILABLE



Patient's name : THAKOR KANUBHAI
Age/Sex : 44 Years/Male
Referred by : MEDI WHEEL
Collection Time : 09:53

Reg. ID : P-6544-23
Accession : 23684
Order Dt/time : 09/03/2024 09:53

Urine Analysis

Sample Type: Urine

Test Name	Result	Units	Biological Reference Interval
<u>Physical Examination</u>			
Quantity :	30	ml	0 - 500 ml
Colour :	Pale Yellow		Pale Yellow
Transparency :	Slight Turbid.		Clear
Reaction :	Acidic		4.6 - 8.0
Specific Gravity :	1.015		1.016 - 1.022
Sediment :	Present		
<u>Chemical Examination</u>			
Albumin :	Present (Faint Trace)		Absent
Sugar :	Present (Trace)		Absent
Acetone :	Absent		Absent
Bile Salts :	Absent		Absent
Bile Pigments :	Absent		Absent
Urobilogen :	Absent		Absent
Nitrites :	Absent		Absent
<u>Microscopic Examination</u>			
Red blood Cells :	2-3	/h.p.f	Absent
Pus Cells :	2-3	/h.p.f	Absent
Epithelial Cells :	1-2	/h.p.f	< 10.0
Amorphous :	Absent	/h.p.f	Absent
Bacteria :	Absent	/h.p.f	Absent
Crystals :	Absent	/h.p.f	Absent
Casts :	Absent	/h.p.f	Absent
Fungus :	Not seen	/h.p.f	Absent

Dr. Gayatri M. Mehta
M. D. (Patho)
Reg. No. : G-32215

DR GAYATRI MEHTA
MD(PATHOLOGY)



DR. ANAND D. PARIKH
MD(PATHOLOGY)



(Entered by :GM Enter Date/Time:09/03/2024 17:03:00) (Verify by :GM Verify Date/Time:09/03/2024 17:03:00)

Vidhi Diagnostics | Pathology Department

L-86, Swatantra Senani Nagar, Opp. Akhbarnagar Petrol Pump, Nr. Akhbarnagar Circle, Nava-Vadaj, Ahmedabad - 380 013.

M. - Pathology : 8849893954, Ph. : 079-27621406, M. 98799 29406, 98250 09406, E-mail : vidhidiagnostics@gmail.com, Web. : www.vidhidiagnostics.com

Time (Pathology) : Mon. to Sat. 8.30 am to 8.00 pm, Sunday 9 am to 12 Noon

Pathology means science behind medicine

CT SCAN & CBCT FACILITY NOW AVAILABLE



Pathology Department

VIDHI[®]
DIAGNOSTICS

Creating Life in
Science

Patient's name : THAKOR KANUBHAI
Age/Sex : 44 Years/Male
Referred by : MEDI WHEEL
Collection Time : 09:53

Reg. ID : P-6544-23
Accession : 23684
Order Dt/time : 09/03/2024 09:53

Stool Examination

STOOL SAMPLE NOT RECEIVED

Dr. Gayatri M. Mehta
M. D. Patho)
Reg. No. : G-32215

DR GAYATRI MEHTA
MD(PATHOLOGY)

DR. ANAND D. PARIKH
MD(PATHOLOGY)

LAB USE ONLY (Entered by :GM Enter Date/Time:09/03/2024 5:07:00 PM) (Verify by :GM Verify Date/Time:09/03/2024 5:08:00 PM)



Vidhi Diagnostics | Pathology Department

L-86, Swatantra Senani Nagar, Opp. Akhbarnagar Petrol Pump, Nr. Akhbarnagar Circle, Nava-Vadaj, Ahmedabad - 380 013.

M. - Pathology : 8849893954, Ph. : 079-27621406, M. 98799 29406, 98250 09406, E-mail : vidhidiagnostics@gmail.com, Web. : www.vidhidiagnostics.com

Time (Pathology) : Mon. to Sat. 8.30 am to 8.00 pm, Sunday 9 am to 12 Noon

Pathology means science behind medicine

CT SCAN & CBCT FACILITY NOW AVAILABLE

Health Check up Booking Request(bobE11167), Beneficiary Code-158152

1 message

23 February 2024 at 15:44

Mediwheel <wellness@mediwheel.in>
To: vidhidiagnostics@gmail.com
Cc: customercare@mediwheel.in



Mediwheel
...Your wellness partner

011-41195959

Dear VIDHI DIAGNOSTICS

We have received a booking request for the details are following. Please provide your confirmation by clicking on the yes button.

Are you sure to confirm the booking? Yes No

Name : MR. THAKOR KANUBHAI BHANUBHAI
Package Name : Mediwheel Full Body Health Checkup Male Above 40
Package Code :
Location : L-86 Swatantra - Senani Nagar , Opp- Akhbarnagar Bus Terminals, New Wadaj , Ahmedabad -13
Contact Details : 9662498820
E-mail id : KANUBHAI.THAKOR@bankofbaroda.com
Booking Date : 23-02-2024
Appointment Date : 09-03-2024

Member Information		
Booked Member Name	Age	Gender
MR. THAKOR KANUBHAI BHANUBHAI	44 year	Male

Please login to your account to confirm the same. Also you mail us for confirmation

Hospital Package Name : Mediwheel Full Body Health Checkup Male Above 40

User Package Name : Mediwheel Full Body Health Checkup Male Above 40

22 Tests included in this Package :

- Stool Test
- Thyroid Profile
- ESR
- Blood Glucose (Fasting)
- General Physician Consultation
- TMT OR 2D ECHO
- Blood Group
- Blood Glucose (Post Prandial)
- Chest X-ray
- ECG
- USG Whole Abdomen
- Eye Check-up consultation
- Urine Sugar Fasting
- Urine Sugar PP
- Dental Consultation

- Urine analysis
- CBC
- HbA1c
- Lipid Profile
- Kidney Profile
- Liver profile
- Prostate Specific Antigen (PSA Male)

Thanks,
Mediwheel Team

You have received this mail because your e-mail ID is registered with This is a system-generated e-mail **Arcofemi Healthcare Limited**, please don't reply to this message.

Please visit to our Terms & Conditions for more informaion. This email is recieved because you are register with us [Click here to unsubscribe](#).

@ 2024 - 25, Arcofemi Healthcare Pvt Limited.(Mediwheel)



भारत सरकार

GOVERNMENT OF INDIA



ઠાકોર કનુભાઈ

Thakor Kanubhai

જાસમ તારીખ/DOB: 12/10/1979

પુરુષ/ MALE

Mobile No: 9662498820

4142 3139 4008

VID : 9152 6206 7164 7173

Vidhi Diagnostics
Laxmi Nagar - Senani Nagar
Opp. Anandnagar Bus Terminal,
Nr. Ashbarnagar Circle,
New Waje, Ahmedabad-13.

મારો આધાર, મારી ઓળખ

Dr. Dinesh S. Modh

M.D., D.M.R.E. (Radiodiagnosis)
Consultant Radiologist & Sonologist
Ex. Junior Lecturer, B.J. Medical College, Civil Hospital, A'bad.



DATE: 09/03/2024		
NAME: Thekore Kamubhai		
AGE: 44 / male		
MEDICAL EXAMINATION:-		
HEIGHT: 161 cm	WEIGHT: 60 kg	
BP: 140 / 90 mmHg	PULSE: 104 Permin	
SPO2: 98	TEMPRATURE: (N)	
RS: (N)	CVS: (N)	
ASYMTOMATIC		
HISTORY: H/O DM since 5 yr - Bilateral polyneuropathy since age of 3 yr - operation in 1977 by Dr. R. C. Chhabranagar		
EYE CHECK-UP:-	RIGHT	LEFT
DISTANCE:	6/6	6/6
NEAR:	N/6 with speers	N/6 with speers
COLOR VISION:	Normal	Normal
DENTAL CHECK-UP:	Staining seen in teeth	
ADV: HE/SHE IS MEDICALLY FIT		

Dr. Vidhi D. Modh
MBBS
Reg. No. G-74540

Vidhi Diagnostics
L-86, Swatantra-Senani Nagar,
Opp. Akhbarnagar Bus Terminals,
Nr. Akhbarnagar Circle,
New Wadaj, Ahmedabad-13.

ISO 9001:2015 Certified Diagnostics Center
Vidhi Imaging Center

L-86, Swatantra Senani Nagar, Opp. Indian Oil Petrol Pump, Akhbarnagar Circle, Nava Vadaj, Ahmedabad - 380 013.

Phone : (Radiology) 079-2762 1406 | M. 98799 29406, 98250 09406 | Time (Radiology) : Mon. to Sat. 9 am to 2 pm, 5 to 9 pm, Sunday 9 am to 12 Noon
E-mail : vidhidiagnostics@gmail.com, Website : www.vidhidiagnostics.com

Multislice CT Scan | CBCT-Dental Scan | Live 3D-4D Sonography | Colour Doppler | Echo Cardiography | Interventional Radiology | Maxillofacial Radiology | Fetal Medicine
Digital X-Ray | Digital Mammography | Digital OPG/TMJ | ECG/TMT/PFT/EEG/EMG | Audiometry | Pathology Laboratory | Health Check Up Plans | Pre Employment Check Up

CT SCAN & CBCT FACILITY NOW AVAILABLE

ID: 12948

Name: Kanubhai thakor

Age: 41yrs

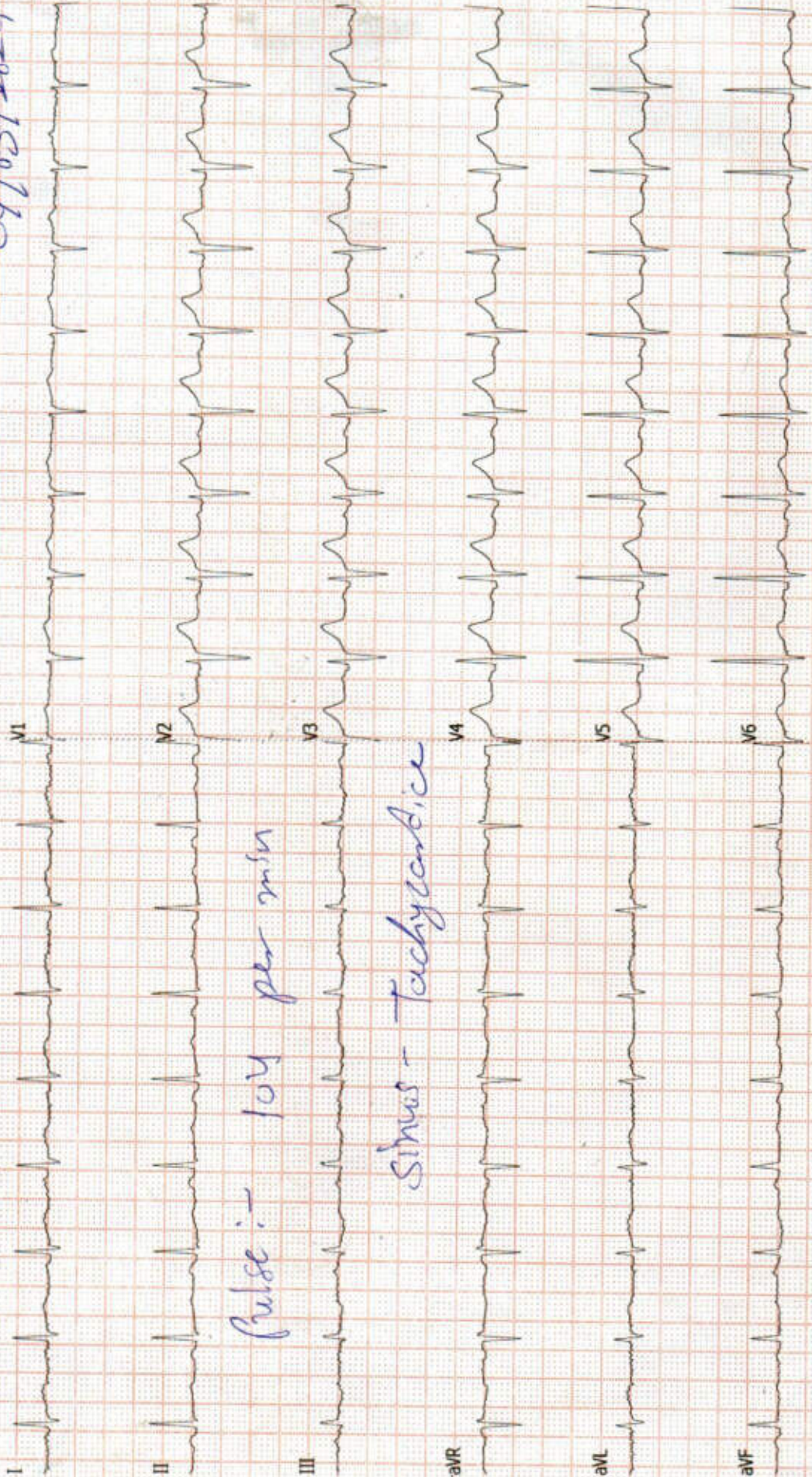
Sex: Male

Hospital:

Dr. Avinash Bhatnagar
MBBS D-Cardio
G-3946

HR : 105 bpm
PR : 136 ms
QRS : 84 ms
QT/QTc : 326/430 ms
P/QRS/T : 44/55/29 deg.
RV5/SV1 : 1.048/-0.558 mv
RV5+SV1 : 1.606 mv

0.67Hz - 35Hz AC 50Hz 25 mm/s 10 mm/mv



Pulse :- 104 per min
Sinus - Tachycardia

Need to be confirmed by doctor. Doctor Name: _____

09/03/2024

Dr. Dinesh S. Modh

M.D., D.M.R.E. (Radiodiagnosis)

Consultant Radiologist & Sonologist

Ex. Junior Lecturer, B.J. Medical College, Civil Hospital, A'bad.

VIDHI
DIAGNOSTICS



Patient's name : KANUBHAI THAKOR
Reg. ID : R-14172-23
Referred by : MEDI WHEEL

Age/Sex : 44 Years/Male
Accession : 23721
Date : 09/03/2024

USG ABDOMEN

LIVER: Liver is normal in size and bright in echotexture s/o fatty liver grade1. Intrahepatic biliary radicals appear normal.

Portal vein is normal in caliber. Common Bile duct is normal in course & caliber. No e/o calculus is seen in biliary tree.

GALL BLADDER: is distended & appear normal. No e/o calculus or cholecystitis is seen. GB wall thickness appears normal. No evidence of pericholecystic fluid is seen.

SPLEEN: Spleen is normal in size & shows normal echo texture. No evidence of diffuse or focal lesion is seen. Splenic vein appears normal.

PANCREAS: Pancreas appears normal in size & echotexture. No evidence of diffuse or focal lesion is seen. Main pancreatic duct is normal.

KIDNEY: Both kidneys appear normal in size and echopattern. Corticomedullary differentiation is maintained.

No evidence of calculus or hydronephrosis is seen on both sides.
Both supra renal region appear normal.

No evidence of pre & para aortic lymphadenopathy is seen.

Gas filled non-dilated bowel loops are seen in abdomen.

No evidence of free fluid is seen in abdomen.

No evidence of dilated or thickened bowel loops is seen.

Urinary bladder appears normal. No e/o calculus or mass lesion is seen.

Prostate appears normal in size & echopattern.

Thanks for reference.

Dr. Dinesh S. Modh

MD D.M.R.E. (Radiodiagnosis)

DR DINESH S. MODH

M.D. DMRE(RADIODIAGNOSIS)

ISO 9001:2015 Certified Diagnostics Center

Vidhi Imaging Center

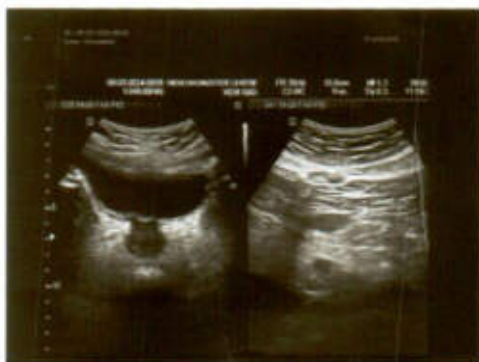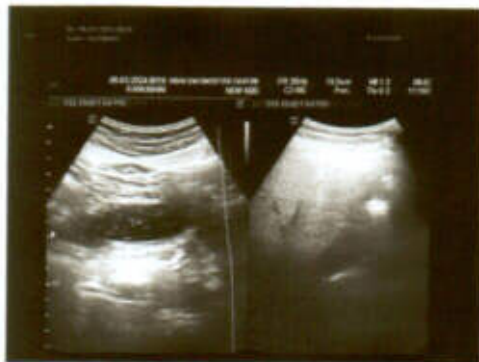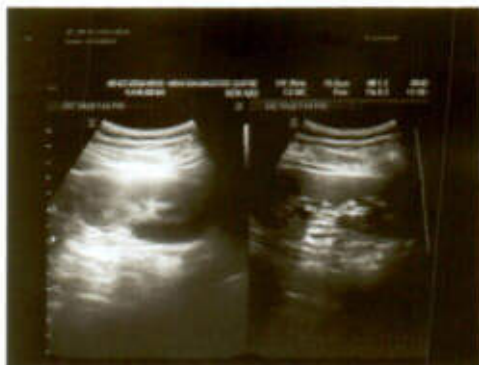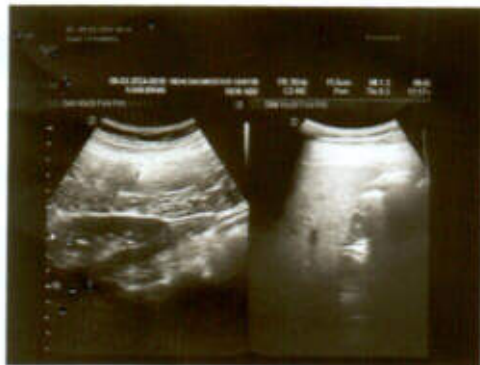L-86, Swatantra Senani Nagar, Opp. Indian Oil Petrol Pump, Akhbarnagar Circle, **Nava Vada**, Ahmedabad - 380 013.

Phone : (Radiology) 079-2762 1406 | M. 98799 29406, 98250 09406 | Time (Radiology) : Mon. to Sat. 9 am to 2 pm, 5 to 9 pm, Sunday 9 am to 12 Noon

E-mail : vidhidiagnostics@gmail.com, Website : www.vidhidiagnostics.com

Multislice CT Scan | CBCT-Dental Scan | Live 3D-4D Sonography | Colour Doppler | Echo Cardiography | Interventional Radiology | Maxillofacial Radiology | Fetal Medicine
Digital X-Ray | Digital Mammography | Digital OPG/TMJ | ECG/TMT/PFT/EEG/EMG | Audiometry | Pathology Laboratory | Health Check Up Plans | Pre Employment Check Up

CT SCAN & CBCT FACILITY NOW AVAILABLE



Dr. Dinesh S. Modh

M.D., D.M.R.E. (Radiodiagnosis)

Consultant Radiologist & Sonologist

Ex. Junior Lecturer, B.J. Medical College, Civil Hospital, A'bad.



Patient's name : KANUBHAI THAKOR
Reg. ID : R-14172-23
Referred by : MEDI WHEEL

Age/Sex : 44 Years/Male
Accession : 23721
Date : 09/03/2024

2D- ECHO REPORT

FINAL CONCLUSION:

LV IS NORMAL SIZE. GOOD LV SYSTOLIC FUNCTION NO RWMA.
LVEF - 60%. NO CONCENTRIC LVH.
NORMAL LV COMPLANCE.
LA IS NORMAL SIZE. NO LA CLOT.
RV IS NORMAL SIZE. GOOD RV SYSTOLIC FUNCTION.
RA IS NORMAL SIZE.
MITRAL VALVE IS NORMAL. NO MS. NO MR. NO MVP.
AORTIC VALVE IS NORMAL. NO AS. NO AR.
TRICUSPID VALVE IS NORMAL. NO TR. RVSP-24 mmHg. NO PAH.

NO CLOT, NO VEGETATION, NO PERICARDIAL EFFUSION.

DIMENSIONS:

AORTA	2.6 C.M
LEFT ATRIUM	2.7 C.M
LVDD	4.1 C.M.
IVSD	1.0 C.M
PWD	1.0 C.M
LVDS	2.6 C.M.

COLOUR DOPPLER FINDING:

STRUCTURE	VELOCITY m/sec
	Max
PULMONARY VALVE	0.7
MITRAL VALVE	E : 0.7 A: 0.4
AORTIC VALVE	1.0

Dr. Avinash Bhaskar
M.D.S D-Cardio
G-15946

DR AVINASH BHASKAR
CLINICAL CARDIOLOGIST
9924836431

ISO 9001:2015 Certified Diagnostics Center

Vidhi Imaging Center

L-86, Swatantra Senani Nagar, Opp. Indian Oil Petrol Pump, Akhbarnagar Circle, Nava Vadaj, Ahmedabad - 380 013.

Phone : (Radiology) 079-2762 1406 | M. 98799 29406, 98250 09406 | Time (Radiology) : Mon. to Sat. 9 am to 2 pm, 5 to 9 pm, Sunday 9 am to 12 Noon

E-mail : vidhidiagnostics@gmail.com, Website : www.vidhidiagnostics.com

Multislice CT Scan | CBCT-Dental Scan | Live 3D-4D Sonography | Colour Doppler | Echo Cardiography | Interventional Radiology | Maxillofacial Radiology | Fetal Medicine
Digital X-Ray | Digital Mammography | Digital OPG / TMJ | ECG / TMT / PFT / EEG / EMG | Audiometry | Pathology Laboratory | Health Check Up Plans | Pre Employment Check Up

CT SCAN & CBCT FACILITY NOW AVAILABLE

Dr. Dinesh S. Modh

M.D., D.M.R.E. (Radiodiagnosis)

Consultant Radiologist & Sonologist

Ex. Junior Lecturer, B.J. Medical College, Civil Hospital, A'bad.



Patient's name : KANUBHAI THAKOR
Reg. ID : R-14172-23
Referred by : MEDI WHEEL

Age/Sex : 44 Years/Male
Accession : 23721
Date : 09/03/2024

X-RAY CHEST (PA VIEW)

Both lung fields appear normal.
No e/o consolidation or cavitations is seen.
Both costo-phrenic angles appear clear.
Cardiac size is with in normal limits.
Both domes of diaphragm appear normal.
Bony thoracic cage appears normal.

Thanks for reference.

Dr. Dinesh S. Modh
MD DM (Radiodiagnosis)
DR DINESH S. MODH
M.D. DMRE(RADIODIAGNOSIS)

ISO 9001:2015 Certified Diagnostics Center

Vidhi Imaging Center

L-86, Swatantra Senani Nagar, Opp. Indian Oil Petrol Pump, Akhbarnagar Circle, Nava Vada], Ahmedabad - 380 013.

Phone : (Radiology) 079-2762 1406 | M. 98799 29406, 98250 09406 | Time (Radiology) : Mon. to Sat. 9 am to 2 pm, 5 to 9 pm, Sunday 9 am to 12 Noon

E-mail : vidhidiagnostics@gmail.com, Website : www.vidhidiagnostics.com

Multislice CT Scan | CBCT-Dental Scan | Live 3D-4D Sonography | Colour Doppler | Echo Cardiography | Interventional Radiology | Maxillofacial Radiology | Fetal Medicine
Digital X-Ray | Digital Mammography | Digital OPG / TMJ | ECG / TMT / PFT / EEG / EMG | Audiometry | Pathology Laboratory | Health Check Up Plans | Pre Employment Check Up

CT SCAN & CBCT FACILITY NOW AVAILABLE