

Chandan Diagnostic

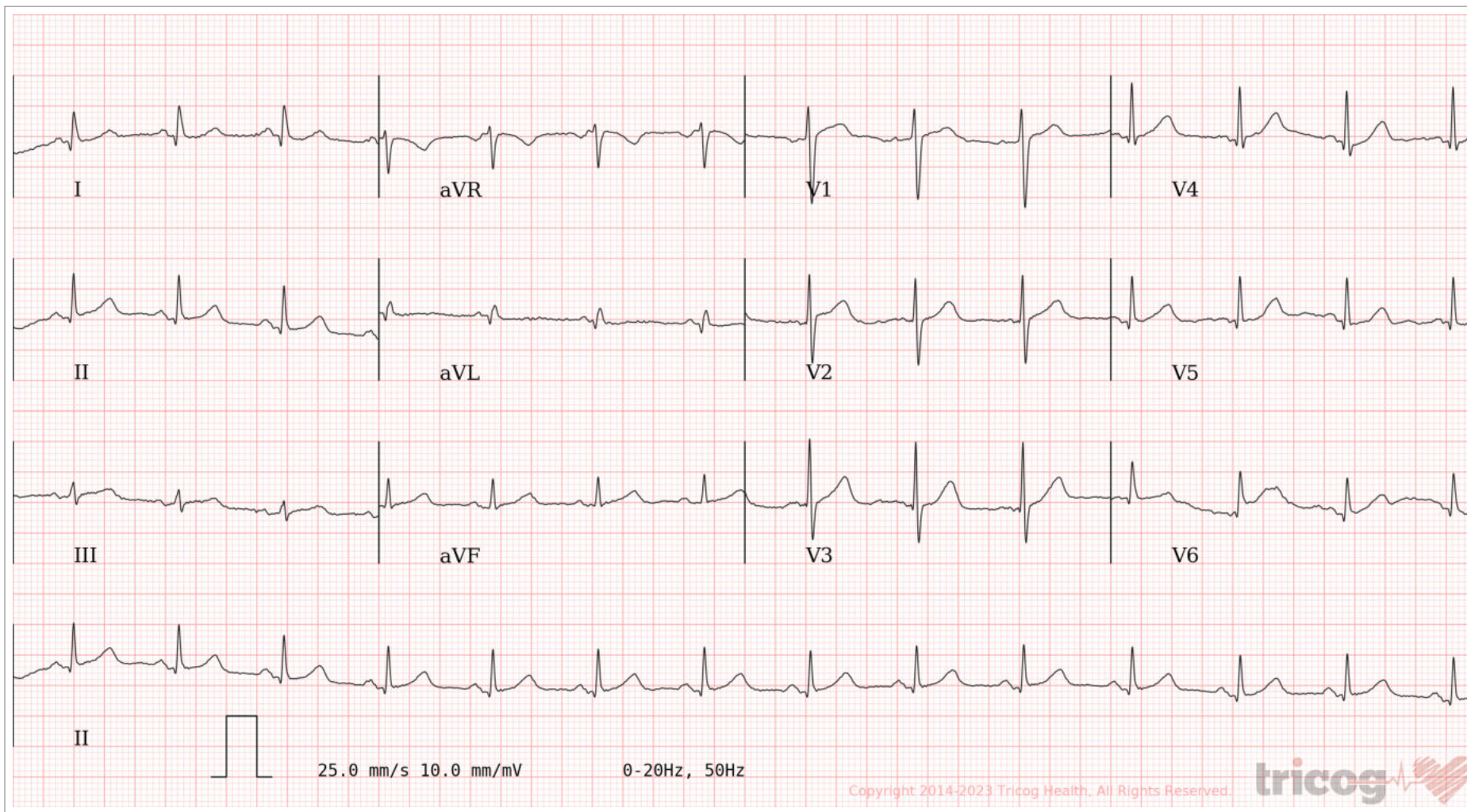



Age / Gender: 44/Male

Date and Time: 8th Apr 23 11:48 AM

Patient ID: CVAR0002132324

Patient Name: Mr. NIRAJ KUMAR SRIVATAV-BOBE31016



AR: 86bpm VR: 86bpm QRSD: 72ms QT: 350ms QTcB: 418ms PRI: 134ms P-R-T: 36° 47° 62°

ECG Within Normal Limits: Sinus Rhythm. Please correlate clinically.

AUTHORIZED BY

Dr. Charit
MD, DM: Cardiology

63382

REPORTED BY

Dr Jamila Tambawala

88212

Disclaimer: Analysis in this report is based on ECG alone and should only be used as an adjunct to clinical history, symptoms and results of other invasive and non-invasive tests and must be interpreted by a qualified physician.

CHANDAN DIAGNOSTIC CENTRE

Name of Company: Bob
Name of Executive: Nitay Kumar Srivastava
Date of Birth: 04/05/1978
Sex: Male / Female
Height: 156 CMs
Weight: 68 KGs
BMI (Body Mass Index): 27.9
Chest (Expiration / Inspiration) 93 / 96 CMs
Abdomen: 91 CMs
Blood Pressure: 114 / 72 mm/Hg
Pulse: 74 BPM - Regular / Irregular
RR: 19 Resp/Min
Ident Mark: Mole on Rt eye (Below the eye)
Any Allergies: No
Vertigo: No
Any Medications: ① Diabetes - Tab Not Conf - 3 months.
Any Surgical History: No
Habits of alcoholism/smoking/tobacco:
Chief Complaints if any: ① Paresthesia Lt leg (swollen in medial)
Lab Investigation Reports: No
Eye Check up vision & Color vision: Both = Mild Color vision.
Left eye: Normal
Right eye: Normal



CHANDAN DIAGNOSTIC CENTRE

Add: 99, Shivaji Nagar Mahmoorganj, Varanasi
Ph: 9235447795,0542-3500227
CIN : U85110DL2003PLC308206



| | | | |
|--------------|--------------------------------------|---------------|------------------------|
| Patient Name | : Mr. NIRAJ KUMAR SRIVATAV-BOBE31016 | Registered On | : 08/Apr/2023 11:06:05 |
| Age/Gender | : 44 Y 0 M 0 D /M | Collected | : N/A |
| UHID/MR NO | : CVAR.0000036877 | Received | : N/A |
| Visit ID | : CVAR0002142324 | Reported | : 08/Apr/2023 12:05:18 |
| Ref Doctor | : Dr.MEDIWHEEL VNS | Status | : Final Report |

DEPARTMENT OF CARDIOLOGY-2D-ECHO

2D ECHO *

2D ECHO & COLOUR DOPPLER REPORT :-

AORTIC VALVES STUDY-

| | | |
|--------------|-----|------|
| AO DIAMETER | 2.6 | Cms. |
| LA DIAMETER | 2.6 | Cms. |
| CUSP OPENING | 1.4 | Cms. |

LEFT VENTRICLE-

| | | |
|-------|-----|-----|
| IVSd | 1.0 | cms |
| LVIDd | 4.4 | cms |
| LVPWd | 1.0 | cms |
| IVSs | 1.5 | cms |
| LVIDs | 2.9 | cms |
| LVPWs | 1.6 | cms |
| EDV | 90 | ml |
| ESV | 33 | ml |

- EJECTION FRACTION : 62 % (60 ± 7 %)
- SHORTENING FRACTION : 33 % (30 ± 5%)

RIGHT VENTRICLE-

- RVIDd : 2.6 cm

DIMENSIONAL IMAGING-

| | |
|---|--------|
| MITRAL VALVE | NORMAL |
| AORTIC VALVE | NORMAL |
| PULMONARY VALVE | NORMAL |
| TRICUSPID VALVE | NORMAL |
| INTER VENTRICULAR SEPTUM | NORMAL |
| INTERATRIAL SEPTUM | NORMAL |
| INTRACARDIAC CLOT / VEGETATION / MYXOMA | ABSENT |
| LEFT ATRIUM | NORMAL |
| LEFT VENTRICLE | NORMAL |
| RIGHT VENTRICLE | NORMAL |
| RIGHT ATRIUM | NORMAL |
| PERICARDIUM | NORMAL |





CHANDAN DIAGNOSTIC CENTRE

Add: 99, Shivaji Nagar Mahmoorganj, Varanasi
Ph: 9235447795, 0542-3500227
CIN : U85110DL2003PLC308206



| | | | |
|--------------|--------------------------------------|---------------|------------------------|
| Patient Name | : Mr. NIRAJ KUMAR SRIVATAV-BOBE31016 | Registered On | : 08/Apr/2023 11:06:05 |
| Age/Gender | : 44 Y 0 M 0 D /M | Collected | : N/A |
| UHID/MR NO | : CVAR.0000036877 | Received | : N/A |
| Visit ID | : CVAR0002142324 | Reported | : 08/Apr/2023 12:05:18 |
| Ref Doctor | : Dr.MEDIWHEEL VNS | Status | : Final Report |

DEPARTMENT OF CARDIOLOGY-2D-ECHO

OTHER NORMAL

COLOUR FLOW MAPPING-

| | VELOCITY (m/s) | PRESSURE GRADIENT (mm/Hg) | REGURGITATION |
|----------------|----------------|---------------------------|---------------|
| MITRAL FLOW | E: A: | NORMAL | TRACE |
| AORTIC FLOW | | NORMAL | ABSENT |
| PULMONARY FLOW | | NORMAL | ABSENT |
| TRICUSPID FLOW | | NORMAL | TRACE |

SUMMARY OF FINDINGS AND ECHOCARDIOGRAPHY DIAGNOSIS-

- LV IS NORMAL IN SIZE AND EJECTION FRACTION. NO LVH. NO RWMA
- OTHER PARAMETERS WITHIN NORMAL RANGE
- IAS AND IVS ARE INTACT, NO SHUNT AT GREAT VESSEL
- NO THRUMBUS /CLOT/ EFFUSION

FINAL IMPRESSION-

- NO RESTING RWMA
- GOOD BIVENTRICULAR SYSTOLIC FUNCTION WITH LVEF 62%
- NO LVH WITH NORMAL DIASTOLIC FUNCTION
- NO CHAMBER DILATATION WITH TRACE MR AND TR
- NO CLOT/ VEGETATION/ PAH/ EFFUSION

*** End Of Report ***



Dr. Ganesh Shankar (MBBS PGDCC)

This report is not for medico legal purpose. If clinical correlation is not established, kindly repeat the test at no additional cost within seven days.

Facilities: Pathology, Bedside Sample Collection, Health Check-ups, Digital X-Ray, ECG (Bedside also), Allergy Testing, Test And Health Check-ups, Ultrasonography, Sonomammography, Bone Mineral Density (BMD), Doppler Studies, 2D Echo, CT Scan, MRI, Blood Bank, TMT, EEG, PFT, OPG, Endoscopy, Digital Mammography, Electromyography (EMG), Nerve Condition Velocity (NCV), Audiometry, Brainstem Evoked Response Audiometry (BERA), Colonoscopy, Ambulance Services, Online Booking Facilities for Diagnostics, Online Report Viewing *
365 Days Open *Facilities Available at Select Location



CHANDAN DIAGNOSTIC CENTRE

Near vision: - *Normal*
Far vision: - *Normal*
Dental check up: - *Normal*
ENT Check up: - *Normal*
Eye Checkup: - *Normal*

Final impression

Certified that I examined Niraj Kumar Srivastava ^{S/o} or D/o
..... is presently in good health and free from any
cardio-respiratory/communicable ailment, ~~he/she~~ is **fit / Unfit** to join any
organization.



Dr. R.C. ROY
MBBS., MD. (Radio Diagnosis)
Reg. No.-26913

Client Signature :-

Niraj

.....
Signature of Medical Examiner

Name & Qualification - Dr. R. C. Roy (MBBS, MD)

Date ... 8.19 / 2023

Place - VARANASI

Chandan Diagnostic Center
39, Shivaji Nagar, Mahmoorganj
Varanasi-221010 (U.P.)
Phone No.: 0542-2223232



CHANDAN DIAGNOSTIC CENTRE

Add: 99, Shivaji Nagar Mahmoorganj, Varanasi
Ph: 9235447795,0542-3500227
CIN : U85110DL2003PLC308206



| | | | |
|--------------|--------------------------------------|---------------|------------------------|
| Patient Name | : Mr. NIRAJ KUMAR SRIVATAV-BOBE31016 | Registered On | : 08/Apr/2023 11:06:05 |
| Age/Gender | : 44 Y 0 M 0 D /M | Collected | : N/A |
| UHID/MR NO | : CVAR.0000036877 | Received | : N/A |
| Visit ID | : CVAR0002142324 | Reported | : 08/Apr/2023 12:05:18 |
| Ref Doctor | : Dr.MEDIWHEEL VNS | Status | : Final Report |

DEPARTMENT OF CARDIOLOGY-2D-ECHO

2D ECHO *

2D ECHO & COLOUR DOPPLER REPORT :-

AORTIC VALVES STUDY-

| | | |
|--------------|-----|------|
| AO DIAMETER | 2.6 | Cms. |
| LA DIAMETER | 2.6 | Cms. |
| CUSP OPENING | 1.4 | Cms. |

LEFT VENTRICLE-

| | | |
|-------|-----|-----|
| IVSd | 1.0 | cms |
| LVIDd | 4.4 | cms |
| LVPWd | 1.0 | cms |
| IVSs | 1.5 | cms |
| LVIDs | 2.9 | cms |
| LVPWs | 1.6 | cms |
| EDV | 90 | ml |
| ESV | 33 | ml |

- EJECTION FRACTION : 62 % (60 ± 7 %)
- SHORTENING FRACTION : 33 % (30 ± 5%)

RIGHT VENTRICLE-

- RVIDd : 2.6 cm

DIMENSIONAL IMAGING-

| | |
|---|--------|
| MITRAL VALVE | NORMAL |
| AORTIC VALVE | NORMAL |
| PULMONARY VALVE | NORMAL |
| TRICUSPID VALVE | NORMAL |
| INTER VENTRICULAR SEPTUM | NORMAL |
| INTERATRIAL SEPTUM | NORMAL |
| INTRACARDIAC CLOT / VEGETATION / MYXOMA | ABSENT |
| LEFT ATRIUM | NORMAL |
| LEFT VENTRICLE | NORMAL |
| RIGHT VENTRICLE | NORMAL |
| RIGHT ATRIUM | NORMAL |
| PERICARDIUM | NORMAL |





CHANDAN DIAGNOSTIC CENTRE

Add: 99, Shivaji Nagar Mahmoorganj, Varanasi
Ph: 9235447795, 0542-3500227
CIN : U85110DL2003PLC308206



| | | | |
|--------------|--------------------------------------|---------------|------------------------|
| Patient Name | : Mr. NIRAJ KUMAR SRIVATAV-BOBE31016 | Registered On | : 08/Apr/2023 11:06:05 |
| Age/Gender | : 44 Y 0 M 0 D /M | Collected | : N/A |
| UHID/MR NO | : CVAR.0000036877 | Received | : N/A |
| Visit ID | : CVAR0002142324 | Reported | : 08/Apr/2023 12:05:18 |
| Ref Doctor | : Dr.MEDIWHEEL VNS | Status | : Final Report |

DEPARTMENT OF CARDIOLOGY-2D-ECHO

OTHER

NORMAL

COLOUR FLOW MAPPING-

| | VELOCITY (m/s) | PRESSURE GRADIENT (mm/Hg) | REGURGITATION |
|----------------|----------------|---------------------------|---------------|
| MITRAL FLOW | E: A: | NORMAL | TRACE |
| AORTIC FLOW | | NORMAL | ABSENT |
| PULMONARY FLOW | | NORMAL | ABSENT |
| TRICUSPID FLOW | | NORMAL | TRACE |

SUMMARY OF FINDINGS AND ECHOCARDIOGRAPHY DIAGNOSIS-

- LV IS NORMAL IN SIZE AND EJECTION FRACTION. NO LVH. NO RWMA
- OTHER PARAMETERS WITHIN NORMAL RANGE
- IAS AND IVS ARE INTACT, NO SHUNT AT GREAT VESSEL
- NO THRUMBUS /CLOT/ EFFUSION

FINAL IMPRESSION-

- NO RESTING RWMA
- GOOD BIVENTRICULAR SYSTOLIC FUNCTION WITH LVEF 62%
- NO LVH WITH NORMAL DIASTOLIC FUNCTION
- NO CHAMBER DILATATION WITH TRACE MR AND TR
- NO CLOT/ VEGETATION/ PAH/ EFFUSION

*** End Of Report ***



Dr. Ganesh Shankar (MBBS PGDCC)

This report is not for medico legal purpose. If clinical correlation is not established, kindly repeat the test at no additional cost within seven days.

Facilities: Pathology, Bedside Sample Collection, Health Check-ups, Digital X-Ray, ECG (Bedside also), Allergy Testing, Test And Health Check-ups, Ultrasonography, Sonomammography, Bone Mineral Density (BMD), Doppler Studies, 2D Echo, CT Scan, MRI, Blood Bank, TMT, EEG, PFT, OPG, Endoscopy, Digital Mammography, Electromyography (EMG), Nerve Condition Velocity (NCV), Audiometry, Brainstem Evoked Response Audiometry (BERA), Colonoscopy, Ambulance Services, Online Booking Facilities for Diagnostics, Online Report Viewing *
365 Days Open *Facilities Available at Select Location





D63/6B-99, Shivaji Nagar Colony,
Mahmoorganj, Varanasi, Uttar Pradesh
221010, India

Latitude

25.305399°

Longitude

82.979020°

LOCAL 13:09:45

SATURDAY 04.08.2023

GMT 07:39:45

ALTITUDE 42 METER