

Patient Name : Mrs.CHETANA VYKUNTAIAH Y K	Collected : 26/Oct/2024 10:22AM
Age/Gender : 40 Y 9 M 12 D/F	Received : 26/Oct/2024 12:34PM
UHID/MR No : CMYS.0000062465	Reported : 26/Oct/2024 02:03PM
Visit ID : CMYSOPV130900	Status : Final Report
Ref Doctor : Self	Sponsor Name : ARCOFEMI HEALTHCARE LIMITED
Emp/Auth/TPA ID : 22S35011	

DEPARTMENT OF HAEMATOLOGY

ARCOFEMI - MEDIWHEEL - FULL BODY ANNUAL PLUS CHECK ADVANCED - FEMALE - 2D ECHO - PAN INDIA - FY232

Test Name	Result	Unit	Bio. Ref. Interval	Method
HEMOGRAM , WHOLE BLOOD EDTA				
HAEMOGLOBIN	14.3	g/dL	12.5-15	Spectrophotometer
PCV	41.70	%	36-46	Electronic pulse & Calculation
RBC COUNT	4.43	Million/cu.mm	3.8-4.8	Electrical Impedance
MCV	94.1	fL	83-101	Calculated
MCH	32.3	pg	27-32	Calculated
MCHC	34.4	g/dL	31.5-34.5	Calculated
R.D.W	11.5	%	11.6-14	Calculated
TOTAL LEUCOCYTE COUNT (TLC)	10,300	cells/cu.mm	4000-10000	Electrical Impedance
DIFFERENTIAL LEUCOCYTIC COUNT (DLC)				
NEUTROPHILS	77	%	40-80	Electrical Impedance
LYMPHOCYTES	16	%	20-40	Electrical Impedance
EOSINOPHILS	1	%	1-6	Electrical Impedance
MONOCYTES	5	%	2-10	Electrical Impedance
BASOPHILS	1	%	0-2	Electrical Impedance
ABSOLUTE LEUCOCYTE COUNT				
NEUTROPHILS	7931	Cells/cu.mm	2000-7000	Calculated
LYMPHOCYTES	1648	Cells/cu.mm	1000-3000	Calculated
EOSINOPHILS	103	Cells/cu.mm	20-500	Calculated
MONOCYTES	515	Cells/cu.mm	200-1000	Calculated
BASOPHILS	103	Cells/cu.mm	0-100	Calculated
Neutrophil lymphocyte ratio (NLR)	4.81		0.78- 3.53	Calculated
PLATELET COUNT	287000	cells/cu.mm	150000-410000	Electrical impedance
ERYTHROCYTE SEDIMENTATION RATE (ESR)	22	mm at the end of 1 hour	0-20	Modified Westergren
PERIPHERAL SMEAR				

R.B.C: Majority are normocytic normochromic.

W.B.C: Are normal in number,morphology and increase in neutrophils.

Platelets: Adequate and are seen in singles and clumps.

Hemoparasites: Not seen.

Page 2 of 14



Dr. PAVAN KUMAR M
M.B.B.S,M.D(Pathology)
Consultant Pathologist

SIN No:MYS241001482




Patient Name : Mrs.CHETANA VYKUNTAIAH Y K	Collected : 26/Oct/2024 10:22AM
Age/Gender : 40 Y 9 M 12 D/F	Received : 26/Oct/2024 12:34PM
UHID/MR No : CMYS.0000062465	Reported : 26/Oct/2024 03:20PM
Visit ID : CMYSOPV130900	Status : Final Report
Ref Doctor : Self	Sponsor Name : ARCOFEMI HEALTHCARE LIMITED
Emp/Auth/TPA ID : 22S35011	

DEPARTMENT OF HAEMATOLOGY

ARCOFEMI - MEDIWHEEL - FULL BODY ANNUAL PLUS CHECK ADVANCED - FEMALE - 2D ECHO - PAN INDIA - FY232

Test Name	Result	Unit	Bio. Ref. Interval	Method
BLOOD GROUP ABO AND RH FACTOR , WHOLE BLOOD EDTA				
BLOOD GROUP TYPE	B			Forward & Reverse Grouping with Slide/Tube Aggluti
Rh TYPE	POSITIVE			Forward & Reverse Grouping with Slide/Tube Agglutination



Dr. PAVAN KUMAR M
M.B.B.S,M.D(Pathology)
Consultant Pathologist

SIN No:MYS241001482



Patient Name : Mrs.CHETANA VYKUNTAIAH Y K	Collected : 26/Oct/2024 01:37PM
Age/Gender : 40 Y 9 M 12 D/F	Received : 26/Oct/2024 02:04PM
UHID/MR No : CMYS.0000062465	Reported : 26/Oct/2024 02:51PM
Visit ID : CMYSOPV130900	Status : Final Report
Ref Doctor : Self	Sponsor Name : ARCOFEMI HEALTHCARE LIMITED
Emp/Auth/TPA ID : 22S35011	

DEPARTMENT OF BIOCHEMISTRY

ARCOFEMI - MEDIWHEEL - FULL BODY ANNUAL PLUS CHECK ADVANCED - FEMALE - 2D ECHO - PAN INDIA - FY232

Test Name	Result	Unit	Bio. Ref. Interval	Method
GLUCOSE, FASTING , NAF PLASMA	89	mg/dl	74-106	GOD, POD

Comment:

As per American Diabetes Guidelines, 2023

Fasting Glucose Values in mg/dL	Interpretation
70-100 mg/dL	Normal
100-125 mg/dL	Prediabetes
≥126 mg/dL	Diabetes
<70 mg/dL	Hypoglycemia

Note:

- 1.The diagnosis of Diabetes requires a fasting plasma glucose of > or = 126 mg/dL and/or a random / 2 hr post glucose value of > or = 200 mg/dL on at least 2 occasions.
2. Very high glucose levels (>450 mg/dL in adults) may result in Diabetic Ketoacidosis & is considered critical.

Test Name	Result	Unit	Bio. Ref. Interval	Method
GLUCOSE, POST PRANDIAL (PP), 2 HOURS , SODIUM FLUORIDE PLASMA (2 HR)	96	mg/dl	70-140	GOD, POD

Comment:

It is recommended that FBS and PPBS should be interpreted with respect to their Biological reference ranges and not with each other.

Conditions which may lead to lower postprandial glucose levels as compared to fasting glucose levels may be due to reactive hypoglycemia, dietary meal content, duration or timing of sampling after food digestion and absorption, medications such as insulin preparations, sulfonylureas, amylin analogues, or conditions such as overproduction of insulin.



Dr. PAVAN KUMAR M
M.B.B.S,M.D(Pathology)
Consultant Pathologist

SIN No:MYS241001535



Patient Name : Mrs.CHETANA VYKUNTAIAH Y K	Collected : 26/Oct/2024 10:22AM
Age/Gender : 40 Y 9 M 12 D/F	Received : 26/Oct/2024 01:52PM
UHID/MR No : CMYS.0000062465	Reported : 26/Oct/2024 03:25PM
Visit ID : CMYSOPV130900	Status : Final Report
Ref Doctor : Self	Sponsor Name : ARCOFEMI HEALTHCARE LIMITED
Emp/Auth/TPA ID : 22S35011	

DEPARTMENT OF BIOCHEMISTRY

ARCOFEMI - MEDIWHEEL - FULL BODY ANNUAL PLUS CHECK ADVANCED - FEMALE - 2D ECHO - PAN INDIA - FY232

Test Name	Result	Unit	Bio. Ref. Interval	Method
HBA1C (GLYCATED HEMOGLOBIN) , WHOLE BLOOD EDTA				
HBA1C, GLYCATED HEMOGLOBIN	4.6	%		HPLC
ESTIMATED AVERAGE GLUCOSE (eAG)	85	mg/dL		Calculated

Comment:

Reference Range as per American Diabetes Association (ADA) 2023 Guidelines:

REFERENCE GROUP	HBA1C %
NON DIABETIC	<5.7
PREDIABETES	5.7 – 6.4
DIABETES	≥ 6.5
DIABETICS	
EXCELLENT CONTROL	6 – 7
FAIR TO GOOD CONTROL	7 – 8
UNSATISFACTORY CONTROL	8 – 10
POOR CONTROL	>10

Note: Dietary preparation or fasting is not required.

1. HbA1c is recommended by American Diabetes Association for Diagnosing Diabetes and monitoring Glycemic Control by American Diabetes Association guidelines 2023.

2. Trends in HbA1c values is a better indicator of Glycemic control than a single test.

3. Low HbA1c in Non-Diabetic patients are associated with Anemia (Iron Deficiency/Hemolytic), Liver Disorders, Chronic Kidney Disease. Clinical Correlation is advised in interpretation of low Values.

4. Falsely low HbA1c (below 4%) may be observed in patients with clinical conditions that shorten erythrocyte life span or decrease mean erythrocyte age. HbA1c may not accurately reflect glycemic control when clinical conditions that affect erythrocyte survival are present.

5. In cases of Interference of Hemoglobin variants in HbA1C, alternative methods (Fructosamine) estimation is recommended for Glycemic Control

A: HbF >25%

B: Homozygous Hemoglobinopathy.

(Hb Electrophoresis is recommended method for detection of Hemoglobinopathy)



Dr. PAVAN KUMAR M
M.B.B.S,M.D(Pathology)
Consultant Pathologist

SIN No:MYS241001486



Patient Name : Mrs.CHETANA VYKUNTAIAH Y K	Collected : 26/Oct/2024 10:22AM
Age/Gender : 40 Y 9 M 12 D/F	Received : 26/Oct/2024 12:41PM
UHID/MR No : CMYS.0000062465	Reported : 26/Oct/2024 02:44PM
Visit ID : CMYSOPV130900	Status : Final Report
Ref Doctor : Self	Sponsor Name : ARCOFEMI HEALTHCARE LIMITED
Emp/Auth/TPA ID : 22S35011	

DEPARTMENT OF BIOCHEMISTRY

ARCOFEMI - MEDIWHEEL - FULL BODY ANNUAL PLUS CHECK ADVANCED - FEMALE - 2D ECHO - PAN INDIA - FY232

Test Name	Result	Unit	Bio. Ref. Interval	Method
LIPID PROFILE , SERUM				
TOTAL CHOLESTEROL	152	mg/dl	0-200	CHOD
TRIGLYCERIDES	83	mg/dl	0-150	GPO, Trinder
HDL CHOLESTEROL	49	mg/dL	40-60	CHOD
NON-HDL CHOLESTEROL	103	mg/dL	<130	Calculated
LDL CHOLESTEROL	86.44	mg/dL	<100	Calculated
VLDL CHOLESTEROL	16.54	mg/dL	<30	Calculated
CHOL / HDL RATIO	3.10		0-4.97	Calculated
ATHEROGENIC INDEX (AIP)	0.10		<0.11	Calculated

Comment:

Reference Interval as per National Cholesterol Education Program (NCEP) Adult Treatment Panel III Report.

	Desirable	Borderline High	High	Very High
TOTAL CHOLESTEROL	< 200	200 - 239	≥ 240	
TRIGLYCERIDES	<150	150 - 199	200 - 499	≥ 500
LDL	Optimal < 100 Near Optimal 100-129	130 - 159	160 - 189	≥ 190
HDL	≥ 60			
NON-HDL CHOLESTEROL	Optimal <130; Above Optimal 130-159	160-189	190-219	>220



Dr. PAVAN KUMAR M
M.B.B.S,M.D(Pathology)
Consultant Pathologist

SIN No:MYS241001484



Patient Name : Mrs.CHETANA VYKUNTAIAH Y K	Collected : 26/Oct/2024 10:22AM
Age/Gender : 40 Y 9 M 12 D/F	Received : 26/Oct/2024 12:41PM
UHID/MR No : CMYS.0000062465	Reported : 26/Oct/2024 02:41PM
Visit ID : CMYSOPV130900	Status : Final Report
Ref Doctor : Self	Sponsor Name : ARCOFEMI HEALTHCARE LIMITED
Emp/Auth/TPA ID : 22S35011	

DEPARTMENT OF BIOCHEMISTRY

ARCOFEMI - MEDIWHEEL - FULL BODY ANNUAL PLUS CHECK ADVANCED - FEMALE - 2D ECHO - PAN INDIA - FY232

Test Name	Result	Unit	Bio. Ref. Interval	Method
LIVER FUNCTION TEST (LFT) , SERUM				
BILIRUBIN, TOTAL	0.45	mg/dl	0-1.2	NBD
BILIRUBIN CONJUGATED (DIRECT)	0.16	mg/dl	0-0.2	Diazotized sulfanilic acid
BILIRUBIN (INDIRECT)	0.29	mg/dL	0.0-1.1	Dual Wavelength
ALANINE AMINOTRANSFERASE (ALT/SGPT)	12	U/l	0-45	IFCC
ASPARTATE AMINOTRANSFERASE (AST/SGOT)	18.0	U/l	0-31	IFCC
AST (SGOT) / ALT (SGPT) RATIO (DE RITIS)	1.5		<1.15	Calculated
ALKALINE PHOSPHATASE	68.00	U/l	42-98	IFCC (AMP buffer)
PROTEIN, TOTAL	6.60	g/dl	6.4-8.3	Biuret
ALBUMIN	4.30	g/dl	3.5-5.2	Bromcresol Green
GLOBULIN	2.30	g/dL	2.0-3.5	Calculated
A/G RATIO	1.87		0.9-2.0	Calculated

Comment:

LFT results reflect different aspects of the health of the liver, i.e., hepatocyte integrity (AST & ALT), synthesis and secretion of bile (Bilirubin, ALP), cholestasis (ALP, GGT), protein synthesis (Albumin) Common patterns seen:

1. Hepatocellular Injury:

*AST – Elevated levels can be seen. However, it is not specific to liver and can be raised in cardiac and skeletal injuries.*ALT – Elevated levels indicate hepatocellular damage. It is considered to be most specific lab test for hepatocellular injury. Values also correlate well with increasing BMI. Disproportionate increase in AST, ALT compared with ALP. AST: ALT (ratio) – In case of hepatocellular injury AST: ALT > 1 In Alcoholic Liver Disease AST: ALT usually >2. This ratio is also seen to be increased in NAFLD, Wilson’s diseases, Cirrhosis, but the increase is usually not >2.

2. Cholestatic Patten:*ALP – Disproportionate increase in ALP compared with AST, ALT. ALP elevation also seen in pregnancy, impacted by age and sex.*Bilirubin elevated- predominantly direct , To establish the hepatic origin correlation with elevated GGT helps.

3. Synthetic function impairment:*Albumin- Liver disease reduces albumin levels, Correlation with PT (Prothrombin Time) helps.

4. Associated tests for assessment of liver fibrosis - Fibrosis-4 and APRI Index.



Dr. PAVAN KUMAR M
M.B.B.S,M.D(Pathology)
Consultant Pathologist

SIN No:MYS241001484



Patient Name : Mrs.CHETANA VYKUNTAIAH Y K	Collected : 26/Oct/2024 10:22AM
Age/Gender : 40 Y 9 M 12 D/F	Received : 26/Oct/2024 12:41PM
UHID/MR No : CMYS.0000062465	Reported : 26/Oct/2024 02:58PM
Visit ID : CMYSOPV130900	Status : Final Report
Ref Doctor : Self	Sponsor Name : ARCOFEMI HEALTHCARE LIMITED
Emp/Auth/TPA ID : 22S35011	

DEPARTMENT OF BIOCHEMISTRY

ARCOFEMI - MEDIWHEEL - FULL BODY ANNUAL PLUS CHECK ADVANCED - FEMALE - 2D ECHO - PAN INDIA - FY232

Test Name	Result	Unit	Bio. Ref. Interval	Method
RENAL PROFILE/KIDNEY FUNCTION TEST (RFT/KFT) , SERUM				
CREATININE	0.64	mg/dL	0.51-1.04	Enzymatic colorimetric
UREA	22.44	mg/dl	13-43	Urease, UV
BLOOD UREA NITROGEN	10.5	mg/dL	8.0 - 23.0	Calculated
URIC ACID	3.60	mg/dL	2.6-6	Uricase
CALCIUM	9.40	mg/dl	8.6-10.3	Arsenazo III
PHOSPHORUS, INORGANIC	3.32	mg/dl	2.7-4.5	Molybdate
SODIUM	139	mmol/L	135-145	Direct ISE
POTASSIUM	4.2	mmol/L	3.5-5.1	Direct ISE
CHLORIDE	107	mmol/L	98 - 107	Direct ISE
PROTEIN, TOTAL	6.60	g/dl	6.4-8.3	Biuret
ALBUMIN	4.30	g/dl	3.5-5.2	Bromcresol Green
GLOBULIN	2.30	g/dL	2.0-3.5	Calculated
A/G RATIO	1.87		0.9-2.0	Calculated



Dr. PAVAN KUMAR M
M.B.B.S.,M.D(Pathology)
Consultant Pathologist

SIN No:MYS241001484




Patient Name : Mrs.CHETANA VYKUNTAIAH Y K	Collected : 26/Oct/2024 10:22AM
Age/Gender : 40 Y 9 M 12 D/F	Received : 26/Oct/2024 12:41PM
UHID/MR No : CMYS.0000062465	Reported : 26/Oct/2024 02:44PM
Visit ID : CMYSOPV130900	Status : Final Report
Ref Doctor : Self	Sponsor Name : ARCOFEMI HEALTHCARE LIMITED
Emp/Auth/TPA ID : 22S35011	

DEPARTMENT OF BIOCHEMISTRY

ARCOFEMI - MEDIWHEEL - FULL BODY ANNUAL PLUS CHECK ADVANCED - FEMALE - 2D ECHO - PAN INDIA - FY232

Test Name	Result	Unit	Bio. Ref. Interval	Method
GAMMA GLUTAMYL TRANSPEPTIDASE (GGT) , SERUM	10.00	U/l	0-38	IFCC



Dr. PAVAN KUMAR M
M.B.B.S,M.D(Pathology)
Consultant Pathologist

SIN No:MYS241001484



Patient Name	: Mrs.CHETANA VYKUNTAIAH Y K	Collected	: 26/Oct/2024 10:22AM
Age/Gender	: 40 Y 9 M 12 D/F	Received	: 26/Oct/2024 12:41PM
UHID/MR No	: CMYS.0000062465	Reported	: 26/Oct/2024 02:58PM
Visit ID	: CMYSOPV130900	Status	: Final Report
Ref Doctor	: Self	Sponsor Name	: ARCOFEMI HEALTHCARE LIMITED
Emp/Auth/TPA ID	: 22S35011		

DEPARTMENT OF IMMUNOLOGY

ARCOFEMI - MEDIWHEEL - FULL BODY ANNUAL PLUS CHECK ADVANCED - FEMALE - 2D ECHO - PAN INDIA - FY232

High	High	High	High	Pituitary Adenoma; TSHoma/Thyrotropinoma
------	------	------	------	--



Dr. PAVAN KUMAR M
M.B.B.S,M.D(Pathology)
Consultant Pathologist

SIN No:MYS241001485



Patient Name : Mrs.CHETANA VYKUNTAIAH Y K	Collected : 26/Oct/2024 10:22AM
Age/Gender : 40 Y 9 M 12 D/F	Received : 26/Oct/2024 01:12PM
UHID/MR No : CMYS.0000062465	Reported : 26/Oct/2024 02:23PM
Visit ID : CMYSOPV130900	Status : Final Report
Ref Doctor : Self	Sponsor Name : ARCOFEMI HEALTHCARE LIMITED
Emp/Auth/TPA ID : 22S35011	

DEPARTMENT OF CLINICAL PATHOLOGY

ARCOFEMI - MEDIWHEEL - FULL BODY ANNUAL PLUS CHECK ADVANCED - FEMALE - 2D ECHO - PAN INDIA - FY232

Test Name	Result	Unit	Bio. Ref. Interval	Method
COMPLETE URINE EXAMINATION (CUE) , URINE				
PHYSICAL EXAMINATION				
COLOUR	PALE YELLOW		PALE YELLOW	Visual
TRANSPARENCY	CLEAR		CLEAR	Physical Measurement
pH	6.0		5-7.5	Double Indicator
SP. GRAVITY	1.010		1.002-1.030	Bromothymol Blue
BIOCHEMICAL EXAMINATION				
URINE PROTEIN	NEGATIVE		NEGATIVE	Protein Error Of Indicator
GLUCOSE	NEGATIVE		NEGATIVE	Glucose Oxidase
URINE BILIRUBIN	NEGATIVE		NEGATIVE	Azo Coupling Reaction
URINE KETONES (RANDOM)	NEGATIVE		NEGATIVE	Sodium Nitro Prusside
UROBILINOGEN	NORMAL		NORMAL	Modified Ehrlich Reaction
NITRITE	NEGATIVE		NEGATIVE	Diazotization
LEUCOCYTE ESTERASE	NEGATIVE		NEGATIVE	Leucocyte Esterase
CENTRIFUGED SEDIMENT WET MOUNT AND MICROSCOPY				
PUS CELLS	4 - 6	/hpf	0-5	Microscopy
EPITHELIAL CELLS	1 - 2	/hpf	<10	Microscopy
RBC	NIL	/hpf	0-2	Microscopy
CASTS	NIL		0-2 Hyaline Cast	Microscopy
CRYSTALS	ABSENT		ABSENT	Microscopy

Comment:

All urine samples are checked for adequacy and suitability before examination. All abnormal chemical examination are rechecked and verified by manual methods. Microscopy findings are reported as an average of 10 high power fields.



Dr. PAVAN KUMAR M
M.B.B.S,M.D(Pathology)
Consultant Pathologist

SIN No:MYS241001481



Patient Name : Mrs.CHETANA VYKUNTAIAH Y K	Collected : 26/Oct/2024 10:22AM
Age/Gender : 40 Y 9 M 12 D/F	Received : 26/Oct/2024 01:13PM
UHID/MR No : CMYS.0000062465	Reported : 26/Oct/2024 01:58PM
Visit ID : CMYSOPV130900	Status : Final Report
Ref Doctor : Self	Sponsor Name : ARCOFEMI HEALTHCARE LIMITED
Emp/Auth/TPA ID : 22S35011	

DEPARTMENT OF CLINICAL PATHOLOGY

ARCOFEMI - MEDIWHEEL - FULL BODY ANNUAL PLUS CHECK ADVANCED - FEMALE - 2D ECHO - PAN INDIA - FY232

Test Name	Result	Unit	Bio. Ref. Interval	Method
URINE GLUCOSE(POST PRANDIAL)	NEGATIVE		NEGATIVE	GOD-POD

Test Name	Result	Unit	Bio. Ref. Interval	Method
URINE GLUCOSE(FASTING)	NEGATIVE		NEGATIVE	GOD-POD

*** End Of Report ***



Dr. PAVAN KUMAR M
M.B.B.S,M.D(Pathology)
Consultant Pathologist

SIN No:MYS241001488



Patient Name	: Mrs. Chetana Vykuntaiah Y K	Age	: 40Yrs 9Mths 16Days
UHID	: CMYS.0000062465	OP Visit No.	: CMYSOPV130900
Printed On	: 29-10-2024 11:39 AM	Advised/Pres Doctor	: --
Department	: Radiology	Qualification	: --
Referred By	: Self	Registration No.	: --
Employeer Id	: 22S35011		

DEPARTMENT OF RADIOLOGY

LIVER: It is normal in size and echotexture. No focal lesions seen. IHBR are not dilated. CBD and Portal vein are normal.

GALL BLADDER: It is well distended and normal. No calculi seen.

SPLEEN: It is normal in size, outline and echopattern. No e/o focal lesions.

PANCREAS: It is normal.

RIGHT KIDNEY: It measures 9.5 cm with parenchymal thickness of 1.2cm. It is normal in size, outline and echotexture. No e/o calculus or hydronephrosis seen.

LEFT KIDNEY: It measures 9.7cm with parenchymal thickness of 1.2cm. It is normal in size, outline and echotexture. No e/o calculus or hydronephrosis seen.

URINARY BLADDER: It is well distended. The UB wall is normal. No calculi seen.

UTERUS: It is anteverted and measures 7.8x4.1x 6.2cm with ET=7.7 mm. It is normal in size, outline and echotexture. No mass lesion.

Minimally POD collection .

Rt. OVARY: It measures 2.9x1.8cm. It is normal. No mass lesion seen.

Lt. OVARY: It measures 2.6x 2.2cm. It is normal. No mass lesion seen.

OTHERS: No e/o free fluid in the abdomen. No e/o lymphadenopathy. No e/o gut wall thickening. No mass lesion seen in the abdomen.

IMPRESSION: NORMAL STUDY.

---End Of The Report---



Dr.CHETAN HOLEPPAGOL
MBBS, DNB(RADIO DIAGNOSIS)
90037
Radiology

Patient Name : Mrs. Chetana Vykuntaiah Y K Age : 40Yrs 9Mths 16Days
UHID : CMYS.0000062465 OP Visit No. : CMYSOPV130900
Printed On : 29-10-2024 11:39 AM Advised/Pres Doctor : --
Department : Radiology Qualification : --
Referred By : Self Registration No. : --
Employee Id : 22S35011

DEPARTMENT OF RADIOLOGY

RIGHT BREAST: It is normal in echopattern. No e/o focal nodular or mass lesions seen. No e/o calcifications. The skin over the breast is normal. Nipple and areola are normal. The subcutaneous, mammary and retro mammary zones are normal.

LEFT BREAST: It is normal in echopattern. No e/o focal nodular or mass lesions seen. No e/o calcifications. The skin over the breast is normal. Nipple and areola are normal. The subcutaneous, mammary and retro mammary zones are normal.

No e/o axillary lymphadenopathy.

IMPRESSION: NORMAL STUDY.

---End Of The Report---



Dr.CHETAN HOLEPPAGOL
MBBS, DNB(RADIO DIAGNOSIS)
90037
Radiology

Patient Name	: Mrs. Chetana Vykuntaiah Y K	Age	: 40Yrs 9Mths 13Days
UHID	: CMYS.0000062465	OP Visit No.	: CMYSOPV130900
Printed On	: 26-10-2024 07:56 AM	Advised/Pres Doctor	: --
Department	: Radiology	Qualification	: --
Referred By	: Self	Registration No.	: --
Employeer Id	: 22S35011		

DEPARTMENT OF RADIOLOGY

Lung fields are clear.

Cardio thoracic ratio is normal.

Apices, costo and cardio phrenic angles are free.

Cardio vascular shadow and hila show no abnormal feature.

Bony thorax shows no significant abnormality.

Domes of diaphragm are well delineated.

IMPRESSION: NORMAL STUDY .

---End Of The Report---



Dr.CHETAN HOLEPPAGOL
MBBS, DNB(RADIO DIAGNOSIS)
90037
Radiology



Patient	Mrs. Chetana Vykuntaiah Y K	Doctor	RASHMI B N	Appt ID	CMYSAPT1192
Age/Gender	40Y Female	Qualification	MBBS, DGO, DNB (GYNAECOLOGY)	Consult Date	27 Oct 2024
UHID	CMYS.0000062465	Reg. No.	33393	Order Bill ID	CMYS-OCR-24560
				Visit Display ID	CMYSOPV130900

VITALS

Weight : 78Kgs	Height : 158Cms
Pulse : 74 BPM	Spo2 : 98%
BP : 120 / 70 MmHg	Respiratory Rate : 22 BPM
Temperature : 98.3 °F	

RASHMI B N
Doctor's Signature

Apollo Health and Lifestyle Limited

(CIN-U85110TG2000PLC115819)

Corporate Office: 7-1-617/A, 7* Floor, Imperial Towers, Ameerpet, Hyderabad-500016, Telangana

Ph No: 040-4904 7777 | www.apollohl.com | Email ID:enquiry@apollohl.com

Patient Name	: Mrs. Chetana Vykuntaiah Y K	Age	: 40Yrs 9Mths 13Days
UHID	: CMYS.0000062465	OP Visit No.	: CMYSOPV130900
Printed On	: 26-10-2024 07:55 AM	Advised/Pres Doctor	: --
Department	: Cardiology	Qualification	: --
Reffered By	: Self	Registration No.	: --
Employeer Id	: 22S35011		

DEPARTMENT OF CARDIOLOGY

Observation :-

1. Sinus Rhythm.
2. Heart rate is 72 beats per minutes.

Impression:

NORMAL RESTING ECG.

---End Of The Report---



Dr. GURU PRASAD B V
MBBS, PGDCC
69949
Cardiology



Patient	Mrs. Chetana Vykuntaiah Y K	Doctor	PRAVEEN R	Appt ID	CMYSAPT1193
Age/Gender	40Y Female	Qualification	MBBS, MS (ENT)	Consult Date	27 Oct 2024
UHID	CMYS.0000062465	Reg. No.	66012	Order Bill ID	CMYS-OCR-24560
				Visit Display ID	CMYSOPV130900

VITALS

Weight : 78Kgs	Height : 158Cms
Pulse : 74 BPM	Spo2 : 98%
BP : 110 / 80 MmHg	Respiratory Rate : 22 BPM
Temperature : 98.3 °F	

PRAVEEN R
Doctor's Signature

Apollo Health and Lifestyle Limited

(CIN-U85110TG2000PLC115819)

Corporate Office: 7-1-617/A, 7* Floor, Imperial Towers, Ameerpet, Hyderabad-500016, Telangana

Ph No: 040-4904 7777 | www.apollohl.com | Email ID:enquiry@apollohl.com

8, 9, 12, eye

H → 157
W → 62.6
BP → 120/80

Name : Mrs. Chetana Vykuntiah Y K

Age : 40Y 9M 12D

UHID : CMYS.0000062465

Address : Mysore Mysore Karnataka INDIA 570001

sex : Female



Plan : ARCOFEMI MEDIWHEEL FEMALE AHC
CREDIT PAN INDIA OP AGREEMENT

OP No: CMYSOPVL30900

BIB No: CMYS-OCR-24560

Date: Oct 26th, 2024, 10:10 AM

Sno.	Service Type/Service Name	Department	
1	ARCOFEMI MEDIWHEEL - FULL BODY ANNUAL PLUS CHECK ADVANCED - FEMALE - 2D ECHO - PAN INDIA - FY2324		
1	ULTRASOUND - WHOLE ABDOMEN	Ultrasound Radiology	<input type="checkbox"/>
2	FITNESS BY GENERAL PHYSICIAN	Consultation	<input type="checkbox"/>
3	HSAIc, GLYCATED HEMOGLOBIN	Biochemistry	<input type="checkbox"/>
4	LBC PAP TEST PAPSURE	Histopathology	<input type="checkbox"/>
5	COMPLETE URINE EXAMINATION	Clinical Pathology	<input type="checkbox"/>
6	SONO MAMMOGRAPHY - SCREENING	Mammography	<input type="checkbox"/>
7	BLOOD GROUP ABO AND RH FACTOR	Blood Bank	<input type="checkbox"/>
8	LIVER FUNCTION TEST (LFT)	Biochemistry	<input type="checkbox"/>
9	GLUCOSE, POST PRANDIAL (PP), 2 HOURS (POST MEAL)	Biochemistry	<input type="checkbox"/>
10	GLUCOSE, FASTING	Biochemistry	<input type="checkbox"/>
11	OPHTHAL BY GENERAL PHYSICIAN	Consultation	<input type="checkbox"/>
12	DIET CONSULTATION	General	<input type="checkbox"/>
13	DENTAL CONSULTATION	Consultation	<input type="checkbox"/>
14	BODY MASS INDEX (BMI)	General	<input type="checkbox"/>
15	X-RAY CHEST PA	X Ray Radiology	<input type="checkbox"/>
16	HEMOGRAM - PERIPHERAL SMEAR	Haematology	<input type="checkbox"/>
17	PERIPHERAL SMEAR	Haematology	<input type="checkbox"/>
18	LIPID PROFILE	Biochemistry	<input type="checkbox"/>
19	2D ECHO	Cardiology	<input type="checkbox"/>
20	GYNAECOLOGY CONSULTATION	Consultation	<input type="checkbox"/>
21	ECG	Cardiology	<input type="checkbox"/>
22	THYROID PROFILE (TOTAL T3, TOTAL T4, TSH)	Biochemistry	<input type="checkbox"/>
23	ENT CONSULTATION	Consultation	<input type="checkbox"/>
24	URINE GLUCOSE(POST PRANDIAL)	Clinical Pathology	<input type="checkbox"/>
25	URINE GLUCOSE(FASTING)	Clinical Pathology	<input type="checkbox"/>
26	GAMMA GLUTAMYL TRANSFERASE (GGT)	Biochemistry	<input type="checkbox"/>
27	RENAL PROFILE/RENAL FUNCTION TEST (RFT/KFT)	Biochemistry	<input type="checkbox"/>

CERTIFICATE OF MEDICAL FITNESS

This is to certify that I have conducted the clinical examination

of Mrs. Kethana Dykuntinas ^{Y.K.} on 26/10/24

After reviewing the medical history and on clinical examination it has been found that he/she is

	Tick
<ul style="list-style-type: none"> • Medically Fit 	✓
<ul style="list-style-type: none"> • Fit with restrictions/recommendations <p>Though following restrictions have been revealed, in my opinion, these are not impediments to the job.</p> <p>1.....</p> <p>2.....</p> <p>3.....</p> <p>However the employee should follow the advice/medication that has been communicated to him/her.</p> <p>Review after _____</p>	
<ul style="list-style-type: none"> • Currently Unfit. Review after _____ recommended 	
<ul style="list-style-type: none"> • Unfit 	

Dr. 
Medical Officer
Apollo Clinic
 # 23, 1st Floor,
 Kalidasa Road, Mysore - 02
 Ph: 0821-4006040/41

This certificate is not meant for medico-legal purposes.

(Phy)

Mrs. Chetana Vykurtaiah Y K
40 year Female.

Dr. Umesh

Height : 154	Weight : 62.2	BMI :	Waist Circum :
Temp :	Pulse : 70/4	Resp : 20/dt	B.P : 120/80

General Examination /
Allergies History

Clinical Diagnosis & Management Plan

CUG
R
B7 / 10/13

90 Varicose vein
Ad

T- ALT- D₃ 60K Once
or Weekly (10)

Regular Exercise

Venous Doppler
both lower limbs

Follow up date :


Doctor Signature

Apollo Clinic
23, 1st Floor,
Kalldasa Road, Mysore - 02
Ph : 0821-4006040/41

Gyn Consultation

Date : 10/26/2024 Department : Obstetrics & Gynaecology
 Patient Name : Mrs. Chetana Vykuntaiah Y K Doctor : Dr. RASHMI B N
 UHID : CMYS.0000062465 Registration No. : 33393, 26110124
 Age / Gender : 40 Yrs 9 Mths 12 Days / Female Qualification : MBBS, DGO, DNB (GYNAECOLOGY)
 Consultation Timing : 2:32 PM

Height : 154	Weight : 62.6	BMI :	Waist Circum :
Temp :	Pulse :	Resp :	B.P : 120/80

General Examination / Allergies History

Clinical Diagnosis & Management Plan

PH → NS.

PH - DM +
hypertension +.

scan →

mammogram →

} renal study

adv : laparoscopic sterilization ↓ A.

MI → 18 yrs.

P1 L2
I - twins -
CS - PH
76 yrs.

PH - regular yda
VMP → 20 days
20 wk.

Follow up date :

Doctor Signature

Dr. Rashmi B N

Apollo Clinic
23, 1st Floor,
Kalidasa Road, Mysore - 02
Ph : 0821-4006040/41

Date : 10/26/2024 Department : Nutrition & Dietetics
 Patient Name : Mrs. Chetana Vykuntaiah Y K Doctor : Miss.MADHURA B P
 UHID : CMYS.0000062465 Registration No. : A104102
 Age / Gender : 40Yrs 9Mths 12Days / Female Qualification : M.Sc. Nutrition and Dietetics
 Consultation Timing : 2:33 PM Ph.D⁺

Height : 154	Weight : 62.6	BMI : 26 kg/m ²	Waist Circum : 78cm - 52kg
Temp :	Pulse :	Resp :	B.P : 120/80

General Examination / Allergies History

Clinical Diagnosis & Management Plan

ESK - 22
 Thyroxine - 12.72

- Advised low calorie, high protein diet with fiber rich foods.
- Take small frequent meals. Do not skip meals.
- Include all variety of seasonal fruits, vegetables & green leafy vegetables.
- Include nuts like Almonds & walnuts regularly.
- Include dry-fruits like dried dates & raisins
- Seed cycling - 1 Teaspoon each, dry roasted.
 - 1st day of periods - 13th day - Flaxseeds & Pumpkin seeds.
 - 2nd 14th day - 20th day - Sesame seeds & sunflower seeds.
- Avoid maida, sugar, too much of salt, sodas, soda & cream.
- Drink 12-14 big glasses of water / day.

Follow up date :

Doctor Signature

Apollo Clinic
 # 23, 1st Floor,
 Kalidasa Road, Mysore - 02
 Ph : 0821-4006040/41

26/10/2024

Date : 10/26/2024 Department : ENT
 Patient Name : Mrs. Chetana Vykuntaiah Y K Doctor : Dr. PRAVEEN KUMAR R
 UHID : CMYS.0000062465 Registration No. : 66012
 Age / Gender : 40Yrs 9Mths 12Days / Female Qualification : MBBS, MS (ENT)
 Consultation Timing : 2:33 PM

Height : 1.54	Weight : 62.6	BMI :	Waist Circum :
Temp :	Pulse :	Resp :	B.P : 120/80

General Examination /
Allergies History

Clinical Diagnosis & Management Plan

Come for regular health checkup

Findings for (E)

Eor -

(R) Eor - war - normal
 Bilateral TM - (N)

nose - nasal mucus - (N)

OR SM (C)

oral cavity & oropharynx - (N)
 neck (N)

As

GRA'S

Follow up date :

Doctor Signature

Apollo Clinic
 # 23, 1st Floor,
 Kalidasa Road, Mysore - 02
 Ph : 0821-4006040/41

[Opthal]

Date : 10/26/2024 Department : Dental
 Patient Name : Mrs. Chetana Vykuntaiah Y K Doctor : Dr. JYOTHISHREE PV
 UHID : CMYS.0000062465 Registration No. : 33268A
 Age / Gender : 40Yrs 9Mths 12Days / Female Qualification : B.D.S[Bachelor of Dental Surgery]
 Consultation Timing : 2:32 PM

Height : 154	Weight : 62.6	BMI :	Waist Circum :
Temp :	Pulse :	Resp :	B.P : 120/80

General Examination /
Allergies History

Clinical Diagnosis & Management Plan

Distance vision

Vn $\left\{ \begin{array}{l} 6/6 \\ 6/6 \end{array} \right.$

near vision

NG

Colour vision

(CV) = normal

(BE) = normal vision

Follow up date : 26/10/20

Aceba
 Doctor Signature
Apollo Clinic
 # 23, 1st Floor,
 Kalidasa Road, Mysore - 02
 Ph : 0821-4006040/41

(Dental)

Date : 10/26/2024 Department : Dental
Patient Name : Mrs. Chetana Vykuntaiah Y K Doctor : ~~D. JYOTHISHREE TV~~
UHID : CMYS.0000062465 Registration No. : 33268A
Age / Gender : 40Yrs 9Mths 12Days / Female Qualification : B.D.S [Bachelor of Dental Surgery]
Consulation Timing : 2:32 PM

Height : 154	Weight : 62.6	BMI :	Waist Circum :
Temp :	Pulse :	Resp :	B.P : 90/80

General Examination /
Allergies History

Clinical Diagnosis & Management Plan

O/E

upper arch proclined,
20/13 spacing noted

Deep bite noted

Gen Teeth addition noted

Adv - ortho intervention

Follow up date :

Doctor Signature

Jyothishree TV

Apollo Clinic
23, 1st Floor,
Kaldasa Road, Mysore - 02
PH : 0821-4006040/41

Patient Name	: Mrs. Chetana Vykuntaiah Y K	Age	: 40Yrs 9Mths 12Days
UHID	: CMYS.0000062465	OP Visit No.	: CMYSOPV130900
Printed On	: 26-10-2024 01:26 PM	Advised/Pres Doctor	: --
Department	: Radiology	Qualification	: --
Referred By	: Self	Registration No.	: --
Employer Id	: 22S35011		

DEPARTMENT OF RADIOLOGY

Lung fields are clear.

Cardio thoracic ratio is normal.

Apices, costo and cardio phrenic angles are free.

Cardio vascular shadow and hila show no abnormal feature.

Bony thorax shows no significant abnormality.

Domes of diaphragm are well delineated.

IMPRESSION: NORMAL STUDY.

---End Of The Report---



Dr.CHETAN HOLEPPAGOL
MBBS, DNB(RADIO DIAGNOSIS)
90037
Radiology

Patient Name: Mrs. Chetana Vykuntaiah Y K	Date : 26.10.2024	Referring Doctor: Dr. Self
Age / Sex: 40Yrs/Female	UHID No : 62465	Location : OP
ULTRASONOGRAPHY- ABDOMEN & PELVIS		

LIVER: It is normal in size and echotexture. No focal lesions seen. IHBR are not dilated. CBD and Portal vein are normal.

GALL BLADDER: It is well distended and normal. No calculi seen.

SPLEEN: It is normal in size, outline and echopattern. No e/o focal lesions.

PANCREAS: It is normal.

RIGHT KIDNEY: It measures 9.5 cm with parenchymal thickness of 1.2cm. It is normal in size, outline and echotexture. No e/o calculus or hydronephrosis seen.

LEFT KIDNEY: It measures 9.7cm with parenchymal thickness of 1.2cm. It is normal in size, outline and echotexture. No e/o calculus or hydronephrosis seen.

URINARY BLADDER: It is well distended. The UB wall is normal. No calculi seen.

UTERUS: It is anteverted and measures 7.8x4.1x 6.2cm with ET=7.7 mm. It is normal in size, outline and echotexture. No mass lesion.

Minimally POD collection .

Rt. OVARY: It measures 2.9x1.8cm. It is normal. No mass lesion seen.

Lt. OVARY: It measures 2.6x 2.2cm. It is normal. No mass lesion seen.

OTHERS: No e/o free fluid in the abdomen. No e/o lymphadenopathy. No c/o gut wall thickening. No mass lesion seen in the abdomen.

IMPRESSION: NORMAL STUDY.

Just
Dr. Karthik H V MDRD , DNB
Consultant Radiologist.

Apollo Health and Lifestyle Limited

(CIN: U65110FC2000PLC15819)


Head Office: 1-10-60 G, Ashoka Raghupathi Chambers, 5th Floor, Begumpet, Hyderabad, Telangana - 500 016
Ph No: (040) 4004 7777, Fax No: 4004 7744 | Email ID: enquiry@apolloh.com | www.apolloh.com

APOLLO CLINICS NETWORK KARNATAKA

Bangalore (Heavenly Road) | Belandur | Electronic City | Frazer Town | HSR Layout | Indira Nagar | JP Nagar | Kundalahalli
Koramangala | Varjapur Road | Mysore (VV Mahalle)

Online appointments: www.apolloclinic.com

TO BOOK AN APPOINTMENT

 **1860 500 7788**

Patient Name: Mrs.Chetan Vykuntaiah V K	Date :26.10.2024	Referring Doctor: Dr .Self
Age / Sex: 40Yrs/Female	UHID No: 62465	Location : OP
ULTRASONOGRAPHY- BREAST		

RIGHT BREAST: It is normal in echopattern. No e/o focal nodular or mass lesions seen. No e/o calcifications. The skin over the breast is normal. Nipple and areola are normal. The subcutaneous, mammary and retro mammary zones are normal.

LEFT BREAST: It is normal in echopattern. No e/o focal nodular or mass lesions seen. No e/o calcifications. The skin over the breast is normal. Nipple and areola are normal. The subcutaneous, mammary and retro mammary zones are normal.

No e/o axillary lymphadenopathy.

IMPRESSION: NORMAL STUDY.



Dr. Karthik H V MDRD , DNB
Consultant Radiologist.

Apollo Health and Lifestyle Limited

CIN: LMS110TG2000PLC1158191
Regd Office: 1-10-60-62, Ashoka Raghupathi Chambers, 5th Floor, Begumpet, Hyderabad, Telangana - 500 016
Ph: No. 080 4504 7777 | Fax No. 4904 7744 | Email: ID: enquiry@apolloh.com | www.apolloh.com

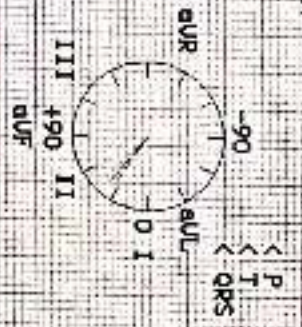
APOLLO CLINICS NETWORK KARNATAKA
Bangalore (Basavahogudi) | Bellandur | Electronic City | Fraser Town | HSR Layout | Indira Nagar | JP Nagar | Kundalahalli |
Koramangala | Sarjapur Road | Mysore (VV Mohalla)

Online appointments: www.apolloclinic.com

TO BOOK AN APPOINTMENT

 **1860 500 7788**

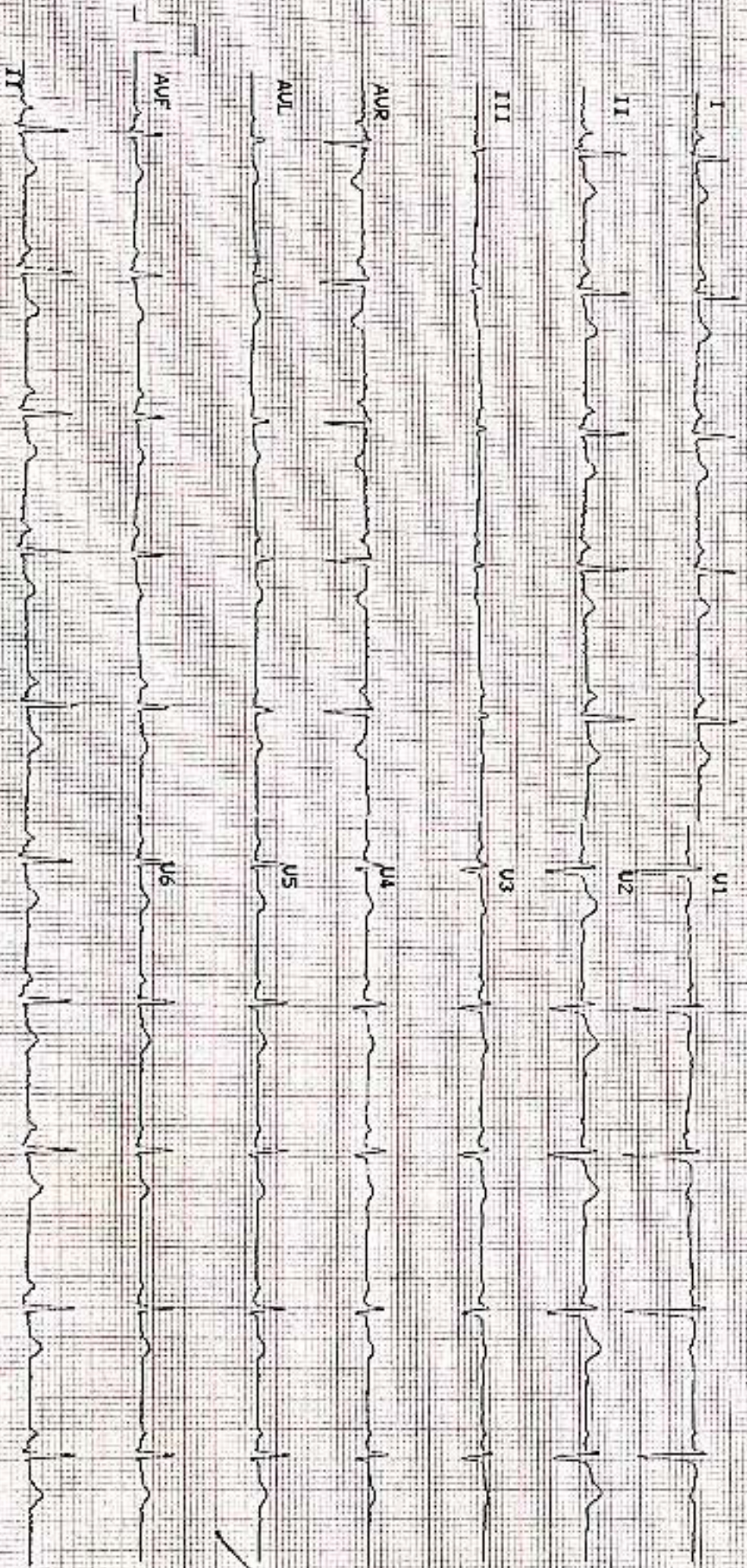
AGE: _____ NO: _____
Measurement Results:
QRS : 100 ms
QT/QTcB : 398 / 402 ms
PR : 146 ms
P : 116 ms
RR/PP : 980 / 950 ms
P/QRS/T : 45 / 40 / 35 degrees
QTd/QTcBd : 30 / 30 ms
Sokolow : 1.6 mV
AK : 8



Interpretation:

Apollo Clinic
23, 1st Floor,
Kallidasa Road, Mysore - 02
Ph : 0821-4006040/41

Unconfirmed report



Patient's Name : Mrs. Chetana Vykuntalah Y K	Age & sex : 40Yrs /Female
Date :26 .10.2024	UHID No :62465

2D ECHOCARDIOGRAPHY STUDY

Impression:

- Normal chamber volumes
- Normal left ventricular function. EF 60%
- No regional wall motion abnormality
- Normal valves
- No clots. No pericardial effusion

Findings

Left Ventricle:	Normal
Right Ventricle	Normal
Left Atrium	Normal
Right Atrium	Normal
Aorta	Normal
Pulmonary Artery	Normal
IAS	Intact
IVS	Intact
Valves	Normal
Pericardium	Normal
Doppler	Normal

Dr. **Dr. C.B. KESHAVAMURTHY MD, DM, DNB**
CONSULTANT CARDIOLOGIST

Apollo Health and Lifestyle Limited

(CIN: UR5110TG2000P12115819)
Regd Office: 1, 10-142, 62, Ashoka Road, 5th Floor, Begumpet, Hyderabad, Telangana - 500 016
Ph. No: 040 4004 7777 Fax No: 4904 7744 | Email: enquiry@apolloh.com | www.apolloh.com

APOLLO CLINICS NETWORK KARNATAKA
Bangalore | Basavanagudi | Hebbal | Electronic City | Frazer Town | HSR Layout | Indira Nagar | JP Nagar | Kundalahalli |
Koramangala | Sarjapur Road | Mysore (VV Mahalle)

Online appointments: www.apolloclinic.com

TO BOOK AN APPOINTMENT

 **1860 500 7788**

Patient's Name : Mrs. Chetana Vykuntaiah Y K	Age & sex : 40Yrs /Female
Date :26 .10.2024	UHID No :62465

Measurements

AO : 2.29 cm
LA : 2.84 cm

RV : 1.60 cm
LVIDd : 3.59 cm
LVIDs : 2.44 cm
IVSd : 1.08 cm
IVSs : 1.30 cm
PWd : 1.08 cm
PWs : 1.35 cm
EF : 60.0 %
FS : 32.0 %

Doppler

MV	TV	AV	PV
E: 0.73 m/s	E 0.69 m/s	V max 1.30 m/s	V max 0.62 m/s
A: 0.46 m/s	A 0.56 m/s		
MR Nil	TR Nil	AR Nil	PR Nil


Dr. C.B. KESHAVAMURTHY MD, DM, DNB
CONSULTANT CARDIOLOGIST

Apollo Health and Lifestyle Limited

CIN: U85110TG2000PLC1158199
Regd Office: 1 TO 60/62, Ashoka Raghupathi Chambers, 5th Floor, Begumpet, Hyderabad, Telangana - 500 016
Ph. No (040) 4904 7777, Fax No 4904 7744 | Email ID enquiry@apollohcl.com | www.apollohcl.com

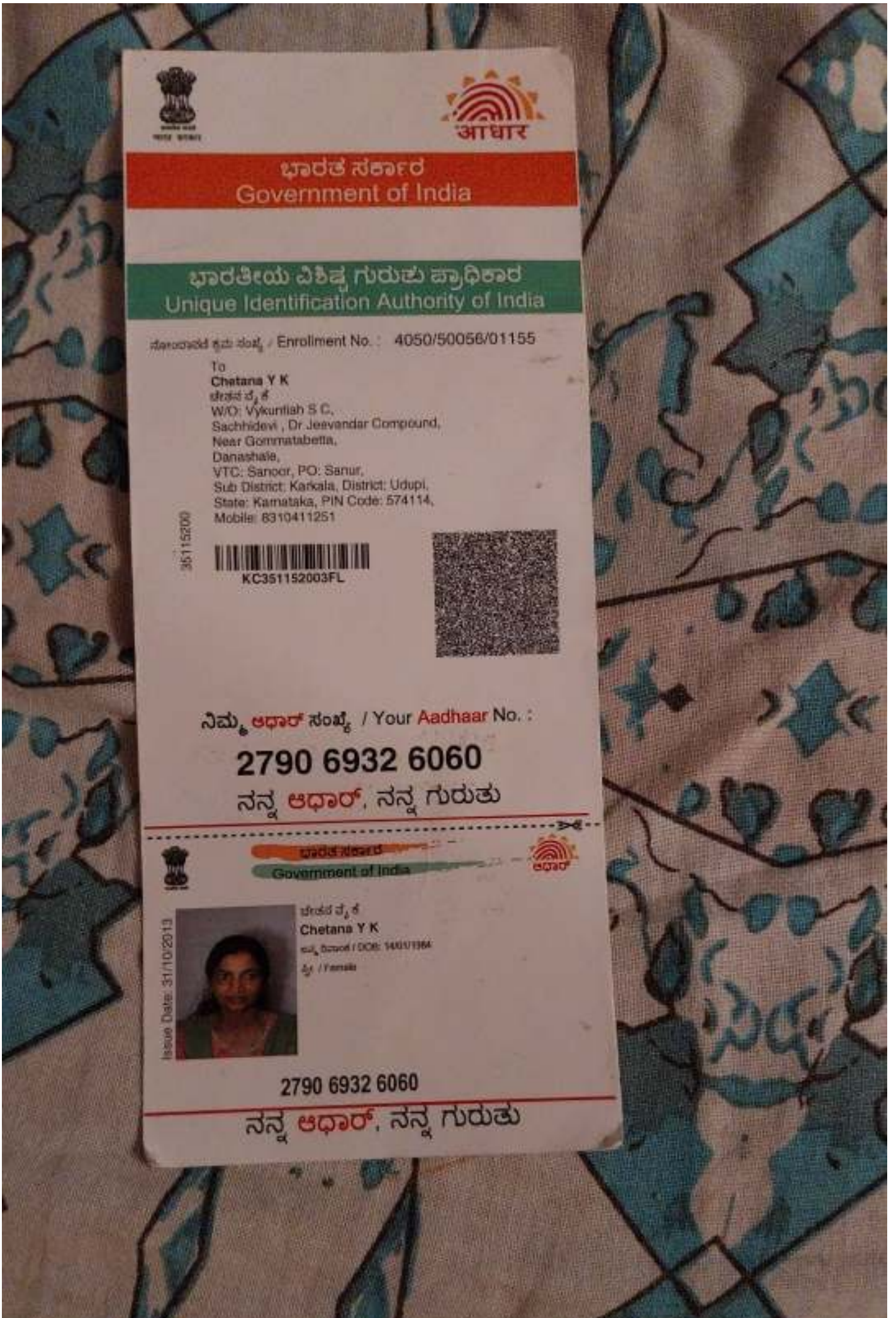APOLLO CLINICS NETWORK KARNATAKA

Bangalore: Basavanagudi | Bellandur | Electronic City | Frasier Town | HSR Layout | Indira Nagar | JP Nagar | Kundalahalli |
Koramangala | Sarjapur Road | Mysore: VV Mahalla

Online appointments: www.apolloclinic.com

TO BOOK AN APPOINTMENT

 **1860 500 7788**



ಭಾರತ ಸರ್ಕಾರ
Government of India

ಭಾರತೀಯ ವಿಶಿಷ್ಟ ಗುರುತು ಪ್ರಾಧಿಕಾರ
Unique Identification Authority of India

ನೋಂದಾಯಿತ ಕ್ರಮ ಸಂಖ್ಯೆ / Enrollment No. : 4050/50056/01155

To
Chatana Y K
 ಚಿತ್ರಾತಮೆ ಕೆ
 W/O: Vykunlish S C,
 Sachhidevi , Dr Jeevandar Compound,
 Near Gommatabetta,
 Danashale,
 VTC: Sanoor, PO: Sanur,
 Sub District: Karkala, District: Udupi,
 State: Karnataka, PIN Code: 574114,
 Mobile: 8310411251

35115200



ನಿಮ್ಮ ಆಧಾರ್ ಸಂಖ್ಯೆ / Your Aadhaar No. :

2790 6932 6060

ನನ್ನ ಆಧಾರ್, ನನ್ನ ಗುರುತು



ಭಾರತ ಸರ್ಕಾರ
Government of India

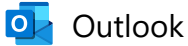


Issue Date: 31/10/2013

ಚಿತ್ರಾತಮೆ ಕೆ
Chetana Y K
 ಜನ್ಮ ದಿನಾಂಕ / DOB: 14/03/1984
 ಪ್ರ / Female

2790 6932 6060

ನನ್ನ ಆಧಾರ್, ನನ್ನ ಗುರುತು



Your appointment is confirmed

From noreply@apolloclinics.info <noreply@apolloclinics.info>
Date Fri 25-10-2024 16:00
To vykuntaiah2010@gmail.com <vykuntaiah2010@gmail.com>
Cc Mysore Apolloclinic <mysore@apolloclinic.com>; Yogeesh KV <mkt.mysore@apolloclinic.com>; Syamsunder M <syamsunder.m@apollohl.com>



Dear Chetna Vykuntaiah,

Greetings from Apollo Clinics,

Your corporate health check appointment is confirmed at KALIDASA RAOD clinic on 2024-10-26 at 08:15-08:30.

Table with 2 columns: Field Name, Value. Fields include Payment Mode, Corporate Name (ARCOFEMI HEALTHCARE LIMITED), Agreement Name ([ARCOFEMI MEDIWHEEL FEMALE AHC CREDIT PAN INDIA OP AGREEMENT]), and Package Name ([ARCOFEMI - MEDIWHEEL - FULL BODY ANNUAL PLUS CHECK ADVANCED - FEMALE - 2D ECHO - PAN INDIA - FY2324]).

"Kindly carry with you relevant documents such as HR issued authorization letter and or appointment confirmation mail and or valid government ID proof and or company ID card and or voucher as per our agreement with your company or sponsor."

Note: Video recording or taking photos inside the clinic premises or during camps is not allowed and would attract legal consequences.

Note: Also once appointment is booked, based on availability of doctors at clinics tests will happen, any pending test will happen based on doctor availability and clinics will be updating the same to customers.

Instructions to be followed for a health check:

- 1. Please ensure you are on complete fasting for 10-To-12-Hours prior to check.
2. During fasting time do not take any kind of alcohol, cigarettes, tobacco or any other liquids (except Water) in the morning. If any medications taken, pls inform our staff before health check.

3. Please bring all your medical prescriptions and previous health medical records with you.
4. Kindly inform our staff, if you have a history of diabetes and cardiac problems.

For Women:

1. Pregnant women or those suspecting are advised not to undergo any X-Ray test.
2. It is advisable not to undergo any health check during menstrual cycle.

For further assistance, please call us on our Help Line #: 1860 500 7788.

Clinic Address: 23, KALIDASA ROAD, VV MOHLLA, MYSORE.

Contact No: (0821) 400 6040 - 41.

P.S: Health Check-Up may take 4 - 5hrs for completion on week days & 5 - 6hrs on Saturdays, kindly plan accordingly, Doctor Consultation will be completed after all the Reports are ready.

Warm Regards,
Apollo Clinic