 **GPS Map Camera**



Sion Koliwada, Maharashtra, India
16/1, Rd Number 29, Namdev Koli Marg, Sion, Mumbai, Sion Koliwada,
Maharashtra 400022, India
Lat 19.040488°
Long 72.864637°
02/05/24 09:38 AM GMT +05:30



GPS Map Camera



Mumbai, Maharashtra, India

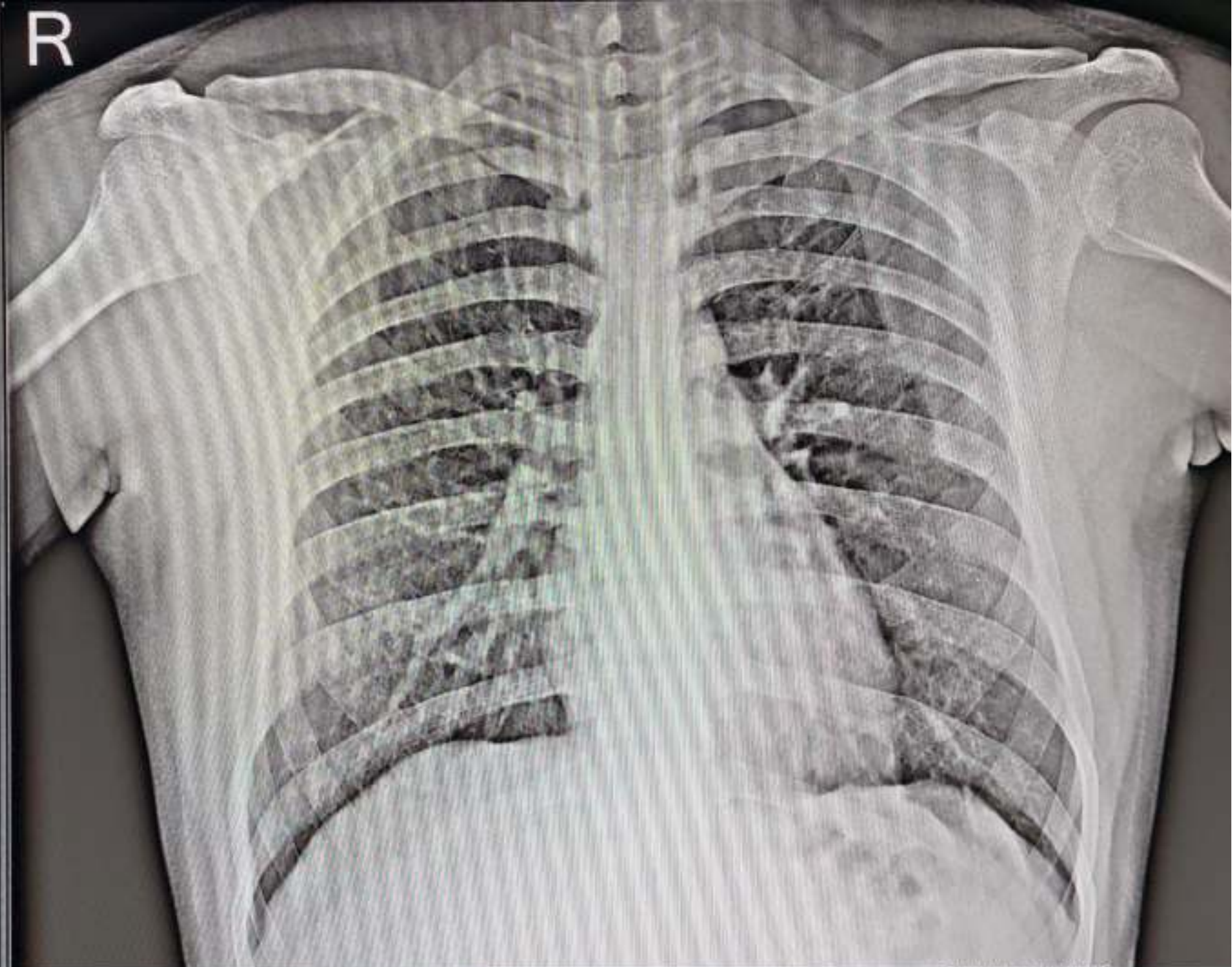
Shop no 3 Saiprasad building Opp Croma showroom, near Cinemax theater, Sion East, Sion, Mumbai, Sion Koliwada, Maharashtra 400022, India

Lat 19.03965°

Long 72.864438°

02/05/24 09:39 AM GMT +05:30

R



MR NIKHIL S BHOSALE 02052401 22 YRS CHEST PA 5/2/2024
ATHARVA HOSPITAL AND RESEARCH CENTRE, SION

Activate Windows
Go to Settings to activate Windows.

MER- MEDICAL EXAMINATION REPORT

Date of Examination 02/05/24			
NAME Nikhil S. Bhosale			
AGE	22 yrs.	Gender	male
HEIGHT(cm)	165 cm	WEIGHT (kg)	67
B.P.	120/80		
ECG	WNL		
X Ray	WNL		
Vision Checkup	Color Vision : (N)		
	Far Vision Ratio : (N) 6/6		
	Near Vision Ratio : (N) 6/6		
Present Ailments	NO		
Details of Past ailments (If Any)	Yes- Radicular cyst in maxilla on 20/9/23		
Comments / Advice : She / He is Physically Fit	Yes.		

Signature with Stamp of Medical Examiner

DR. ATUL P. CHIRMADE
M.B.B.S., M.S.
Consultant Laproscopic & Oncosurgeon
Reg No 80962

ATHARVA DIAGNOSTIC CENTRE
Gr. Floor, Shop No. 5, Saiprasad Bldg.,
F-Wing, Sion Kamgar CHS, Sion,
Mumbai - 400 022.

CERTIFICATE OF MEDICAL FITNESS

This is to certify that I have conducted the clinical examination

of Nikhil S. Bhosale on 02/05/24

After reviewing the medical history and on clinical examination it has been found that he/she is

	Tick
<ul style="list-style-type: none">• Medically Fit	<input checked="" type="checkbox"/>
<ul style="list-style-type: none">• Fit with restrictions/recommendations <p>Though following restrictions have been revealed, in my opinion, these are not impediments to the job.</p> <p>1.</p> <p>2.</p> <p>3.</p> <p>However the employee should follow the advice/medication that has been communicated to him/her.</p> <p>Review after</p>	
<ul style="list-style-type: none">• Currently Unfit. <p>Review after recommended</p>	
<ul style="list-style-type: none">• Unfit	

Dr. _____
Medical Officer
The Apollo Clinic, (Location)

This certificate is not meant for medico-legal purposes

DR. ATUL P. CHIRMADE
M.B.S., M.S.
Consultant Laproscopic & Oncosurgeon
Reg No 88992

ATHARVA DIAGNOSTIC CENTRE
Gr. Floor, Shop No. 5, Saiprasad Bldg.,
F-Wing, Slon Kamgar CHS, Slon,
Mumbai - 400 022.



ATHARVA DIAGNOSTIC CENTRE

FULLY AUTOMATED COMPUTERISED PATHOLOGY

X-RAY, SONOGRAPHY, E.C.G. & 2D ECHO

Shop No. 6, Ground Floor, Sai Prasad Building, Sion Kamgar CHS, Ltd., Opp. Croma Showroom,
Sion (E), Mumbai - 400 022. • Email : atharvahospital@ymail.com
Ph.: 022-2401 6640 / 913609 6640 • Mob.: 98922 44833 / 98678 39996

Reg. No. : 1229	Date : 02/05/2024
Patient's Name : MR NIKHIL S BHOSALE	Age : 22 Yrs. Mnts.
Ref. by : Dr. ATUL P CHIRMADE	Sex : Male
Lab No. :	

EXAMINATION OF BLOOD

HAEMOGRAM DONE ON PE6000 FULLY AUTO HEMATOLOGY ANALYZER

			Reference Values (Adults)
Haemoglobin	13.9	M 14.0 - 17.5 [g/dl]
Erythrocytes	4.50	M 4.5 - 5.9 [$\times 10^6$ /u l]
Haematocrit	42.3	M 41.5 - 50.5 [%]
Mean Corpuscular Volume		87.3	82.0 - 92.0 [fl]
Mean Corpuscular Haemoglobin		30.8	27.0 - 31.0 [pg]
Mean Corps Hb. Concentration		32.8	30 - 36 [g/dl]
Leucocytes	7,600	4,500 to 9,600 [/u l]

DIFFERENTIAL COUNT

	%	Reference Values %	
Segmented Neutrophils	60	40 to 75	Microcytes :
Bandforms	00		Macrocytes :
Lymphocytes	35	20 to 40	Hypochromia :
Monocytes	02	02 to 08	Anisocytosis :
Eosinophils	03	00 to 05	Poikilocytosis :
Basophils	00	01 to 20	Polychromasia :
			Target cells :
			Tear drops :
			Inclusions :
			Toxic granules :

Platelet Count ... 3,02,000 1,40,000 - 4,40,000 [/u l] Atypical Lymphocytes :

Nucleated RBC ...
WC Morphology ...

E.S.R. (Westergren's Method) 4 mm at the end of 1st Hour. Normal Range
M 0-15 mm
F 0-20 mm

Comments:

PATHOLOGIST
Dr. Darshan Gohil MD Path-2008/09/3489

CHECKED



ATHARVA DIAGNOSTIC CENTRE

FULLY AUTOMATED COMPUTERISED PATHOLOGY

X-RAY, SONOGRAPHY, E.C.G. & 2D ECHO

Shop No. 6, Ground Floor, Sai Prasad Building, Sion Kamgar CHS. Ltd., Opp. Croma Showroom,
Sion (E), Mumbai - 400 022. • Email : atharvahospital@ymail.com
Ph.: 022-2401 6640 / 913609 6640 • Mob.: 98922 44833 / 98678 39996

Reg. No. : 1229	Date : 02/05/2024
Patient's Name : MR NIKHIL S BHOSALE	Age : 22 Yrs. Mnts.
Ref. by : Dr. ATUL P CHIRMADE	Sex : Male
Lab No. :	

FASTING BLOOD SUGAR

Observed Value: 78 mg/dl.
(Normal Range : 60 to 110 mg/dl.)

Urine Examination

Urine Sugar : Absent
Urine Ketone : Absent

BLOOD SUGAR 2.0 HOURS AFTER LUNCH

Observed Value : 100 mg/dl.
(Normal Range : Up to 140 mg/dl.)

Urine Examination

Urine Sugar : Absent
Urine Ketone : Absent

NOTE: Kindly interpret the result in light of history of diet & medication

Comments:

PATHOLOGIST 
Dr. Darshan Gohil MD Path-2008/09/3489

CHECKED



ATHARVA DIAGNOSTIC CENTRE

FULLY AUTOMATED COMPUTERISED PATHOLOGY

X-RAY, SONOGRAPHY, E.C.G. & 2D ECHO


Shop No. 6, Ground Floor, Sai Prasad Building, Sion Kamgar CHS. Ltd., Opp. Croma Showroom,
Sion (E), Mumbai - 400 022. • Email : atharvahospital@ymail.com
Ph.: 022-2401 6640 / 913609 6640 • Mob.: 98922 44833 / 98678 39996

Reg. No. : 1229
Patient's Name : MR NIKHIL S BHOSALE
Ref. by : Dr. ATUL P CHIRMADE
Lab No. :

Date : 02/05/2024
Age : 22 Yrs.
Sex : Male

EXAMINATION OF BLOOD

INVESTIGATIONS	OBSERVED VALUE	NORMAL VALUE
Creatinine	0.86	0.5 - 1.4 mg/dl.
S.G.P.T.	24.90	0 - 40 IU/L
Total Bilirubin	0.44	0 - 1.0 mg/dl.
Direct Bilirubin	0.19	0 - 0.35 mg/dl.
Indirect Bilirubin	0.25	



Comments:

HAEMOGRAM DONE ON STAR21 PLUS

Pathologist

Dr. Darshan G. M.D. Path - 2008/09/3489

CHECKEDSH



ATHARVA DIAGNOSTIC CENTRE

FULLY AUTOMATED COMPUTERISED PATHOLOGY

X-RAY, SONOGRAPHY, E.C.G. & 2D ECHO

Shop No. 6, Ground Floor, Sai Prasad Building, Sion Kamgar CHS. Ltd., Opp. Croma Showroom,
Sion (E), Mumbai - 400 022. • Email : atharvahospital@ymail.com
Ph.: 022-2401 6640 / 913609 6640 • Mob.: 98922 44833 / 98678 39996

Reg. No. : 1229
Patient's Name : MR NIKHIL S BHOSALE
Ref. by : Dr. ATUL P CHIRMADE
Lab No. :

Date : 02/05/2024
Age : 22 Yrs. Mnts.
Sex : Male

EXAMINATION OF BLOOD

BLOOD GROUP : 'O'

Rh(D) FACTOR : POSITIVE

Comments:

PATHOLOGIST

Dr. Darshan Gohil MD Path-2008/09/3489

CHECKED



ATHARVA DIAGNOSTIC CENTRE

FULLY AUTOMATED COMPUTERISED PATHOLOGY

X-RAY, SONOGRAPHY, E.C.G. & 2D ECHO

Shop No. 6, Ground Floor, Sai Prasad Building, Sion Kamgar CHS. Ltd., Opp. Croma Showroom,
Sion (E), Mumbai - 400 022. • Email : atharvahospital@ymail.com
Ph.: 022-2401 6640 / 913609 6640 • Mob.: 98922 44833 / 98678 39996

Reg. No. : 1229	Date : 02/05/2024
Patient's Name : MR NIKHIL S BHOSALE	Age : 22 Yrs. Mnts.
Ref. by : Dr. ATUL P CHIRMADE	
Lab No. :	Sex : Male

EXAMINATION OF URINE

PHYSICAL EXAMINATION

Quantity	: 30 ml.	Deposit	: Absent
Colour	: Pale Yellow	Sp. Gravity	: 1.020
Appearance	: Clear		

CHEMICAL EXAMINATION

Reaction	: Acidic	Occult Blood	: Absent
pH	: 6.0	Bile Pigment	: Absent
Albumin	: Absent	Bile Salts	: Absent
Sugar	: Absent	Urobilinogen	: Normal
Ketone bodies	: Absent		

MICROSCOPIC EXAMINATION [CENTRIFUGE SEDIMENT]

Red Blood Cells	: Absent	Amorphous material	: Absent
Pus Cells	: 1-2/H.P.F.	Spermatozoa	: Absent
Epithelial Cells	: 1-2/H.P.F.	Yeast	: Absent
Casts	: Absent	Trichomonas vaginalis	: Absent
Crystals	: Absent		
Mucus threads	: Absent		
Bacteria	: Absent		

Note: Examination performed on morning sample.

Comments:

PATHOLOGIST
Dr. Darshan Gonde MD Path-2008/09/3489

CHECKED



ATHARVA DIAGNOSTIC CENTRE

FULLY AUTOMATED COMPUTERISED PATHOLOGY

X-RAY, SONOGRAPHY, E.C.G. & 2D ECHO

Shop No. 6, Ground Floor, Sai Prasad Building, Sion Kamgar CHS. Ltd., Opp. Croma Showroom,
Sion (E), Mumbai - 400 022. • Email : atharvahospital@ymail.com
Ph.: 022-2401 6640 / 913609 6640 • Mob.: 98922 44833 / 98678 39996

Patient's Name :- Mr. Nikhil S Bhosale.

Date:- 02nd May 2024

Referred By :- Dr. Atul P. Chirmade.

Age & Sex:- 22 Yrs. / M

Examination :- X-ray Chest P.A. View

X-ray Chest P.A. View :-

Both lung fields are clear

Heart and aorta are clear

Both C.P. angles are clear.

Pleura, diaphragm and ribcage appear normal.

Impression:-

> Normal Radiogram.

DR SANDEEP NYAYANIRGUNE
M.D. DNB DMRE
RADIOLOGIST & SONOLOGIST

Patient's Name: Nikhil S. Bhosale

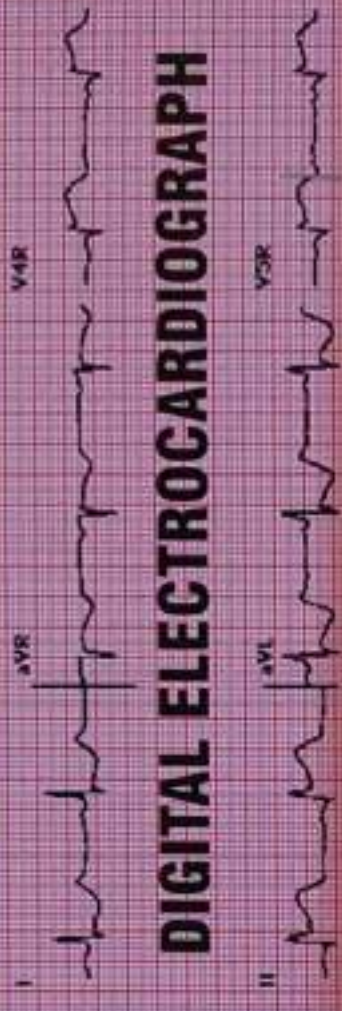
Age: 22 Sex: M/F

Date: 10/05/24 Receipt No.:

Referred by Dr.: Atul P. Chirmode

Conclusion: WNL

Probable Diagnosis:



DIGITAL ELECTROCARDIOGRAPH



ATIARVA DIAGNOSTIC CENTRE

FULLY AUTOMATED COMPUTERISED PATHOLOGY

X-RAY, SONOGRAPHY, E.C.G. & 2D ECHO

Shop No. 6, Ground Floor, Sai Prasad Building,
 Sion Kamgar CHS. Ltd., Opp. Croma Showroom,
 Near PVR Cinemas, Sion (E), Mumbai - 400 022.

Ph.: 022-2401 6640 / 913609 6640
 Mobile : 98922 44833 / 98678 39996

ATIARVA