



Mrs. Bhatari
33yrs/F

O/E Rootstumps 45, stains + +, Calculus + +.

Adv. Extraction 45
• scaling & polishing



(This is only professional opinion and not the diagnosis, Please correlate clinically)

Q Block South City 11, Sohna Road, Main Sector-47, Gurgaon, Haryana

Ph.: 0124-4900000 (100 Lines) Fax : 0124-2218733 E-mail : parkmedicenters@gmail.com

PARK GROUP OF HOSPITALS : West Delhi • South Delhi • Gurgaon • Karnal • Panipat • Hodal • Ambala • Behror

the **health** care providers

the **health** care providers






9/2/23



For medical exam



Nose - Mld DNS (+) + (L)
det MAD

Throat - INAD

[Handwritten signature]



(This is only professional opinion and not the diagnosis, Please correlate clinically)

Q Block South City 11, Sohna Road, Main Sector-47, Gurgaon, Haryana

Ph.: 0124-4900000 (100 Lines) Fax : 0124-2218733 E-mail : parkmedicenters@gmail.com

PARK GROUP OF HOSPITALS : West Delhi • South Delhi • Gurgaon • Karnal • Panipat • Hodal • Ambala • Behror

the **health** care providers

the **health** care providers





©Phthel



Cert. No. MC-4830



Cert. No. H-2016-0369

Mrs - Bhatnari

eye - 33y/F

Dr. Anand Anand

Date - 9/2/23

Health checkup

vn { 6/6 P
 unaided
 6/6 P

MCT { 14
 15

MV { MG
 MG

Colour vision — normal (BE)

FM — Normal



(This is only professional opinion and not the diagnosis, Please correlate clinically)

Q Block South City 11, Sohna Road, Main Sector-47, Gurgaon, Haryana

Ph.: 0124-4900000 (100 Lines) Fax : 0124-2218733 E-mail : parkmedicenters@gmail.com

PARK GROUP OF HOSPITALS : West Delhi • South Delhi • Gurgaon • Karnal • Panipat • Hodal • Ambala • Behror

the **health** care providers

the **health** care providers



NAME	: MRS. BHATERI	DATE	: 9 / 2 / 2023
Age Sex	: 33 Years / Female	Inpatient No	:
PERFORMED BY	: Dr. ELA MADAAN	BILL NO.	: 24038701

TRANS THORACIC ECHO CARDIOGRAPHY REPORT

MITRAL VALVE

Morphology AML: Normal / Thickening / Calcification / Flutter / Vegetation / Non significant Prolapse / SAM
PML: Normal / Thickening / Calcification / Prolapse / Paradoxical Motion / Fixed.
Subvalvular deformity: Present / Absent

Doppler Normal / Abnormal
Mitral Stenosis Present / Absent
Mitral Regurgitation; Absent / Normal / Mild / Trace / Moderate / Severe.

TRICUSPID VALVE

Morphology Normal / Atresia / Thickening / Calcification / Prolapse / Vegetation / Doming.
Doppler Normal / Abnormal
Tricuspid Stenosis: Present / Absent.
Tricuspid Regurgitation: Absent / Mild / Trace / Moderate

PULMONARY VALVE

Morphology Normal / Atresia / Thickening / Calcified / Doming / Vegetation.
Doppler Normal / Abnormal.
Pulmonary stenosis: Present / Absent
Pulmonary regurgitation: Present / Absent

AORTIC VALVE

Morphology Normal / Thickened / Mildly / Calcified / Flutter / Vegetation / Restricted / Opening
No. of Cusps 1 / 2 / 3 / 4
Doppler Normal / Abnormal
Aortic Stenosis : Present / Absent
Aortic regurgitation : Present / Absent / Mild / Trace



Cert. No. H-2016-0369 Cert. No. MC - 4830

(This is only professional opinion and not the diagnosis, please correlate clinically)

Q Block, South City -II, Sohna Road, Sector-47, Gurgaon, Haryana
Ph.: 0124-4900000 (100 Lines), Toll Free No. : 1800-102-6767, Mob.: 62 62 82 82 35, Email: customercare@parkhospital.in

PARK GROUP OF HOSPITALS : West Delhi - Gurugram - Faridabad - Sonapat - Panipat - Karnal - Ambala - Patiala - Behror - Jaipur

the **health** care providers

the **health** care providers





Park Hospital

GROUP SUPER SPECIALITY HOSPITAL

<u>Measurements</u>	<u>Normal Values</u>	<u>Measurements</u>	<u>Normal Value</u>
IVSD : 1.1cm	(0.6-1.1cm))	LA : 2.8cm	(1.9-4.0cm)
LVID : 4.6cm	(3.7-5.6cm)	LVOT : 1.5cm	
LVPW : 0.9cm	(0.6-1.1cm)	AORTA : 2.6cm	(2.0-3.7cm)
EF : 55%	(55% - 80%)	IVSmotion :	Normal / Flat / Paradoxical
Any Other			

CHAMBERS:-

LV Normal / Enlarged / Clear / Thrombus /
 Contraction Normal LV shows concentric LVH, no gradient across LVOT /Inetic / Intra capillary
 Regional wall motion abnormality: Absent/ Present

LA Normal /Enlarged / Clear /Thrombus / Myxoma; LAA: Clear / Thrombus

RA Normal / Clear / Thrombus, Dilated.

RV Normal / Mildly Dilated / Enlarged / Clear / Thrombus / Hypertrophied/
PERICARDIUM Normal / Thickening / Calcification / Effusion.

COMMENTS & SUMMARY:-

- All Cardiac Chamber Dimensions are within normal limits.
- Global LVEF 55%
- No RWMA
- NORMAL LV FUNCTION
- TRACE MR / NO AR
- TRACE TR
- GOOD RV FUNCTION
- IAS/IVS. No Flow seen across IAS/IVS.
- No Thrombus/Mass in any chamber.
- No Pericardial Effusion.



Please correlate clinically

Dr. ELA MADAAN
 MBBS, PGDCC
 Fellowship in non Invasive
 Cardiology



Cert. No. H-2016-0369 Cert. No. MC - 4830

(This is only professional opinion and not the diagnosis, please correlate clinically)

Q Block, South City -II, Sohna Road, Sector-47, Gurgaon, Haryana
 Ph.: 0124-4900000 (100 Lines), Toll Free No. : 1800-102-6767, Mob.: 62 62 82 82 35, Email: customercare@parkhospital.in

PARK GROUP OF HOSPITALS : West Delhi - Gurugram - Faridabad - Sonipat - Panipat - Karnal - Ambala - Patiala - Behror - Jaipur

the **health** care providers

the **health** care providers



Scanned with OKEN Scanner



DEPARTMENT OF PATHOLOGY

Patient Name : Mrs. BHATERI	Bill Date : 09/02/2023 12:47 PM
MR No : 671595	Sample Col Dt/Tm : 09/02/2023 01:18 pm
Age/Sex : 33 Years 1 Months 9 Days / Female	Sample Rec Dt/Tm : 09/02/2023 01:04 pm
Type : OPD	Reporting Date : 2023-02-09 00:22:01 15:52:
TPA/Corporate : MEDIWHEEL PVT LTD	Sample ID : 97822
Ref Doctor : Dr.RMO	Bill/Req. No. : 24038701

Test	Result	Bio. Ref. Interval	Units	Method
------	--------	--------------------	-------	--------

BLOOD SUGAR FASTING

PLASMA GLUCOSE FASTING	84	60 - 110	mg/dl	GOD TRINDERS
------------------------	----	----------	-------	--------------

***** END OF THE REPORT *****



Dr. PRADIP KUMAR
Consultant (Microbiology)

Dr. SONIA KUMARI
MD Pathology (Gold Medalist)

Dr. NISHA TIWARI
MBBS, MD (Microbiology)

USER NM ARUN



(This is only professional opinion and not the diagnosis, please consult your doctor for further clinical advice) Page 1 of 1

Q Block, South City -II, Sohna Road, Sector-47, Gurgaon, Haryana
Ph.: 0124-4900000 (100 Lines). Toll Free No. : 1800-102-6767, Mob.: 62 62 82 82 35, Email: customercare@parkhospital.in

PARK GROUP OF HOSPITALS : West Delhi - Gurugram - Faridabad - Sonapat - Panipat - Karnal - Ambala - Patiala - Behror - Jaipur

the **health** care providers

the **health** care providers





DEPARTMENT OF PATHOLOGY

Patient Name : Mrs. BHATERI

MR No : 671595

Age/Sex : 33 Years 1 Months 9 Days / Female

Type : OPD

TPA/Corporate : MEDIWHEEL PVT LTD

Bill Date : 09/02/2023

Reporting Date : 09/02/2023

Sample ID : 97822

Bill/Req. No. : 24038701

Ref Doctor : Dr.RMO

Test	Result	Bio. Ref. Interval	Units	Method
BLOOD SUGAR 2 HR. PP				
BLOOD SUGAR P.P.	125	80 - 150	mg/dl	

***** END OF THE REPORT *****



Sample no.

Dr. SONIA KUMARI
MBBS, MD (PATHOLOGY) Gold medalist

Dr. PRADIP KUMAR
Consultant (Microbiology)

Dr. NISHA TIWARI
MBBS, MD (Microbiology)

USER NM ARUN



Cert. No. H-2016-0369 Cert. No. MC - 4830

(This is only professional opinion and not the diagnosis, please correlate clinically)

Q Block, South City -II, Sohna Road, Sector-47, Gurgaon, Haryana
Ph.: 0124-4900000 (100 Lines), Toll Free No. : 1800-102-6767, Mob.: 62 62 82 82 35, Email: customercare@parkhospital.in

PARK GROUP OF HOSPITALS : West Delhi - Gurugram - Faridabad - Sonapat - Panipat - Karnal - Ambala - Patiala - Behror - Jaipur

the **health** care providers

the **health** care providers





DEPARTMENT OF PATHOLOGY

Patient Name : Mrs. BHATERI
MR No : 671595
Age/Sex : 33 Years 1 Months 9 Days / Female
Type : OPD
TPA/Corporate : MEDIWHEEL PVT LTD

Bill Date : 09/02/2023
Reporting Date : 09/02/2023
Sample ID : 97822
Bill/Req. No. : 24038701
Ref Doctor : Dr.RMO

Test	Result	Bio. Ref. Interval	Units	Method
URINE ROUTINE AND MICROSCOPY				
PHYSICAL CHARACTERSTICS				
QUANTITY	40ml	5 - 100	ml	Vishal
COLOUR	Pale Yellow	Pale Yellow		
TURBIDITY	Clear	clear		urinometer
SPECIFIC GRAVITY	1.025	1.000-1.030		PH PAPER
PH	Acidic	Acidic/Alkaline		
CHEMICAL EXAMINATION-1				
UROBILINOGEN	NIL	NIL	mg/dl	Ehrlich Protein error indicator
URINE PROTEIN	NIL	NIL		
BLOOD	NIL	NIL	mg/dL	GOD-POD/Benedicts SOD.
GLUCOSE	NIL	NIL		
URINE KETONE	NIL	NIL		
MICRO.EXAMINATION				
PUS CELL	2-4	0-5	cells/hpf	Microscopic
RED BLOOD CELLS	Nil	0-2	cells/hpf	
EPITHELIAL CELLS	1-2	0-5	cells/hpf	
CASTS	NIL	NIL	/hpf	
CRYSTALS	NIL	NIL	/hpf	
OTHER	NIL			

***** END OF THE REPORT *****



Sample no.

Dr. SONIA KUMARI
MBBS, MD (PATHOLOGY) Gold medalist

Dr. PRADIP KUMAR
Consultant (Microbiology)

Dr. NISHA TIWARI
MBBS, MD (Microbiology)

USER NM SHOAI BPA166



Cert. No. H-2016-0369 Cert. No. MC - 4830

(This is only professional opinion and not the diagnosis, please correlate clinically)

Q Block, South City -II, Sohna Road, Sector-47, Gurgaon, Haryana
Ph.: 0124-4900000 (100 Lines), Toll Free No. : 1800-102-6767, Mob.: 62 62 82 82 35, Email: customercare@parkhospital.in

PARK GROUP OF HOSPITALS : West Delhi - Gurugram - Faridabad - Sonapat - Panipat - Karnal - Ambala - Patiala - Behror - Jaipur





DEPARTMENT OF PATHOLOGY

Patient Name : Mrs. BHATERI	Bill Date : 09/02/2023
MR No : 671595	Reporting Date : 09/02/2023
Age/Sex : 33 Years 1 Months 9 Days / Female	Sample ID : 97822
Type : OPD	Bill/Req. No. : 24038701
TPA/Corporate : MEDIWHEEL PVT LTD	Ref Doctor : Dr.RMO

Test	Result	Bio. Ref. Interval	Units	Method
------	--------	--------------------	-------	--------

BLOOD GROUPING AND RH FACTOR

BLOOD GROUP	* O * RH POSITIVE	MATRIX GEL
-------------	-------------------	------------

***** END OF THE REPORT *****



Sample no.

Dr. SONIA KUMARI
MBBS, MD (PATHOLOGY) Gold medalist

Dr. PRADIP KUMAR
Consultant (Microbiology)

Dr. NISHA TIWARI
MBBS, MD (Microbiology)

USER NM ARUN



Cert. No. H-2016-0365 Cert. No. MC-4630

(This is only professional opinion and not the diagnosis, please correlate clinically) Page 1 of 1

Q Block, South City-II, Sohna Road, Sector-47, Gurgaon, Haryana

Ph.: 0124-4900000 (100 Lines), Toll Free No. : 1800-102-6767, Mob.: 62 62 82 82 35, Email: customercare@parkhospital.in

PARK GROUP OF HOSPITALS : West Delhi - Gurugram - Faridabad - Sonapat - Panipat - Karnal - Ambala - Patiala - Behror - Jaipur

the **health** care providers

the **health** care providers





DEPARTMENT OF PATHOLOGY

Patient Name : Mrs. BHATERI
 MR No : 671595
 Age/Sex : 33 Years 1 Months 9 Days / Female
 Type : OPD
 TPA/Corporate : MEDIWHEEL PVT LTD

Bill Date : 09/02/2023
 Reporting Date : 09/02/2023
 Sample ID : 97822
 Bill/Req. No. : 24038701
 Ref Doctor : Dr.RMO

Test	Result	Bio. Ref. Interval	Units	Method
CBC				
HAEMOGLOBIN	10.6	L 12 - 15	gm/dL	COLORIMETRY
TOTAL LEUCOCYTE COUNT	5500	4000-11000	/ μ L	ELECTRICAL
DIFFERENTIAL COUNT				
NEUTROPHILS	60	40.0 - 80.0	%	FLOW CYTOMETRY
LYMPHOCYTES	30	20.0 - 40.0	%	FLOW CYTOMETRY
MONOCYTES	08	2.0 - 10.0	%	FLOW CYTOMETRY
EOSINOPHILS	02	0.0 - 5.0	%	FLOW CYTOMETRY
BASOPHILS	00	0.0 - 2.0	%	FLOW CYTOMETRY
RED BLOOD CELL COUNT	4.4	3.5 - 5.5	millions/ μ L	ELECTRICAL
PACKED CELL VOLUME	36.8	35.0 - 50.0	%	ELECTRICAL
MEAN CORPUSCULAR VOLUME	83.1	83 - 101	fL	ELECTRICAL
MEAN CORPUSCULAR HAEMOGLOBIN	23.9	L 27 - 31	Picogrames	CALCULATED
MEAN CORPUSCULAR HB CONC	28.8	L 33 - 37	g/dl	CALCULATED
PLATELET COUNT	307	150 - 450	thou/ μ L	ELECTRICAL
RDW	13.3	11.6 - 14.5	%	CALCULATED
SPECIMEN TYPE	WHOLE BLOOD-EDTA			

***** END OF THE REPORT *****



Sample no.

Dr. SONIA KUMARI
 MBBS, MD (PATHOLOGY) Gold medalist

Dr. PRADIP KUMAR
 Consultant (Microbiology)

Dr. NISHA TIWARI
 MBBS, MD (Microbiology)

USER NM ARUN



Cert. No. H-2016-0360 Cert. No. MC-4835

(This is only professional opinion and not the diagnosis, please correlate clinically)

Q Block, South City -II, Sohna Road, Sector-47, Gurgaon, Haryana
 Ph.: 0124-4900000 (100 Lines), Toll Free No. : 1800-102-6767, Mob.: 62 62 82 82 35, Email: customercare@parkhospital.in

PARK GROUP OF HOSPITALS : West Delhi - Gurugram - Faridabad - Sonapat - Panipat - Karnal - Ambala - Patiala - Behror - Jaipur

the health care providers

the health care providers





DEPARTMENT OF PATHOLOGY

Patient Name : Mrs. BHATERI
MR No : 671595
Age/Sex : 33 Years 1 Months 9 Days / Female
Type : OPD
TPA/Corporate : MEDIWHEEL PVT LTD

Bill Date : 09/02/2023
Reporting Date : 09/02/2023
Sample ID : 97822
Bill/Req. No. : 24038701
Ref Doctor : Dr.RMO

Test	Result	Bio. Ref. Interval	Units	Method
ESR (WESTERGREN)				
E.S.R. - II HR.	25		mm II Hr.	Westergren

***** END OF THE REPORT *****



Sample no.

Dr. SONIA KUMARI
MBBS, MD (PATHOLOGY) Gold medalist

Dr. PRADIP KUMAR
Consultant (Microbiology)

Dr. NISHA TIWARI
MBBS, MD (Microbiology)

USER NM ARUN



Cert. No. H-2016-0369 Cert. No. MC-4830

(This is only professional opinion and not the diagnosis, please correlate clinically)

Q Block, South City -II, Sohna Road, Sector-47, Gurgaon, Haryana
Ph.: 0124-4900000 (100 Lines), Toll Free No. : 1800-102-6767, Mob.: 62.62.82.82.35, Email: customer@parkhospital.in

PARK GROUP OF HOSPITALS : West Delhi - Gurugram - Faridabad - Sonapat - Panipat - Karnal - Ambala - Patiala - Behror - Jaipur





DEPARTMENT OF PATHOLOGY

Patient Name : Mrs. BHATERI
MR No : 671595
Age/Sex : 33 Years 1 Months 9 Days / Female
Type : OPD
TPA/Corporate : MEDIWHEEL PVT LTD

Bill Date : 09/02/2023
Reporting Date : 09/02/2023
Sample ID : 97822
Bill/Req. No. : 24038701
Ref Doctor : Dr.RMO

Test	Result	Bio. Ref. Interval	Units	Method
THYROID PROFILE				
TRI-IODOTHYRONINE (T3)	1.57	0.60 - 1.81	ng/ml	Chemiluminescence
THYROXINE (T4)	12.4	5.01 - 12.45	µg/dL	Chemiluminescence
THYROID STIMULATING HORMONE	0.66	0.5-5.50,	µIU/ml	
SPECIMEN TYPE	SERUM			
Method : chemiluminescent immunoassay				

Note : Clinical Significance:

Thyroid function tests (TFTs) is a collective term for blood tests used to check the function of the thyroid. TFTs may be requested if a patient is thought to suffer from hyperthyroidism (overactive thyroid) or hypothyroidism (underactive thyroid), or to monitor the effectiveness of either thyroid-suppression or hormone replacement therapy. It is also requested routinely in conditions linked to thyroid disease, such as atrial fibrillation and anxiety disorder. A TFT panel typically includes thyroid hormones such as thyroid-stimulating hormone (TSH, thyrotropin) and thyroxine (T4), and triiodothyronine (T3) depending on local laboratory policy.

Note: Please correlate with clinical condition

***** END OF THE REPORT *****



Sample no.

Dr. SONIA KUMARI
MBBS, MD (PATHOLOGY) Gold medalist

Dr. PRADIP KUMAR
Consultant (Microbiology)

Dr. NISHA TIWARI
MBBS, MD (Microbiology)

USER NM DINESH



Cert. No. H-2016-0380 Cert. No. MC - 4630

(This is only professional opinion and not the diagnosis, please correlate clinically)

Q Block, South City -II, Sohna Road, Sector-47, Gurgaon, Haryana
Ph.: 0124-4900000 (100 Lines), Toll Free No. : 1800-102-6767, Mob.: 62 62 82 82 35, Email: customercare@parkhospital.in

PARK GROUP OF HOSPITALS : West Delhi - Gurugram - Faridabad - Sonapat - Panipat - Karnal - Ambala - Patiala - Behror - Jaipur

the health care providers the health care providers





DEPARTMENT OF PATHOLOGY

Patient Name : Mrs. BHATERI
MR No : 671595
Age/Sex : 33 Years 1 Months 9 Days / Female
Type : OPD
TPA/Corporate : MEDIWHEEL PVT LTD

Bill Date : 09/02/2023
Reporting Date : 09/02/2023
Sample ID : 97822
Bill/Req. No. : 24038701
Ref Doctor : Dr.RMO

Test	Result	Bio. Ref. Interval	Units	Method
LFT (LIVER FUNCTION TEST)				
LFT				
TOTAL BILIRUBIN	0.3	0 - 1.2	mg/dL	DIAZO
DIRECT BILIRUBIN	0.2	0 - 0.4	mg/dL	DIAZO
INDIRECT BILIRUBIN	0.1	0.10 - 0.6	mg/dL	CALCULATED
SGOT (AST)	19	0 - 45	U/L	IFCC WITHOUT
SGPT (ALT)	11	0 - 45	U/L	IFCC WITHOUT
ALKALINE PHOSPHATASE	65	30 - 170	IU/L	MODIFIED IFCC
TOTAL PROTEINS	6.7	6.4 - 8.0	g/dL	BIURET
ALBUMIN	4.2	3.3 - 5.5	g/dL	BCG DYE
GLOBULIN	2.5	2.3 - 4.5	g/dL	CALCULATED
A/G RATIO	1.68	1.1 - 2.2		CALCULATED

SPECIMEN TYPE SERUM

***** END OF THE REPORT *****



Sample no.

Dr. SONIA KUMARI
MBBS, MD (PATHOLOGY) Gold medalist

Dr. PRADIP KUMAR
Consultant (Microbiology)

Dr. NISHA TIWARI
MBBS, MD (Microbiology)

USER NM ARUN



(This is only professional opinion and not the diagnosis, please correlate clinically) Page 1 of 1

Q Block, South City -II, Sohna Road, Sector-47, Gurgaon, Haryana

Ph.: 0124-4900000 (100 Lines), Toll Free No. : 1800-102-6767, Mob.: 62 62 82 82 35, Email: customercare@parkhospital.in

PARK GROUP OF HOSPITALS : West Delhi - Gurugram - Faridabad - Sonapat - Panipat - Karnal - Ambala - Patiala - Behror - Jaipur

the **health** care providers

the **health** care providers





DEPARTMENT OF PATHOLOGY

Patient Name : Mrs. BHATERI
MR No : 671595
Age/Sex : 33 Years 1 Months 9 Days / Female
Type : OPD
TPA/Corporate : MEDIWHEEL PVT LTD

Bill Date : 09/02/2023
Reporting Date : 09/02/2023
Sample ID : 97822
Bill/Req. No. : 24038701
Ref Doctor : Dr.RMO

Test	Result	Bio. Ref. Interval	Units	Method
KFT (RENAL PROFILE)				
KFT				
SERUM UREA	22	10 - 45	mg/dL	UREASE-GLDH
SERUM CREATININE	0.9	0.4 - 1.4	mg/dL	MODIFIED JAFFES
SERUM URIC ACID	3.4	2.5 - 7.0	mg/dL	URICASE
SERUM SODIUM	137	136 - 148	mmol/L	ISE
SERUM POTASSIUM	3.6	3.5 - 5.5	meq/l	ISE
SERUM CALCIUM	8.7	8.5 - 10.5	mg/dL	ARSENazo III
SERUM PHOSPHORUS	3.9	2.5 - 4.5	mg/dL	AMMONIUM
SPECIMEN TYPE	SERUM			

***** END OF THE REPORT *****



Sample no.

Dr. SONIA KUMARI
MBBS, MD (PATHOLOGY) Gold medalist

Dr. PRADIP KUMAR
Consultant (Microbiology)

Dr. NISHA TIWARI
MBBS, MD (Microbiology)

USER NM ARUN



Cert. No. H-2016-0369 Cert. No. MC-4830

(This is only professional opinion and not the diagnosis, please correlate clinically)

Q Block, South City -II, Sohna Road, Sector-47, Gurgaon, Haryana
Ph: 0124-4900000 (100 Lines), Toll Free No.: 1800-102-6767, Mob.: 62 62 82 82 35, Email: customercare@parkhospital.in

PARK GROUP OF HOSPITALS : West Delhi - Gurugram - Faridabad - Sonapat - Panipat - Karnal - Ambala - Patiala - Behror - Jaipur

the **health** care providers

the **health** care providers





DEPARTMENT OF PATHOLOGY

Patient Name : Mrs. BHATERI
 MR No : 671595
 Age/Sex : 33 Years 1 Months 9 Days / Female
 Type : OPD
 TPA/Corporate : MEDIWHEEL PVT LTD

Bill Date : 09/02/2023
 Reporting Date : 09/02/2023
 Sample ID : 97822
 Bill/Req. No. : 24038701
 Ref Doctor : Dr.RMO

Test	Result	Bio. Ref. Interval	Units	Method
LIPID PROFILE				
LIPID PROFILE				
TOTAL CHOLESTEROL	187	0 - 250	mg/dL	CHOD -Trinder
SERUM TRIGLYCERIDES	169	H 60 - 165	mg/dl	GPO-TRINDER
HDL-CHOLESTEROL	42	30 - 70	mg/dl	DIRECT
VLDL CHOLESTEROL	33	H 6 - 32	mg/dL	calculated
LDL	152	H 50 - 135	mg/dl	calculated
LDL CHOLESTEROL/HDL RATIO	3.6	H 1.0 - 3.0	mg/dL	calculated
TOTAL CHOLESTEROL/HDL RATIO	4.4	2.0 - 5.0	mg/dl	calculated
SPECIMEN TYPE	SERUM			

***** END OF THE REPORT *****



Sample no.

Dr. SONIA KUMARI
 MBBS, MD (PATHOLOGY) Gold medalist

Dr. PRADIP KUMAR
 Consultant (Microbiology)

Dr. NISHA TIWARI
 MBBS, MD (Microbiology)

USER NM ARUN



Cert. No. H-2016-0369 Cert. No. MC-4930

(This is only professional opinion and not the diagnosis, please correlate clinically)

Q Block, South City -II, Sohna Road, Sector-47, Gurgaon, Haryana

Ph.: 0124-4900000 (100 Lines), Toll Free No. : 1800-102-6767, Mob.: 62 62 82 82 35, Email: customercare@parkhospital.in

PARK GROUP OF HOSPITALS : West Delhi - Gurugram - Faridabad - Sonapat - Panipat - Karnal - Ambala - Patiala - Behror - Jaipur





BP - 100/80

Weight - 62.8 Kg

Married for 10 yr.

P2. Last child 6 yr
Both LSCs.

Cycles. 3-4/28-30 regular flow @
LMP 2/2/23.

G.C. fair, afebrile, Paller. mild.

P/A Soft Pfennessel mass in +

P/S Cx(H)
P/V W. RU NS for fa fec

PA P. Smear later

[Signature]



Cert. No. H-2016-0369 Cert. No. MC-4830

(This is only professional opinion and not the diagnosis, please correlate clinically)

Q Block, South City-II, Sohna Road, Sector-47, Gurgaon, Haryana

Ph.: 0124-4900000 (100 Lines), Toll Free No. : 1800-102-6767, Mob.: 62 62 82 82 35, Email: customercare@parkhospital.in

PARK GROUP OF HOSPITALS : West Delhi - Gurugram - Faridabad - Sonapat - Panipat - Karnal - Ambala - Patiala - Behror - Jaipur

the **health** care providers

the **health** care providers





Mrs. Bhatnagar

Health checkup

NO W/O HTN / DM / Hypothyroid

BP- 110/60 mmHg

PR- 78/min

SpO₂ - 98% RA

ALU

W/O 2 reports / eos

CNS

CVS

R/S

P/A

WNL

Aggarwal



(This is only professional opinion and not the diagnosis, please correlate clinically)

Q Block, South City -II, Sohna Road, Sector-47, Gurgaon, Haryana

Ph.: 0124-4900000 (100 Lines), Toll Free No. : 1800-102-6767, Mob.: 62 62 82 82 35, Email: customercare@parkhospital.in

PARK GROUP OF HOSPITALS : West Delhi - Gurugram - Faridabad - Sonapat - Panipat - Karnal - Ambala - Patiala - Behror - Jaipur

the **health** care providers

the **health** care providers





DEPARTMENT OF RADIOLOGY

Patient Name	Mrs. BHATERI	Billed Date	: 09/02/2023	12.47 PM
Reg No	671595	Reported Date	: 09/02/2023	
Age/Sex	33 Years 1 Months 9Days / Female	Req. No.	: 24038701	
Type	OPD	Consultant Doctor	: Dr. RMO	

USG WHOLE ABDOMEN

The real time, B mode, gray scale sonography of the abdominal organs was performed.

LIVER : The liver is normal in size, 13.1shape and echotexture. No evidence of any focal lesion. IHBR is not dilated.

GALL BLADDER : The gall bladder is well distended . No evidence any calculus or mass seen.

GB wall thickness with in normal limits.No evidence of pericholecystic fluid is seen.

BILE DUCT :The common bile duct is normal in caliber. No evidence of calculus is noted in common bile duct.

SPLEEN :The spleen is normal in size and shape.Its echotexture is homogeneous.No evidence of focal lesion is noted.

PANCREAS :The pancreas is normal in size, shape, contours and echotexture.No evidence of solid or cystic mass lesion is noted.MPD is not dilated. No evidence of peripancreatic collection.

KIDNEYS : The bilateral kidneys are normal in size and echotexture. Cortico-medullary differentiation is maintained.There is no evidence of obvious calculus or hydronephrosis.

URINARY BLADDER :The urinary bladder is well distended.It shows uniformly thin walls and sharp mucosa.No evidence of calculus is seen. No evidence of mass or diverticulum is noted.

UTERUS: The uterus is anteverted. It measures 7.2x3.6x3.7 cms. in the longitudinal, anteroposterior and transverse dimensions respectivelyThe uterine margins is smooth and does not reveal any contour abnormalities.

The uterine myometrium shows homogeneous echotexture.

No evidence of leiomyoma is noted. No solid or cystic mass lesion is noted.

The endometrial echo is in the midline and measures 4mm.

The ovaries on the either side show normal echotexture.

No adnexal mass is seen.No cyst is seen in ovaries.

No evidence of ascites or interbowel free fluid is seen.

No evidence of obvious retroperitoneal or mesentric lymphadenopathy is seen.

IMPRESSION- NORMAL STUDY

To be correlated clinically.



Dr.ANSHU K.SHARMA
MBBS,MD
CONSULTANT RADIOLOGIST

Dr.MANJEET SEHRAWAT
MBBS,MD,PDCC
CONSULTANT RADIOLOGIST

Dr. NEENA SIKKA
MBBS,DNB
CONSULTANT RADIOLOGIST

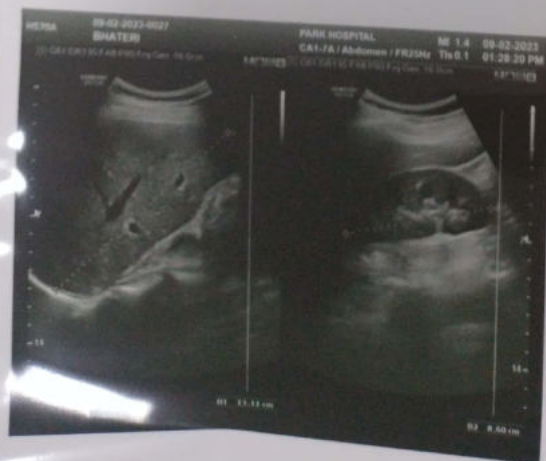
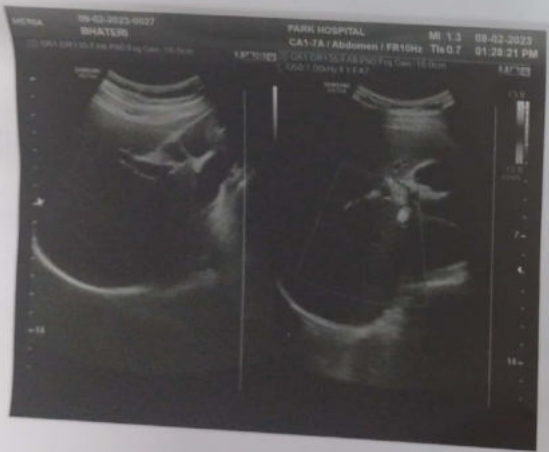
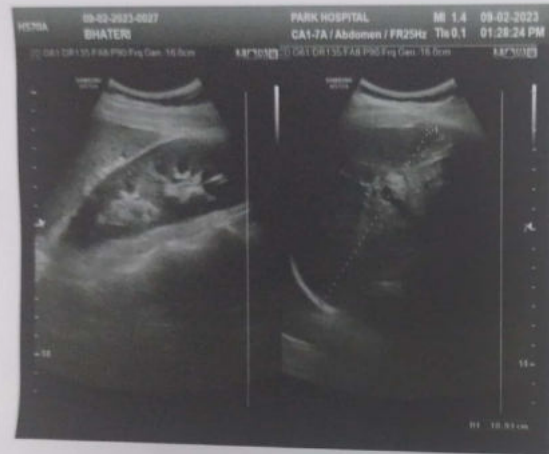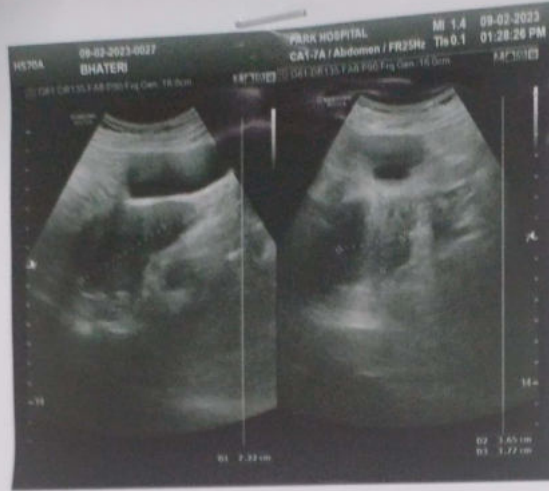(This is only professional opinion and not the diagnosis, please correlate clinically)

Q Block, South City -II, Sohna Road, Sector-47, Gurgaon, Haryana

Ph.: 0124-4900000 (100 Lines), Toll Free No. : 1800-102-6767, Mob.: 62 62 82 82 35, Email: customercare@parkhospital.in

PARK GROUP OF HOSPITALS : West Delhi - Gurugram - Faridabad - Sonapat - Panipat - Karnal - Ambala - Patiala - Behror - Jaipur





DEPARTMENT OF RADIOLOGY

Patient Name	Mrs BHATERI	Billed Date	09/02/2023	12 47 PM
Reg No	671595	Reported Date	09/02/2023	
Age/Sex	33 Years 1 Months 9Days / Female	Req. No.	24038701	
Type	OPD	Consultant Doctor	Dr. RMO	

X-RAY CHEST AP/PA

X-RAY CHEST P.A. VIEW

Bilateral lungs appears normal.

No focal lung lesion seen.

No evidence of free fluid is seen.

Both hila are normal in size, have equal density and bear normal relationship.

The heart and trachea are central in position and no mediastinal abnormality is visible.

The cardiac size is normal for patient age and view.

The domes of the diaphragms are normal in position, and show smooth outline.

To be correlated clinically



Dr. ANSHU K. SHARMA
MBBS, MD
CONSULTANT RADIOLOGIST

Dr. MANJEET SEHRAWAT
MBBS, MD, PDCC
CONSULTANT RADIOLOGIST

Dr. NEENA SIKKA
MBBS, DNB
CONSULTANT RADIOLOGIST



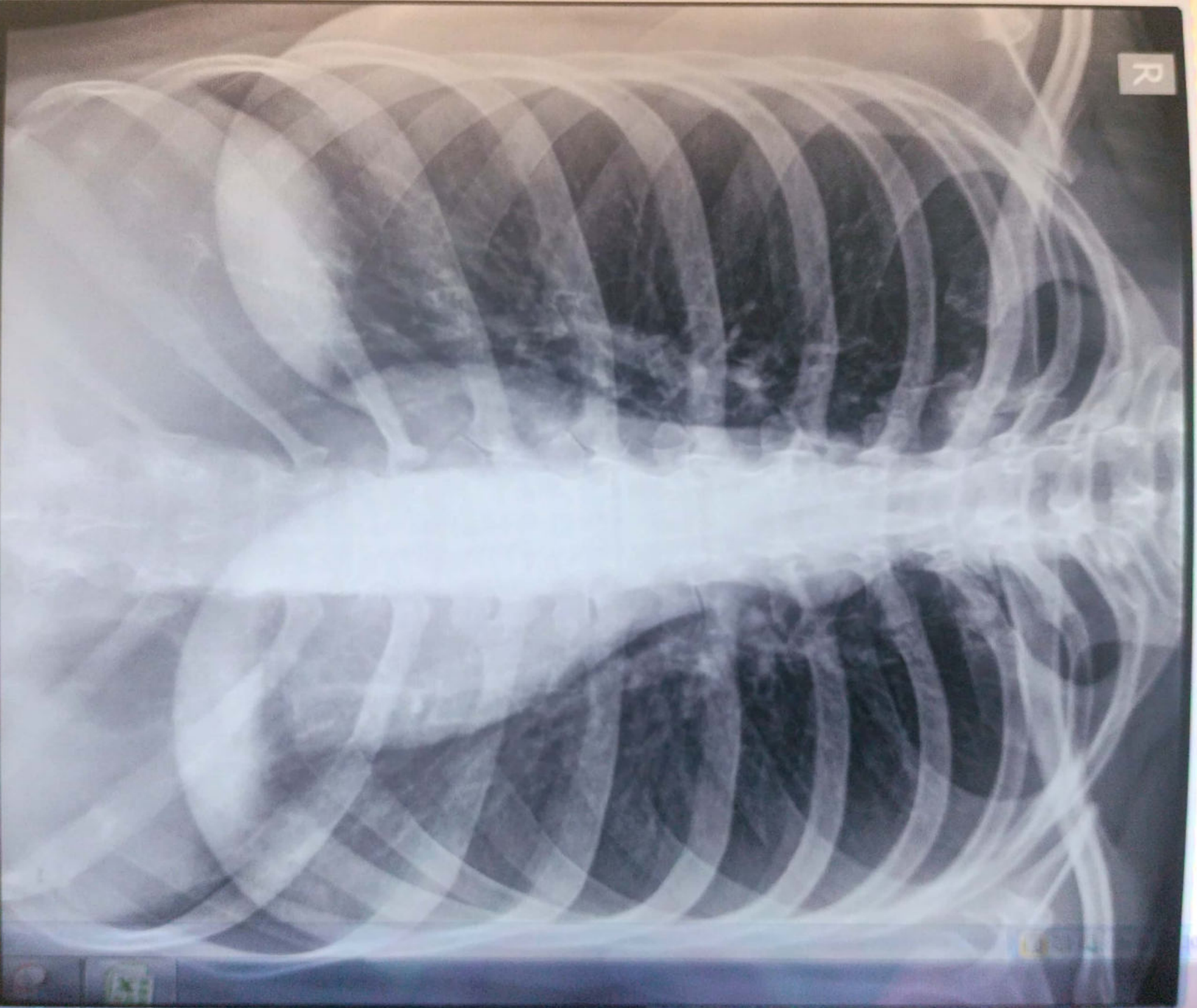
(This is only professional opinion and not the diagnosis, please correlate clinically)

Q Block, South City -II, Sohna Road, Sector-47, Gurgaon, Haryana
Ph.: 0124-4900000 (100 Lines), Toll Free No. : 1800-102-6767, Mob.: 62 62 82 82 35, Email: customercare@parkhospital.in

PARK GROUP OF HOSPITALS : West Delhi - Gurugram - Faridabad - Sonapat - Panipat - Karnal - Ambala - Patiala - Behror - Jaipur



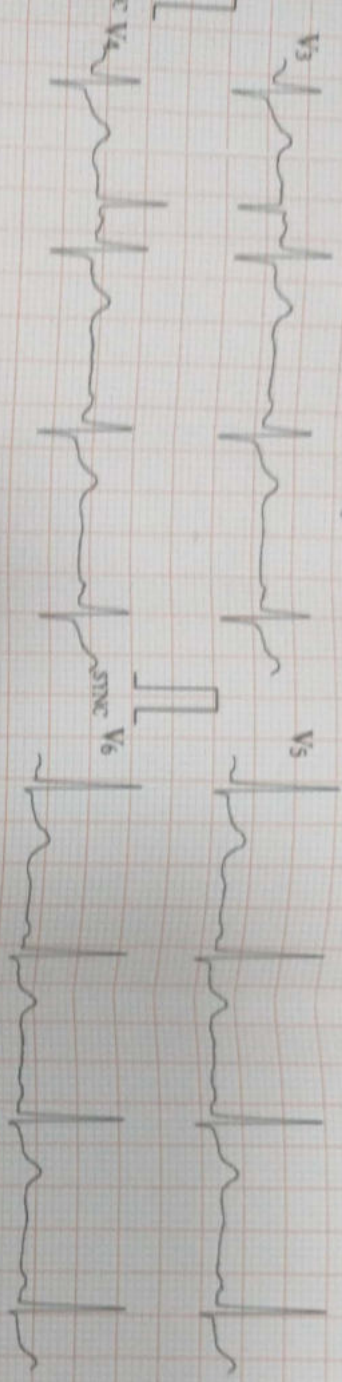
R



BHATERI 33Y F Female
Chest PA
REQ24038701 2/9/2023 1:09:35 PM
PARK HOSPITAL, SOUTH CITY II, GURGAON, HARYANA

10mm/mV

10mm/mV



ID : 0002

HR : 76.9

R-R : 858

P-R : 204

QRS : 91

QT/QTc : 367/395

P/QTST : 67/60/37

RV5/SV1 : 1.330/0.710 mV

RV5-SVL : 2.040

Name: BHATNARAYAN

Sex: Female

Age: 31

Sinus Rhythm
 Abnormality/Flat T

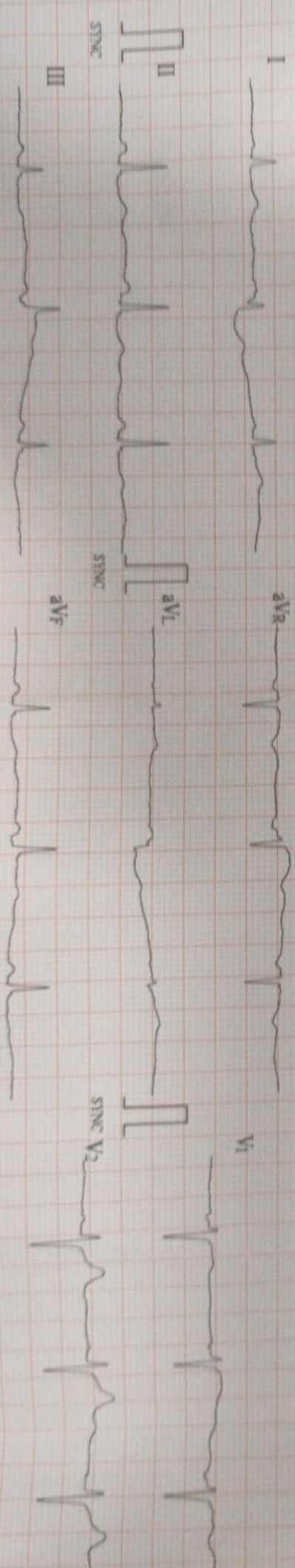
Unconfirmed report Verified by:

25mm/s 0.5 mV

10mm/mV

10mm/mV

10mm/mV



ECG-1209 V1.0001 B105: V0-0001 AAF: V0-0001 2016-09-09 00:00