



भारत सरकार  
GOVERNMENT OF INDIA

জিতেন্দ্র প্রসাদ

Jitendra Prasad

जन्म तिथि / DOB : 07/02/1987

पुरुष / MALE



6483 8153 3196

मेरा आधार, मेरी पहचान



भारतीय विशिष्ट पहचान प्राधिकरण  
UNIQUE IDENTIFICATION AUTHORITY OF INDIA

Address

S/O Jamuna Prasad 83/H  
Khatir Bazar Lane  
Serampore Rishra  
Serampore M Rishra  
Hooghly West Bengal -  
712248

विवरण:

S/O यमुना प्रसाद, 83/एच  
खतिर बाजार लाने  
सेरामपुर रिशरा, जे. पश्चिम बंगाल (712248)  
भारतीय पहचान - 712248



1947



help@uidai.gov.in



www.uidai.gov.in



6483 8153 3196

P.O. Box No.1947,  
Bengaluru-560 001

Handwritten signature in blue ink.

  
**बैंक ऑफ बड़ोदा**  
**Bank of Baroda**

नाम  
Name : JITENDRA PRASAD

कार्डनंबर क्र. E.C. No. 90629

  
संयोजक अधिकारी  
Issuing Authority CM (Coord) EZ

  
  
धारक के हस्ताक्षर  
Signature of Holder



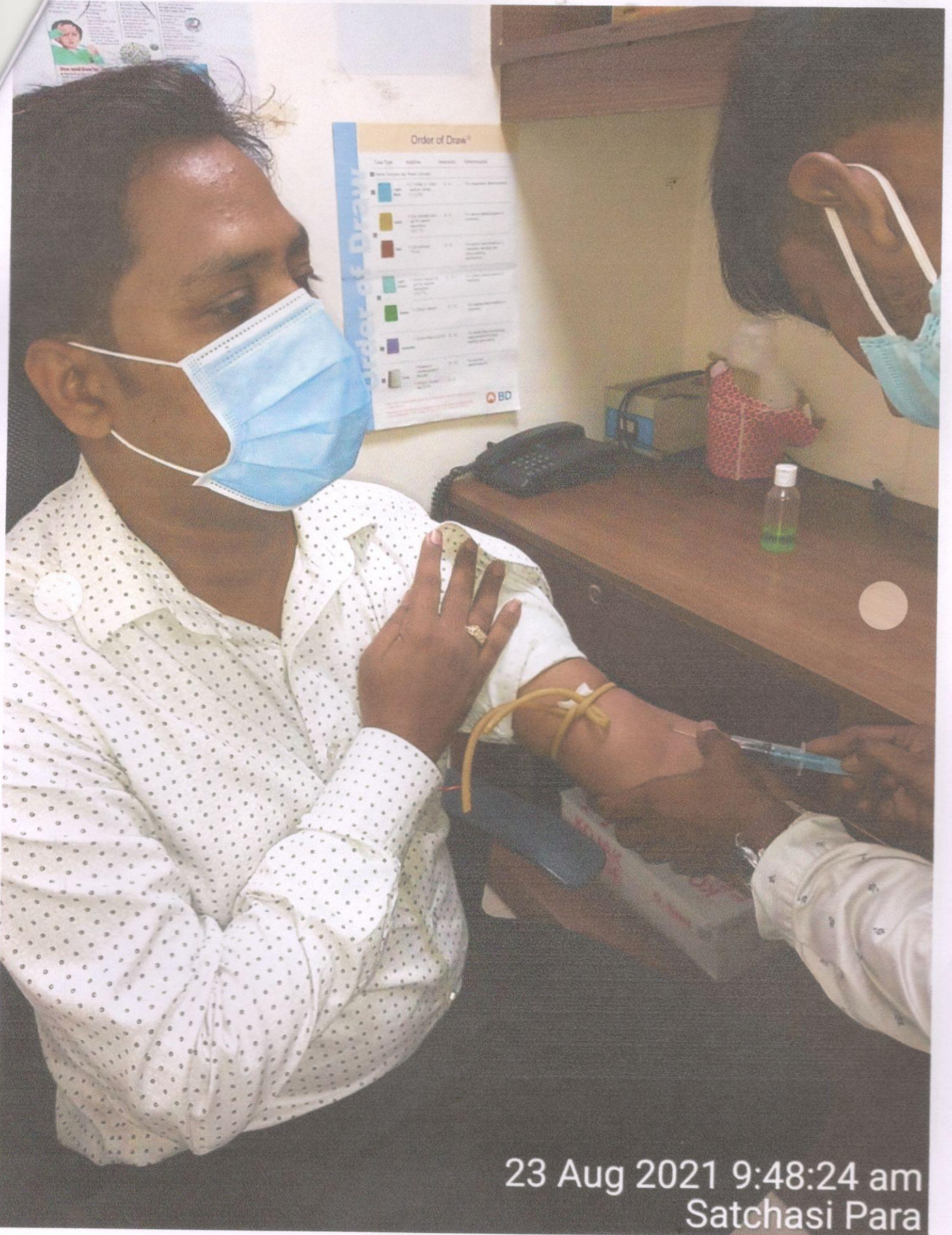
WISSANIR NO.7075  
DATE:27/02/2012

विषय वर परिचयित हो विना  
संस्थापक महाराज (पुस्तक) वरु सारु सारु, सारु सारु सारु सारु  
सं-26, वी सारु, सारु सारु सारु सारु, सारु 400 051, सारु  
सं-91 22 4698 5196 सारु 91 22 2652 5747

If found, please return to :  
Asst. General Manager (Security), Bank of Baroda, Baroda Corporate Centre  
C-26, G Block, Bandra-Kurla Complex, Mumbai 400 051, India  
Phone : 91 22 8689 5196 Fax : 91 22 2652 5747

रु सारु / Blood Group :  
संस्थापक महाराज / Identification mark : TWO MOLE ON THE NOSE

संस्थापक महाराज / Issuing Office  
BOB, Eastam Zone, Plot No. 38/2, Block - GN, Sector - V, Salt Lake City, Kolkata - 700 091



23 Aug 2021 9:48:24 am  
Satchasi Para



23 Aug 2021 9:40:34 am  
Satchasi Para



**DR. BOUDHAYAN BHATTACHARJEE**

MBBS. (MEDICAL COLLEGE, KOLKATA) MD (TROPICAL MEDICINE)  
CONSULTANT PHYSICIAN & INTENSIVIST

**TO WHOM IT MAY CONCERN**

THIS IS TO CERTIFY THAT, MR. JITENDRA PRASAD, 34Y/MALE,  
IS PHYSICALLY FIT.

HIS ALL REPORTS ARE IN NORMAL RANGE.

DATE: 24.08.21 .....

Dr. BOUDHAYAN BHATTACHARJEE  
MBBS, MD (TROPICAL MEDICINE)  
65631 of WBMC

*Boudhayan Bhattacharjee*  
.....

SIGNATURE  
STAMP

**DR. SOURADEEP RAY**


MBBS, MS (ENT)  
ASSOCIATE PROFESSOR R.G. KAR MEDICAL, KOLKATA.  
REGD.NO. 63999 (WBMC)

**TO WHOM IT MAY CONCERN**

THIS IS TO CERTIFY THAT **MR. JITENDRA PRASAD, 34Y/MALE,**  
HAS NO PROBLEM IN HIS EAR, NOSE AND THROAT.

HIS EAR IS CLEAN, NO HEARING PROBLEM OBSERVED,  
NASAL PASSAGE IS CLEAR, WITH PROPER SMELLING CAPACITY,  
THROAT IS CLEAR, NO INFECTION FOUND IN TONSILS.

DATE: 24.08.21



SIGNATURE

DC STAMP

**APOLLO CLINIC OM TOWER**  
36C, B.T ROAD OPP "RBU"  
KOL 700002  
Ph 033 25565555  
033 25563333



**DR. ABHIRUP MUKHERJEE**

BDS (WBUHS)  
Oral & Dental Surgeon  
Regn.No. 3726 Part A (Wbdc)

**TO WHOM IT MAY CONCERN**

THIS IS TO CERTIFY THAT **MR. JITENDRA PRASAD, 34Y/MALE,**  
HAS NO ORAL PROBLEM.

THERE IS NO CAVITY AND BAD SMELL OBSERVED IN HIS MOUTH.

DATE: 24.08.21

**DR. ABHIRUP MUKHERJEE**  
BDS (WBUHS)  
Oral & Dental Surgeon  
Regn. No. 3726 Part A (WBDC)

A. Mukherjee

SIGNATURE  
DC STAMP

To whom it may concern.


I am Sushma Prasad aged 34, I came to Apollo Clinic on tower Sathya mare. today 22/08/21, 36 C.B.T. Road Kol-2 for my medical checkup.

For my full body checkup I could not complete treadmill test due to ail in my waist. please do its needful

Thank you.

Sushma Prasad

APOLLO CLINIC OM TOWER  
36C, B.T. ROAD OPP "RBU"  
KOL 700002  
Ph 033 25565555  
033 25563333

  
22/08/21

**DEPARTMENT OF RADIOLOGY X-RAY OF CHEST (PA) VIEW**

MR. NO- FSIN.0000000

SEX-MALE

NAME: -MR. JITENDRA PRASAD

EXAMINATION DATE- 23/08/2021


AGE- 34 YRS

REPORT DATE- 23/08/2021

REF DR.: -SELF

**FINDINGS:**

- Bilateral lung fields are clear.
- Tracheal shadow is in the midline.
- Bilateral CP angle are clear
- Both hilum appear normal .
- CTR appears normal .
- No definite bone fracture is noted.



**DR. ARNAB MANDAL**

MD, Physician, PGDUS (Delhi) CEPT-USG (WBUHS KOLKATA)  
Fellow of Jefferson Ultrasound Radiology and Education Institute  
Philadelphia Ex-Radiology Resident (S.E. Railway)  
Regd.No:72022(WBMC)

**APOLLO CLINIC @ OM TOWER**  
Opp. of Rabindra Bharati University  
Licensee : Satyam Credit Pvt. Ltd.

36C, B. T. Road, Kolkata - 700 002

E-mail : [sinthimor@theapolloclinic.com](mailto:sinthimor@theapolloclinic.com)  
[satyamcreditpvtltd@gmail.com](mailto:satyamcreditpvtltd@gmail.com)



033 2556 3333



033 2556 5555



+91 98521 66666



+91 74392 97827

<b>NAME: MR.JITENDRA PRASAD</b>	<b>AGE:34YRS</b>	<b>SEX:MALE</b>
<b>REF BY: SELF</b>	<b>MR NO:FSIN-0000</b>	<b>DATE: 23.08.2021</b>

**ULTRASOUND OF WHOLE ABDOMEN**

**LIVER:** Liver is **Enlarged Moderate fatty changes seen**. The intrahepatic tubular structures are normal. No focal area of altered echogenicity is noted. The porta hepatis is normal. The common bile duct at porta measures- ( **0.36cm** ) . The portal vein measures- ( **1.03cm** ) at porta.

**GALL BLADDER:** : Gall bladder is distended. Wall is normal limits. No calculus or mass is seen within the gall bladder.

**PANCREAS:** It is normal in size, Shape, Outline and echotexture. Pancreatic duct is not dilated.

**SPLEEN:** Spleen in normal size- ( **11.09cm** ), Shape, Outline and echotexture. No parenchymal lesion is noted.

**RIGHT KIDNEY:** kidneys are normal in position, size, shape, outline and echotexture. The cortico medullary differentiation is maintained. No calculus or hydronephrosis is seen.

**RIGHT KIDNEY:** measures – ( **9.60cm** ).

**LEFT KIDNEY:** kidneys are normal in position, size, shape, outline and echotexture. The cortico medullary differentiation is maintained. **A calculus seen in mid pole (0.56cm)**.


**LEFT KIDNEY:** measures – ( **8.73cm** ).

**URINARY BLADDER:** : It is well distended with normal wall thickness . No calculus or mass is seen within the urinary bladder.

**PROSTATE:** It is normal in size, Shape & homogenous echotexture. The prostatic outline is smooth. The periprostatic plane is normal. It is normal size measures- ( **2.78cmX3.20cmX3.08cm** ) Vol-14.35ml.

**IMPRESSION:**

- HEPATOMEGALY MODERATE FATTY CHANGES.
- LEFT RENAL CALCULUS.

  
**DR.SUSMITA CHOWDHURY**  
MBBS,MD.  
CONSULTANT SONOLOGIST

