

Health Check up Booking Request(22E32656)

lediwheel <wellness@mediwheel.in>
o: healthcare.medicals@gmail.com
c: customercare@mediwheel.in

Wed, Sep 4, 2024 at 4:05 P

**011-41195959****Dear Healthcare Medical Centre and Diagnostic**

We have received a booking request with the following details. Provide your confirmation by clicking on the Yes button.

You confirm this booking?

Name : Devesh pathak
Contact Details : 9920312219
Hospital Package Name : Mediwheel Full Body Health Checkup Male Below 40
Location : 76/754 Mahavir Suryadarshan Soc., Satyanagar Road, Mahavir Nagar, Kandivali (W)
Appointment Date : 07-09-2024

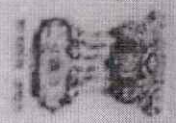Member Information

Booked Member Name	Age	Gender
Devesh pathak	34 year	Male

Tests included in this Package

- Blood Group
- Stool Test
- CBC
- HbA1c
- Lipid Profile
- Kidney Profile
- Liver Profile
- Blood Glucose (Post Prandial)
- Thyroid Profile
- Urine Sugar Fasting
- ~~Urine Sugar PP~~
- ESR
- Blood Glucose (Fasting)
- TMT OR 2D ECHO (Any 1) Chosen By Candidate
- Chest X-ray
- ECG
- USG Whole Abdomen
- Eye Check-up consultation
- Dental Consultation

07/09/2024



भारत सरकार

Government of India



देवेश पाठक

Devesh Pathak

जन्म तिथि/DOB: 02/02/1990


पुरुष/ MALE

Healthcare Soc.-
Mahavir Suryadasthram Nagar
Satyra Nagar Road, Mahavir Nagar
Kandivalli (W), Mumbai - 400 091
Tel. No. 28999 7808

6520 8965 6409

VID : 9188 3194 6874 3073

भेरा आधार, भेरी पहचान



Dr. NUPUR RAI
MBBS, DIPLOMA CARDIOLOGY (PGDCC)
Reg. No. 2018115643

- COMPU. PATHOLOGY • ALLERGY TESTING
- DIGITAL WHOLE BODY X-RAYS
- DIGITAL 3D SONOGRAPHY
- DIGITAL WHOLE BODY COLOUR DOPPLER
- DIGITAL 2-D ECHO WITH COLOUR DOPPLER
- E.C.G. • LUNG FUNCTION TEST
- MAMMOGRAPHY & BONE MINERAL DENSITOMETRY

- COMPUTERISED STRESS TEST
- DENTAL
- ADVANCED DENTISTRY
- PHYSIOTHERAPY
- AUDIOMETRY & SPEECH THERAPY
- FULL BODY HEALTH CHECK-UPS
- CORPORATE HEALTH CHECKUPS



HEALTHCARE

MEDICAL CENTRE & DIAGNOSTICS

NAME:	MR DEVESH PATHAK	DATE	07/09/2024
HEIGHT: 167CMS	WEIGHT: 72.5 KG	AGE:	34YRS
REFERRED BY:	MEDIWHEEL	SEX:	MALE

PRESENT COMPLAINT: NONE	
CURRENT MEDICATION: NONE	
PAST HISTORY: H/O COVID IN 2021	
FAMILY HISTORY: H/O FATHER HTN ,DM SINCE 5 YRS	
ALLERGY: NONE	
HABITS: WHISKEY 90-180ML OR 750ML BEER ONCE IN A WEEK & SMOKING 1 CIGARETTES ONCE IN 3-4 DAYS SINCE 10 YRS	
APPETITE: NORMAL	
SLEEP: NORMAL	BLADDER: NAD
BOWEL: NAD	
GENERAL EXAMINATION:	ADVICE
P: 74/min BP: 120/80 mm of Hg	<i>fit for employment</i>
ICTERUS: NIL	OEDEMA: NIL
OTHERS: NAD	<i>Exercise daily</i>
RS: NAD	<i>Rest</i>
CVS: NAD	
PA: NAD	
CNS: NAD	
INVESTIGATION:	

DR. Y. J. MEHTA
[M.D.]

DR. NUPUR RAI
MBBS, DIPLOMA CARDIOLOGY (PGDCC)
Reg. No.. 2018115643

Healthcare
Mahavir Suryadarshan Soc,
Satya Nagar Road, Mahavir Nagar
Kandivali (W), Mumbai - 400 067
Tel. No. 2869 7808

- COMPU. PATHOLOGY • ALLERGY TESTING
- DIGITAL WHOLE BODY X-RAYS
- DIGITAL 3D SONOGRAPHY
- DIGITAL WHOLE BODY COLOUR DOPPLER
- DIGITAL 2-D ECHO WITH COLOUR DOPPLER
- E.C.G. • LUNG FUNCTION TEST
- MAMMOGRAPHY & BONE MINERAL DENSITOMETRY

- COMPUTERISED STRESS TEST
- DENTAL
- ADVANCED DENTISTRY
- PHYSIOTHERAPY
- AUDIOMETRY & SPEECH THERAPY
- FULL BODY HEALTH CHECK-UPS
- CORPORATE HEALTH CHECKUPS



OPHTHALMIC REPORT

NAME <i>Mr Devesh Pathak</i>	DATE <i>7-09-2024</i>
R- NO	AGE <i>34 yrs</i>
REF. BY DR. <i>Mediwheel</i>	SEX <i>Male</i>

V.A. WITHOUT GLASSES: **RIGHT EYE** *6/6 N6* **LEFT EYE** *6/6 N6*

V.A. WITH GLASSES: *—*

SLIT LAMP EXAMINATION: *—*

IOP - SCHIOTZ TONOMETER: *—*

FUNDUS: *—*

COLOUR VISION: (ISHIHARA CHART) *Normal (PSE)*

OCULAR MOVEMENTS: *Full Normal (PSE)*

RETINOSCOPY: *—*

Prescription:

	SPH	CYL	AXIS	SPH	CYL	AXIS	
DISTANCE	<i>6/6</i>	<i>—</i>	<i>—</i>	<i>—</i>	<i>—</i>	<i>—</i>	<i>N6</i>
NEAR	<i>N6</i>	<i>—</i>	<i>—</i>	<i>—</i>	<i>—</i>	<i>—</i>	<i>N6</i>

CLINICAL IMPRESSION: *(R)*
ADVICE: *—*

Healthcare
Mahavir Suryadarshan Soc,
Satya Nagar Road, Mahavir Nagar
Kandivali (W), Mumbai - 400 067
Tel. No. 2869 7808

DR SAYA **Healthcare** Soc.
Mahavir Suryadarshan Soc,
Satya Nagar Road, Mahavir Nagar
Kandivali (W), Mumbai - 400 067
Tel. No. 2869 7808

- COMPU. PATHOLOGY • ALLERGY TESTING
- DIGITAL WHOLE BODY X-RAYS
- DIGITAL 3D SONOGRAPHY
- DIGITAL WHOLE BODY COLOUR DOPPLER
- DIGITAL 2-D ECHO WITH COLOUR DOPPLER
- E.C.G. • LUNG FUNCTION TEST
- MAMMOGRAPHY & BONE MINERAL DENSITOMETRY

- COMPUTERISED STRESS TEST
- DENTAL
- ADVANCED DENTISTRY
- PHYSIOTHERAPY
- AUDIOMETRY & SPEECH THERAPY
- FULL BODY HEALTH CHECK-UPS
- CORPORATE HEALTH CHECKUPS



HEALTHCARE

MEDICAL CENTRE & DIAGNOSTICS

NAME	MR DEVESH PATHAK	DATE	07.09.2024
		AGE	34 YRS
REF. BY DR	MEDIWHEEL	SEX	MALE

X-RAY CHEST (PAVIEW).

The lungs on the either side show equal translucency.

The pleural spaces are normal.

The cardiac size is normal.

The domes of the diaphragms are normal in position, and show smooth outline.

Ribs appear normal.

IMPRESSION :
NO EVIDENCE OF PLEURAL OR PARENCHYMAL PATHOLOGY IS NOTED.

Correlate clinically .

[Signature]

DR,SACHIN JADKAR
Consultant Radiologist

Note : Investigations have their limitations. Solitary radiological investigations never confirm the final diagnosis. They only help in diagnosing the disease in correlation to clinical symptoms and other related tests. Please interpret accordingly

- COMPU. PATHOLOGY • ALLERGY TESTING
- DIGITAL WHOLE BODY X-RAYS
- DIGITAL 3D SONOGRAPHY
- DIGITAL WHOLE BODY COLOUR DOPPLER
- DIGITAL 2-D ECHO WITH COLOUR DOPPLER
- E.C.G. • LUNG FUNCTION TEST
- MAMMOGRAPHY & BONE MINERAL DENSITOMETRY

- COMPUTERISED STRESS TEST
- DENTAL
- ADVANCED DENTISTRY
- PHYSIOTHERAPY
- AUDIOMETRY & SPEECH THERAPY
- FULL BODY HEALTH CHECK-UPS
- CORPORATE HEALTH CHECKUPS



HEALTHCARE

MEDICAL CENTRE & DIAGNOSTICS

NAME	MR DEVESH PATHAK	DATE	07.09.2024
		AGE	34 YRS
REF. BY DR.	MEDIWHEEL	SEX	MALE

REAL TIME ABDOMINAL SONOGRAPHY SHOWS

Copyright © The McGraw-Hill Companies, Inc. Permission required for reproduction or display.

LIVER : Liver is normal in size showing homogenous parenchymal echotexture. There is no evidence of solid or cystic mass. The portal and the hepatic venous system appears normal.

Gall bladder : The Gall bladder is well distended .The gall bladder wall of normal thickness . No evidence of gall stones.

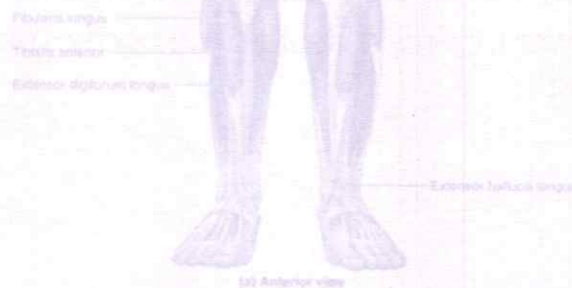PANCREAS : Pancreas is normal in size with smooth margin and homogenous parenchymal echotexture. No focal lesion seen.

KIDNEYS : Both kidneys are normal in size and shows homogenous cortical echotexture. Central calyceal echoes appear normal. There is no evidence of hydronephrosis, focal lesion or renal calculus.

- (a) Right kidney measures: 10.4 x 4.1 cms
- (b) Left kidney measures: 10.8 x 5.0 cms.

SPLEEN : The spleen is normal in size with homogenous parenchymal echotexture. No focal lesions are seen.

AORTA : The upper aorta and para aortic regions appear normal.



- COMPU. PATHOLOGY • ALLERGY TESTING
- DIGITAL WHOLE BODY X-RAYS
- DIGITAL 3D SONOGRAPHY
- DIGITAL WHOLE BODY COLOUR DOPPLER
- DIGITAL 2-D ECHO WITH COLOUR DOPPLER
- E.C.G. • LUNG FUNCTION TEST
- MAMMOGRAPHY & BONE MINERAL DENSITOMETRY

- COMPUTERISED STRESS TEST
- DENTAL
- ADVANCED DENTISTRY
- PHYSIOTHERAPY
- AUDIOMETRY & SPEECH THERAPY
- FULL BODY HEALTH CHECK-UPS
- CORPORATE HEALTH CHECKUPS



NAME	MR DEVESH PATHAK	DATE	07.09.2024
		AGE	34 YRS
REF. BY DR.	MEDIWHEEL	SEX	MALE

URINARY BLADDER : Urinary bladder is well distended. No evidence of calculus or intraluminal mass seen in the bladder.

PROSTATE : Prostate is normal in size & and shows homogenous echopattern. No evidence of focal lesion.

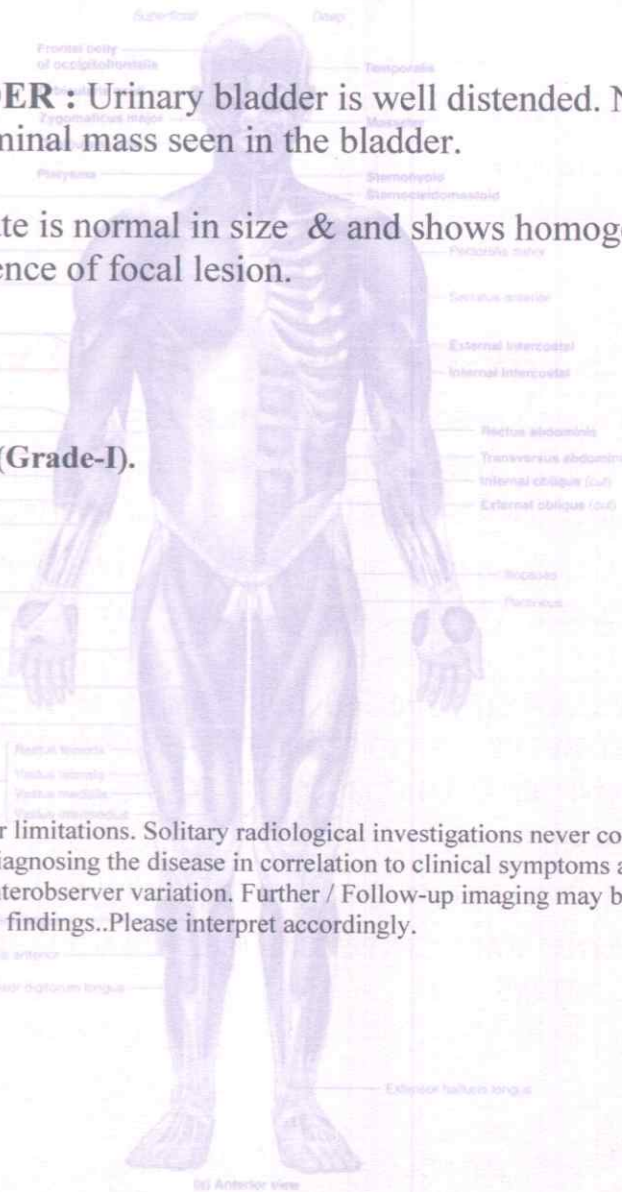
IMPRESSION :

➤ **Mild fatty liver (Grade-I).**

Suggest : Clinical correlation.


DR. SACHIN JADKAR
CONS.RADIOLOGIST.

Note : Investigations have their limitations. Solitary radiological investigations never confirm the final diagnosis. They only help in diagnosing the disease in correlation to clinical symptoms and other related tests. USG is known to have interobserver variation. Further / Follow-up imaging may be needed in some cases for confirmation of USG findings..Please interpret accordingly.



- COMPU. PATHOLOGY
- DIGITAL X-RAY
- DIGITAL SONOGRAPHY
- DIGITAL COLOR DOPPLER
- 2D ECHO CARDIOGRAPHY
- MAMMOGRAPHY & BONE MINERAL DENSITOMETRY (BMD)
- ECG ■ PFT
- COMPU. TREADMILL TEST
- PHYSIOTHERAPY
- DENTAL
- HEALTH CHECK-UP



MEDICAL CENTRE & DIAGNOSTICS

ELECTROCARDIOGRAM (ECG)

MR DEVESH PATHAK
ELIC7670 07-Sep-2024



ECG

PATIENT MR DEVESH PATHAK AGE. 34 SEX CMJ

REF. BY DR. MEDIWHEEL DATE 7/9/2024

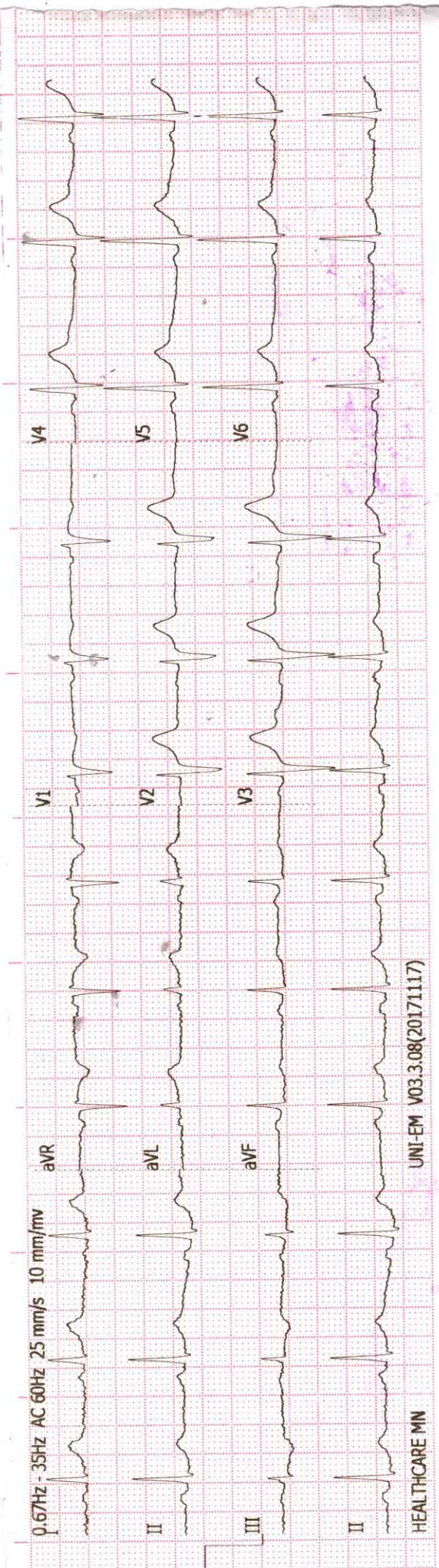
INTERPRETATION : Sino Ahythmic

Dr.

Dr. NUPUR RAI
MBBS, DIPLOMA CARDIOLOGY (PGDCC)
Reg. No. 2018115643

Healthcare
Mahavir-Suryadarshe-Soc.
Satya Nagar Road, Mahavir Nagar
Kandivali (W), Mumbai - 400 067
Tel. No. 2869 7808

EM 10/17



HOME VISIT FACILITIES CONTACT : 501.777.0000
E-mail : healthcare.medicals@gmail.com **Website :** www.healthcarediag.com
Timing : Monday to Saturday 7.00 am TO 10.00 pm Sunday 7.00 am TO 2.00 pm

History :

B.P. :

Drugs :

Standard :

Auricular Rate : *72 bpm*

Ventricular Rate :

Rhythm :

Mechanism :

Voltage :

Axis :

P. Waves :

PR Interval :

Q. Waves : *(N)*

QRS Interval :

ST Segment :

T. Waves :

QT Interval :

Extra Systoles :

REMARKS & CONCLUSIONS :

Sinus Arrhythmia