


meeliwheel



भारत सरकार
GENERAL HEALTH OPINDIA



नेता कीर्तिधर बर्निया
Naina Liladhar Baria


जन्म वर्ष / Year of Birth : 1975
वर्ग / Female 28/02/1975

DR. HARI CHHARLANI
MBBS
GENERAL PHYSICIAN
KMC REG. NO. - 91702

DR. PUSP HEALTH
GENERAL PHYSICIAN
KMC REG. NO. - 91702

3245 3325 1643

मेडिकल



47/16

आधार - सामान्य माणसाचा अधिकार

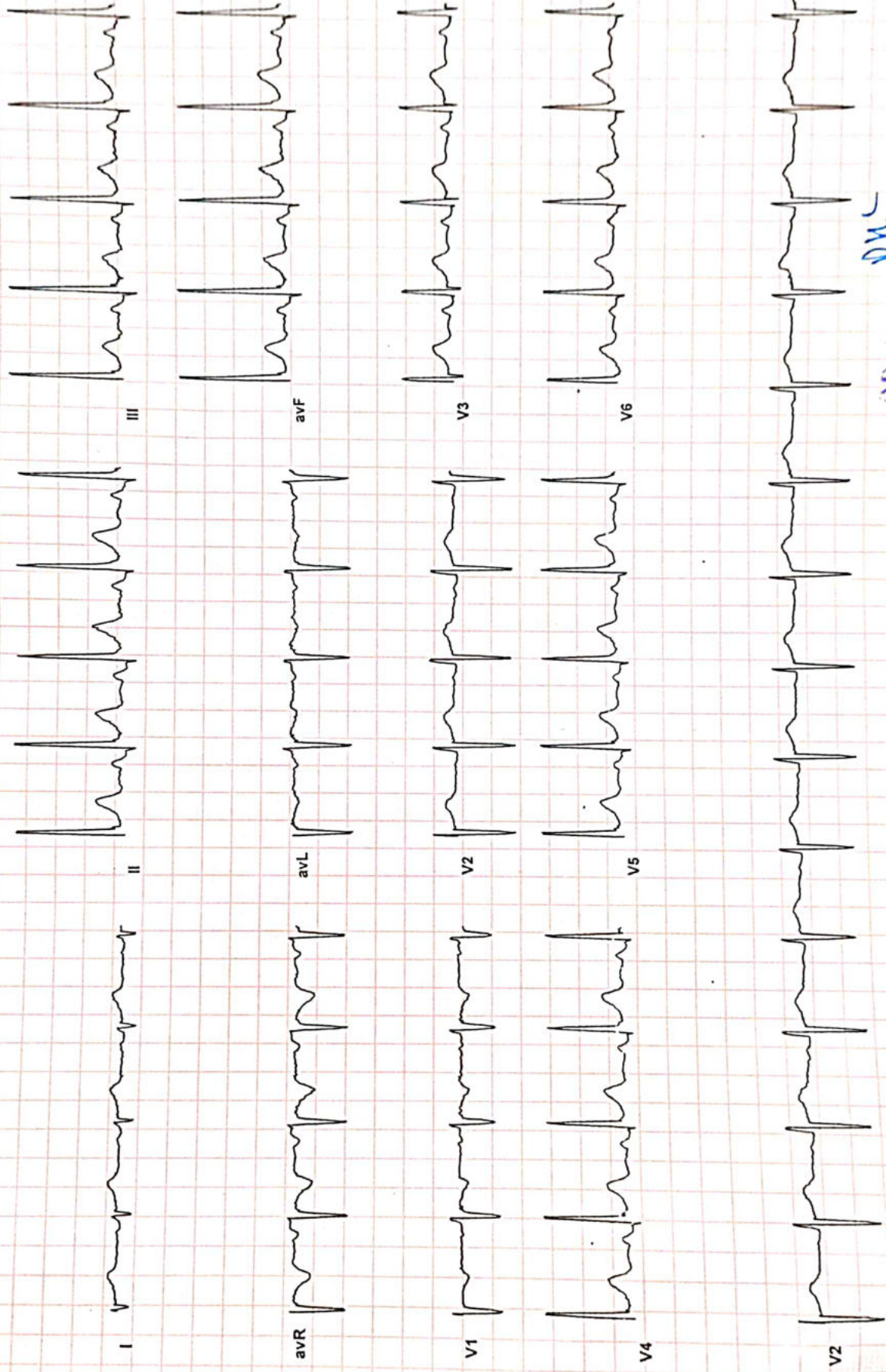
DR PLUS HEALTHCARE CENTRE- MUMBAI CENTRAL

2199 / NAINA BARIA / 48 Yrs / F

Heart Rate : 86 bpm / Tested On : 24-Sep-22 11:46:22 / HF 0.05 Hz - LF 100 Hz / Notch 50 Hz / Sn 1.00 Cm/mV / Sw 25 mm/s

/ ReFd By.: DR.HARI CHHABLANI

ECG



DR. PURVI CHHABLANI
Reported By: DR. PURVI CHHABLANI

WMC



Patient's Name : NAINA BARIA

Referred By : SELF

Report Date : 24/09/2022

Age : 48 Years

Sex : FEMALE

X- RAY CHEST

BOTH THE LUNG FIELED ARE CLEAR.

THE HILAR SHADOWS APPEAR NORMAL.

THE COSTO-PHRENIC ANGELS ARE CLEAR.

THE CARDIAC SHADOWS APPEAR NORMAL.

THE TRACHEAL IS CENTRAL IN POSITION.

THE BONY CAGE APPEARS NORMAL.

IMPRESSION : THE ABOVE EXAMINATION IS WITHIN NORMAL LIMITS.


DR. A. J. MAZUMDAR

MD. DMRE, MDRD

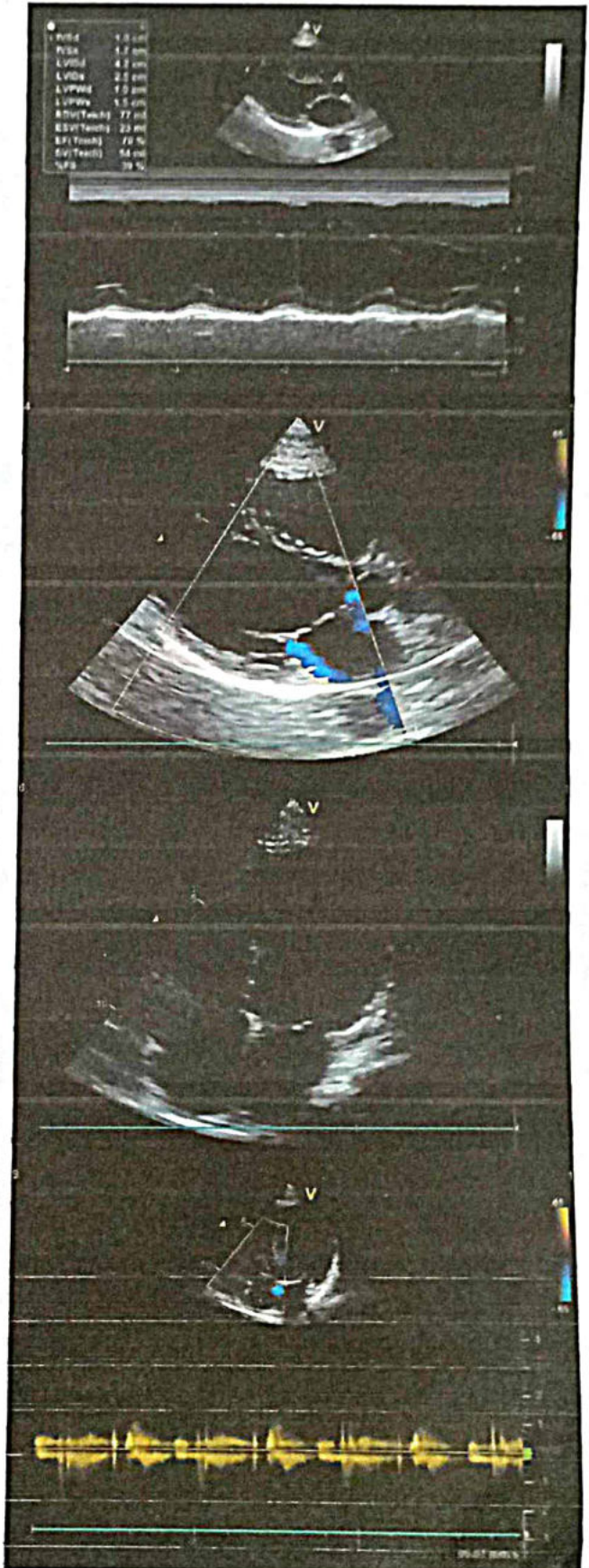
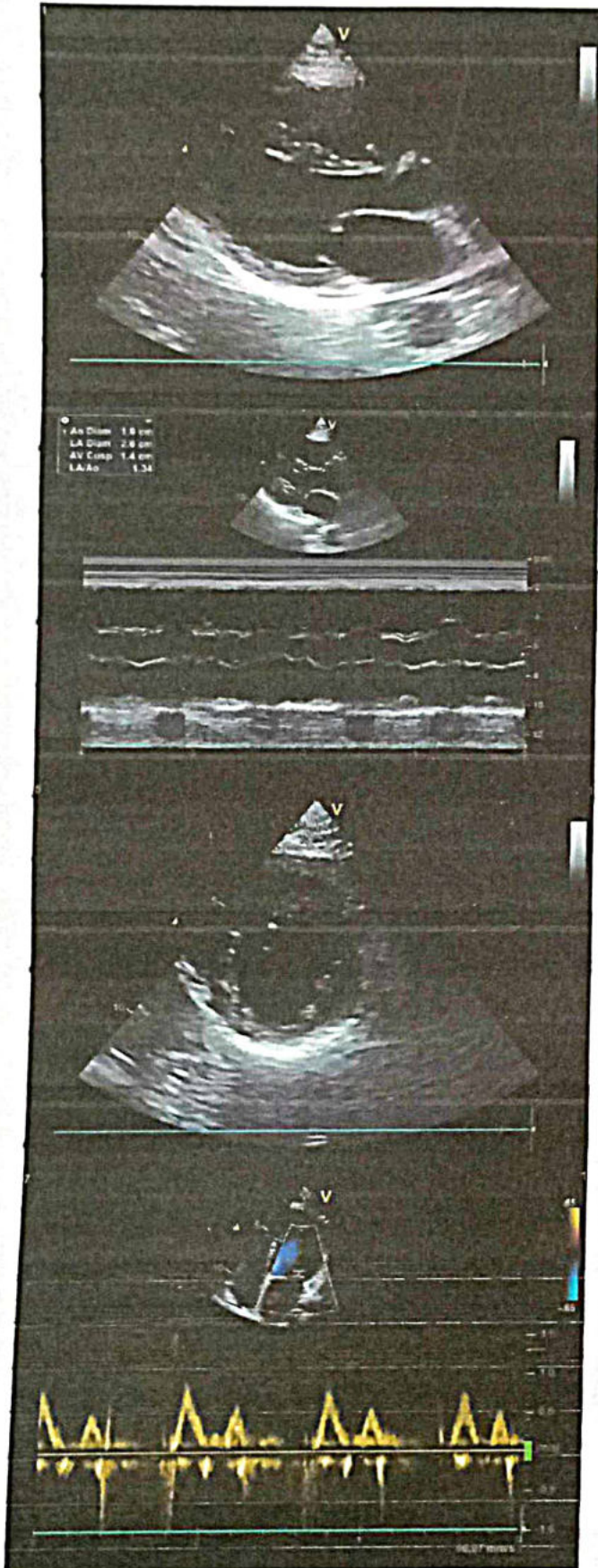
DR. PLUS HEALTHCARE CENTRE
NATHANI HEIGHTS', B-WING
42, MUMBAI CENTRAL (EAST)

Name NAINA BARIA

Age 48

Sex Female

Date 24/09/2022





NAME : NAINA BARIA

48/F

DATE:24/09/2022

REF BY : SELF

2D-ECHO. AND COLOR DOPPLER REPORT

- NORMAL CARDIAC VALVES WITH GRADE I MR, TRIVIAL TR AND AR .
- NORMAL CARDIAC CHAMBERS
- NO E/O REGIONAL WALL MOTION ABNORMALITY. WITH NORMAL LVEF OF 60 %.
- NO E/O PULMONARY HYPERTENSION .PASP 30 mmHg by TR jet.
- NO E/O LEFT VENTRICULAR HYPERTROPHY.
- NO E/O DIASTOLIC DYSFUNCTION.
- NO E/O PERICARDIAL EFFUSION.
- NO E/O INTRACARDIAC CLOT OR VEGETATION
- INTACT IAS / IVS
- **CONVENTIONL DOPPLER :**
 - E TO A RATIO IS MORE THAN ONE IN LV INFLOW.
 - THERE IS NO GRADIENT ACROSS AV, LVOT OR RVOT
 - PASP FROM TR JET IS 30 mm OF Hg.
- **COLOUR DOPPLER:**
 - TRIVIAL TR

EF Slope		110		85-120 mm/sec
Opening Amplitude		23		
Posterior leaflet				
E.P.S.S		02		mm
Mitral valve prolapse				
Vegetations				
TRICUSPID VALVE		OBSERVED		NORMAL VALUES
PULMONARY VALVE		OBSERVED		NORMAL VALUES
EF Slope				
'A' Wave				
Midsystolic notch				
Flutter				
Other Findings				
AORTIC VALVE		OBSERVE		NORMAL VALUES
Cuspal opening		14		mm
Closure line		Central		
Eccentricity index		1		
Other Findings				
DIMENSIONS		OBSERVED		NORMAL VALUES
1. Lvd (Diastolic)		42		26-52
2. Lvd (Systolic)		25		24-42mm
3. RVD (Diastolic)		18		7-23mm
4. IVST (Diastolic)		10		6-11mm
5. IVST (Systolic)		17		
6. LVPWT (Diastolic)		10		6-11mm
7. LVPWT (Systolic)		15		
8. Aortic root		22		22-37mm
9. left Atrium		26		19-40mm
	STRUCTURE	REGURG GRADING	VELOCITY m/sec	STENOSIS GRADIENT mm/Hg
			Max mean	Peak mean
MITRAL VALVE	NORMAL	0/3	/	/
TRICUSPID VELVE	NORMAL	TRIVIAL	/	/
PULMONARY VELVE	NORMAL	0/4	/	/
AORTIV VALVE	NORMAL	0/4	/	/


DR.P.H.CHHABLANI
M.B.B.S, DNB.(MEDICINE)
CONSULTANT PHYSICIAN AND CARDIOLOGIST.

DR. PURVI CHHABLANI
M.B.B.S, DNB. (Medicine)
Consultant Physician And Intensive
Reg No 77696



Dr-Plus Healthcare Centre

NATHANI HEIGHTS, B-Wing, Shop No. 51, Ground Floor, Opp. Mumbai Central Station (East), Mumbai - 400 008.

Full Name

NAINA BARIA

Life to be assured:

48/F

24/09/2022

	Type of Test	Actual Reading	Normal Range
1	Fasting Blood Sugar	94.6	70-100 mg%
2	PPBS		
3	Total Cholesterol	138.6	110 TO 140 mg%
4	VERY LOW DENSITY LEVEL(VLDL)	196.6	120-200 mg%
5	High Density Lipid (HDL)	20.3	10-30 mg/dl
6	Low Density Lipid (LDL)	55.2	40-60 mg%
7	S. Triglycerides	121.1	<u>Upto 150</u>
		128.3	50-150 mg%
8	CHOL/HDL	3.5	Upto 5
9	HDL/LDL		
10	S. Creatinine	0.4	
11	Blood Urea Nitrogen (BUN)	0.9	0.5-1.2 mg%
12	BUN/CREAT RATIO	16.5	7-21 mg%
13	S. Proteins	18.3	
14	(a) Albumin	6.5	6.0-7.9 mg%
15	(b) Globulin	3.5	3.5-5.5 mg%
16	A/G RATIO	3.0	2.0-3.5 mg%
17	S. Bilirubin	1.1	
18	(a) Direct	1.1	0.3-1.3mg%
19	(b) Indirect	0.6	0.0-0.8 mg%
20	SGOT (AST)	0.5	0.0-0.5 mg%
21	SGPT (ALT)	18.9	05-34 IU
22	GGTP (GGT)	23.4	05-40 IU
23	SGOT/SGPT	30.1	05-50 IU
		0.8	
24	HBA1C	5.6	UPTO 6.5
25	S. Alkaline Phosphatase	98.9	30-115 IU
26	T3	108.8	80-180ng/dl
27	T4	6.9	4.6-12 ug/dl
28	TSH	2.6	0.4-4.0 mIU/L
29	SERUM URIC ACID	5.4	2.5-7.2mg/dl
30	URINE SUGAR PP	ABSENT	
31	URINE SUGAR FASTING	ABSENT	
32	BLOOD GROUP	"B POSITIVE "	

DR. RAKESH PATKAR
M.D., D.N.B. (Pathology)
Reg. No. 2013/05/1660



Dr-Plus Healthcare Centre

NATHANI HEIGHTS, B-Wing, Shop No. 51, Ground Floor, Opp. Mumbai Central Station (East), Mumbai - 400 008.

Full Name

NAINA BARIA

48/F

24/09/2022

Life to be assured:

HAEMOGRAM

		Normal Range			
1.	Red Blood Cell Count	3.9	[M : 4.5 - 5.6 / F : 3.5 - 5.5/cu.mm]		
2.	Hb%	12.2	[M: 14-18 / F : 11-16%]		
3.	Hematocrit	35.6	[M : 40-53 / F : 30-47 %]		
4.	Indices:				
(a)	MCV(Mean Corpuscular Volume)	88.6	[79-101 cu.mi.]		
(b)	MCH(Mean Corpuscular Hb)	27.9	[27-32 pg]		
(c)	MCHC(Mean Corpuscular Hb Concentration)	33.5	[32-38%]		
5.	Morphology				
	Macrocytes :	--	Microcytes:	--	Hypochromia: --
	Piokilocytosis:	--	Anisocytosis:	--	
6.	Target cells:	--			
	Spherocytes:	--	Elliptocytes:	--	
7.	TOTALW.B.C.Count	5,500	{4000-11000/cu.mm}		
Differential Count					
a)	Neutrophils :	58	[45 - 70%]	c)	Eosinophils: 05 [01 - 06%]
b)	Lymphocytes :	32	[20 - 45%]	d)	Monocytes: 04 [00 - 08%]
e)	Basophils :	01	[00 - 01%]		
8.	Platelets :3.85	1.5-4.5 Lacks/cu.mm			
9.	Erythrocyte Sedimentation Rate:11	20 mm at end of 1 hour			Method : Westergrens

ROUTINE URINE EXAMINATION (RUA)

1. Physical Examination:

(i)	Colour:	YELLOW	(ii)	Sediment:	CLEAR
(iii)	Transparency:	ABSENT	(iv)	Reaction:	ACIDIC
(v)	Specific gravity	1.005			

2. Chemical Examination:

(i)	Protein :	ABSENT	(ii)	Sugar:	ABSENT
(iii)	Bile salt:	ABSENT	(iv)	Bile pigment:	ABSENT

3. Microscopic Examination:

(i)	Red Blood Cells:	ABSENT	(ii)	Epithelial Cells:	ABSENT
(iii)	Crystals:	ABSENT	(iv)	Pus Cells:	01 TO 02/HPF
(v)	Casts:	ABSENT	(vi)	Deposits:	ABSENT
(vii)	Bacteria's:	ABSENT			

DR. RAJESH PATKAR
M.D., D.N.B. (Pathology)
Reg. No. 2013/05/1660



Dr. Hari Chhablani

Cardiometabolic Physician & Intensivist
M.B.B.S., F.C.C.P. (RESP. MED.), PGDHHM,
PGDMLS, FELLOW INTENSIVE CARE MED.

ATTACHED TO: Wockhardt Hospital • Saifee Hospital • Apollo Spectra Hospital

NATHANI HEIGHTS, B-Wing, Shop No. 42, Ground Floor, Opp. Mumbai Central Station (East),
Mumbai - 400 008. • Cell : 98206 46163 • E : drharichhablani@gmail.com

PHYSICIAN REPORT

DATE : 24/09/2022

NAME : NAINA BARIA 48/F

PRESENTING COMPLAINS : NIL.

PAST HISTORY :NIL

FAMILY HISTORY: NOT SIGNIFICANT.

TREATMENT : NIL

HABITS: NIL

HT.- 157 CM. WT.- 58 Kg. BMI.-23.5

P: 86/MIN ., REGULAR BP: 120/76

EYE EXAMINATION : NEAR VISION -B/E- N6 , DISTANT VISION -B/E -6/6 COLOR VISION : NORMAL

RS: CLEAR

CVS: S1,S2 REGULAR

PA: SOFT

CNS: CLINICALLY NAD

ENT EXAMINATION : WNL

LABS: ATTACHED

2-D- ECHO : ATTACHED

ECG: ATTACHED

X-RAY : ATTACHED

IMPRESSION : : FIT ON CLINICAL MEDICAL EXAMINATION .


DR. HARI CHHABLANI
M.B.B.S;F.C.C.P.(RESP.MEDICINE) PGDHHM, PGDMLS
FELLOW INTENSIVE CARE
MMC REG. NO. - 91702

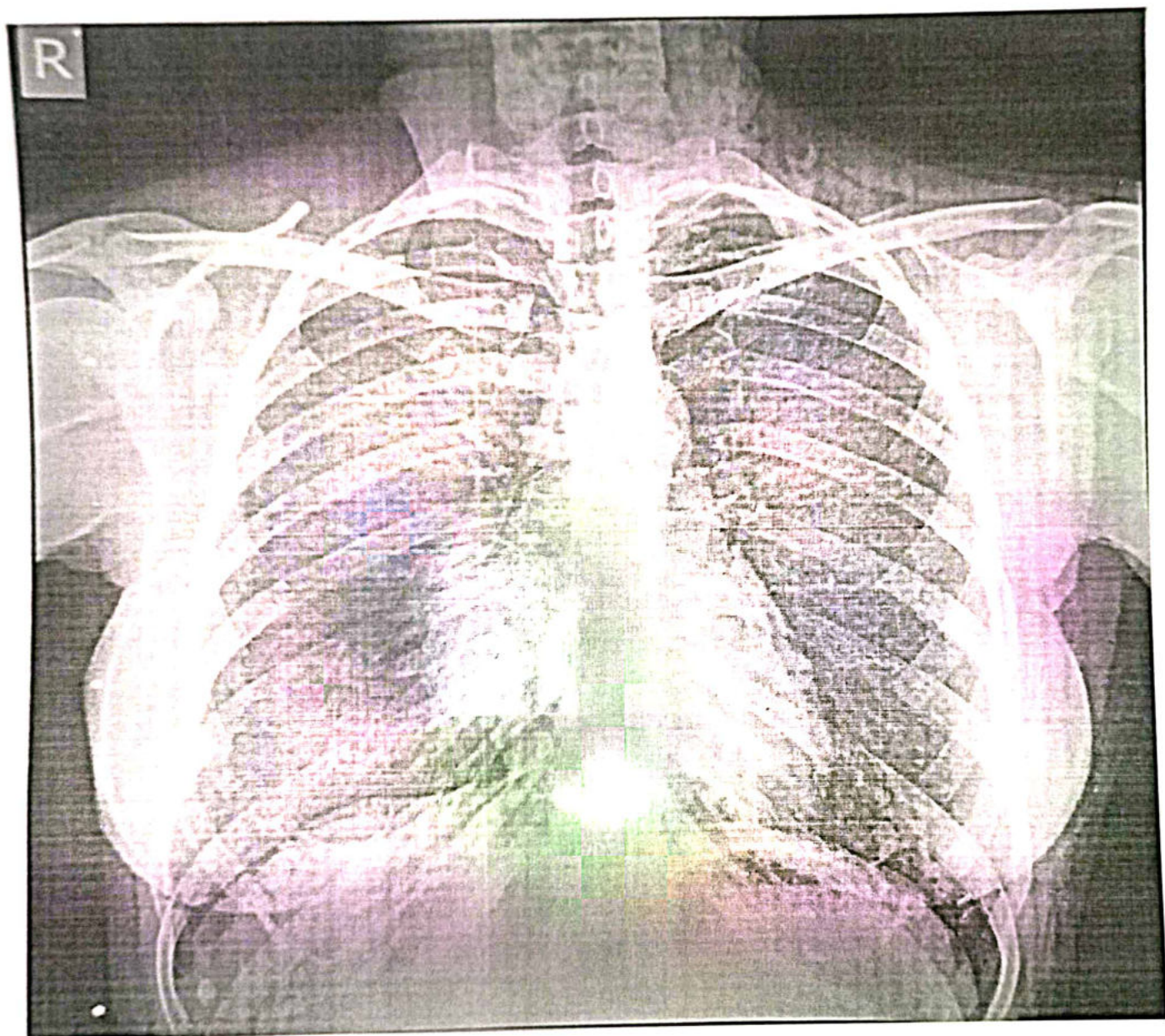
Patient's Name : NAINA BARIA

Report Date : 24/09/2022

Referred By : SELF


Age : 48 Years

Sex : FEMALE



'DR. PLUS HEALTHCARE CENTRE'
'ASTHANI HEIGHTS', B-WING,
42, MUMBAI CENTRAL (EAST)



 GPS Map Camera

Mumbai, Maharashtra, India

Shop No 65, Nathani Heights, Marzban Parsi Colony, Dalal Estate, Mumbai Central, Mumbai, Maharashtra 400008, India

Lat 18.968779°

Long 72.819974°

24/09/22 10:30 AM GMT +05:30

