



A.L.C. Advance Imaging Diagnostics

ISO 9001:2015 Certified center

(A Unit of P.K.Arogyam Health & Wellness Center)

E-95, P.C. Colony, Near Sai Netryalaya Transformer, Kankarbagh, Patna - 20

alcdiagnostics@gmail.com

www.pkarogyamhealthcheckup.com

7050037694, 8271206196

OPINION MUST BE CORRELATES WITH CLINICALLY & OTHER INVESTIGATION FOR FINAL DIAGNOSIS. NOT FOR MEDICO LEGAL PURPOSE

PATIENT NAME : Miss. BIBHA SINGH

PATIENT ID: 4069

COL DATE : 12/03/2022 REPORTING DATE: 12/03/2022 AGE SEX : 33 YRS/F

REF.BY : DR. / MEDIBUDDY..

TEST NAME	RESULT	Unit	REF.RANGE
Total Triiodothyronin T3	1.01	ng/mL	0.80 -2.00 ng/mL
Total Thyroxin T4	4.90	µg/dL	5.10 -14.10 µg/dL
Serum TSH	2.11	µIU/mL	0.27 – 4.20 µIU/mL

THYROID DISORDER (>: Increase: < Decrease: n Normal

1. T3(n) T4(n) TSH(n) :EUTHYROID STATE:
2. T3(>) T4(>) TSH(<): HYPERTHYROIDISM:
3. T3(<)T4(<) TSH(>): HYPOTHYROIDISM:
4. T3(n)T4(n) TSH(>) : SUB-CLINICAL HYPO-THYROIDISM:
5. T3(n)T4(n) TSH(<): SUB-CLINICAL HYPER-THYROIDISM:
6. T3(>) T4(n) TSH(<): T3 THYROTOXICOSIS:

Total T3/T4 level is dependent on Level:

So determination of free T3/T4is a better MARKER of Thyroid Function



Dr. Ankur Kumar
MBBS, MD
Consultant Pathologist
Reg. No 39540

ESTB BY:-

Dr. P. K. Tiwari
MD, M.Sc (Radio Imaging)
Ph.D (Alb Nuclear Medicine)
Consultant Imagiologist & Sonologist

Dr. S. Kumar
MD (Pat)
Consultant Pathologist

Dr. Abhishek Kumar
MBBS, MD
Consultant Neuropathologist

Dr. Anjali
MBBS, MD
Consultant (IMT, EEG Specialist)

Consultant Radiologist

Dr. Kumari Suman
MBBS, DGO, MD
Consultant (TVS & HSG Specialist)

PRINTING MISTAKE SHOULD BE REPORTED BACK IMMEDIATELY/ यहाँ जन्म से पहले भुण का लिंग जाँच नहीं होता है ।



A.L.C. Advance Imaging Diagnostics

ISO 9001:2015 Certified center

(A Unit of P.K.Arogyam Health & Wellness Center)

E-95, P.C. Colony, Near Sai Netryalaya Transformer, Kankarbagh, Patna - 20

alcdiagnostics@gmail.com

www.pkarogyamhealthcheckup.com

7050037694, 8271206196

OPINION MUST BE CORRELATES WITH CLINICALLY & OTHER INVESTIGATION FOR FINAL DIAGNOSIS. NOT FOR MEDICO LEGAL PURPOSE

PATIENT NAME : Mrs. BIBHA SINGH

PATIENT ID: 4069

COL DATE : 12/03/2022 REPORTING DATE: 12/03/2022 AGE SEX : 33 YRS/F

REF.BY : DR. /MEDIWHEEL.

TEST NAME	RESULT	Unit	REF.RANGE
-----------	--------	------	-----------

BLOOD SUGAR (F)	82.0 mg/dl		70 - 110 mg/dl
-------------------	------------	--	----------------

LIPID PROFILE:-

TOTAL CHOLESTROL	142.0 mg/dl		130 -250 mg/dl
------------------	-------------	--	----------------

TRIGLYCERIDE	69.2 mg/dl		50 -160 mg/dl
--------------	------------	--	---------------

HDL CHOLESTROL	40.0 mg/dl		30 - 60 mg/dl
----------------	------------	--	---------------

LDL CHOLESTROL	88.2 mg/dl		80 -130 mg/dl
----------------	------------	--	---------------

VLDL CHOLESTROL	13.8 mg/dl		15 - 40 mg/dl
-----------------	------------	--	---------------

T.CH./HDL RATIO	3.5:1		Upto 5:1
-----------------	-------	--	----------

LDL/HDL RATIO	2.2:1		2 - 4:1
---------------	-------	--	---------



Dr. Ankur Kumar
MBBS, MD
Consultant Pathologist
Reg. No 39540
Consultant Radiologist

ESTD BY:-

Dr. P. K. Tiwari
MD, M.Sc (Radio Imaging)
Ph.D (AI) Nuclear Medicine
Consultant Imaginologist & Sonologist

Dr. S. Kumar
MD (Pat)
Consultant Pathologist

Dr. Abhishek Kumar
MBBS, MD
Consultant Neuropathologist

Dr. Anjali
MBBS, MD
Consultant (TMT, EEG Specialist)

Dr. Kumari Suman
MBBS, DGO, MD
Consultant (TVS & HSG Specialist)

PRINTING MISTAKE SHOULD BE REPORTED BACK IMMEDIATELY/ यहाँ जन्म से पहले भ्रूण का लिंग जाँच नहीं होता है ।



A.L.C. Advance Imaging Dignostics

ISO 9001:2015 Certified center

(A Unit of P.K.Arogyam Health & Wellness Center)

E-95, P.C. Colony, Near Sai Netryalaya Transformer, Kankarbagh, Patna - 20

alcdiagnostics@gmail.com

www.pkarogayamhealthcheckup.com

7050037694, 8271206196

OPINION MUST BE CORRELATES WITH CLINICALLY & OTHER INVESTIGATION FOR FINAL DIAGNOSIS. NOT FOR MEDICO LEGAL PURPOSE

PATIENT NAME : Mrs. BIBHA SINGH

PATIENT ID: 4069

COL DATE : 12/02/2022 REPORTING DATE: 12/03/2022 AGE SEX:- 33 YRS/F

REF.BY : DR./ MEDIWHEEL

TEST NAME	RESULT	Unit	REF.RANGE
LFT:-			
SGPT	14.5 IU/L		5 - 48 IU/L
SGOT	17.8 IU/L		5 - 40 IU/L
ALKALINE PHOSPHATASE	67.4 IU/L		25 - 147 IU/L
TOTAL PROTIN	6.9 g/dl		6.0 - 8.7 g/dl
SERUM ALBUMIN	4.8 g/dl		3.5 - 5.4 g/dl
SERIUM GLUBLINE	2.9 g/dl		2.3 - 3.6 g/dl
AG RATIO	1.6 : 1		1.0 - 2.3 g/dl
BILRUBIN			
TOTAL	0.74 mg/dl		0.1 - 1.1 mg/dl
IRECT	0.29 mg/dl		0.0 - 0.32 mg/dl
INDIRECT	0.45 mg/dl		0.0 - 0.78 mg/dl
KFT/RFT			
URIC ACID	4.8 mg/dl		3.2 - 7.0 mg/dl
SERUM CREATNINE	0.7 mg/dl		0.6 - 1.5 mg/dl
BLOOD URIA	28.7 mg/dl		5 - 45 mg/dl
BLOOD URIA NITROZEN(BUN).	12.9 mg/dl		13 - 39 mg/dl



Dr. Ankit Kumar
MBBS, MD
Consultant Pathologist
Reg. No. 39540
Consultant Radiologist

ESTD BY-

Dr. P. K. Tiwari
MD, M.S. (Radio Imaging)
Ph.D. (Lab Nuclear Medicine)
Consultant Interventional & Geriatrics

Dr. S. Kumar
MD (Path)
Consultant Pathologist

Dr. Abhishek Kumar
MBBS, MD
Consultant Neuro Patho Physiologist

Dr. Anjali
MBBS, MD
Consultant (TMT, EEG Specialist)

Dr. Kumari Suman
MBBS, DGO, MD
Consultant (TVS & HSG Specialist)

PRINTING MISTAKE SHOULD BE REPORTED BACK IMMEDIATELY/यहाँ जन्म से पहले भ्रुण का लिंग जाँच नहीं होता है ।



A.L.C. Advance Imaging Diagnostics

ISO 9001:2015 Certified center

(A Unit of P.K.Arogyam Health & Wellness Center)

E-95, P.C. Colony, Near Sai Netryalaya Transformer, Kankarbagh, Patna - 20

alcdiagnostics@gmail.com

www.pkarogayamhealthcheckup.com

7050037694, 8271206196

OPINION MUST BE CORRELATES WITH CLINICALLY & OTHER INVESTIGATION FOR FINAL DIAGNOSIS. NOT FOR MEDICO LEGAL PURPOSE

PATIENT NAME : Mrs. BIBHA SINGH

PATIENT ID: 4069

COL DATE : 12/03/2022 REPORTING DATE: 13/03/2022 AGE SEX : 33 YRS/F

REF.BY : DR./ MEDIWHEEL.

GLYCOSYLATED HEMOGLOBIN

TEST NAME	RESULT	Unit	REF.RANGE
HbA1c	4.2 %		Below 5.7 % : Normal 5.7 – 6.4 % : Prediabetic > = 6.5 % : Diabetic
AVERAGE PLASMA GLUCOSE	93.0 mg/dl		90 – 120 mg/dl : Good Control 121 – 150 mg/dl : Fair Control 151 - 180 mg/dl: Unsatisfactory Control >180 mg/dl : Poor Control



Dr. Ankur Kumar
MBBS, MD
Consultant Pathologist,
Reg. No 39540

Consultant Radiologist

ESTD BY:-

Dr. P. K. Tiwari
MD, M.Sc (Radio Imaging)
Ph D (Air Nuclear Medicine)
Consultant Imaginologist & Sonologist

Dr. S. Kumar
MD (Pat)
Consultant Pathologist

Dr. Abhishek Kumar
MBBS, MD
Consultant Neuropatho Physiologist

Dr. Anjali
MBBS, MD
Consultant (TMT, EEG Specialist)

Dr. Kumari Suman
MBBS, DGO, MD
Consultant (TVS & HSG Specialist)

PRINTING MISTAKE SHOULD BE REPORTED BACK IMMEDIATELY/ यहाँ जन्म से पहले भ्रुण का लिंग जाँच नहीं होता है ।



A.L.C. Advance Imaging Dignostics

ISO 9001:2015 Certified center

(A Unit of P.K.Arogyam Health & Wellness Center)

E-95, P.C. Colony, Near Sai Netryalaya Transformer, Kankarbagh, Patna - 20

alcdiagnostics@gmail.com

www.pkarogayamhealthcheckup.com

7050037694, 8271206196

OPINION MUST BE CORRELATES WITH CLINICALLY & OTHER INVESTIGATION FOR FINAL DIAGNOSIS. NOT FOR MEDICO LEGAL PURPOSE

PATIENT NAME : Mrs. BIBHA SINGH

PATIENT ID: 4069

COL DATE : 12/03/2022 REPORTING DATE: 12/03/2022 AGE SEX:- 33 YRS/F

REF.BY : DR. / MEDIWHEEL.

TEST NAME	RESULT	Unit	REF.RANGE
ESR	18 mm/hr		<20 mm/hr
CBC			
Total W.B.C. Count	7100 /cumm		4000-11,000 /cumm
R B C COUNT	3.5 Million/ CUmm		4 - 7 Million/ CUmm
Platelets count	1.64 Lakh/ cumm		1.5-5.0 Lakh/ cumm
Differential Count of W.B.C.			
Neutrophils	60 %		40-70%
Lymphocytes	36 %		25-40%
Eosinophils	03 %		01-05%
Mnonocytes	01 %		00-02%
Basophiles	00 %		00-0%
HAEMOGLOBIN	9.8 gm/dl (67.1 %)		14.6 gm/dl = 100%
PCV	32.5 %		35-47 %
MCV	79.9 fl		76-96 fl
MCH	28.1 pg		29-35 pg
MCHC	30.4 %		30-38 %



Dr. Ankur Kuma
MBBS, MD
Consultant Pathologist
Reg. No 39540

Consultant Radiologist

ESTD BY-

Dr. P. K. Tiwari
MD, M.Sc (Radio Imaging)
Ph.D (Ab Nuclear Medicine)
Consultant Imagingologist & Sonologist

Dr. S. Kumar
MD (Pat)
Consultant Pathologist

Dr. Abhishek kumar
MBBS, MD
Consultant Neuropatho Physiologist

Dr. Anjali
MBBS, MD
Consultant (IMT, EEG Specialist)

Dr. Kumari Suman
MBBS, DGO, MD
Consultant (TVS & HSG Specialist)

PRINTING MISTAKE SHOULD BE REPORTED BACK IMMEDIATELY/यहाँ जन्म से पहले गुण का लिंग जाँच नहीं होता है ।



A.L.C. Advance Imaging Dignostics

ISO 9001:2015 Certified center

(A Unit of P.K.Arogyam Health & Wellness Center)

E-95, P.C. Colony, Near Sai Netryalaya Transformer, Kankarbagh, Patna - 20

www.pkarogyanhealthcheckup.com

7050037694, 8271206196

OPINION MUST BE CORRELATES WITH CLINICALLY & OTHER INVESTIGATION FOR FINAL DIAGNOSIS. NOT FOR MEDICO LEGAL PURPOSE

PATIENT NAME : Mrs. BIBHA SINGH PATIENT ID: 4069
COL DATE : 12/03/2022 REPORTING DATE: 12/03/2022 AGE SEX:- 33 YRS/F
REF.BY : DR. / MEDIWHEEL

TEST NAME	RESULT	Unit	REF.RANGE
BLOOD GROUP	: 'A'		
Rh Typing	: POSITIVE		

Note: Do always cross - matching before blood transfusion



Dr. Anku Kumar
MBBS, MD
Consultant Pathologist
Reg. No. 29714

ESTD BY-

Dr. P. K. Tiwari
MD, M.Sc (Radio Imaging)
Ph.D (Ait Nuclear Medicine)
Consultant Imaginologist & Sonologist

Dr. S. Kumar
MD (Pat)
Consultant Pathologist

Dr. Abhishek Kumar
MBBS, MD
Consultant Neuropatho Physiologist

Dr. Anjali
MBBS, MD
Consultant(TMT,EEG Specialist)

Consultant Radiologist

Dr. Kumari Suman
MBBS, DGO, MD
Consultant (TVS & HSG Specialist)

PRINTING MISTAKE SHOULD BE REPORTED BACK IMMEDIATELY/यहाँ जन्म से पहले भुण का लिंग जॉच नहीं होता है ।

ID: 4069 CASE: 1 BIBHA SINGH
AGE: 33Y 0M 08D FEMALE
160Cms 51Kg

12/03/2022 10:37:37
ALC ADVANCE IMAGING DIAGNOSTICS
E95 PC COLONY KANKARBAGH PATNA

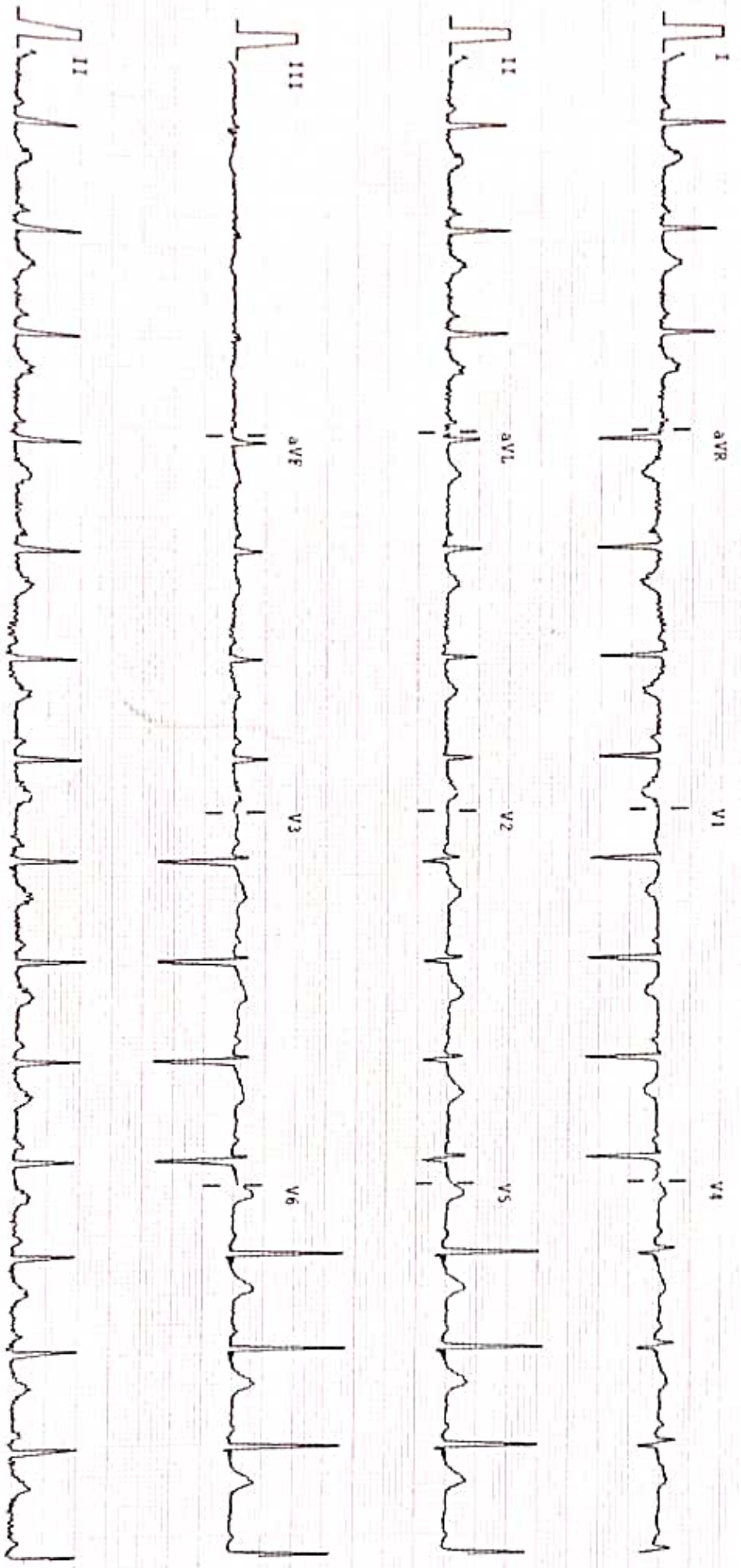
RATE 88 bpm SINUS RHYTHM
P-R 678 ms POOR R WAVE PROGRESSION
P-R 124 ms
QRS 74 ms
QT 356 ms
QTc 405 ms

--AXIS--
P 46°
QRS 33°
T 21°

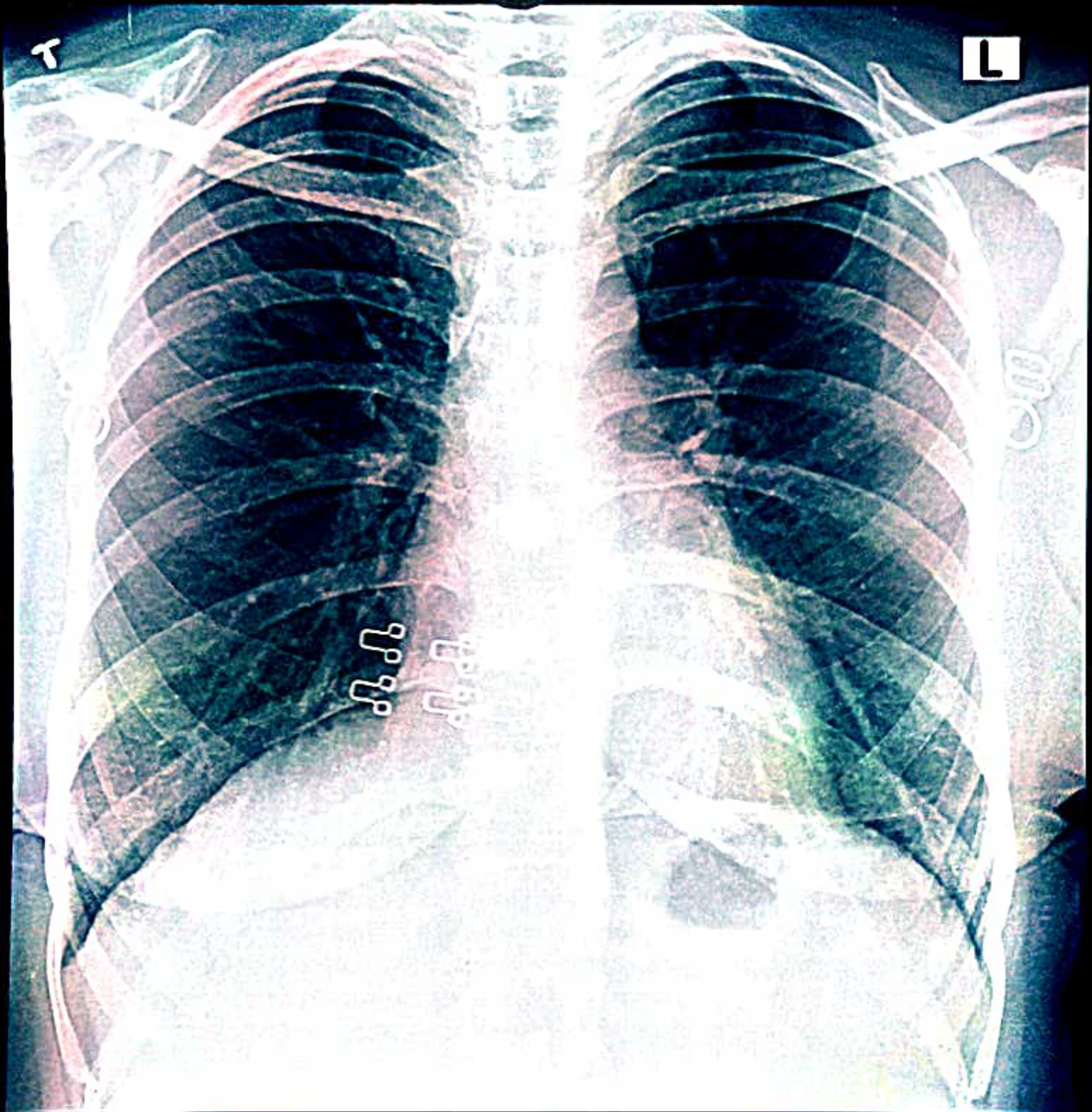
12 SL. REPORT FORMAT 3x4+1L SO REF: DR BOB DR DR ABHISHEK KUMAR MBBS MD



Dr. Abhishek Kumar
MBBS, MD



25mm/sec 10mm/mV Notch: ON ELC: ON 0.05 - 35Hz ALLENGERS PISCES 1012(VER.--- 1.8) CLINICALLY CORRELATE THE FINDINGS.



BIBHA SINGH AGE 33 YEARS BY DR. MEDIWHEEL CHEST,FRN P->A 3/12/2022
A.L.C. Advance Imaging Diagnostics Centre PATNA - 20



A.L.C. Advance Imaging Diagnostics

ISO 9001:2015 Certified center

(A Unit of P.K.Arogyam Health & Wellness Center)

E-95, P.C. Colony, Near Sai Netryalaya Transformer, Kankarbagh, Patna - 20

alcdiagnostics@gmail.com

www.pkarogyamhealthcheckup.com

7050037694, 8271206196

OPINION MUST BE CORRELATES WITH CLINICALLY & OTHER INVESTIGATION FOR FINAL DIAGNOSIS. NOT FOR MEDICO LEGAL PURPOSE

Pt. Name :- **BIBHA SINGH**
Ref. By :- **DR. B O B**

Date:- **14-Mar-22**
Age / Sex – **33 Yrs. F.**

Thanks for your kind referral

X-RAYCHEST (P.A.VIEW)

The lungs on the either side show equal translucency.

The peripheral pulmonary vasculature is normal.

No focal lung lesion is seen.

The pleural spaces are normal.

Both hila are normal in size, have equal density and bear normal relationship.

The heart and trachea are central in position and no mediastinal abnormality is visible.

The cardiac size is normal.

The domes of the diaphragms are normal in position, and show smooth outline.

IMPRESSION

- NO EVIDENCE OF PULMONARY OR CARDIAC PATHOLOGY IS NOTED.


Dr. A. K. Singh
MBBS, PGDMGH
Consultant Radiologist

Consultant Radiologist

ESTD BY:-

Dr. P. K. Tiwari
MD, M.Sc (Radio Imaging)
Ph.D (All Nuclear Medicine)
Consultant Imagingologist & Sonologist

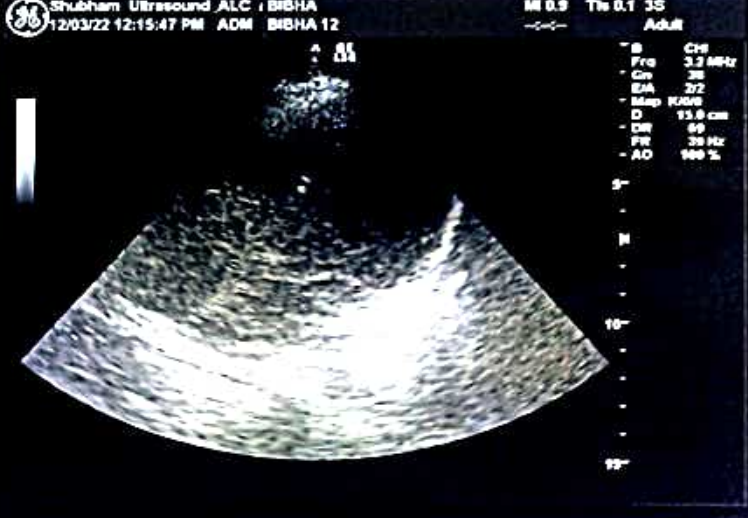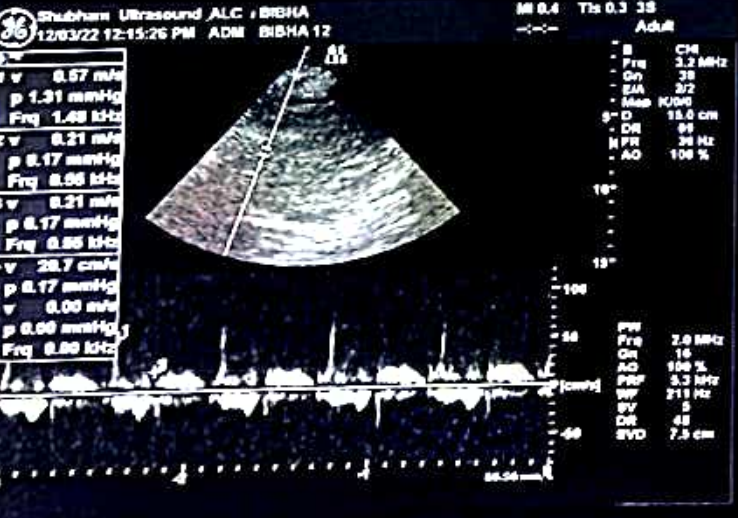
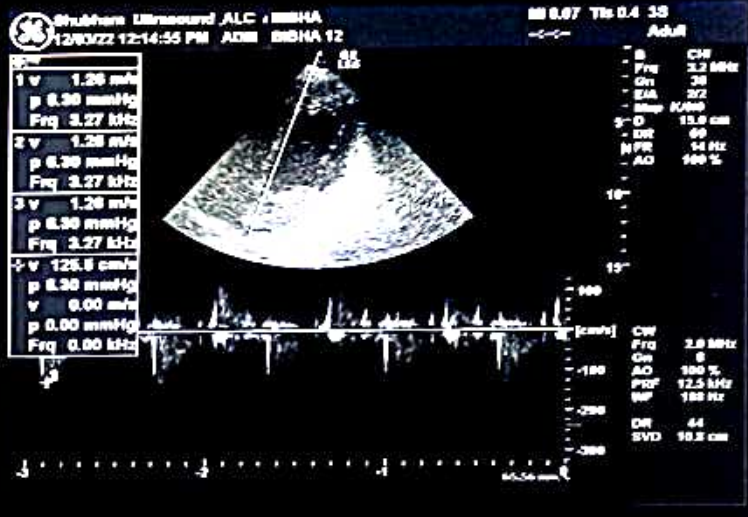
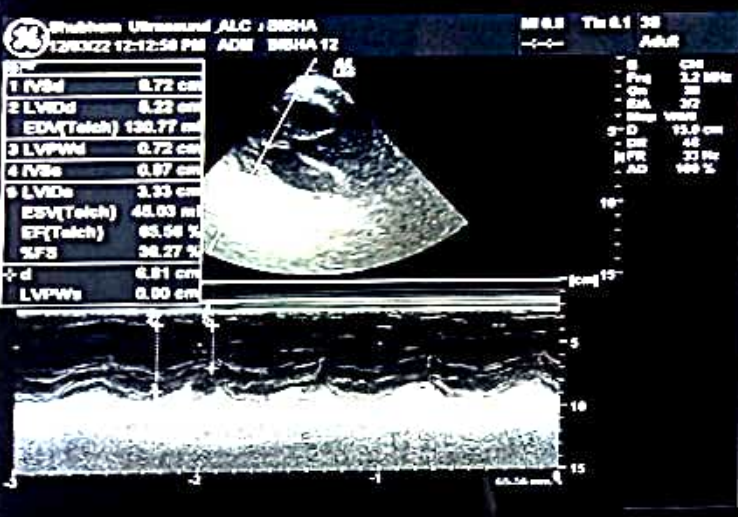
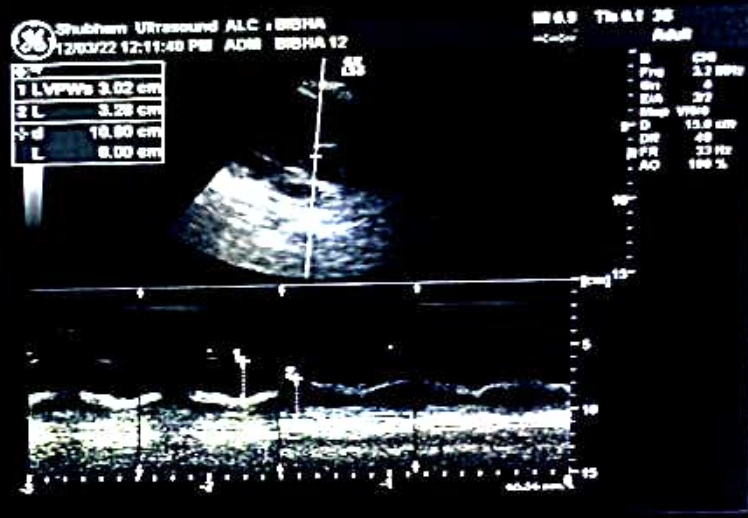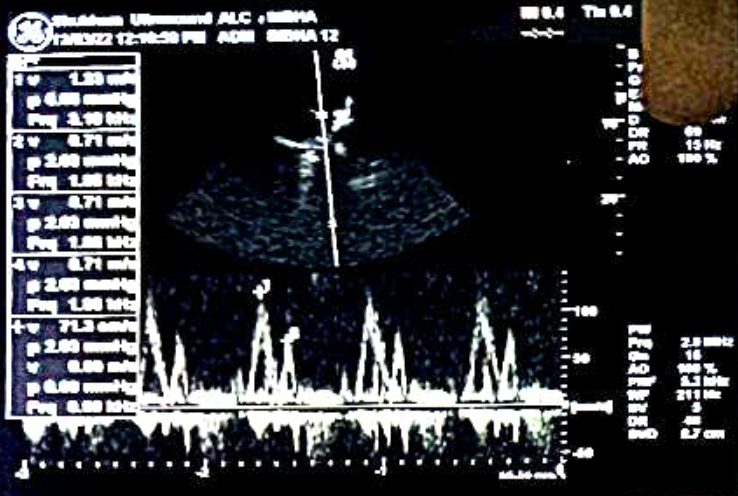
Dr. S. Kumar
MD (Pat)
Consultant Pathologist

Dr. Abhishek Kumar
MBBS, MD
Consultant Neuropathology Physiologist

Dr. Anjali
MBBS, MD
Consultant (TMT, EEG Specialist)

Dr. Kumari Suman
MBBS, DGO, MD
Consultant (IVS & HSG Specialist)

PRINTING MISTAKE SHOULD BE REPORTED BACK IMMEDIATELY/ यहाँ जन्म से पहले भ्रूण का लिंग जाँच नहीं होता है ।





A.L.C. Advance Imaging Diagnostics

ISO 9001:2015 Certified center

(A Unit of P.K.Arogyam Health & Wellness Center)

E-95, P.C. Colony, Near Sai Netryalaya Transformer, Kankarbagh, Patna - 20

alcdiagnostics@gmail.com

www.pkarogyamhealthcheckup.com

7050037694, 8271206196

OPINION MUST BE CORRELATES WITH CLINICALLY & OTHER INVESTIGATION FOR FINAL DIAGNOSIS. NOT FOR MEDICO LEGAL PURPOSE

ECHOCARDIOGRAPHY & COLOR DOPPLER REPORT

Patient's Name : Mrs. BIBA SINGH

Age/Sex : 32 Yrs /F

Ref. by : B O B

Date : 14-Mar-22

ECHOCARDIOGRAPHIC WINDOW: Fair

2D & M MODE ECHOCARDIOGRAPHY

Left ventricle

EDD:	52	mm (20 - 28 mm / m ²)	ESD:	33	mm(13 - 21 mm / m ²)
IVS :	10	mm (6 - 11 mm)	PW:	8	mm(6 - 11 mm)
Ejection fraction:	65% (61 ± 8%)		FS:	35	%(34 - 44 %)
IVS:	Intact		LV clot	Absent	

Left atrium/ Aorta 33/30 mm

Right ventricle Normal

Right atrium Normal

Pericardium Normal with no pericardial effusion

2D:

Normal LA/LV Size and normally contracting left ventricle. No RWMA, concentric LVH

Mitral valve

AML/ PML: Normal

Tricuspid valve Normal

Aortic valve Normal

Pulmonary valve Normal

Continuous & Pulse Wave Doppler study

Valve	Velocity (m/sec)			Gradient (mmHg)			Valve area (PHT Method)	Regurg.
	Peak	Mean	EDV	Peak	Mean	EDG		
Mitral	E=1.2 A=0.7			6.0	2.0			Nil
Tricuspid	E=1.5 A=0.2			1.3	0.2			Nil
Aortic	1.3			5.0	2.5			Nil
Pulmonary	6.3			3.5	1.7			Nil



ESTD BY:-

Dr. P. K. Tiwari
MD, M.Sc (Radio Imaging)
Ph.D (AI) Nuclear Medicine
Consultant Imaginologist & Sonologist

Dr. S. Kumar
MD (Pat)
Consultant Pathologist

Dr. Abhishek Kumar
MBBS, MD
Consultant Neuropatho Physiologist

Dr. P. Tiwari
MBBS, MD
Consultant (TMT, EEG Specialist)

Consultant Radiologist

Dr. Kumari Suman
MBBS, DGO, MD
Consultant (TVS & HSG Specialist)

PRINTING MISTAKE SHOULD BE REPORTED BACK IMMEDIATELY/ यहाँ जन्म से पहले भ्रुण का लिंग जाँच नहीं होता है ।

A.L.C. Advance Imaging Dignostics

ISO 9001:2015 Certified center

(A Unit of P.K.Arogyam Health & Wellness Center)

E-95, P.C. Colony, Near Sai Netryalaya Transformer, Kankarbagh, Patna - 20

alcdiagnostics@gmail.com

www.pkarogayamhealthcheckup.com

7050037694, 8271206196

OPINION MUST BE CORRELATES WITH CLINICALLY & OTHER INVESTIGATION FOR FINAL DIAGNOSIS. NOT FOR MEDICO LEGAL PURPOSE

Colour Flow Imaging

No TR, No MR/PR, No AR

No flow shunt

COMMENTS :

- ◆ Normal size all chamber
- ◆ Normal LV filling Pressure
- ◆ No RWMA
- ◆ Normal LV systolic function
- ◆ Grade I LV diastolic dysfunction.
- ◆ Global LVEF = 60%
- ◆ All cardiac valves are normal
- ◆ No PAH, Mild concentric LVH
- ◆ No MS / TS / AS / PS / PR
- ◆ No clot / vegetation / pericardial effusion.

IMPRESSION:

All chambers are normal

No RWMA, No PAH

Grade I LV diastolic dysfunction.

Normal LV systolic function, LVEF – 60%

Please correlate clinically

DR. SANDEEP KUMAR MBBS MD

DR. SANDEEP KUMAR

MBBS, MD (Med.)

Reg. No.-BCMR33225



Consultant Radiologist

ESTD BY-

Dr. P. K. Tiwari

MBBS, MSc (Radio Imaging)

Ph.D. (AB Nuclear Medicine)

Consultant Imagingologist & Sonologist

Dr. S. Kumar

MBBS (Path)

Consultant Pathologist

Dr. Abhishek Kumar

MBBS, MD

Consultant Neuropsychologist

Dr. Anjali

MBBS, MD

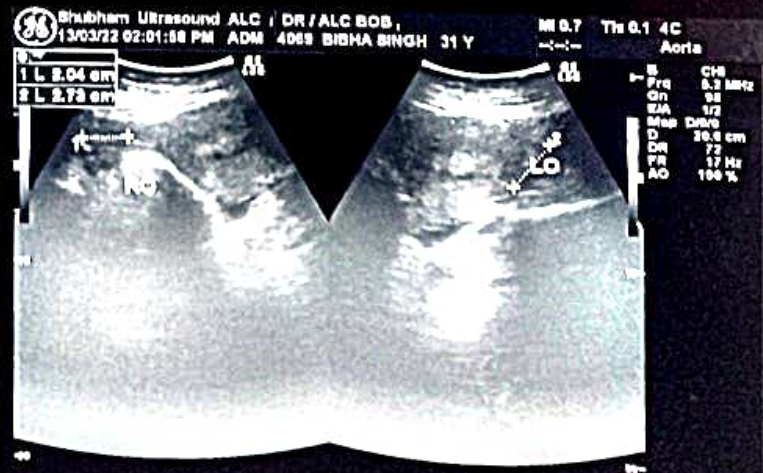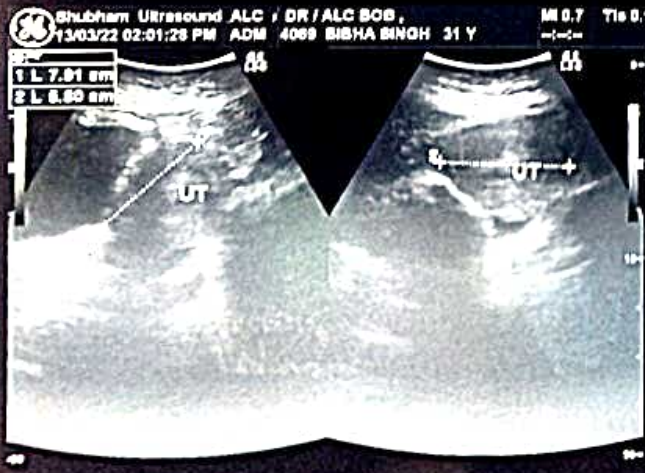
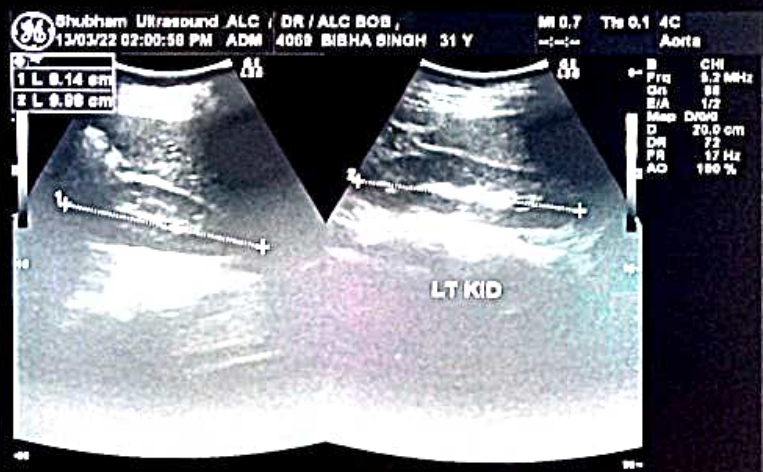
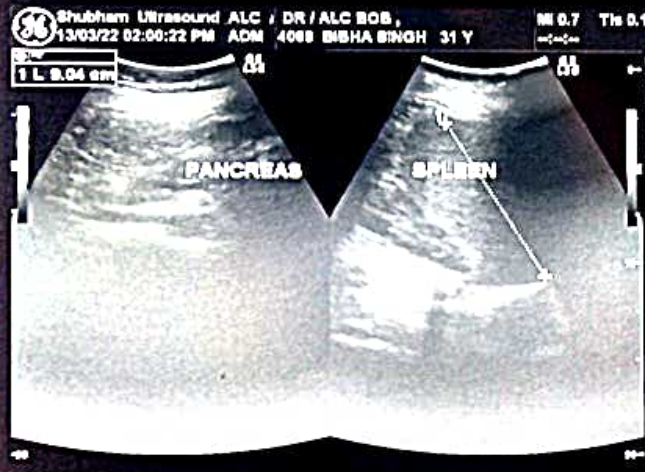
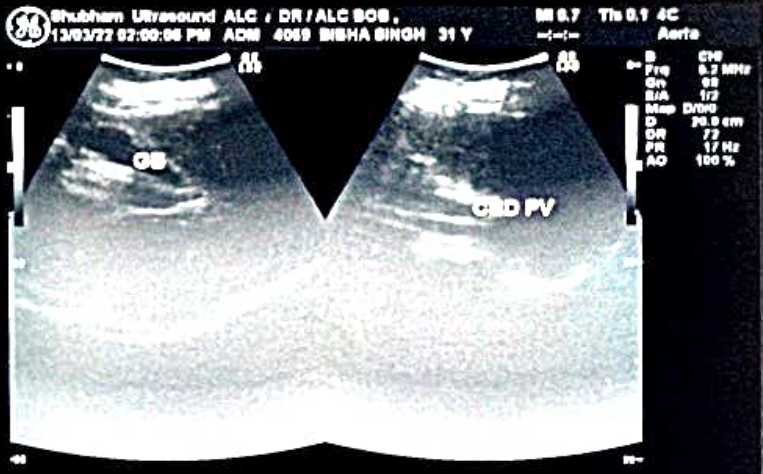
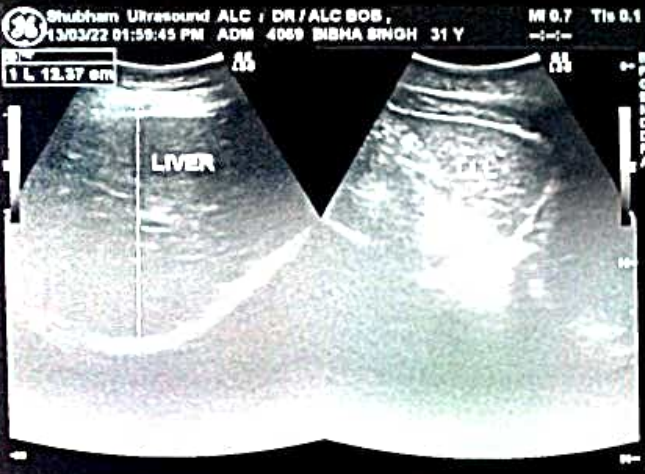
Consultant (TMT EEG) Specialist

Dr. Kumari Sumati

MBBS, DNB, MD

Consultant (IVS & HSG) Specialist

PRINTING MISTAKE SHOULD BE REPORTED BACK IMMEDIATELY/ यहाँ जन्म से पहले भुण का लिंग ज्ञान नहीं होता है ।





SUBHAM IMAGING & A.L.C. DIAGNOSTICS CENTRE

H.O. : Ajay Market, Bank of Baroda Building, East Ashok Nagar, Kankarbagh, Patna - 20

B.O. : Khanpura Road (Below Gyan Sharowar School), Paliganj, Patna.

e-mail : shubham.pat.usg@gmail.com # website : www.pkarogayamhealthcheckup.com

OPINION MUST BE CORRELATES WITH CLINICAL & OTHER INVESTIGATION FOR DIAGNOSIS NOT FOR MEDICO LEGAL PURPOSE

Pl. Name :- **BIBHA SINGH**

Ref. By :- **DR BOB**

Date:- **13-Mar-22**

Age / Sex - **31 Yrs. F.**

REAL TIME U.S.G. OF WHOLE ABDOMEN

Thanks for your kind referral

(Report.)

- LIVER** :- Measures 12.89 cm. Normal in shape, size and echo texture. I.H.B.R. are not dilated. Hepatic veins are normal. No SOL seen.
- G.BL.** :- Lumen is echo free. Wall thickness appears normal.
- C.B.D.** :- Measures 3.3 mm in diameter with echo free lumen. No calculi or mass seen.
- P.V.** :- Measures 7.2 mm in diameter. Appears normal. No thrombus seen.
- PANCREAS** :- Normal in shape, size and echo texture. No calcification mass seen.
- SPLEEN** :- Measures 9.89 cm. Normal in shape, size and echo texture. No SOL seen.
- KIDNEY** :- Both kidney shows normal shape, size & echotexture. C.M.D.intact. P.C.S.is not dilated. No calculi, cyst or hydronephrosis seen on either side.
Right Kidney :- Measures 9.80 X 3.1 cm.
Left Kidney :- Measures 9.60 X 3.2 cm.
- URETER** :- Not dilated. No apparent calculi seen.
- U.BLADDER**:- Shows normal in outline with echo free lumen. No calculi or mass seen.
Pre void - 210 ml. Post void - is in significant
- UTERUS** :- Is normal in size, shape & position measuring 7.30 X 5.10 cm. Endometrial And Myometeriam appears normal in limits No focal mass lesion seen
- ADNEXA** :- Both ovary appears normal in size and shape.
Rt Ovary Measures - 2.10 cm Lt Ovary Measures 2.30 cm
- P.O.D** :- No collection seen in P.O.D
- R.I.F.** :- Son graphically no appendicular mass or collection seen.
- OTHERS** :- No Ascites. no Lymph Adenopathy. No pleural effusion seen on either side.

IMPRESSION

➤ **Son graphically normal scan no detectable lesion seen**



ESTB BY:-

Dr. P. K. Tiwari

MD, M.Sc (Radio Imaging)

Ph.D (Alt Nuclear Medicine)

Consultant Imajionologist & Sonologist

Dr. S. Kumar

MD. (Pat)

Consultant Pathologist

Dr. A. K. Singh
MBBS, PGDMCH
Consultant Radiologist
13/3/22
Consultant Radiologist

Dr. A. K. Singh

MBBS, PGDMCH

Consultant Radiologist & Sonologist

PRINTING MISTAKE SHOULD BE REPORTED BACK IMMEDIATELY/ यहाँ जन्म से पहले भुण का लिंग जाँच नहीं होता है ।



A.L.C. Advance Imaging Diagnostics

ISO 9001:2015 Certified center

(A Unit of P.K.Arogyam Health & Wellness Center)

E-95, P.C. Colony, Near Sai Netryalaya Transformer, Kankarbagh, Patna - 20

alcdiagnostics@gmail.com

www.pkarogyamhealthcheckup.com

7050037694, 8271206196

OPINION MUST BE CORRELATES WITH CLINICALLY & OTHER INVESTIGATION FOR FINAL DIAGNOSIS. NOT FOR MEDICO LEGAL PURPOSE

PATIENT NAME : Mrs .SUDHA RANI PATIENT ID: 4076
COL DATE : 12/03/2022 REPORTING DATE: 12/03/2022 AGE SEX:- 53 YRS/F
REF.BY : DR. /MEDIWHEEL.

ROUTINE EXAMINATION OF URINE

PHYSICAL EXAMINATION

Quantity	15 ml	Colour....	Straw
Appearance...	Clear	Sediment ...	Nil
Specific gravity....	1.010		

CHEMICAL EXAMINATION

Reaction	6.0	Nitrite.....	Not done
Sugar	Nil	Bile Pigment	Not done
Albumin	Nil	Urobilinogen....	Not done
Excess of Phosphate....	Nil	Chile.....	Not done
Bile Salt	Not Done	Acetone...	Not done

MICROSCOPIC EXAMINATION

Erythrocytes....	Nil	Casts	Nil
Leucocytes	1-3 / HPE	Crystals....	Nil
Epith. Cell	A, Few		Nil



Dr. Ankur Kumar
MBBS, MD
Consultant Pathologist
Reg. No 39540

Consultant Radiologist

ESTD BY-

Dr. P. K. Tiwari
MD, M.Sc (Radio Imaging)
Ph.D (Art Nuclear Medicine)
Consultant Imagingologist & Sonologist

Dr. S. Kumar
MD (Pat)
Consultant Pathologist

Dr. Abhishek Kumar
MBBS, MD
Consultant Neuropathology & Physiologist

Dr. Anjali
MBBS, MD
Consultant (TMT, EEG Specialist)

Dr. Kumari Suman
MBBS, DGO, MD
Consultant (TVS E- HSG Specialist)

PRINTING MISTAKE SHOULD BE REPORTED BACK IMMEDIATELY/ यहाँ जन्म से पहले भ्रूण का लिंग जाना नहीं होता है ।